

How to Cite:

Reddy, J. V., Kumari, K. P., & Lokanadham, S. (2022). A study on arterial patterns of human heart and their variations by using post-mortem coronary arteriogram in Tirupathi population. *International Journal of Health Sciences*, 6(S5), 6233–6241. <https://doi.org/10.53730/ijhs.v6nS5.10122>

A study on arterial patterns of human heart and their variations by using post-mortem coronary arteriogram in Tirupathi population

J. Vasudeva Reddy

Professor, Department of Anatomy, Sri Padmavathi Medical College (W), Tirupathi, Andhra Pradesh-517502,

K. Praveena Kumari

Research Scholar, Department of Anatomy, Bharath Institute of Higher Education and Research, Chennai-600073.

S. Lokanadham

Associate Professor, Department of Anatomy, Santhiram Medical College, Nandyal, Kurnool, Andhra Pradesh - 518501.

Corresponding author email: drsadhuln.anatomy@gmail.com

Abstract---Background: The impact of post-mortem angiography increases because of the rapid evaluation of organ-specific vascular patterns, vascular alteration under pathologic and physiologic conditions and tissue changes induced by artificial and unnatural causes. Aim: To study the human heart arterial patterns and their variation by using post-mortem arteriogram. Materials and Methods: Eighty human fresh heart specimens were obtained from the Forensic Department, S.V. Medical College, Tirupati. The hearts were perfused with normal saline followed by injection of barium sulphate suspension and ligated at the proximal end of coronary arteries. Skiagrams were taken in different views and studied. Results: we have observed all the branches of right and left coronary arteries. The right and left dominance pattern, Vieussens annulus, anastomosis between the great blood vessels and posterior interventricular branches, AV nodal, SA nodal branches and variations of branches were noted in our study Conclusion: Our study will be useful in analyzing the arterial system of the heart and gives valuable supplement to conventional autopsy procedures.

Keywords---coronary arteriogram, post-mortem angiography, human heart.

Introduction

The vascular system has always been difficult to visualize, but large vessels may be observed with clarity by using angiograms¹ (Aghayev et al.,2005). It is possible to establish a post-mortem circulation that permits visualization of the arterial, parenchymal, and venous phases in comparison with clinical angiography (Grabherr et al.,2006). Variations of coronary arteries can be fatal and lead to sudden death during strenuous activity. They include an additional orifice for a third coronary artery usually anterior to the right coronary ostium in the anterior aortic sinus and anastomoses with left coronary artery in the form of circle around pulmonary trunk termed Annulus of Vieussens (Robicsek et al.,1967). The heart is supplied by two coronary arteries, a right and a left one. Right coronary artery originates from anterior aortic sinus at the root of the ascending aorta and left coronary artery from left posterior aortic sinus at the root of the ascending aorta. Variant cardiac anatomy has great importance to understand and manage cardiac diseases (Dombe et al., 2012). The present study aims to study the human heart arterial patterns and variation of branches by using post-mortem arteriograms.

Materials and Methods

Eighty human fresh heart specimens were obtained from the Forensic Department, S.V. Medical College, Tirupati to study the arterial pattern of heart from the origin of coronary arteries to their termination. The coronary ostia were visualised and approached by splitting open and trimming ascending aorta longitudinally from its distal cut end. A polyethylene catheter was introduced into the coronary ostia and passed for some distance into the proximal part of main stems of right and left coronary arteries. A black silk ligature was applied around each vessel to keep the catheter in position and to prevent retrograde flow of the radio opaque substance. The heart was then perfused with a 20 ml syringe, with normal saline followed by injection of barium sulphate suspension (25% suspension in distilled water). The injection was done at constant pressure for possible entry into all branches. Subsequently, while withdrawing the catheter, a ligature was applied at the most proximal part of coronary arteries to prevent the radio opaque medium from coming out of the blood vessels. The procedure was performed over both the coronary arteries. The skiagrams were taken in postero-anterior, antero-posterior and right anterior oblique view and studied. The ethical committee clearance was taken from the S.V.Medical College Ethical Committee, Tirupathi.

Results

We have utilized 80 human fresh hearts obtained from forensic department to study the coronary vascular pattern by using post-mortem coronary angiography. Anomalous origin of 4 coronary ostia from the right sinus of Valsalva was observed in a patient with hypertrophic cardiomyopathy. Right atrial branches, right marginal artery and posterior interventricular branches of right coronary artery, and left coronary artery branches like left anterior descending, diagonal, left marginal and left circumflex arteries were visualized. We have also observed anastomoses of septal perforators (Figure 1). The right coronary artery terminated

at crux and beyond in 59 hearts (74%), right to the crux in 16 hearts (20%) and at the right border in 5 hearts (6%). The antero-posterior view of arteriograms showed a posterior interventricular branch of right coronary artery in 86% cases, indicating right coronary dominance (Figure 2). Right anterior oblique view of post-mortem coronary angiograms showed a sino atrial nodal branch arising from the left circumflex branch of left coronary artery (23.33%) or from the right coronary artery (76.6%) [Table 1]. The branches of the right and left coronary arteries were also visualized (Figure 3). Antero posterior view of arteriograms showed atrioventricular nodal artery arising from either the right (90%) or left coronary artery (10 %; Figure 4). Blood supply to sino atrial node from the right coronary artery was noted in 76.6% of cases and from the left coronary circumflex branch in 23.3% of cases. Blood supply to atrioventricular node was from the right coronary artery in 90% cases and from the left coronary artery in the remaining 10% cases. Left anterior oblique view of post-mortem arteriograms showed sinoatrial nodal artery, annulus of Vieussens and right dominance (Figure 5). Antero posterior view of arteriograms showed posterior interventricular branch from the left circumflex indicating left dominance in 10% cases (Figure 6). Anteroposterior view of arteriograms showed that left anterior descending artery went around the apex to the posterior part of interventricular septum in one case (Figure 7).

Discussion

Angiography provides legal documentation and can serve to guide subsequent cardiac dissection. The extra ostium due to conus branch aroused directly from aorta was observed in 50% of cases (Beach et al.,2001). Right coronary artery ended at right margin of the heart 1 in 82 cases and also failed to reach posterior interventricular sulcus in 6% of hearts and travelled beyond the crux in 84% cases (Williams et al., 1995; James, 1961). The sino atrial node was supplied from the right coronary artery in 55% cases, from the left circumflex in 45% of hearts (Becker and Anderson, 1980).In an another study sinoatrial node was supplied from the right coronary artery in 65% cases and 35% from circumflex branch of left coronary artery (Baroldi and Scmazzone,1976). It was found that the branch to SA node arose as the branch of right coronary artery in 55% of cases in computed tomography angiograms (Kini et al.,2007).Coronary predominance in the present study showed 86% hearts with right coronary dominance, 11 % of hearts with left predominance and 3% hearts with balanced type of circulation. The right predominance was observed in 70% of hearts, left predominance in 20% of hearts and 10% balanced type of circulation (Schlesinger, 1940; Desmet et al., 1992). It was found that left circumflex to be dominant in 19.5% of the cases, while they found co-dominance in 20% of the cases (Mian et al.,2011). In 6000 selective arteriograms that right coronary dominance was present in 60% of persons (Grabherr et al., 2007; Smith et al., 1999). The results of our study are in agreement with previous literature and variations in the present study may be due to embryological malformations but the knowledge of such variations is important to surgeons before planning a heart surgeries.

Acknowledgements

The authors are also grateful to authors, editors and publishers of all those articles, journals and books from where the literature for this article has been reviewed and discussed.

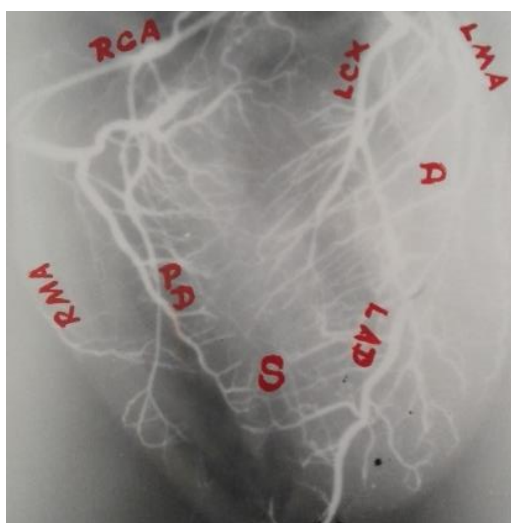
References

1. Aghayev E., Thali M.J., Sonnenschein M., Hurlimann J., Jackowski C., Kilchoer T., Dirnhofer R. (2005) Fatal steamer accident; blunt force injuries and drowning in post-mortem MSCT and MRI. *Forensic Sci Int.* 152: 65-71.
2. Becker AE, Anderson RH. (1983) *Cardiac Pathology. An Integrated Text and Colour Atlas.* Edinburgh, Churchill Livingstone. Pp 17.
3. Baroldi G, Mantero O, Scomazzoni G. (1976) The collaterals of the coronary arteries in normal and pathological heart. *Circulation Res.* 4: 223.
4. D.Dombe., T. Anitha., P. A. Giri ., S. D. Dombe ., M. V. Ambiyee. (2012) Clinically relevant morphometric analysis of left coronary artery. *International Journal of Biological and Medical Research.* 3 (1):1327-1330.
5. Desmet., W. Vanhaecke J V rolis., M. Piessens J. (1992) Isolated single coronary artery a review of 50,000 consecutive coronary angiographies. *Eur Heart J.* 13:1637 -40.
6. Grabherr S., Djonov V., Friess A., Thali MJ., Ranner G., Vock P., Dirnhofer R. (2006) Post-mortem angiography after vascular perfusion with diesel oil and a lipophilic contrast agent. *AJR.* 187:515-523.
7. James TN. (1961) *Anatomy of the coronary arteries.* New York. Paul B Hoeber. 12-150.
8. Kini S., Bis KG., Weaver L. (2007) Normal and variant coronary arterial and venous anatomy on high - resolution CT angiography. *AJR Am J Roentgenol.* 188:1665-1674.
9. L. Beach., A. Burke., D. Chute., R. Virmani. (2001) Anomalous origin of 4 coronary ostia from the right sinus of valsalva in a patient with hypertrophic cardiomyopathy. *Archives of Pathology and Laboratory Medicine.* 125 :1489-1490.
10. Mian FA., Malik SN., Ismail M., Khan IS., Kachlu AR., Rehman M. (2011) Coronary artery dominance: What pattern exists in Pakistani population? *Ann Pak Inst Med Sci.* 7:3-5.
11. Robicsek F., Sanger P.W., Daugherty., H.K. Gallucci V. (1967) Origin of anterior interventricular coronary artery and vein from the left mammary vessels. *J. Thoracic. Cardiovasc. Surg.* 53:602.
12. Schlesinger MJ. (1940) Relation of anatomic pattern to pathological conditions of the coronary arteries. *Arch Path.* 30:403-415.
13. Silke Grabherr., Valentin Djonov., Kathrin Yen., Michael J. Thali., Richard Dirnhofer. (2007). *Postmortem Angiography: Review of Former and Current Methods. Review - Forensic Radiology. American Journal of Roentgenology.* 188: 832-838.
14. Khidoyatova, M. R., Kayumov, U. K., Inoyatova, F. K., Fozilov, K. G., Khamidullaeva, G. A., & Eshpulatov, A. S. (2022). Clinical status of patients with coronary artery disease post COVID-19. *International Journal of Health & Medical Sciences,* 5(1), 137-144. <https://doi.org/10.21744/ijhms.v5n1.1858>

15. Smith M., Trummel DE., Dolz M., Cina SJ. (1999) *A simplified method for post-mortem coronary angiography using gastrograffin*. Arch Pathol Lab Med. 123:885-8.
16. Suryasa, I. W., Rodríguez-Gámez, M., & Koldoris, T. (2021). The COVID-19 pandemic. International Journal of Health Sciences, 5(2), vi-ix. <https://doi.org/10.53730/ijhs.v5n2.2937>
17. Williams P., Bannister LH., Berry MM., Collins P., Dyson M., Dussek JE. (1995) Cardiovascular system-The arterial system. Glabella G, editor. Gray's Anatomy. The Anatomical Basis of Medicine and Surgery. 38 th ed. Edinburgh, London: Churchill Livingstone; 1505-1510.

Table 1: Incidence of human heart arterial patterns by arteriogram study (n =80)

Arteriogram observations of heart arterial pattern(n=80)									
Coronary Dominance (Posterior Interventricular Branch)			Origin of Sino Atrial Nodal artery		Origin of AtrioVentricular Nodal artery		Right Coronary Artery termination		
Right	Left	Balance	Right	Left	Right	Left	Beyond crux	crux	Right border
69 (86%)	9 (11%)	2 (3%)	62 (76.6%)	18 (23.3%)	72 (90%)	8 (10%)	59 (74%)	16 (20 %)	5 (6%)

**Figure-1:** A.P.view of Arteriogram showing coronary arteries (RCA: Right coronary artery; LCA: Left coronary artery; PD: posterior interventricular; LAD: Left anterior descending; LCX: left circumflex; S: septal perforators)

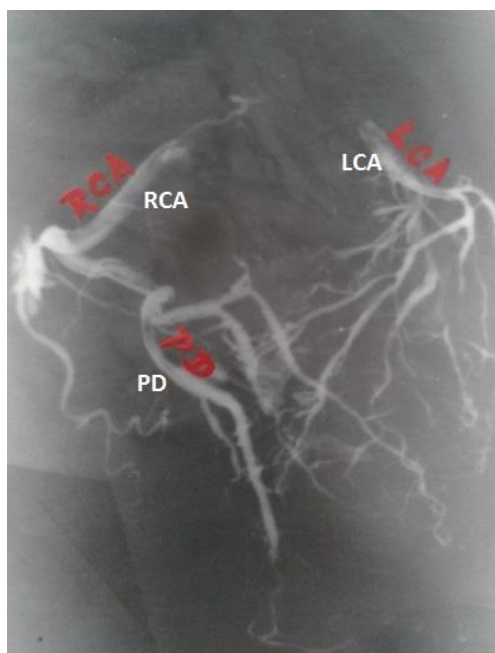


Figure-2: A.P.view of Arteriogram showing right coronary Dominance (RCA: Right coronary artery; LCA: Left coronary artery; PD: posterior interventricular)

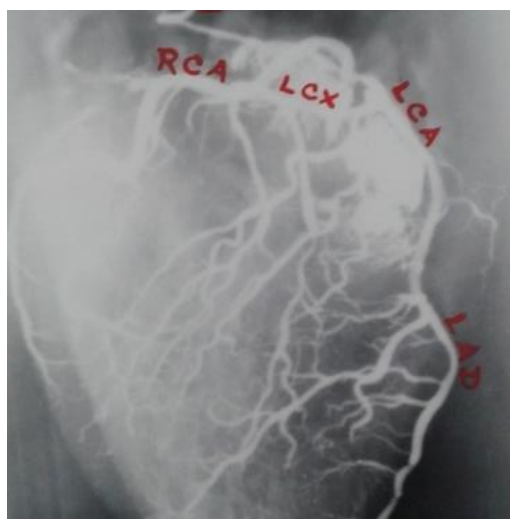


Figure-3: Right Anterior Oblique view of Arteriogram showing sinoatrial nodal branch from left circumflex branch of LCA (RCA: Right coronary artery; LCA: Left coronary artery; SN: Sino atrial nodal branch; LCX: left circumflex)

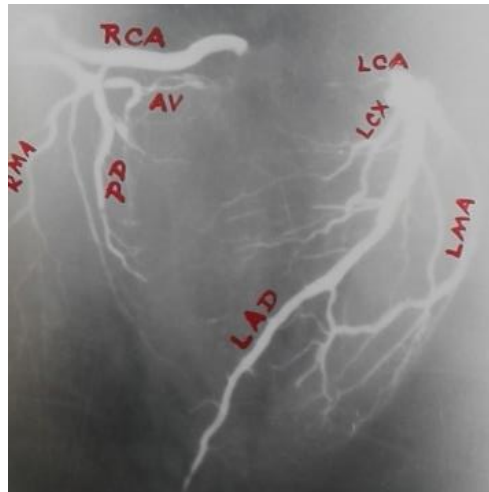


Figure-4: A.P.view of Arteriogram showing Atrioventricular (AV) nodal artery (RCA: Right coronary artery; LCA: Left coronary artery; PD: posterior interventricular; LAD: Left anterior descending; LCX: left circumflex)

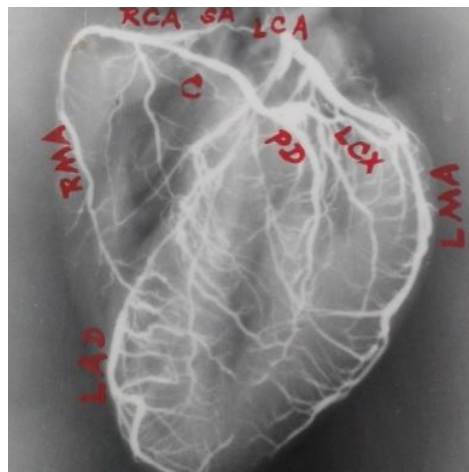


Figure-5: Left Anterior Oblique view of Arteriogram showing sinoatrial nodal branch from RCA(RCA: Right coronary artery; LCA: Left coronary artery; SA: Sino atrial nodal branch; RMA: Right marginal; C: Annulus vieussens)

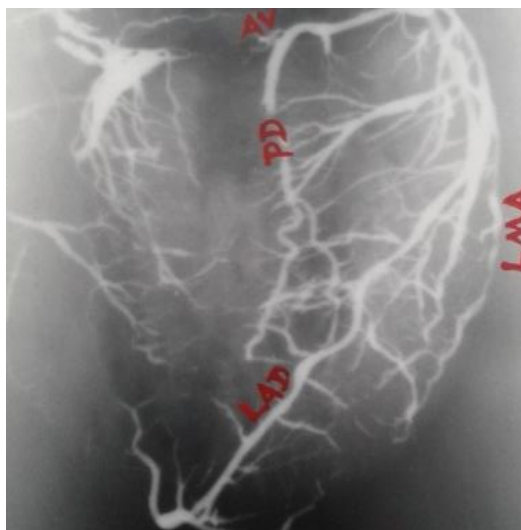


Figure-6: A.P.view of Arteriogram showing Left coronary Dominance and AV nodal branch arising from LCX (RCA: Right coronary artery; LCA: Left coronary artery; PD: posterior interventricular; LMA: left Marginal)

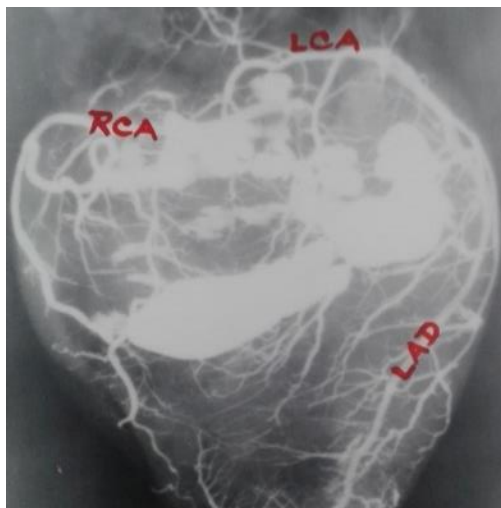


Figure-7: A.P.View of Arteriogram showing coronary arteries Left Anterior Descending is going round the apex(A) to posterior part of interventricular septum (RCA: Right coronary artery; LCA: Left coronary artery; LAD: left anterior descending)