

**How to Cite:**

Kanimozhi, S., Sumathy, G., & Bupesh, G. (2022). Effect of methanolic extract of sphaeranthus amaranthoides (MESA) on nicotine-induced Serum testosterone levels in adult Wistar albino rats. *International Journal of Health Sciences*, 6(S6), 3658–3665. <https://doi.org/10.53730/ijhs.v6nS6.10206>

## **Effect of methanolic extract of sphaeranthus amaranthoides (MESA) on nicotine-induced Serum testosterone levels in adult Wistar albino rats**

**Selvakumaran Kanimozhi**

Department of Anatomy, Sree Balaji Dental College and Hospital, BIHER, Chennai, India | Sri Sai Ram Siddha College, Tambaram, Chennai, India

**Govindarajan Sumathy\***

Department of Anatomy, Sree Balaji Dental College and Hospital, BIHER, Chennai, India.

\*Corresponding author

**Giridharan Bupesh\***

Natural Products and Tribal Health Research, Department of Forest Science, Nagaland University, Lumami, Zunheboto-798627, Nagaland, India

\*Corresponding author

**Abstract**--Background: Infertility is one of the most common health issues. Infertility in men occurs when sperms cannot fertilize eggs. Infertility can be caused by a variety of factors, medical conditions, and medications. Testicular insufficiency results when a normal individual is exposed to some toxic substances and lifestyle disorders. Smoking cigarette is one such condition that affects male reproductive system. Nicotine is the main metabolite of cigarette smoke. Testicular damages are always related with hormonal changes. Objectives: The aim of this study is to evaluate the effects of Methanolic extract of sphaeranthus amaranthoides with regard to Changes in serum testosterone levels caused as a result of nicotine -induced testicular damage. Methods: Four equal groups( 24nos) of male wistar albino rats were randomly assigned to control, nicotine and methanol extract of sphaeranthus amaranthoides with doses1(250 mg/kg BW) and 2 (500 mg/kg BW), respectively. The animals were treated for forty-eight days. The blood samples were collected at the interval of 20, 40, and 48 days, to evaluate the serum testosterone levels. Results: Nicotine reduced Serum testosterone level ( $p < 0.001$ ). When treated along with Methanolic extract of sphaeranthus amaranthoides treatment significantly increased blood testosterone level ( $p < 0.001$ ). Conclusion:

Methanolic extract of *Sphaeranthus amaranthoides* improves serum testosterone and retains spermatogenesis

**Keyword**--methanolic extract, *sphaeranthus amaranthoides* (MESA), nicotine-induced, serum testosterone

## Introduction

Smoking is the most hazardous habit to the health of a human being, especially when it comes to reproduction. (1) WHO stated that smoking affected one-third of the world population (2). Studies have shown that smoking can cause infertility problems (3). Fertility rates (4), semen volume (5), sperm concentration and motility (4), as well as hormone profiles (4) are affected by Nicotine. The leaves and stems of *Nicotiana tabacum* contain a significant amount of nicotine. Of the more than 4,000 chemicals found in tobacco products, nicotine takes the top spot. (6) The toxic effects of nicotine can be caused by direct or indirect effects on reproductive structures via the endocrine system. Nicotine disrupts Sertoli cell activity, which is essential for spermatogenesis. Tobacco smoke can cause testicular shrinkage, spermatogenic disruption, and morphological abnormalities in germ cells.

Androgens are the major male reproductive hormones, and the chief steroid hormone, testosterone, is formed by the testicular Leydig cells. Testosterone levels in plasma can serve as a useful indicator of testicular function. Nicotine lowers gonad development and steroid synthesis in rats by inhibiting androgens, Luteinizing hormone, and testosterone release (4). Luteinizing hormone (LH) binds to the Leydig cells' LH receptors and stimulates cAMP production. (7) This increases cholesterol translocation into mitochondria, where cholesterol is metabolized to pregnanolone at the mitochondrial inner membrane. Pregnenolone is then converted to testosterone. Testosterone is involved in the development of secondary sexual characteristics and regulates spermatogenesis. Nicotine inhibits the release of androgens, LH, and testosterone, which are essential to gonadal development and steroidogenesis (4). In seminiferous tubules, nicotine lowers testosterone production, which may contribute to sperm reduction (8). Because of the complex etiology of male-factor infertility, it is difficult to determine at what level drug exposure is responsible for it (9) Several aspects of sexual development, including spermatogenesis, differentiation, and maintenance of accessory sexual organs are affected by this androgen, testosterone (10)

In the Siddha system, *Sphaeranthus amaranthoides* is widely used to treat vomiting, male infertility, anorexia, and cough. (11) Male infertility is treated with 4-8 g of leaf powder combined with butter. Histomorphometric analysis of tissues plays an important role in diagnosing male reproductive toxicity. This might reveal the intensity of the toxicity, the cellular site of the damage, and the effect of *Sphaeranthus amaranthoides* on Nicotine's negative effects in male albino rats. We wanted to assess the possible effects of *sphaeranthus amaranthoides* on nicotine-induced reproductive toxicity in this animal by quantifying changes in nicotine-induced male reproductive organs at the light microscopic level. Toxic agents such as nicotine and other substances that negatively impact the male

reproductive system may be mitigated by antioxidant compounds present in herbal plants(12). This study was designed to analyze the effects of *Sphaeranthus amaranthoides* against nicotine-induced male offspring of Wistar rats.

### **Materials and Methods**

Male Wistar albino rats with a proven breeding history, weighing around  $190 \pm 25$  gm were used for the study. Animals were randomly divided into four groups (n = 6) such as control, Nicotine (NT), Nicotine followed by Methanolic extract of *sphaeranthus amaranthoides* administered (NT + MESA DOSE 1), Nicotine administered (NT), Nicotine followed by Methanolic extract of *sphaeranthus amaranthoides* administered (NT + MESA DOSE 2). The quarantine procedures and the animal maintenance were according to the recommendations of the Canadian Council Guide to the Care and Use of Experimental Animals (1993) and CPCSEA (India) Guidelines for laboratory animal facility (2003). The Institutional Animal Ethical Committee, Sathyabama university, has approved the protocol of the work (IAEC No. SU/CLATR/IAEC/X/086/2018).

### **Drugs and Chemicals**

- Chemical drugs: Freshly prepared Nicotine (0.5 mg/kg b.wt) (Sigma aldrich )
- Herbal drug: Methanolic extract of *sphaeranthus amaranthoides*.

### **Mode of administration**

- Single-dose 99% Nicotine (Liquid) (Sigma Aldrich) in 0.9% normal saline administered to the experimental animals intraperitoneally.
- The methanolic extract of *sphaeranthus amaranthoides* is administered orally via a cannula.

### **Drug dosage**

Nicotine (0.5 mg/kg b.wt) was administered (13) (Sigma Aldrich ) in 0.9% normal saline by the intraperitoneal route (single dose). Methanolic extract of *sphaeranthus amaranthoides* in two different doses Dose 1 - 250mg/kg B.wt and Dose 2 - 500mg/kg B.wt . Both were administered daily orally for 48 days by cannula.

### **Body weights**

We recorded our food and water intake daily, while we measured our body weight once a week. The bodies of the animals were weighed once a week, and their behavior was observed daily during the experiment. Each animal was given a unique identification number.

### **Blood Sampling**

Blood samples were obtained from the retro-orbital vein in a micro-hematocrit capillary tube. The plasma was separated by centrifugation and stored at  $-72^{\circ}\text{C}$  for subsequent hormone assays. Serum levels of total testosterone were estimated

on day 20, day 40, and the 48<sup>th</sup> day of the treatment period. The concentration of Serum testosterone was evaluated by using (an enzyme-linked immunosorbent assay(14)

## Results

Table 1  
Effects of Nicotine, Nicotine + MESA Dose 1 and 2 on serum testosterone level

Parameters	N	Groups			
		Control	Nicotine	Nicotine+ MESA Dose 1	Nicotine+ MESA Dose 2
Day - 20	6	4.81±0.72	4.92±0.24	4.75±0.47	4.55±0.6
Day - 40	6	4.94±0.7	4.3±0.47*	5.01±0.46	4.96±0.63
Day - 48	6	5.05±0.63	3.67±0.57*	5.43±0.38	5.48±0.6

Values are expressed as mean±SD. values sharing \* were significantly different at  $p < 0.001$

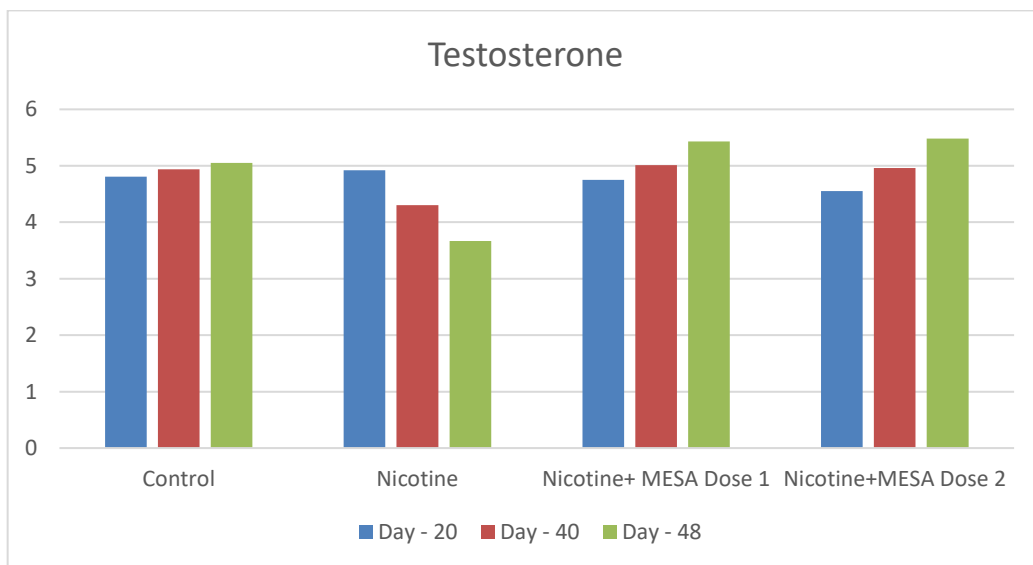
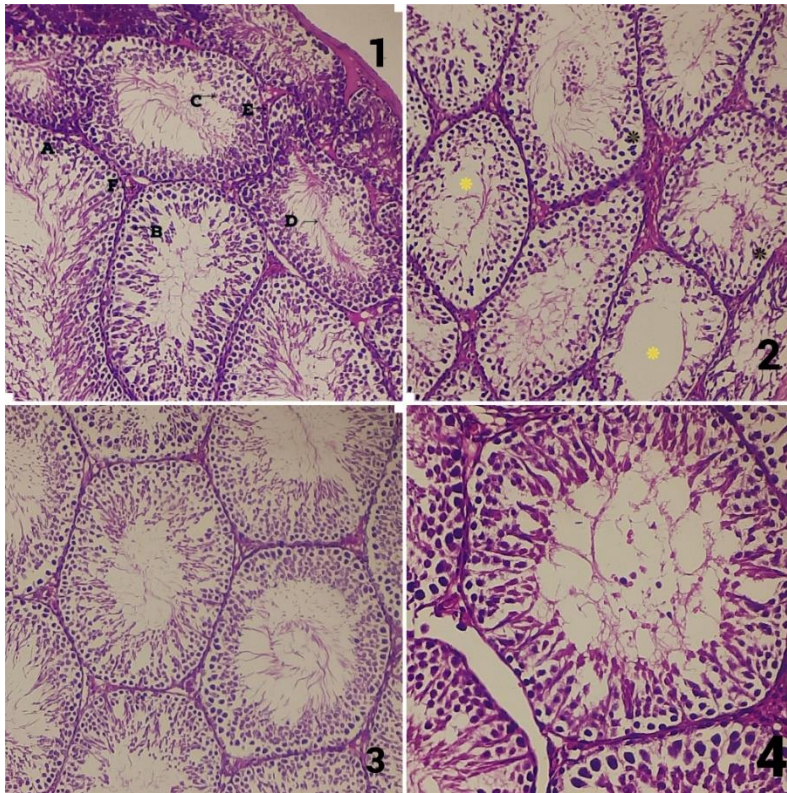


Fig 1. Comparison of testosterone levels of rats after treatment of Nicotine and MESA Dose 1 and 2

The effects of Nicotine, Nicotine +MESA Dose 1, and Nicotine + MESA Dose 2 on the levels of serum testosterone and their comparison with that of control on 20<sup>th</sup> day, 40<sup>th</sup> day and 48<sup>th</sup> day of the treatment were summarized in the table. The change in the serum testosterone was not significant after 20<sup>th</sup> day. Significant difference was seen after 40<sup>th</sup> day of the treatment. The nicotine group showed a significant decrease in Serum testosterone when compared to nicotine group (p

< 0.001). Nicotine +MESA Dose 1 and 2 showed a significant rise in serum testosterone levels as compared to nicotine.



A - Spermatogonium ;B- Sertoli cell; C- Spermatid; D- Sperms; E- Leydig cells; F- Blood vessels; Deterioration of the germinal epithelium \*Absence of spermatozoa in the lumen

Fig. 2. Cross section of Testes H&E 10x

1 - Control, 2- nicotine ,3 – Nicotine + Extract dose 1,4- Nicotine + Extract dose 2

## Discussion

Testosterone is a sex hormone with important physiological functions. In men, this hormone regulates sex drive (libido), bone mass, fat distribution, muscle mass, and sperm production. In the body, testosterone is converted to estradiol, an estrogen(15)(16). Nicotine decreases serum testosterone and damages male reproductive organs in nicotine-treated rats.( 4)Lower testosterone levels were always associated with fewer Leydig cells and Sertoli cells of the testes affected by nicotine (17). From various studies, it was evident that the testosterone levels in all nicotine-treated rats were similar (12).

Testosterone is required for the development and function of the testes and male accessory reproductive glands.Reduced levels of serum testosterone have been shown to adversely affect the structure, weight, and function of the testes and epididymis. Low serum testosterone levels have been reported to adversely affect

the structure, function, and weight of the testes and epididymis(18)There is therefore a possibility that the significant reduction in testes weight could be due to a decrease in serum testosterone levels of rats treated with nicotine, whereas the decrease in serum testosterone levels of rats exposed to nicotine could have been caused by disrupted cytoarchitecture, since nicotine adversely affects the number of Leydig cells that synthesize testosterone.It is possible that altered Testosterone levels may adversely affect the hypothalamic-pituitary-gonadal axis during puberty.The changes in the testosterone levels in Nicotine administered rats were not significant in the 20<sup>th</sup> day. The testosterone levels were decreased on the 40<sup>th</sup>, and 48<sup>th</sup> days.In adults, hormonal imbalances may lead to infertility and affect puberty and other reproductive functions. But Nicotine+MESA at the dose level of 250 mg/kg bw and 500 mg/kg bw showed the level of testosterone was increased at 40<sup>th</sup> day and 48<sup>th</sup> day of treatment. Thus the Effect of Methanolic extract of *Sphaeranthus amaranthoides* against nicotine on testosterone level was highly significant. The high level of testosterone in testis is essential for the normal spermatogenesis as well as for the maintenance of the structural morphology and the normal physiology of seminiferous tubule(19). In our study (Fig 2) spermatogenesis was affected severely in nicotine group. The reduction in the number and volume of Leydig cells could have reduced the testosterone level and which could in turn affect spermatogenesis(20- 21).

## Conclusion

According to the results of this study, It was clear that Nicotine damages the Leydig cells and in turn, the production of testosterone was decreased.Thus Methanolic extract of *Sphaeranthus amaranthoides* at the dose level of 250 mg/kg b.w and 500 mg/kg b.w was effective against Nicotine induced hormonal imbalance. Considerably the methanolic extract of *sphaeranthus amaranthoides* increased the testosterone level significantly.To explore the possible mechanisms that cause hormonal imbalances, more studies are required.

## References

1. Testosterone and testicular changes in F1 offspring of Wistar rats maternally exposed to nicotine during gestation Ibukun P Oyeyipo,<sup>1</sup> Damilare H Adeyemi,<sup>1</sup> and Temilade R Abe<sup>1</sup>JBRA Assist Reprod. 2018 Jul-Sep; 22(3): 162–166. doi: 10.5935/1518-0557.20180031}
2. WHO - World Health Organization . The World Health Report 1999 - Making a difference. Geneva: World Health Organization; 1999
3. Haustein KO. Cigarette smoking, nicotine and pregnancy. *Int J Clin Pharmacol Ther.* 1999;37:417–427.
4. Oyeyipo IP, Raji Y, Bolarinwa AF. Nicotine alters male reproductive hormones in male albino rats: The role of cessation. *J Hum Reprod Sci.* 2013;6:40–44.doi: 10.4103/0974-1208.112380.
5. Pasqualotto FF, Sobreiro BP, Hallak J, Pasqualotto EB, Lucon AM. Cigarette smoking is related to a decrease in semen volume in a population of fertile men. *BJU Int.* 2006;97:324–326. doi: 10.1111/j.1464-410X.2005.05906.x
6. Rustemeier K, Stabbert R, Haussmann HJ. Evaluation of the potential effects of ingredients added to cigarettes. Part 2: Chemical composition of mainstream smoke. *Food Chem Toxicol* 2002;40:93–104.

7. Guey-Shyang Hwang et al., Effects of hypoxia on testosterone release in rat leydig cells *Am J Physiol Endocrinol Metab* 297: doi:10.1152/ajpendo.00010.2009.
8. Mohammad Reza Salahshoor Crocin and nicotine Crocin Improves Damage Induced by Nicotine on A Number of Reproductive Parameters in Male Mice *International Journal of Fertility and Sterility* 10(1):71-8 DOI:10.22074/ijfs.2016.4771
9. Risperidone induced reproductive toxicity in male rats targeting leydig cells and hypothalamic-pituitary-gonadal axis by inducing oxidative stress *Gözde Görmüş Andrologia*. 2020;00, doi.org/10.1111/and.138
10. Ibukun P Oyeyipo Nicotine alters male reproductive hormones in male albino rats: The role of cessation (*Journal of Human Reproductive Sciences / Volume 6 / Issue 1 / Jan - Mar 2013* DOI: 10.4103/0974-1208.112380
11. Murugesamudaliyar, Gunapadamporutpanbunool, Siddha materia medicapg .no: 229
12. Fahimeh Mohammadghasemiet al ., The amelioration of nicotine-induced reproductive impairment in male mouse by *Sambucus ebulus* L. fruit extract *Anat Cell Biol* 2021; 54(2): 232-
13. Ibukun Peter Oyeyipo et al, 240 Effects of Nicotine on Sperm Characteristics and Fertility Profile in Adult Male Rats: A Possible Role of Cessation *J Reprod Infertil*. 2011 Jul-Sep; 12(3): 201-207.
14. Fatima Ayaz et al., Study to Investigate the Hormone Analysis in Male Albino Rats under the Pharmacological Kinetics of Thimerosal *Scholars Bulletin* DOI: 10.36348/sb.2021.v07i06.001
15. <https://www.nih.gov/news-events/nih-research-matters/understanding-how-testosterone-affects-men>
16. Gonadal steroids and body composition, strength, and sexual function in men. *N Engl J Med*. 2013 Sep 12;369(11):1011-22. doi: 10.1056/NEJMoa1206168. PMID: 24024838.
17. Rachid Mosbah Nicotine-induced reproductive toxicity, oxidative damage, histological changes and haematotoxicity in male rats: The protective effects of green tea *Experimental and Toxicologic Pathology* doi.org/10.1016/j.etp.2015.01.001
18. George FW, Wilson JD. Hormonal control of sexual development. *Vitam Horm*. 1986;43:145-196. doi: 10.1016/S0083-6729(08)60420-3.; Mooradian AD, Morley JE, Korenman SG. Biological actions of androgens. *Endo Rev*. 1987;8:1-28. doi: 10.1210/edrv-8-1-1.
19. Karanth, S., Yu, W.H., Walczewska, A., Mastronardi, C.A. and McCann, S.M. (2001) Ascorbic Acid Stimulates Gonadotropin Release by Autocrine Action by Means of NO. *Proceedings of the National Academy of Sciences of the United States of America*, 98, 11783-11
20. S. Kanimozhi et al., Histological Changes In Testis Of Adult Wistar Albino Rats - Nicotine-Induced Testicular Damages And The Protective Effects Of Methonolic Extract Of *Sphaeranthus Amaranthoides* *Journal of Pharmaceutical Research International* DOI: 10.9734/JPRI/2022/XXXXX
21. Sundaram KK, Bupesh G, Saravanan KM. Instrumentals behind embryo and cancer: a platform for prospective future in cancer research. *AIMS Molecular Science*, 9: 25-45, 2022. Doi: 10.3934/molsci.2022002

22. Suryasa, I.W., Sudipa, I.N., Puspani, I.A.M., Netra, I.M. (2019). Translation procedure of happy emotion of english into indonesian in kṛṣṇa text. *Journal of Language Teaching and Research*, 10(4), 738–746
23. Ramli, R. M., Sinrang, A. W., & Aminuddin. (2021). Levels of alpha-1 acid glycoprotein (AGP) in stunting and non stunting tolls age 36-60 months . *International Journal of Health & Medical Sciences*, 4(1), 145-149. <https://doi.org/10.31295/ijhms.v4n1.1666>