

How to Cite:

Hussein, Z. M., & Mohammed, H. H. (2022). A comparative morphological study of the accessory sex glands of immature and mature local breed donkey (*Equus asinus*). *International Journal of Health Sciences*, 6(S5), 6970–6983. <https://doi.org/10.53730/ijhs.v6nS5.10217>

A comparative morphological study of the accessory sex glands of immature and mature local breed donkey (*Equus asinus*)

Zahraa M. Hussein

Department of Clinical Laboratory Science and Pharmaceutics, University of Ahl AL-Bayt, Collage of pharmacy, Iraq and Department of Anatomy and Histology, College of Veterinary Medicine, University of Baghdad, Baghdad, Iraq
Corresponding author email: hhashim790@gmail.com

Hadaf H. Mohammed

Department of Anatomy and Histology, College of Veterinary Medicine, University of Baghdad, Baghdad, Iraq

Abstract--Eight samples of accessory sex glands of donkey were used to compare between the immature and mature donkey. The morphological parameters were involved position, relation, shape, length, width, and weight of each gland. The results of in immature and mature donkey the ampulla of ductus deferens were spindle shape structure of ends part of ductus deferens, located dorsally to the urinary bladder and opened into ejaculatory duct, in immature measured 1.85 ± 0.04 cm, 3.81 ± 0.18 mm and 0.96 ± 0.02 g and in mature measured 7.57 ± 0.01 cm, 5.67 ± 0.21 mm, and 6.87 ± 0.02 g in length, width and weight respectively. Vesicular gland of immature donkey was small size located laterally to the ejaculatory duct and cranially to the prostate gland, while in mature was larger elongated gland extended more laterally to the body of urinary bladder, in immature measured 2.13 ± 0.03 cm, 3.96 ± 0.08 mm, 1.28 ± 0.08 g and in mature donkey measured 7.97 ± 0.09 cm, 5.76 ± 0.30 mm, 7.53 ± 0.10 g in length, width and weight respectively. Prostate of immature was dark brown in color, small bilobed gland, located caudally to the vesicular gland and laterally to the pelvic urethra, while in mature donkey was very dark brown, and large bilobed gland, it was measured 1.76 ± 0.19 cm, 3.51 ± 0.20 mm, 3.17 ± 0.10 g and in mature measured 2.90 ± 0.01 cm, 7.88 ± 0.26 mm and 6.40 ± 0.20 g in length, width and weight respectively. Bulbourethral gland of immature donkey was dark brown, slightly large bilobed gland, located caudally to the prostate, laterally to the pelvic urethra and cranially to the crura of penis, measured 1.02 ± 0.04 cm, 4.42 ± 0.13 mm, and 3.97 ± 0.21 g length, width and weight respectively, in mature was redish-brown, very large bilobed gland and was measured 2.94 ± 0.01 cm, 7.21 ± 0.31 mm,

7.02±0.19g .The statistical analysis revealed significant differences between the length, width and weight of these glands in mature and those of immature donkey.

Keywords---accessory gland, ampulla, prostate, vesicular gland, bulbourethral gland, donkey.

Introduction

Donkey is a domestic animal in the equine species. It is from the African wild animals, *Equus africanus*, and used as a numerous jobs as animal working for at least 5000 years (Al-Gharban, 2017; Britannica, 2021). The donkey as a herbivores species animals has many benefits, donkey milk has been used in as a food sources around for thousands of years and become common recently especially in many country of Europe (lisabetta *et al.*, 2012). In mammals the accessory sex glands are revealed variety in numbers, position and dimension (Kumarasamy *et al.*, 2022). The size and texture of each gland are difference according the physiological statue, in the bull and the stallion, the prostate and ampulla of ductus deferens and vesicular glands are easily readily detected by rectal palpation, the bulbourethral glands, although present, are quite difficult to palpate per rectum. In large boars, rectal examination is potentially feasible, but digital examination of smaller boars will only enable palpation of the bulbourethral glands. In smaller dogs, digital examination of the prostate is possible (Michael McGowan (2019). The ampulla, prostate gland and bulbourethral glands are recorded in ram, red sokoto buck and one-humped. The prostate glands are consisted of only disseminated or scattered parts extending along the pelvic urethra in uda ram, red sokoto buck, while prostate glands in one-humped camel is the largest accessory sex gland which situated on the dorsolateral aspect of the pelvic urethra above the ischial arch with a thick inter glandular septum between them and it is almond in shape. On the other hand, the vesicular gland is absent in one-humped camel and more pronounced (Largest, markedly lobulated and dark-greyed in color) in the uda ram and red sokoto buck (Mahmud *et al.*, 2016). Ampulla of ductus, seminal vesicle and bulbourethral glands are observed in ram (*Ovis aris*) and buck (*Caprus hircus*) by Khalaf (2009 and 2010) it presents as a paired in number and well developed, while prostate gland has only disseminated part which embedded in pelvic urethral wall and absent the body of gland (Mohammed and Doohi, 2017) . In monkey (*Macaca radiata*), the seminal vesicles appeared pyramidal shape and is the largest gland that is located over the urinary bladder (Prakash *et al.*, 2009). In *Gazella subgutturosa* the accessory sex glands are consisted three pairs that grouped around the pelvic urethra include; Ampulla of vas deferens, seminal vesicles glands and bulbourethral glands and one single the prostate gland. The seminal vesicle glands are markedly lobulated, irregular in shape, which located at the caudo-dorsal aspect near to the neck of urinary bladder. The bulbourethral glands are paired consist of right and left bulbs or irregular oval-shaped lobes, located at the caudal part of the pelvic urethra closely related to the root of the penis (Mohammed and Doohi, 2017).The current study was aimed to investigate the main differences between the accessory sex glands of immature and mature local breed male donkey.

Materials and Methods

Animals' preparation

A total of eight samples of accessory sex glands of local breed donkey were used allocated into two equal groups (immature and mature) (four each) were used for this study. The animals of study were obtained from department of anatomy and histology at college of veterinary medicine/University of Baghdad. The samples of accessory sex glands were removed from the cadaver, washed up with tap. The morphological parameters of the study involved position, relation, shape, length, width, and weight of each gland in immature and mature animal (Dohi, 2017; Hussan 2021; Al-Falahi et al., 2017; Dawood et al., 2020). The length and width were estimated by digital caliber, weight was estimated by digital balance and the volume was estimated by the water displacement. The images were photographed by digital camera.

Statistical analysis

Data were expressed as mean \pm standard error. Statistical analysis was carried out on the load-bearing data using two-way analysis of variance and the least significant difference. $p < 0.05$ was considered as statistical significance differences.

Results

The anatomical result showed that in immature and mature male donkey the accessory sex glands of reproductive system involeved ampulla of ductus deferens, vesicular gland, prostate gland, and bulbourethral glands (Fig.1 and 2).

Ampulla of ductus deferens

The amulla of ductus deferens of immature donkey was a dillated end parts of the ductus deferens at the end part of pevic cavity in the genital fold, located bilateral to thel urinary bladder and opened into ejaculatory duct, appeared as spindle shape had white – creamy in colour (Fig.1, 3 and 4). It was measured (1.85 ± 0.04 cm) in length, (3.81 ± 0.18 mm) in width , and (0.96 ± 0.02) in weight. In mature donkey the ampulla of ductus deferens was similar that in immarure male donkey in position, colore, but differed in anatomical parameters (Fig.2 and 4). It was measured (7.57 ± 0.01 cm) in length, (5.67 ± 0.21 mm) in diameter , and (7.87 ± 0.02 g) in weight. The statistical analysis revealed singnificant deferernces between the length, width and weight of mature and those of immature donkey (Tab.1, 2 and 3).

Vesicular glands

Vesicular glands of immature male donkey was white in color, small size bilobed gland, located laterally to body of the urinary bladder, laterally to the ejaculatory duct and cranillay to the prostate gland. It was opened into the lumen of ejaculatory duct. It was measured (2.13 ± 0.03 cm) in length, (3.96 ± 0.08 mm) in width, and (1.28 ± 0.08 g) in weight. In mature male donkey the vesicular gland

was pinkish in color, large elongated lobulated gland, it was extended more laterally to the body of urinary bladder, cranially to the prostate gland (Fig.2 and 4). It was measured (7.97 ± 0.09 cm) in length, (5.76 ± 0.30 mm) in diameter, and (7.53 ± 0.10 g) in weight. The statistical analysis revealed significant differences between the length, width and weight of mature and those of immature donkey (Tab.1, 2 and 3).

Prostate

Prostate gland of immature male donkey was dark brown in color, slightly small had semicircular bilobed gland (body) and lack of disseminate part. It was located caudally to the vesicular gland, laterally to the pelvic urethra, cranially to the bulbourethral glands and opened into pelvic urethra (Fig.1, 3 and 5). It was measured (1.76 ± 0.19 cm) in length, (3.51 ± 0.20 mm) in width , and (3.17 ± 0.10 g) in weight. Prostate gland of mature male donkey was very dark brown in color, very large bilobed gland (Body) without disseminate part, located caudally to the vesicular gland, laterally to the pelvic urethra, cranially to the bulbourethral glands (Fig.2 and 4). It was measured (2.90 ± 0.01 cm) in length, (7.88 ± 0.26 mm) in diameter , and (6.40 ± 0.20 g) in weight. The statistical analysis revealed significant differences between the length, width and weight of mature and those of immature donkey (Tab.1, 2 and 3).

Bulbourethral gland

Bulbourethral gland of immature male donkey was dark brown in color, appeared slightly large bilobed gland. It was located caudally to the prostate gland, laterally to the pelvic urethra, cranially to the crura of penis and opened into pelvic urethra (Fig.1, 3 and 6). It was measured (1.02 ± 0.04 cm) in length, (4.42 ± 0.13 mm) in width , and (3.97 ± 0.21 g) in weight. Bulbourethral gland of mature male donkey was reddish-brown in color, very large bilobed gland, surrounded and skeletal muscle. It was located caudally to the prostate gland, laterally to the pelvic urethra, cranially to the crura of penis (Fig.2 and 4). It was measured (2.94 ± 0.01 cm in length, (7.21 ± 0.31 mm) in diameter, and (7.02 ± 0.19 g) in weight. The statistical analysis revealed significant differences between the length, width and weight of mature and those of immature donkey (Tab.1, 2 and 3).

Table (1) shows lengths of accessory sex glands in immature and mature male donkey

Length/cm	immature Mean \pm SE	mature Mean \pm SE	LSD
Ampulla	1.85 \pm 0.04 A a	7.57 \pm 0.01 A b	1.72
Vesicular gland	2.13 \pm 0.03 A a	7.97 \pm 0.09 A b	2.84
prostate gland	1.76 \pm 0.19 A a	2.90 \pm 0.01 B b	1.14
bulbourethral gland	1.02 \pm 0.04 B a	2.94 \pm 0.01 B b	1.62

- Different capital litters represents significant differences between glands at 0.05
- Similar capital litters represents no significant differences between glands at 0.05
- Different small litters represents significant differences between periods at 0.05
- Similar small litters represents no significant differences between periods at 0.05

Table (2) shows widths of accessory sex glands in immature and mature male donkey

Width/mm	immature Mean±SE	mature Mean±SE	LSD
Ampulla	3.81±0.18 A a	5.67±0.21 A b	0.86
Vesicular gland	3.96±0.08 A a	5.76±0.30 A b	1.8
prostate gland	3.51±0.20 A a	7.88±0.26 B b	4.37
bulbourethral gland	4.42±0.13 B a	7.21±0.31 B b	2.79

- Different capital litters represents significant differences between glands at 0.05
- Similar capital litters represents no significant differences between glands at 0.05
- Different small litters represents significant differences between periods at 0.05
- Similar small litters represents no significant differences between periods at 0.05

Table (3) Shows weights of accessory sex glands in immature and mature male donkey

Weight/g	Immature	Mature	LSD
Ampulla	0.96±0.02 A a	6.87±0.02 A b	1.91
Vesicular gland	1.28±0.08 A a	7.53±0.10 B b	2.25
prostate gland	3.17±0.10 B a	6.40±0.20 C b	3.23
bulbourethral gland	3.97±0.21 B a	7.02±0.19 C b	3.05

- Different capital litters represents significant differences between glands at 0.05.
- Similar capital litters represents no significant differences between glands at 0.05.
- Different small litters represents significant differences between periods at 0.05.
- Similar small litters represents no significant differences between periods at 0.05.

Discussion

The current study revealed full numbers of accessory sex glands found in local breed donkey that involved ampulla of ductus deferens, vesicular gland, body of prostate gland and bulbourethral glands such results are similar to those recorded in stallion by Davies (2003), Dascanio and McCue (2014) and in Gazella by Mohammed and Doohi (2017) that recorded that the accessory sex glands are ampulla of vas deferens, seminal vesicles glands and bulbourethral glands and prostate gland. Also in bull Hassan (2021) has recorded four pairs of accessory

sex glands surrounded the pelvic urethras that are ampulla of vas deferens, vesicular glands, prostate gland and bulbourethral glands. The current study suggests that the full numbers of accessory sex glands presents in no seasonally breeding species which their females have monthly reproductive cyclic usually and meeting, such animal required furthermore gland to produce adequate amount of seminal plasma. Incomplete number of accessory sex glands is recorded in other mammalian species such the ocelot (*Leopardus pardalis*) which contained only the prostate and bulbourethral glands (Machado et al., 2020). However (Mahmud et al., 2016) in ram, red sokoto buck and one-humped recorded that the accessory glands composed of three glands that the ampulla, prostate and bulbourethral glands (Khalaf, 2009) recorded in ram (*Ovis aris*) and buck (*Caprus hircus*) only the ampulla of ductus, seminal vesicle and bulbourethral glands. In canine and feline species the number of accessory sex gland was the fewer which recorded only the ampulla of ductus deferens and prostate glands (Abood et al., 2019; Ozkadif et al., 2009; Johnston, 2001; Dimitrov et al., 2010; Dyce et al., 2009). Also in monkey there are the ampulla and prostate (de Siqueira et al., 2018). Our result showed that the shape, position and relation of the ampulla of ductus deferens is similar to those recorded in other mammals especially it well developed in dog (Budras, 2010), in tom cat (Abood et al., 2019), in male indigenous gazelle (*Gazella subgutturosa*) (Mohammed and Doohi 2017), in monkey (Ramos, 1979), in Marca's marmoset (*Mico marcai*) (de Siqueira et al., 2018), in bull (Hassan, 2021), in ram, red sokoto buck and one-humped camel bull (Mahmud et al., 2016), in ram (*Ovis aris*) and buck (*Caprus hircus*) (Khalaf, 2009), in camel, while absents of ampulla is recorded by cats and boar (Frandsen et al., 2009; Dyce et al., 2009). The current study suggest that the ampulla is first gland the add it's part of the seminal plasma with significant differences between the dimensions of the adult and immature, the dimensions of ampulla of current study were lower those recoded in *Gazella* by Mohammed and Doohi (2017), in bull Hassan (2021) and in one humped camel (Mahmud et al., 2016). While the dimension of ampulla in ram was lower than those recoded in ram and buck (Khalaf, 2009), these difference always belonged species difference.

Our study revealed that the **vesicular glands** of immature and mature male donkey were elongated bilateteral apperantly lobulated glands, located laterally to the urinary bladder, this result similar to those reports by Colville and Bassert (2002) in tomcat and dogs, Mahmud et al., 2016) in ram and buck, and Nissar et al. (2012) in Boar. Meanwhile Smith et al. (2008) in camel, Khalaf (2009), Youngquist and Threlfall (2007), Gofur (2015) in small ruminants, and Budras et al. (2003) in stallion they reported that the glands are located dorsolateral for urinary bladder, the current study suggests that differences in position of lobe of vesicular gland could be related with status of fullness or empty of urinary bladder. On the other hand, our study revealed that the vesicular gland is the largest sex accessory gland, it was similarly to those reported by Amrozi et al. (2012), Sohn and Kimura (2012) in Deers, Rahman et al. (2010), Turman and Rich (2010) and Adhikary et al. (2015) in camel, such result suggest that the gland is participate with the largest volume of seminal plasma that add to the ejaculatory duct.

The **prostate gland** in local breed donkey had semicircular shape laterally attached to the pelvic urethra and caudally to the seminal vesicle, such result similar those mentioned in red fox by Ozkadif et al (2009), in tomcat (Dimitrov et al., 2010b; Dyce et al., 2009; Abood et al., 2019) and in stallion, (Davies, 2003; Dascanio and McCue, 2014) and current result dissimilar that observed in dog by Mantis (2008), Smith, (2008), Evans and De Lahunta (2013) whom revealed that the prostate in dog has dorsal to pelvic urethra and related with rectum, moreover, the prostate gland in monkey has conical shape, its base in contact with the trigone of the bladder (Prakash et al., 2009). On the other hand in local breed donkey the prostate had stable position, so this result disagree with reports of Marty *et al.*, (2003) and Manuel and Francisca (2019, Smith (2008), Evans, and De Lahunta, (2013) whom mentioned that in male dogs, the prostate glands is seen in the pelvic region, while in mature dogs will become abdominal as the prostate enlarges in older dogs. The current study showed that the prostate of local breed donkey was without disseminate part, such result is similar some mammals species such as horse (Dyce *et al.*, 2009), tomcat (Abood et al., 2019), and current result dissimilar prostate of ram, buck and camel at which gland is consisted of only disseminate parts which extending along the pelvic urethra (Khalaf, 2009; Farooqui, 2004; Gofur, 2015), in one-humped camel the prostate gland it is the largest accessory sex gland consisted of a dorsal body and ventral disseminate part overlying the prostatic urethra (Mahmud et al., 2016), while in adult bull the prostate has body and disseminate part (Hassan, 2021; Adhikary et al., 2015) , the prostate gland of gazelle is consisted of disseminated part only (Mohammed and Doohi 2017). There significant differences between the dimensions of adult prostate and those in immature, the dimension of prostate in adult donkey similar that recorded by Hassan (2021) in bull which showed lower dimensions, while the prostate gland in stallion is larger (5–8 cm) in long, (2–3 cm) in wide and (1–2 cm) thick (Davies, 2003; Dascanio and McCue, 2014).

The current study revealed that the bulbourethral glands are paired gland present in donkey as to those records by Gofur (2015), Khalaf, 2010), Sohn and Kimura, (2012) in deers, Cunningham (2002) in bull, Mahmud et al. (2016) in camel, Badia et al. (2006b) and Bonet et al. (2013) in boar, McEntee (2012) in stallion, and Dimitrov and Russenov, (2006) in cat, all above authors mentioned that the bulbourethral glands in all domestic mammalian species except the dog.

Acknowledgement

The authors would like to acknowledge all Mr. Muoaid Fadil and staff assistances in laboratory of histological techniques at department of Anatomy, Histology and Embryology- College of Veterinary Medicine/ University of Baghdad.

Conflict of Interest

The authors declare that there are no conflicts of interest regarding the publication of this manuscript.

References

Abood, D. A., Dawood, M. S., and Mohammed, L. E. (2019). Histological Features of the Accessory Sex Gland of Indigenous Tom cat (*Felis catus*). *Al-Anbar Journal of Veterinary Sciences*, 12(2).

- Al-Gharban, H. A. A. J. (2017). Seroepidemiological detection and culture utilization for diagnosis of carrier horses and donkeys with strangles. *Journal of Education College Wasit University*, 1(28), 649-660.
- Al-Falahi, N. H. (2017). Comparative evaluation of bovine pericardial membrane and amniotic membrane in wounds skin healing in rabbits: NH Al-Falahi¹; Dhyaa. Ab. Abood² and MS Dauood². *The Iraqi Journal of Veterinary Medicine*, 41(2), 137-145.
- Adhikary, G. N., Begum, M. I. A., Islam, M. N., Islam, K. M., and Rauf, S. M. A. (2015). Morpho-histometric evaluations of pre-pubertal, pubertal and post pubertal prostate glands of indigenous bulls (*Bos indicus*) of Bangladesh. *International Journal of Biological and Pharmaceutical Research*, 6(8), 586-592.
- Britannica (2021). "donkey". Encyclopedia Britannica, Invalid Date, <https://www.britannica.com/animal/donkey>. Accessed 17 December 2021.
- Budras, K. D. (2010). Anatomy of the Dog: With Aaron Horowitz and Rolf Berg. Schlütersche. 2010 Dec 7, Pp:96.
- Badia, E. ; Briz, M. D. ; Pinart, E. ; Sancho, S. ; Garcia-Gil, N. ; Bassols, J. ; Pruneda, A. ; Bussalleu, E. ; Yeste, M. ; Casas, I. and Bonet, S. (2006a). Structural and ultrastructural features of boar seminal vesicles. *Tissue and Cell*, 38(2): 79-91.
- Badia, E. ; Briz, M. D. ; Pinart, E. ; Sancho, S. ; Garcia, N. ; Bassols, J. and Bonet, S. (2006b). Structural and ultrastructural features of boar bulbourethral glands. *Tissue and Cell*, 38(1), 7-18.
- Dascanio, J. and McCue, P. (2014). Palpation and Ultrasonography of the Accessory Sex Glands. In: *Equine Reproductive Procedures*. John Wiley and Sons. Utrecht University, Netherlands, Pp: 467- 470.
- Bonet, S. ; Garcia, E. and Sepulveda, L. (2013). The boar reproductive system. In *Boar Reproduction: Fundamentals and New Biotechnological Trends*. Bonet, S. ; Casas, I. ; William, V. H. and Yeste, M. (Editions). Springer Berlin Heidelberg. Pp: 65-107.
- Dawood, T. N., Al-Araj, A. S., and Abood, D. A. (2020). Stereological and Histopathological Effects of *Trigonella foenum-graecum* Seeds on Rabbits Ovary. *The Iraqi Journal of Veterinary Medicine*, 44(E0)), 28-32.
- Davies Morel, M.C.G. (2003). *Equine reproductive physiology, Breeding and Stud. management*. 2nd ed. CABI publishing, Pp: 236-280.
- de Siqueira, G. H. L., Silva, F. E., and Santana, M. I. S. (2018). Morphological description of male genital organs of Marca's marmoset (*Mico marcai*). *Anatomia, histologia, embryologia*, 47(4), 372-384.
- Dianne M. Creasy, Robert E. Chapin (2013). *Male Reproductive System*, Editor(s): Wanda M. Haschek, Colin G. Rousseaux, Matthew A. Wallig, Haschek and Rousseaux's Handbook of Toxicologic Pathology (Third Edition), Academic Press, P: 2493-2598, ISBN 9780124157590, <https://doi.org/10.1016/B978-0-12-415759-0.00059-5>.
- Dimitrov, R., Yonkova, P., and Stamatova, K. (2010a) a. Comparative ultrasonographic study on prostate and bulbourethral glands of tomat. *Bulgarian Journal of Agricultural Science*, 16(4), 521-525.
- Dimitrov, R.; Yonkova, P.; Vlodyova, D.; and Kostov, D. (2010b) b. Computed Tomography Imaging of the Topographical Anatomy of Canine Prostate. *Trakia Journal of Sciences*, Vol. 8 No2, Pp: 78-82.

- Dyce, K. M. ; Sack, W. O. and Wensing, C . J .G. (2009 and 2010). Textbook of Veterinary Anatomy. 4th ed. W.B. Saunders Company, USA. pp: 714-720.
- Evans, H. E., and De Lahunta, A. (2013). *Miller's anatomy of the dog-E-Book*. Elsevier Health Sciences. Pp; 374-375.
- Farooqui, M.M. (2004). Morphological, histological and histochemical studies on male genital system of goat (*Capra hircus*). Ph.D. thesis submitted to CSA University, Kanpur.
- Frandsen, R. D. ; Wilke, W. L. and Fails, A.D. (2009). Anatomy and Physiology of farm animals. 7th .Ed. John Wiley and Sons. Pp: 408-410.
- Gofur, M. R. (2015). Anatomy and histomorphometry of accessory reproductive glands of the Black Bengal buck. *Eur. J. Anat.*, 19(2), 171-178.
- Hadaf H. Mohammed and Hussein K Doohi (2017). Histomorphology and histochemistry study of ampulla of vas deferens in adult indigenous gazelle (*Gazella subgutturosa*) . *Journal of Entomology and Zoology Studies* 2017; 5(4): 1452-1455
- Hassan, A. M. (2021). The morphological, histological and histochemical study of male accessory sex glands in adult indigenous Bull (*Bos indicus*). Mcs thesis, College of Veterinary medicine - University of Baghdad.
- Johnston, S. A. (2013). *Veterinary surgery: Small animal-E-BOOK: 2-volume set*. Elsevier Health Sciences.
- Khalaf, A. S. (2009). Comparative Anatomical and Histological study of the Male Accessory Genital Glands in Local Sheep (*Ovis aris*) and Goat (*Caprus hircus*). MCs. thesis, College of Veterinary medicine - University of Baghdad.
- Khalaf, A. S. (2010). Anatomical study of the accessory genital glands in male's sheep (*Ovis aris*) and goats (*Caprus hircus*). *The Iraqi Journal of Veterinary Medicine (ISSN-P: 1609-5693 ISSN-E: 2410-7409)*, 34(2), 1-8.
- Kumarasamy, P., Sasipriya, M., Ganapiriya, V., Muthukumaravel, K., Pradhoshini, K. P., Ahmed, M. S., ... and Faggio, C. (2022). Internal anatomy and ultrastructure of the male reproductive organization of the Sesarmid crab *Muradium tetragonum* (1798)—(Decapoda: Brachyura). *Acta Zoologica*
- lisabetta Salimei, Francesco Fantuz, (2012). Equid milk for human consumption, *International Dairy Journal*, 24 (2) 130-142.
- Machado, L. C., Orlandin, J. R., Karam, R. G., Rós, F. A., Martins, D. D. S., Costa, G. D. M., and Ambrósio, C. E. (2020). Morphology of male and female reproductive tract of the ocelot (*Leopardus pardalis*). *Animal Reproduction*, 17(2).
- Mahmud, M. A., Josephat, O., Abdullahi, S. S., Aminu, U. M., Abdurrahman, B., Akawu, S. H., and Shehu, S. (2016). Species Variation on Gross Morphology and Gross Morphometry of Accessory Sex Glands in One-Humped Camel Bull (*Camelus dromedarius*), Uda Ram and Red Sokoto Buck.
- Mantis, P. (2008). Ultrasonography of the urinary and genital system of the dog and cat. Pp: 63 – 71.
- Marty, M. S., Chapin, R. E., Parks, L. G., and Thorsrud, B. A. (2003). Development and maturation of the male reproductive system. *Birth Defects Research Part B: Developmental and Reproductive Toxicology*, 68(2), 125-136.
- McEntee, K. (2012). Reproductive pathology of domestic mammals. Bulbourethral, Vesicular and prostate glands. McEntee. M.(Eds). Elsevier, Pp: 333- 348
- Michael McGowan (2019). Evaluation of the Fertility of Breeding Males, Editor(s): David E. Noakes, Timothy J. Parkinson, Gary C.W. England, Veterinary

- Reproduction and Obstetrics (Tenth Edition), W.B. Saunders, P:619-634, ISBN 9780702072338, <https://doi.org/10.1016/B978-0-7020-7233-8.00035-5>.
- Nissar, S.; Suri, S. and Sarma, K. (2012). Histology of the Ampulla of Vas Deferens of Backer wali Goat in Different Age Groups. *Indian Vet. J.*, 89(11), 144-145.
- Hepsiba, N., Subhashini, A., Raju, M., & Rao, Y. P. (2018). Changing role of teachers in the present society. *International Journal of Health & Medical Sciences*, 1(1), 35-38. <https://doi.org/10.31295/ijhms.v1n1.37>
- Ozkadif, S., Haligur, A., and Eken, E. (2019). A three-dimensional reconstruction of the scapula in the red fox (*Vulpes vulpes*). *Indian Journal of Animal Research*, 53(3), 336-340.
- Prakash, S., Suresh, S., and Prithiviraj, E. (2009). Anatomical aspects of the male reproductive system in the bonnet monkey (*Macaca radiata*). *Anatomical science international*, 84(1-2), 53.
- Widana, I.K., Sumetri, N.W., Sutapa, I.K., Suryasa, W. (2021). Anthropometric measures for better cardiovascular and musculoskeletal health. *Computer Applications in Engineering Education*, 29(3), 550-561. <https://doi.org/10.1002/cae.22202>
- Ramos, A. S. (1979). Morphologic variations along the length of the monkey vas deferens. *Archives of andrology*, 3(3), 187-196.
- Smith, J. (2008). Canine prostatic disease: a review of anatomy, pathology, diagnosis, and treatment. *Theriogenology*, 70(3), 375-383.
- Turman, E. J., and Rich, T. D. (2010). Reproductive Tract Anatomy and Physiology of the Bull. *Extension Beef Cattle Resource Committee. Beef Cattle*, 1-3.

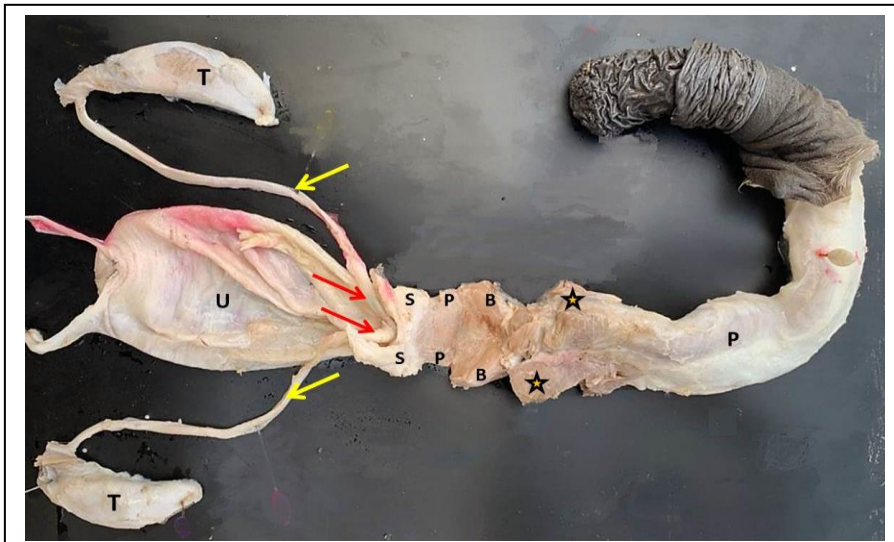


Figure 1: Macrophotograph of immature male reproductive system (Donkey) shows: testis (T), ductus deferens (Yellow arrows), ampulla of ductus deferens (Red arrows), vesicular glands (S), prostate (P), bulbourethral gland (B) and penis (P).

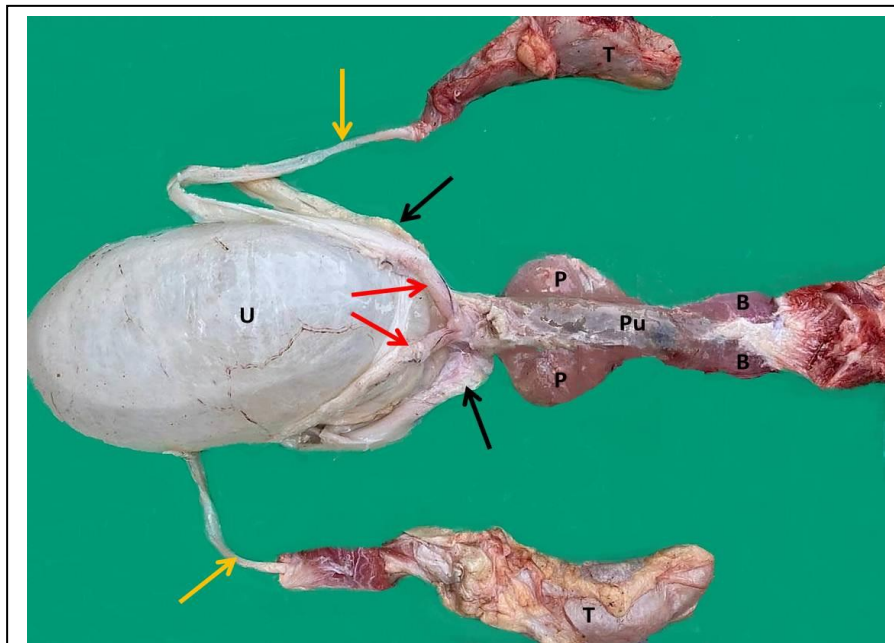


Figure 2: Macrophotograph of mature male reproductive system (Donkey) shows: testis (T), ductus deferens (Yellow arrows), ampulla of ductus deferens (Red arrows), pelvic urethra (Pu), vesicular glands (black arrows), prostate (P), and bulbourethral gland (B).

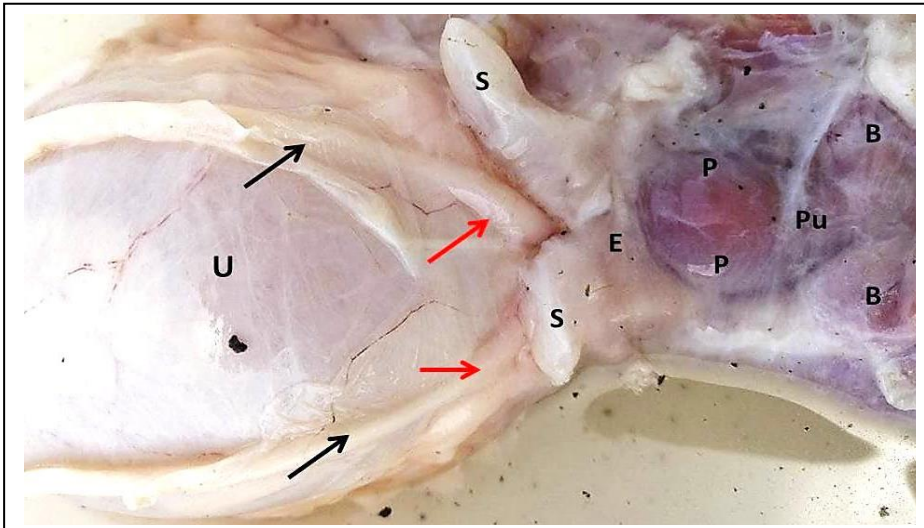


Figure 3: Macrograph of immature accessory sex glands (Donkey) shows: ductus deferens (black arrows), ampulla of ductus deferens (Red arrows), vesicular glands (S), ejaculatory duct (E), prostate (P), and bulbourethral gland (B).

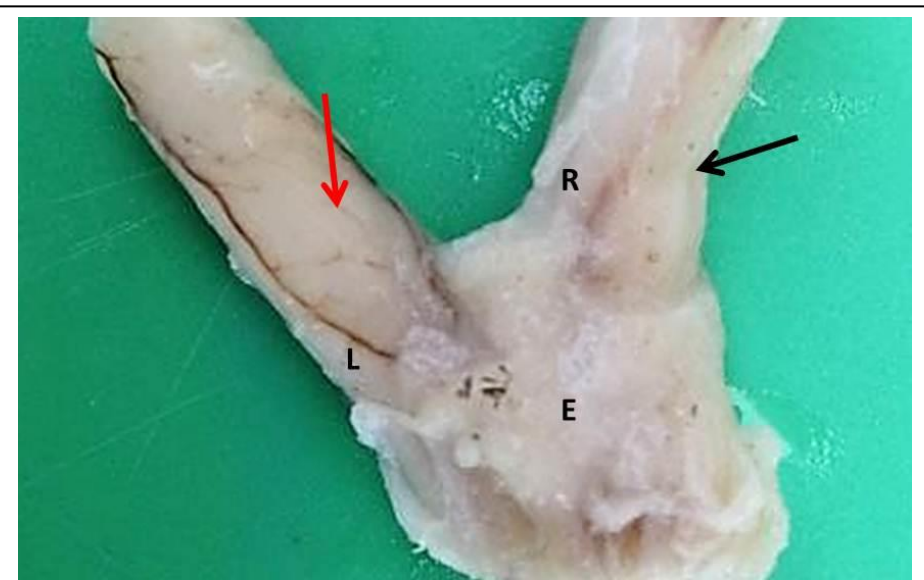


Figure 4: Macrograph of ampulla of ductus deferens (immature donkey) shows: right ampulla (R), left ampulla of ductus deferens (L), right vesicular glands (Black arrow), left vesicular glands (Red arrow), ejaculatory duct (E).

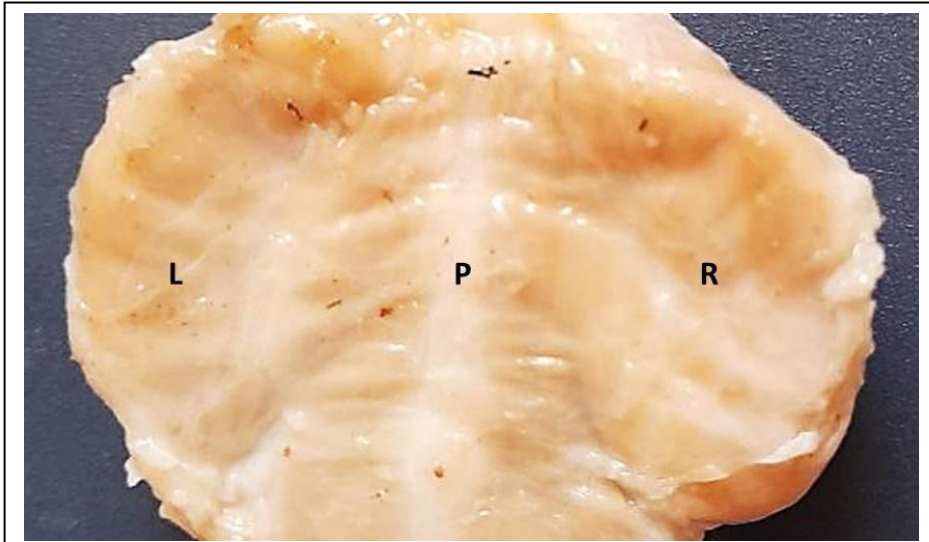


Figure 5: Macrophotograph of prostate (immature donkey) shows: right lobe of prostate (R), left lobe of prostate (L) and pelvic urethra (P).

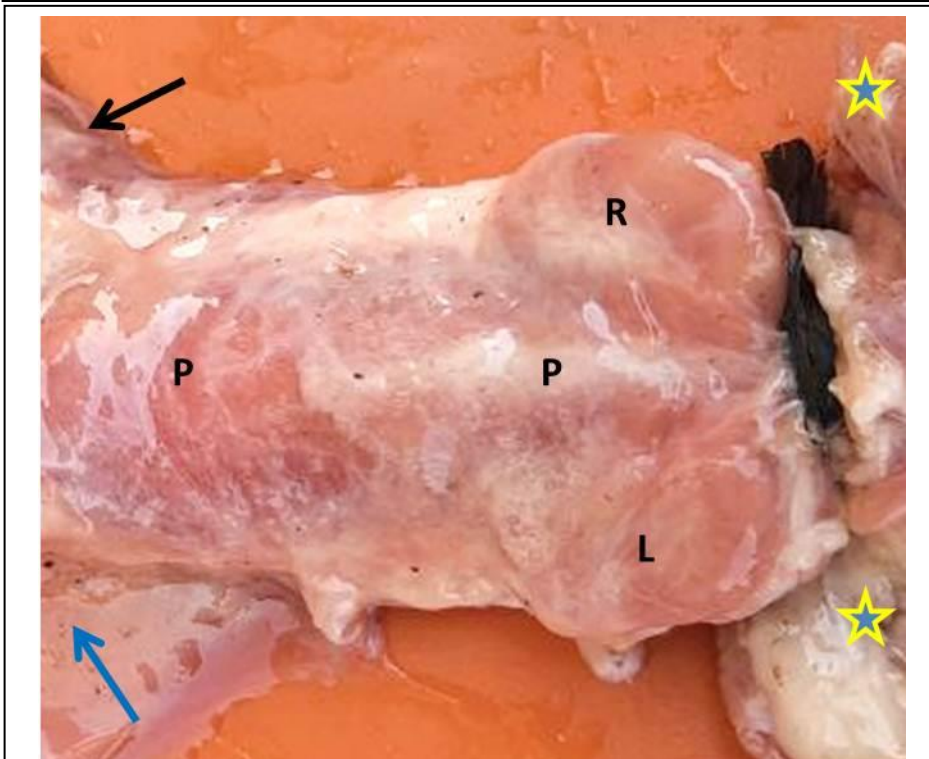


Figure 6: Macrophotograph of prostate and bulbourethral glands (immature donkey) shows: right lobe of prostate (Black arrow), left lobe of prostate (blue arrow), pelvic urethra (P), right lobe of bulbourethral gland (R), left lobe of bulbourethral gland (L), and crura of penis (sterisks)

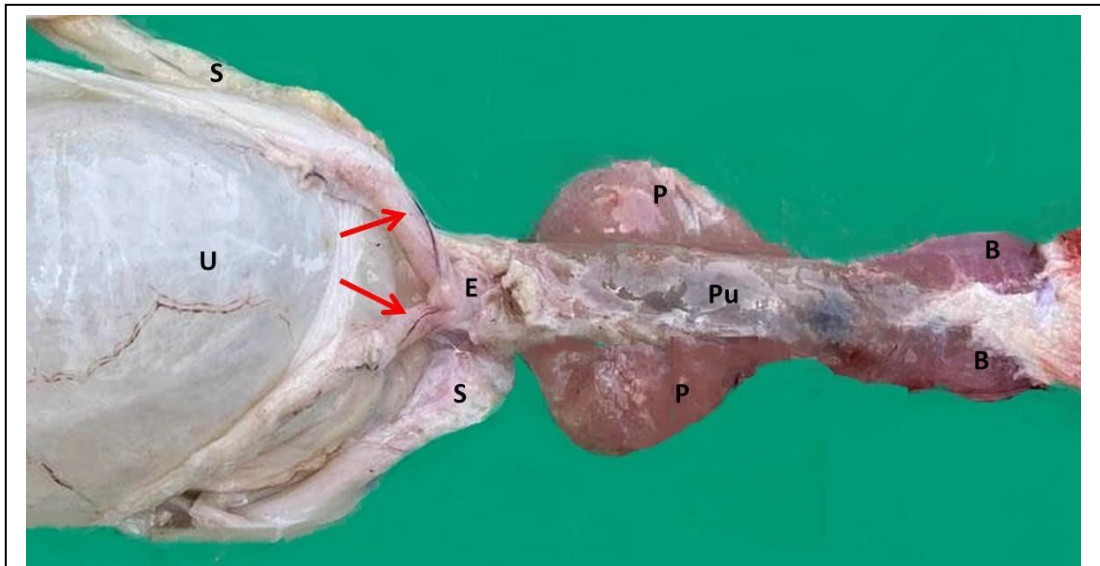


Figure 7: Macrophotograph of mature male accessory gland (Donkey) shows urinary bladder (U), ampulla of ductus deferens (Red arrows), ejaculatory duct (E), vesicular glands (S), prostate (P), pelvic urethra (Pu), and bulbourethral gland (B).