

**How to Cite:**

Soliman, M., Roshdy, S., Abdalla, A., Soliman, N., Agrawal, A., & Denewer, A. (2022). Total breast reconstruction using thoracodorsal artery perforator (TDAP) flap with or without implants: Two centers experience. *International Journal of Health Sciences*, 6(S4), 7846–7852. <https://doi.org/10.53730/ijhs.v6nS4.10307>

## **Total breast reconstruction using thoracodorsal artery perforator (TDAP) flap with or without implants: Two centers experience**

**Mahmoud Soliman**

Surgical Oncology Department, Faculty of Medicine, Mansoura University, Egypt

**Sameh Roshdy**

Surgical Oncology Department, Faculty of Medicine, Mansoura University, Egypt

**Ahmed Abdalla**

Surgical Oncology Department, Faculty of Medicine, Mansoura University, Egypt

**Nermin Soliman**

Radiology Department, Faculty of Medicine, Mansoura University, Egypt

**Amit Agrawal**

Cambridge Breast Unit, Cambridge University Hospitals NHS Foundation Trust, UK

**Adel Denewer**

Surgical Oncology Department, Faculty of Medicine, Mansoura University, Egypt

**Abstract**---Introduction: The thoracodorsal artery perforator (TDAP) flap has been increasingly used for breast reconstruction mainly due to reduced donor site morbidity compared to latissimus dorse (LD) flap. TDAP flap was mainly described for partial reconstruction of breast defects following breast conserving surgery. This study describes the use of the TDAP flap in total breast reconstruction with or without synthetic implants in two breast units. Methods: Between June 2017 and June of 2022, seven patients were included. Six patients from the Oncology Center, Egypt and one patient from Cambridge Breast Unit. Preoperative perforator mapping method was recorded. Patients' demographic data, type of mastectomy and reconstruction and surgical outcome were recorded. Results: Five patients had total breast reconstruction without implants, whilst two patients had implant-enhanced TDAP reconstruction. The mean age of was 39 years (31-43), and the mean mean body mass index (BMI) was 28 kg/m<sup>2</sup> (23-36). Median hospital stay was 3 days. All patients had immediate breast reconstruction following mastectomy without the

need for contralateral symmetrization or corrective surgery. No seroma was reported. Only one patient had complete flap loss, while one patient who had minor wound infection. Conclusion: Total breast reconstruction using the TDAP flap with or without implants is a better alternative to myocutaneous flaps in selected patients with small breasts. Implant-enhanced TDAP flaps offer a reliable autologous-based reconstructive option when abdominal tissue is not available or contraindicated. The pedicled thoracodorsal artery perforator flap offers an alternative for total autologous breast reconstruction in small to medium breasted patients when abdominal tissues are not available

**Keywords**---thoracodorsal artery, perforator flap, breast reconstruction, TDAP, autologous.

## **Introduction**

The thoracodorsal artery perforator (TDAP) flap was first used as a free flap by Angrigiani for reconstruction of postburn skin and soft tissue loss (1). It was not until 2004, when Hamdi and his colleagues reported its use as a pedicled flap for breast reconstruction (2). The main advantage is providing adequate volume to fill different quadrants of the breast with variable sizes, yet with lower donor site morbidity. Nonetheless, in the settings of total breast reconstruction, the limited volume provided by the flap may not be sufficient to restore the full breast mound in patients with large breasts. Implant-enhanced TDAP reconstruction is used to expand reconstruction possibilities and provide extra protection for the implant, but this is limited by prosthesis-related short and long-term complications such as infection and capsular contracture especially if post-mastectomy radiotherapy is planned (3). This study presents the experience of two breast units in TDAP-based total breast reconstruction with or without implants.

## **Patients and Methods**

Between June 2017 and June of 2022, a total of seven patients who underwent total breast reconstruction with TDAP flap with or without implants were retrospectively reviewed. Six patients in the Oncology Center, Mansoura University, Egypt and one patient in the Cambridge University Hospital, United Kingdom were included. TDAP-only based reconstruction was performed in 5 patients, whilst two patients had implant-enhanced reconstruction. Patients with contraindications to or not wishing abdominal-based flaps or those with small sized breasts and excess tissue in the back area were offered this approach. Patient's demographic data, surgical data, surgical outcome and follow up data were analyzed.

## **Surgical Technique**

Preoperative marking of the perforators was routinely done in all patients using doppler flowmetry, preferably in lateral position. Computed Tomographic Angiography (CTA) was done in two patients to aid perforator mapping and

facilitate surgical planning. Thoracodorsal artery (TDA) perforators were assessed in both axial and coronal sections (figure 1) and volume rendering (VR) was used to create enhanced images or 3D images that could be easily interpreted by surgeons when marking the perforators on patient's skin.

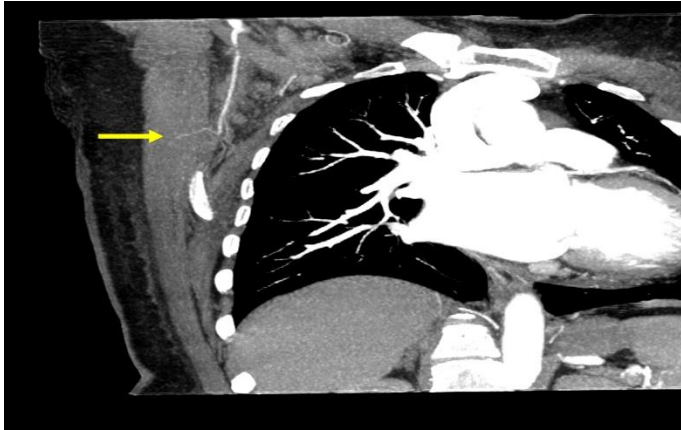


Figure 1: Computed tomographic angiography (CTA) showing one of the perforators of the descending branch of the Thoracodorsal artery (yellow arrow) in coronal view

The flap was designed in a transverse or oblique fashion trying to be in continuity with the inframammary fold (IMF) and including the marked perforators within the flap (figure 2). Mastectomy and axillary surgery were performed in supine position then the patient was rotated to lateral position for flap harvest. Following the incision, the skin flap was deepithelialized, unless needed to replace the areola or any resected breast skin. Extension of the TDAP flap using skin beveling technique was used to augment the harvested fat tissue by harvesting fat deep to the superficial fascia.

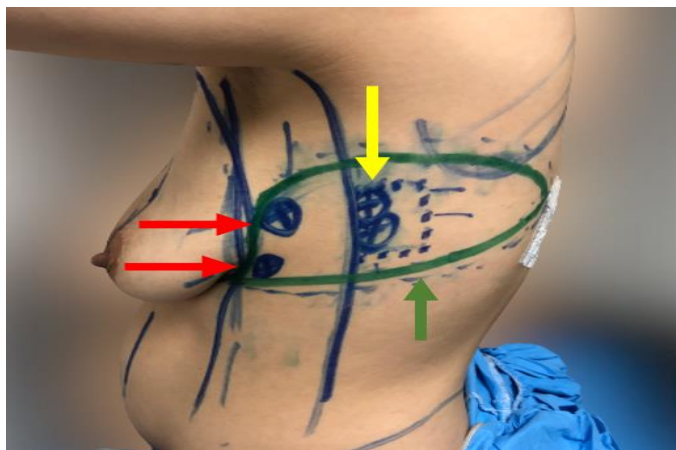


Figure 2: Preoperative TDAP flap markings. Yellow arrow pointing to two TDA perforators identified by doppler 8 and 9 cm below the posterior axillary fold and 1 cm behind the lateral border of the LD muscle. Red arrows pointing to lateral intercostal artery perforators. Green arrow pointing to the flap design

Dissection started from medial to lateral and from below upwards till site of marked perforator was reached. Perforators were then identified and dissected from between muscle fibers (classic TDAP) till reaching descending branch of thoracodorsal artery which was then dissected and followed till reaching main pedicle achieving an adequate pedicle length. If the perforator was not pulsatile or of small diameter, a small cuff from the LD muscle incorporating the perforators was included (MS-LD Type 1 or 2) (figure 3). Intraoperative doppler was used to confirm the site of the perforators and check their status during dissection.

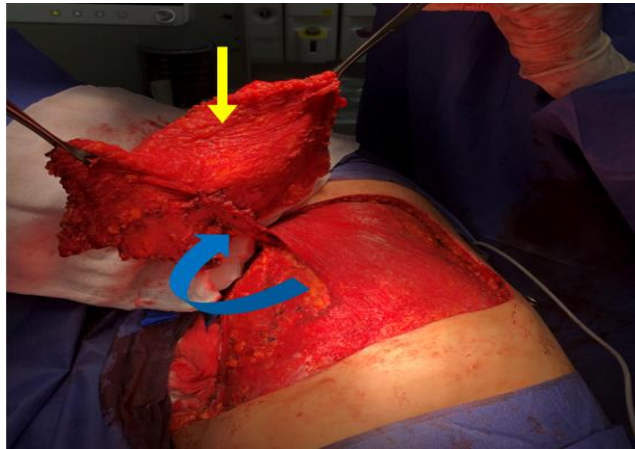


Figure 3: Type 1 TDAP flap harvest. Yellow arrow pointing to the harvested flap and blue arrow showing a 2 cm cuff of the LD incorporating the perforators

The skin paddle was then rotated anteriorly, through the split latissimus dorsi muscle, into the breast area. The donor site was closed primarily after further undermining to allow tension-free closure. The patient was then repositioned into supine position and the flap was fixed in position by a few sutures into the pectoralis major muscle. Two drains were inserted, one in the back and one in the breast.

In patients who had implant-enhanced TDAP flap reconstruction, the pectoralis major muscle was raised off the chest wall creating a pocket for the implant and the exposed infero-lateral portion of the implant was covered using the TDAP flap to provide a total coverage of the implant (figure 4).

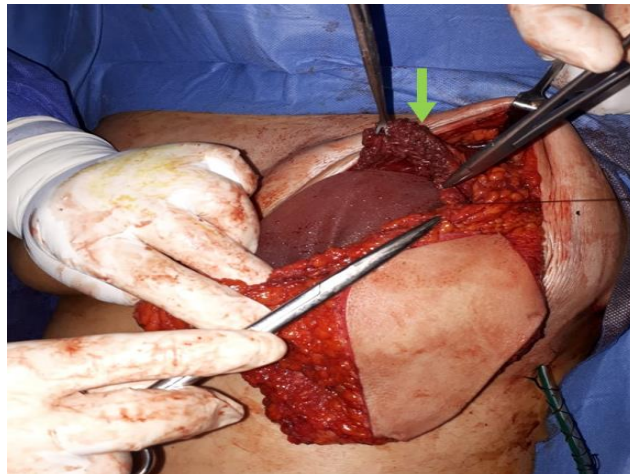


Figure 4: The raised pectoralis major muscle for retro-pectoral implant pocket creation (green arrow)

## Results

In all patients, the flaps were based on one to two perforators arising from the descending branch of the thoracodorsal artery. The mean age of the patients was 39 years (range, 31-43), and the mean body mass index (BMI) was 28 kg/m<sup>2</sup> (range, 23-36). Patients' data are summarized in Table 1.

Table 1: patients' demographic data and mastectomy type

Patients	Age	BMI	Mastectomy	Cup size	Ptosis
1	43	36	SSM	B	1
2	42	23	NSM	A	0
3	31	29	NSM	A	1
4	41	30	SRM	B	2
5	42	23	SSM	C	N/A
6	35	25	SSM	B	2
7	41	32	NSM	B	2

BMI, Body Mass Index (Kg/m<sup>2</sup>); SSM, Skin-Sparing Mastectomy; NSM, Nipple-Sparing Mastectomy; SRM, Skin-Reducing Mastectomy

All patients had no previous surgeries and two had history of controlled diabetes. Three patients had sentinel node biopsy, while the remaining had axillary node dissection. Tumors were multicentric in all cases except one who had unifocal retroareolar tumor necessitating nipple-areola complex (NAC) resection. While five patients had surgery for invasive cancers, two patients had ductal carcinoma in-situ.

Contralateral symmetrizing surgery to achieve symmetry was not required. Only one patient had complete flap loss mainly due to pedicle twisting that was managed by flap resection and completion mastectomy. Apart from one patient who had minor wound infection, all other patients had uneventful postoperative course. Median length of hospital stay was 3 days. Drains were inserted in the

back in all cases with no reported seroma during follow up. Complications, hospital stay, and timing of reconstruction are summarized in table 2.

Table 2: reconstruction data and surgical outcome

Patients	Timing of reconstruction	Type of reconstruction	Complications	Hospital stay (days)
1	Immediate	TDAP alone	Flap loss	3
2	Immediate	TDAP alone	None	1
3	Immediate	TDAP alone	None	3
4	Immediate	TDAP alone	None	2
5	Immediate	TDAP alone	None	1
6	Immediate	TDAP + implant	None	3
7	Immediate	TDAP + implant	Wound infection	4

With a median follow-up of 3 months, no revision surgery was performed in all patients. Neoadjuvant chemotherapy was given in two patients, whilst 3 patients had adjuvant chemotherapy. Only three patients received adjuvant radiotherapy.

## Discussion

Muscle-sparing autologous reconstruction, free or pedicled, offers a better approach compared to myocutaneous autologous tissue such as transverse rectus abdominis myocutaneous (TRAM) flap or latissimus dorsi (LD) flap. TDAP flap-based breast reconstruction represents a contemporary solution to high-risk patients, patients in whom abdominal-based reconstruction is not suitable or units with unavailable microsurgical settings (4). Even more, this flap was reported to be a primary option in patients with small to medium breast size with or without implants (3, 5).

Despite the tedious dissection needed for perforator localization, preoperative mapping of thoracodorsal artery (TDA) perforators using different modalities such as doppler US, color duplex or CT angiography represents the cornerstone in a successful and timely surgery. Computed tomographic angiography (CTA) provides detailed information about vascular anatomy besides reformatting the information into three-dimensional images. In Deep Inferior Epigastric Perforator (DIEP) flaps, CT angiography was found to be superior to Doppler ultrasound for vascular supply preoperative assessment and at identifying the location and course of the perforator vessels and, hence, reduced operative times (6). Hamdi et al described the possibility to convert the classic TDAP flap to muscle sparing variants if the perforators were found to be of small size or non-pulsatile for safe harvest. Type 1 muscle-sparing LD (MS-LD) includes a segment of maximum diameter 2x4cm, type 2 MS-LD in which width of segment is up to 5cm and type 3 when larger segments were included (2).

The major benefit from using the thoracodorsal artery perforator flap is the reduced donor site morbidity such as seroma and surgical pain with better shoulder function preservation (7). In addition, the long pedicle length and wide arc of rotation permits not only partial reconstruction of any breast quadrant, but also total autologous breast reconstruction without free tissue transfer. The

extended TDAP flap was described by Angrigiani by using the skin beveling technique including upper and lower fat superficial to the deep fascia or by augmenting the flap using lipomodelling and fat grafting (8). If the flap is planned to be extended, it is advisable to include at least two perforators to guarantee a robust blood supply to the distal tissue

## Conclusion

This study, despite the small number of cases, further confirms the safety and feasibility of total breast reconstruction using the TDAP flap without implants in carefully selected patients with small non-ptotic breasts. Implant-enhanced TDAP flaps is a better alternative to LD-covered implants with less donor site morbidity. TDAP flap offers a reliable autologous-based reconstructive option in breast units with no microsurgical expertise or equipment. Fat grafting can be required either for immediate augmentation of the flap or as a secondary procedure to correct breast contour or volume.

## References

1. Angrigiani C, Grilli D, Siebert J. Latissimus dorsi musculocutaneous flap without muscle. *Plastic and reconstructive surgery*. 1995;96(7):1608-14.
2. Angrigiani C, Rancati A, Escudero E, Artero G. Extended thoracodorsal artery perforator flap for breast reconstruction. *Gland surgery*. 2015;4(6):519.
3. Eviasty, N., Daud, N. A., Hidayanty, H., Hadju, V., Maddeppungeng, M., & Bahar, B. (2021). The effect of personal coaching on increasing knowledge, attitudes, and actions about lactation nutrition, uterine involution, and lochia in public mothers. *International Journal of Health & Medical Sciences*, 4(1), 155-163. <https://doi.org/10.31295/ijhms.v4n1.1669>
4. Hamdi M, Decorte T, Demuynck M, Defrene B, Fredrickx A, Van Maele G, et al. Shoulder function after harvesting a thoracodorsal artery perforator flap. *Plastic and reconstructive surgery*. 2008;122(4):1111-7.
5. Hamdi M, Rasheed MZ. Advances in autologous breast reconstruction with pedicled perforator flaps. *Clinics in Plastic Surgery*. 2012;39(4):477-90.
6. Hamdi M, Salgarello M, Barone-Adesi L, Van Landuyt K. Use of the thoracodorsal artery perforator (TDAP) flap with implant in breast reconstruction. *Annals of plastic surgery*. 2008;61(2):143-6.
7. Hamdi M, Van Landuyt K, Monstrey S, Blondeel P. Pedicled Perforator Flaps in Breast Reconstruction: A New Concept. *Br J Plast Surg*. 2004;57(6):531-9.
8. Rozen WM, Chubb D, Grinsell D, Ashton MW. Computed tomographic angiography: clinical applications. *Clinics in Plastic Surgery*. 2011;38(2):229-39.
9. Santanelli F, Longo B, Germano S, Rubino C, Laporta R, Hamdi M. Total breast reconstruction using the thoracodorsal artery perforator flap without implant. *Plastic and reconstructive surgery*. 2014;133(2):251-4.
10. Suryasa, I. W., Rodríguez-Gómez, M., & Koldoris, T. (2021). Health and treatment of diabetes mellitus. *International Journal of Health Sciences*, 5(1), i-v. <https://doi.org/10.53730/ijhs.v5n1.2864>