

How to Cite:

Sadiq, S. A., Ikbal, A. H., & Kassim, F. A. (2022). Pathophysiological study of atorvastatin drug on toxicity induced by D-galactose in liver of experimental rats. *International Journal of Health Sciences*, 6(S5), 7863–7877. <https://doi.org/10.53730/ijhs.v6nS5.10453>

Pathophysiological study of atorvastatin drug on toxicity induced by D-galactose in liver of experimental rats

Sadiq Sh. A.

Department of Biology, College of Science, University of Basrah, Basrah, Iraq.
Email: pgs2078@uobasrah.edu.iq

Ikbal A. H.

Department of Biology, College of Science, University of Basrah, Basrah, Iraq.
Email: eqbal.hazam@uobasrah.edu.iq

Kassim F. A.

Department of Clinical Laboratory Sciences, College of Pharmacy, University of Basrah, Basrah, Iraq.
Email: kassim.Kareem@uobasrah.edu.iq

Abstract---Background: This study was designed to clarify the toxic effect of a high dose of atorvastatin and the palliative effect of low doses of atorvastatin on toxicity induced by D-galactose in the liver, kidney, and adrenal gland organs. The current study was conducted on 36 healthy adult male Wistar albino rats (*Rattus norvegicus*) who were sexually mature at the age of 8-10 weeks and weighed between 200 and 250 grams in the animal house of Pharmacy College/ Basrah University. Methods: These rats were selected and divided into six main groups of equal weight, each with six rats. The first group (control) was drenched in (1) mL of normal saline. The second group was drenched in a single dose of atorvastatin (150 mg per kg B.W), the third received D-galactose at a dose of (500 mg per kg B.W), and the fourth group was treated with both D-galactose and atorvastatin (10 mg per kg B.W), the fifth group was coadministered with both D-galactose and atorvastatin (20 mg per kg B.W), and the sixth group where rats cotreated with Dgalactose and atorvastatin (40 mg per kg B.W). The treatment was extended for 8 weeks. At the end of the experiment, all groups were sacrificed, and blood was isolated to measure biochemical tests such as alanine aminotransferase (ALT) and aspartate aminotransferase (AST), and total bilirubin. To prepare for histological examination, the liver was fixed in formalin solution. Results and discussion: The result of biochemical tests revealed: Significant increase in serum aspartate aminotransferase (AST), alanine aminotransferase (ALT), and total bilirubin in both high-dose

atorvastatin and D-galactose treated rats compared with a control group. On other hand, animals cotreated with D-galactose and 10,20, and 40 mg per kg single dose of atorvastatin showed a significant decrease in ALT, AST, and total bilirubin compared with D-galactose treated group. The histological study revealed many pathological changes of different degrees in the liver in all treated animal groups: High dose atorvastatin 150 mg per kg group treated group showed necrotic hepatocyte and fat degeneration. White D-galactose coadministered rats exhibited liver congestion of the central vein and inflammation. Male rat's livers cotreated with D-galactose and 10,20,40 mg per kg atorvastatin revealed less necrosis with mild fat degeneration compared with histological changes noted in the D-galactose group and high dose of atorvastatin.

Keywords---Atorvastatin Drug, Toxicity in Liver, D-galactose.

I. Introduction

Statins, or inhibitors of 3-hydroxy-3-methylglutaryl coenzyme A reductase, are widely used to lower serum cholesterol levels and reduce long-term morbidity and death associated with coronary artery disease. In most animal species and humans, statins are quite efficient at lowering serum cholesterol (Sahebkar *et al.*, 2016). Statins may have non-lipid-related pleiotropic effects in addition to lowering lowdensity lipoprotein cholesterol and cardiovascular morbidity and death. Endothelial function is improved, atherosclerotic plaques are stabilized, anti-inflammatory, immunomodulatory, and antithrombotic effects are present, as are benefits on bone metabolism and a reduced risk of dementia. The suppression of the production of isoprenoid intermediates in the mevalonate pathway is assumed to be the source of these extra advantages (Ward *et al.*, 2019). Furthermore, statin use has been shown to lower pro-inflammatory mediator production, protect cells from oxidative damage during vascular injury, decrease platelet adhesion, activation, and thrombin generation, and improve blood flow (Jiang & Zheng, 2019). Among the statins is Atorvastatin, a synthetic 3-hydroxy-3-methylglutaryl coenzyme A analog with a significant effect in lowering total and low-density lipoprotein cholesterol levels, triglycerides, and changing the makeup of lipoproteins (Huisa *et al.*, 2010). Atorvastatin inhibits the enzyme 3-hydroxy-3-methylglutaryl coenzyme A reductase, which creates mevalonate in hepatic tissue. Mevalonate is a chemical that aids in the production of cholesterol. 3-hydroxy-3-methylglutaryl coenzyme A reductase inhibition reduces cholesterol production, lowering low-density lipoprotein cholesterol levels in the blood (Jabir & Jaffat, 2018). Other well-known qualities of Atorvastatin include anti-oxidant, anti-aging, anti-inflammatory, and analgesic actions (Taghipour *et al.*, 2019). Other statin side effects include neurological and neurocognitive consequences, hepatotoxicity, renal toxicity, and others (gastrointestinal, urogenital, reproductive), many of which are currently unknown (Ward *et al.*, 2019). The most prevalent hepatic adverse effects linked with atorvastatin are asymptomatic hepatic enzyme increases (Bhardwaj, 2007). Dgalactose is an important nutrient and a reducing sugar that reacts with amino acids to form advanced substances associated with glycosylation. Its injection in high doses contributes to the generation of reactive

oxygen species via its metabolism by galactose oxidase to hydrogen peroxide, eventually generating reactive oxygen species, as well as altering the normal osmotic pressure, which leads to metabolic disorders of vital organs and eventually organism aging (Saleh *et al.*, 2019).

II. Materials and Methods

Experimental Animals

The experiments were conducted in the animal house of Pharmacy College, University of Basrah, using (36) healthy adult male Wistar albino rats (*Rattus norvegicus*) which were sexually mature at the age of (8-10) weeks and weighed between (200) and (250) grams. The animals were housed in plastic cages with mesh tops that measured (20×30×40) cm and were kept at a comfortable temperature of (20-30°C) with a 12-hour light/dark cycle. Before beginning the experiment, they were acclimatized for (3) weeks in plastic cages with sanitary beds, (6) rats per cage. Throughout the experiment, all rats were fed standard laboratory pellets and were given fresh clean water *ad libitum* (Salman, 2021).

Preparation of Drugs

The appropriate amount and doses were prepared using Atorvastatin tablets and D-galactose stock powder according to the following formula: $(C_1 V_1 = C_2 V_2)$ C stands for concentration, while V stands for volume. According to Taghipour *et al.*, (2019), D-galactose doses of (500) mg per kg body weight were prepared by dissolving (625) mg of D-galactose powder in (6) ml of normal saline to obtain (104) mg of D-galactose in each 1 ml of prepared solution. An electric grinder was used to ground atorvastatin tablets to a fine powder. Following that, daily doses were weighed using analytical balances. These doses were dissolved in normal saline daily over the experimental period, and gavage was used to administer the medicines to the rats orally. Atorvastatin at dose (10) & (20) mg per kg, single dose per body weight depended on (Panonnummal *et al.*, 2014). Atorvastatin dose (40) mg per kg, single dose per body weight depended on (Jiang & Zheng, 2019). Atorvastatin dose (150) mg per kg, single dose per body weight depended on (Reddy *et al.*, 2010).

Experimental Design

Thirty-six adult male rats were chosen and divided into six groups of equal weight, with six rats in each group, as follows:

1. The First (Control) Group: They were given (1) ml of normal saline through a stomach tube for two months as a negative control.
2. The Second (Atorvastatin 150 mg / kg) Group: This group was administered orally with (1) ml of a hazardous dose of (150) mg per kg, single dose per body weight of atorvastatin for two months as a positive control.
3. The Third (D-galactose 500 mg / kg) Group: This group was administered orally with (1) ml of a hazardous dose of (500) mg per kg, single dose per body weight of D-galactose for two months as a positive control.
4. The Fourth (10 mg / kg atorvastatin & D-galactose) Group: This group was administered orally both of (1) ml Atorvastatin with a dose of (10) mg per kg,

single dose per body weight and (1) ml D-galactose with a dose of (500) mg per kg, single dose per body weight, for two months.

5. The Fifth (20 mg / kg atorvastatin & D-galactose) Group: This group was administered orally both of (1) ml Atorvastatin with a dose of (20) mg per kg, single dose per body weight and (1) ml D-galactose with a dose of (500) mg per kg, single dose per body weight, for two months.
6. The Sixth (40 mg / kg atorvastatin & D-galactose) Group: This group was administered orally both of (1) ml Atorvastatin with a dose of (40) mg per kg, single dose per body weight and (1) ml D-galactose with a dose of (500) mg per kg, single dose per body weight, for two months.

Sample Collection: Collection of Blood Samples

At the end of the eight-week experiment period, all rats in all experimental groups were sacrificed. Following a chloroform anesthesia, an appropriate cut in the rat abdomen was made. The blood samples were obtained from the heart using disposable syringes with a volume of (3-5) cc. (5) ml of blood was placed into jelly test tubes free of anticoagulant and centrifuged at 3500 rpm for (10) minutes to isolate blood serum, which was then transferred to eppendorf tubes and stored at -20 °C. (Cray *et al.* 2009). Biochemical parameters such as liver enzymes alanine aminotransferase and aspartate aminotransferase, total bilirubin, are all measured in blood serum.

Collection of Tissue Samples

At the end of the eight-week experiment, liver from rats in each experimental group were dissected, washed with normal saline to remove blood and tissue debris, then cut into appropriate sizes and transferred to be fixed with formalin (10%) to be ready for histological study. (luna, 1968).

III. Results

Biochemical Results: Effects of D-galactose, Atorvastatin Alone, Combination of D-galactose with Different Doses of Atorvastatin on Liver Enzymes

The obtained results in (Table 1) reveal significant ($P \leq 0.05$) increase of both AST and ALT in serum of male rats treated with D-galactose and atorvastatin at (150 mg per kg) dose compared with control group and other groups. Both AST and ALT in serum of rats coadministration with both D-galactose and different doses of atorvastatin (10, 20, 40 mg per kg) showed significant ($P \leq 0.05$) decrease in comparison with D-galactose group.

Effects of D-galactose, Atorvastatin, Combination of D-galactose with Different Doses of Atorvastatin on Total Bilirubin Concentration

Results in (Table 2) reveal significant ($P \leq 0.05$) increase in total bilirubin concentration in both D- galactose group and high dose atorvastatin group compared with control group. Total bilirubin concentration in serum of rats

treated with both D- galactose and atorvastatin drug at dose (20, 40 mg per kg) exhibited significant ($P \leq 0.05$) decrease compared with D- galactose group.

Table 1: Effects of D-galactose, Atorvastatin Alone, Combination of D-galactose with Different Doses of Atorvastatin on Liver Enzymes: (Mean \pm Standard Deviation)

<u>Treatment</u>	<u>Parameter</u>	<u>ALT</u> <u>Mean\pmSd</u>	<u>AST</u> <u>Mean\pmSd</u>
Control Group		29.9667 \pm 2.36 b	108.7333 \pm 4.88 e
Atorvastatin 150 mg./kg. Group		35.2000 \pm 0.22 a	131.6967 \pm 0.75 d
D -galactose 500 mg./kg. Group		36.7167 \pm 0.51 a	170.3100 \pm 0.81 a
AtorvastatinD-galactose 500 10 mg./kg.mg./kg.	30.3400 \pm 0.07 b	167.6067 \pm 7.71 a	
AtorvastatinD-galactose 500 20 mg./kg.mg./kg.	27.0000 \pm 3.28 b	150.0000 \pm 0.23 b	
AtorvastatinD-galactose 500 40 mg./kg.mg./kg.	27.6733 \pm 0.40 b	140.7633 \pm 1.00 c	
LSD		2.98	6.71
Different letters indicate significant differences among experimental groups at ($P \leq 0.05$).			

Different letters indicate significant differences among experimental groups at ($P \leq 0.05$).

Table 2: Effects of D-galactose, Atorvastatin, Combination of D-galactose with Different Doses of Atorvastatin on Total Bilirubin concentration: (Mean \pm Standard Deviation)

Parameter	Bilirubin	
Treatment	Mean \pm standard deviation	
Control Group	0.6333 \pm 0.21	b
Atorvastatin 150 mg./kg. Group	2.1667 \pm 0.06	a
D-galactose 500 mg./kg. Group	1.7000 \pm 0.87	ab
Atorvastatin 10 mg./kg. + D-galactose 500 mg./kg.	1.2667 \pm 0.29	b
Atorvastatin 20 mg./kg. + D-galactose 500 mg./kg.	0.7000 \pm 0.00	b
Atorvastatin 40 mg./kg. + D-galactose 500 mg./kg.	0.9667 \pm 0.23	b
LSD	0.71	

Different letters indicate significant differences among experimental groups at ($P \leq 0.05$).

Histopathological Results

The liver of Control male rats showed polygonal lobules with central vein and radiating hepatocellular trabeculae enclosing liver sinusoids and hepatocytes. Portal triad composed of bile ductile, portal venule and arteriole appeared at the periphery of the lobules. Hepatocytes showed eosinophilic cytoplasm with large central nuclei and small hyperchromatic nucleoli. No inflammatory Cells, no fibrous connective tissue were observed (Figure 1). Liver tissue in male rats treated with high dose of atorvastatin showed well preserved Lobular architecture, with dilated central vein. Many hepatocytes are necrotic with aggregates of inflammatory cells and areas of fat degeneration. Hepatocytes revealed enlarged nuclei with large, occasionally multiple prominent and eosinophilic nucleoli. Sinusoids are not visualized because of congestion (Figure 2). Liver in male rats treated with D-galactose appear ant fatty degeneration, dilated, congested central veins, many hepato-cellular are necrotic, with increased inflammatory cells. Portal veins and sinusoids appeared dilated and congested (Figure 3). The liver of male rats cotreated with both D-galactose and (10 mg per kg) atorvastatin showed dilated central vein. Mild cell necrosis, atypical nuclei, occasional fat necrosis, bile ducts hypertrophied. Sinusoids appeared normal. No inflammation was observed (Figure 4). Male rats' livers treated with D-galactose and (20 mg per kg) atorvastatin were similar to rats' livers treated with D-galactose and (10 mg per kg) atorvastatin, but necrosis was less or absent. Histology of the liver is almost normal (Figure 5). Liver in male rats cotreated with D-galactose and (40 mg per kg) atorvastatin revealed mild hepatocellular necrosis, congested central vein with mild fat degeneration and inflammatory infiltrate at portal area. Bile ducts are normal (Figure 6).

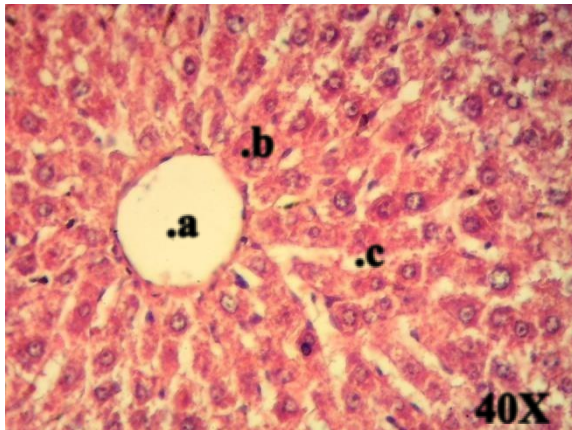


Fig. 1. cross section in liver showing:
a: central vein. **b:** trabeculae enclosing.
c: sinusoids. in control group.

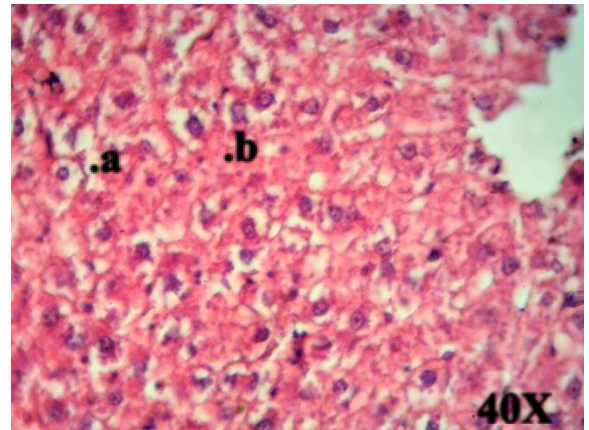


Fig. 2. cross section in liver showing:
a: necrotic. **b:** degeneration. in high
 dose of atorvastatin group.

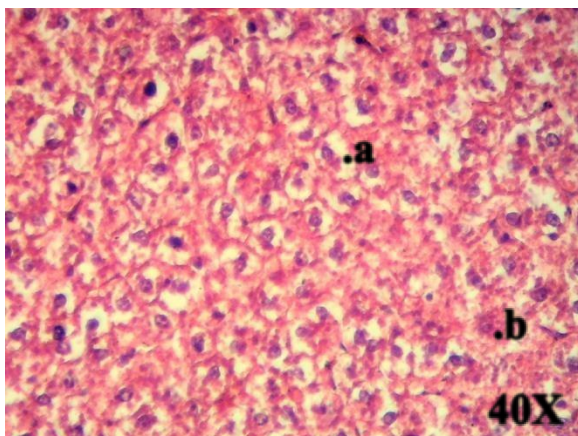


Fig. 3. cross section in liver showing:
a: fatty degeneration. **b:** necrotic.

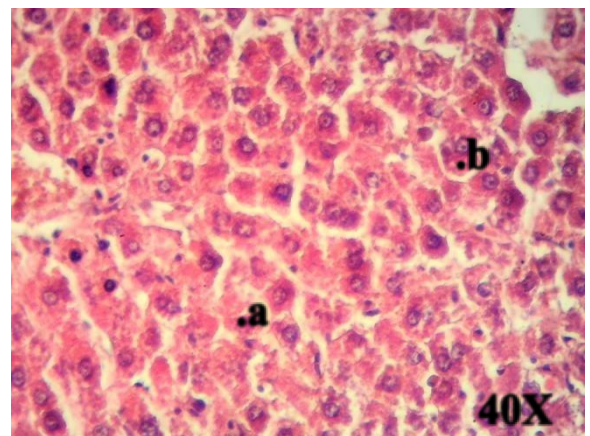


Fig. 4. cross section in liver showing:
a: mild cell necrosis. **b:** atypical nuclei. in
 D-galactose group. in both D-galactose and (10 mg per kg) atorvastatin group.

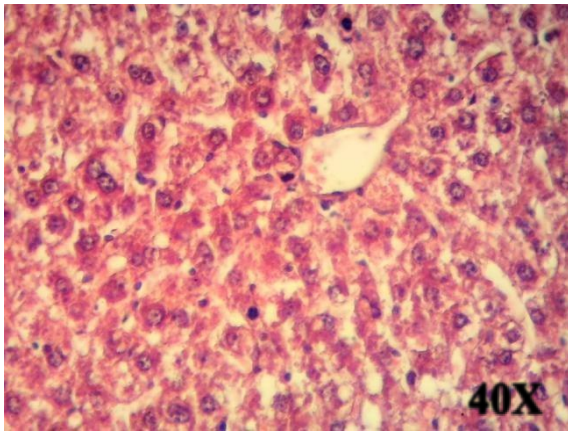


Fig. 5. cross section in liver showing: **a:**central vein. **b:**sinusoids appear normal. in both D-galactose and (10 mg per kg) atorvastatin group.

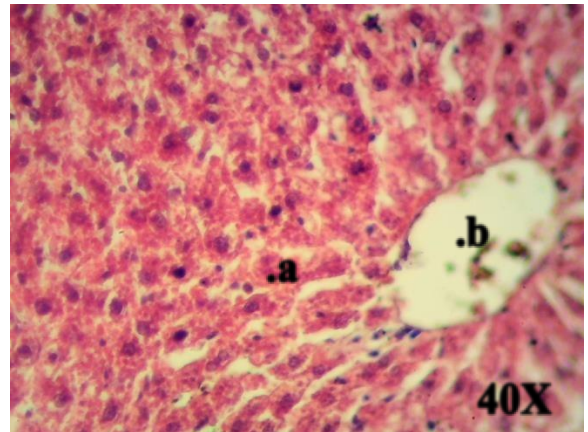


Fig. 6. cross section in liver showing: **a:**mild hepatocellular necrosis. **b:**central vein congested. in both D-galactose and (20 mg per kg) atorvastatin group.

IV. Discussion

Biochemical Results: Effects of D-galactose, Atorvastatin Alone, Combination of D-galactose with Different Doses of Atorvastatin (10,20,40 mg per kg) on Liver Enzymes

The results of current study show a significant ($P \leq 0.05$) increase in both AST and ALT enzymes in D-galactose treated rats compared to control group and other treated rats which agrees with the study of Gao *et al.* (2018) who confirmed that overload of d-galactose can increase the production of reactive oxygen species, resulting in oxidative stress that can attack essential cell constituents, induce lipid peroxidation, damage the membranes of cells and organelles in the liver, cause the swelling and necrosis of hepatocytes, and ultimately result in hepatic injury. Our present study is consistent with the study of Badebustan *et al.* (2019) who observed lipid oxidation in liver, as well as an increase in AST and ALT after D-galactose ingestion. When compared to normal rats, D-galactose causes considerable increases in the liver enzyme biomarkers ALT, AST, total bilirubin, and direct bilirubin. D-galactose-induced increases in liver aminotransferases have been identified as early sensitive markers of liver injury during liver aging (Chen *et al.*, 2018; El-Baz, *et al.*, 2018). In agreement with the results of our current study, increased ALP, AST, and ALT levels indicate that the liver is releasing these enzymes into the bloodstream, indicating hepatotoxicity, liver tissue damage, and liver necrosis (Hu *et al.*, 2014). Hepatocytes ordinarily contain the enzymes alanine aminotransferase (ALT), aspartate aminotransferase (AST), and alkaline phosphatase (ALP), and their levels in the blood are usually related to the severity of the liver injury. The activity of these enzymes rises when the liver is inflamed or dysfunctional. ALT, AST, and ALP levels in the serum and liver of animals treated with D-galactose were found to be significantly elevated in previous studies (Chen *et al.*, 2011, 2018; Huang *et al.*, 2013; Kong *et al.*, 2018; Lin *et al.*, 2018; Liu *et al.*, 2019; Mo *et al.*, 2017; Mohammadi *et al.* 2018; Shahroudi *et al.* 2017; Taghipour *et al.*, 2019; Wang *et al.*, 2018; Yang *et al.*,

2019). However, our results reveal that coadministration of atorvastatin 10,20, and 40 mg per kg with Dgalactose reduce the toxic effects of D-galactose on hepatocytes by a decrease in both ALT and AST. This agrees with the study of Taghipour *et al.*, (2019) who showed that atorvastatin treatment could improve renal and hepatic toxicity induced by D-galactose and regulate ALT, and AST levels in mice. Several studies showed non-alcoholic fatty liver disease patients prescribed statins in before-after interventional studies had a reduction of baseline values for all safety outcomes analyzed, such as ALT and AST, and that the results of the meta-analysis provide pooled data on the safety of statin treatment in patients with non-alcoholic fatty liver disease. The findings add to previous evidence from a retrospective study involving 4024 hyperlipidemia patients, which showed no increased risk of hepatotoxicity in statin-treated patients, reinforcing the evidence that statin therapy may be safe in Non-alcoholic fatty liver disease patients even when liver damage is almost clinically evident (Daniele *et al.*, 2021). Even if serum liver enzymes are mildly elevated, clinicians should not be discouraged from prescribing statins to non-alcoholic fatty liver disease patients. Indeed, a clinically significant drug-induced liver injury by statins is very rare (Einar *et al.*, 2012). Our results show that a high dose of atorvastatin caused an elevation in ALT and AST levels which agrees with Jiang & Zheng (2019) who showed that rats administered atorvastatin at a dose of 80 mg per kg daily exhibited higher levels of AST and ALT, and is consistent with the study of Abed Al-kareem *et al.*, (2020) who observed a significant increase in ALT and AST concentration in albino rats administered atorvastatin for 60 days as many drugs overdoses cause liver injury and elevate levels of liver enzymes biomarkers. Most drug-induced liver injuries induced by statins are a consequence of the idiosyncratic effect. Nevertheless, as most of the statins are metabolized by CYP3A4, the concomitant use of a drug inhibiting CYP3A4 could elevate serum concentration of atorvastatin, simvastatin, and lovastatin and may favor liver enzyme elevation (Karahalil *et al.*, 2017).

Biochemical Results: Effects of D-galactose, Atorvastatin, Combination of Dgalactose with Different Doses of Atorvastatin (10,20,40 mg per kg) on Total Bilirubin concentration

Our present study reveals a significant increase in total bilirubin concentration in D-galactose treated rats which coincides with the study of Chen *et al.*, (2018) and El-Baz, *et al.*, (2018) who noticed that D-galactose treated rats showed considerable increases in liver enzyme biomarkers AST and ALT, and total bilirubin and direct bilirubin. Furthermore, D-galactose significantly raised serum total and direct bilirubin in rat sera. Because bilirubin catabolism is dependent on liver functions, elevated bilirubin levels indicate hepatocellular dysfunction (Boland *et al.*, 2014). In addition, higher direct bilirubin in D-galactose-treated rats implies not only hepatic dysfunction but also reduced intrahepatic excretion of conjugated bilirubin from bile duct hepatocytes (Astegiano *et al.*, 2004). Bilirubin is a mediator of (Heme oxygenase-1-mediated) cytoprotection against oxidative stress and intracellular homeostasis balance (Gomes *et al.*, 2010). This could explain why bilirubin levels in rats exposed to Dgalactose and other oxidative stress stimuli rose (Nam *et al.*, 2018; Roller *et al.*, 2010). Following D-galactose treatment, several studies found a decrease in antioxidant defense machinery and an increase in oxidative stress indicators (Coban *et al.*, 2014; El-

Baz *et al.*, 2018; Zhen *et al.*, 2016). In addition, Machova *et al.*, (2007) explained that atorvastatin therapy led to an elevation in total bilirubin concentration in mice after three weeks, which agrees with our recent findings indicating that rats treated with a high dose of atorvastatin exhibited an elevated level of total bilirubin. Statins' long-term effect on bilirubin levels in people is unknown. In a randomized trial, pravastatin treatment was related to a decreased serum total bilirubin level after one year compared to the control group in patients with advanced hepatocellular carcinoma (Kawata *et al.*, 2001).

Histopathological Results: Effects of high dose Atorvastatin, D-galactose, Combination of D-galactose with Different Doses of Atorvastatin (10,20,40 mg per kg) on Liver

The onslaught of reactive oxygen species on the liver causes it to gradually deteriorate with age. Because D-galactose is primarily processed in the liver, a high level of D-galactose in the body might hurt the liver. Treatment with D-galactose has been shown to cause oxidative stress in the liver by increasing Nitric oxide, malondialdehyde, and 8-hydroxy-2-deoxyguanosine while decreasing Catalase, glutathione peroxidase, superoxide dismutase, nitric oxide synthase, reduced glutathione, and total antioxidant capacity in liver tissues (Chen *et al.*, 2011, 2018; Feng *et al.*, 2016; Ji *et al.*, 2017; Kong *et al.*, 2018; Lei *et al.*, 2016; Li *et al.*, 2005; Liu *et al.*, 2018; Mo *et al.*, 2017; Mohammadi *et al.*, 2018; Noureen *et al.*, 2019; Shahroudi *et al.*, 2017; Xu *et al.*, 2016; Yang *et al.*, 2019; Zhuang *et al.*, 2017). The intracellular (p38 mitogen-activated protein kinase/nuclear factor erythroid 2-heme oxygenase-1) (p38 MAPK-NRF2-HO-1) signaling pathway in the liver has been shown to activate by D-galactose therapy (Gao *et al.*, 2018; Lin *et al.*, 2018). Through the p-p38 mitogen-activated protein kinase (p-p38 MAPK) pathway, a surplus of D-galactose resulted in an accumulation of galactose and its final metabolite galactitol, which finally led to cell osmotic stress and the accumulation of reactive oxygen species (Gao *et al.*, 2018). D-galactose therapy was proven to cause an inflammatory response when combined with oxidative stress, in animals liver issues treated with D-galactose exhibited an increase in inflammatory markers such as tumor necrosis factor-alpha (TNF-), interleukin 6 (IL-6), nuclear factor kappa beta (NF-B), inducible nitric oxide synthase (iNOS), and COX-2 inhibitors (COX2) (Feng *et al.*, 2016; Huang *et al.*, 2013; Ji *et al.*, 2017; Liu *et al.*, 2018). Therapy with D-galactose significantly increased the expression levels of apoptotic proteins in liver tissues when compared to the control group, including B-cell lymphoma-2-associated X protein, procaspase-3, caspase-3, and the ratio of B-cell lymphoma-2 to B cell lymphoma2-associated X protein (Chen *et al.*, 2018; Gao *et al.*, 2018; Shahroudi *et al.*, 2017; Xu *et al.*, 2016). Furthermore, when compared to the control group, the liver index of the D-galactose-treated mice was significantly lower (Gao *et al.*, 2018; Liu *et al.*, 2019). Reduced liver index translates to a lower liver coefficient, which is the result of the D-galactose treatment. Treatment with D-galactose can harm the liver structurally and histologically. The hepatocyte arrangement was shown to be chaotic in D-galactose-treated mice, whereas the hepatic cords were organized loosely with sinusoid dilatation (Liu *et al.*, 2019; Huang *et al.*, 2013). Pathological damage to the hepatocytes included an increase in intercellular space and ballooning degeneration (Lin *et al.*, 2018; Wang *et al.*, 2018; Zhuang *et al.*, 2017). The sizes of the cell nuclei in the liver varied, and some were dissolved (Liu *et al.*,

2019). The hepatocytes showed swelling, the cytoplasm was vacuolar and loose, the central veins congestive and dilated, and parts of the hepatocytes showed eosinophilic changes (Gao *et al.*, 2018). The swollen hepatocytes led to the intrusion of lymphocytes and inflammatory cells (Chen *et al.*, 2018; Gao *et al.*, 2018; Ji *et al.*, 2017; Liu *et al.*, 2019; Taghipour *et al.*, 2019; Zhuang *et al.*, 2017). Necrosis, pyknosis, fibrosis, central vein congestion, fat deposit, and apoptosis other damages were also seen in the hepatocytes. (Chen *et al.*, 2018; Feng *et al.*, 2016; Huang *et al.*, 2013; Ji *et al.*, 2017; Liu *et al.*, 2019; Taghipour *et al.*, 2019; Zhuang *et al.*, 2017). Some of the histomorphological damages observed in the livers of D-galactose-treated rats were similar to those observed in the naturally aged control. The livers of the D-galactose-treated rats showed some different other changes and an expression in hepatic-gal protein increased (Huang *et al.*, 2013; Wang *et al.*, 2018). D-galactose-treated animals had lower glycogen levels and greater lipid accumulation in their livers than the control animals (Wang *et al.*, 2018). All of these previous studies support our findings that the D-galactose-treated group's liver tissue suffers from fatty degeneration and necrosis. And the use of atorvastatin at doses of 10, 20, and 40 mg per kg in combination with Dgalactose reduces these histological lesions. Another study by Mustafa & Abdullah (2019) found that atorvastatin caused focal lymphocyte accumulation and cytoplasmic vacuolization in the liver of male albino rats.

V. Conclusions

The current study concludes the following: D-galactose and atorvastatin at toxic doses raise liver biomarkers like AST, ALT, and bilirubin. Hepatotoxicity can be reduced by taking atorvastatin at doses of 10, 20, and 40 mg per kg of body weight. D-galactose and atorvastatin at 150 mg per kg body weight induce histological changes in the liver. The most effective and potent dose of atorvastatin to alleviate Hepatotoxicity is 20 mg per kg.

References

- Abed Al-kareem Z., Kadhim S., H Naser I. H., (2020), A Comparative Study between Atorvastatin and Pitavastatin Toxicity on Liver and Kidney in Albino Rats. *Systematic Reviews in Pharmacy*; 11(10): 1224-1227. <https://doi.org/10.31838/srp.2020.10.175>
- Astegiano, M., Sapone, N., Demarchi, B., Rossetti, S., Bonardi, R., Rizzetto, M., (2004). Laboratory evaluation of the patient with liver disease. *Eur. Rev. Med. Pharmacol. Sci.* 8, 3–9.
- Badibostan, H., Mehri, S., Mohammadi, E., & Hosseinzadeh, H. (2019). Protective effect of thymoquinone on D-galactose-induced aging in mice. *Jundishapur Journal of Natural Pharmaceutical Products*, 14(1), 14–23. <https://doi.org/10.5812/jjnpp.13911>
- Bhardwaj, S. S., & Chalasani, N. (2007). Lipid-Lowering Agents That Cause Drug-Induced Hepatotoxicity. *Clinics in Liver Disease*, 11(3), 597–613. <https://doi.org/10.1016/j.cld.2007.06.010>
- Boland, B. S., Dong, M. H., Bettencourt, R., Barrett-Connor, E., & Loomba, R. (2014). Association of Serum Bilirubin with Aging and Mortality. *Journal of Clinical and Experimental Hepatology*, 4(1), 1–7. <https://doi.org/10.1016/j.jceh.2014.01.003>

- Chen H-I, Wang C-H, Kuo Y-W, Tsai C-H (2011) Antioxidative and hepatoprotective effects of fructo-oligosaccharide in D-galactose-treated Balb/cJ mice. *Brit J Nutr* 105:805–809. <https://doi.org/10.1017/s000711451000437x>.
- Chen, P., Chen, F., & Zhou, B. (2018). Antioxidative, anti-inflammatory and antiapoptotic effects of ellagic acid in liver and brain of rats treated by D-galactose. *Scientific Reports*, 8(1). <https://doi:10.1038/s41598-018197320>
- Çoban, J., Betül-Kalaz, E., Küçükgergin, C., Aydın, A. F., Doğan-Ekici, I., DoğruAbbasoğlu, S., & Uysal, M. (2014). Blueberry treatment attenuates D-galactose-induced oxidative stress and tissue damage in rat liver. *Geriatrics & Gerontology International*, 14(2), 490–497. <https://doi:10.1111/ggi.12096>
- Cray, C., Rodriguez, M., Zaias, J., & Altaian, N. H. (2009). Effects of storage temperature and time on clinical biochemical parameters from rat serum. *Journal of the American Association for Laboratory Animal Science*, 48(2), 202–204.
- Daniele Pastori; Arianna Pani; Arianna Di Rocco; Danilo Menichelli; Gianluca Gazzaniga; Alessio Farcomeni; Laura D'Erasmus; Francesco Angelico; Maria Del Ben; Francesco Baratta; (2021). Statin liver safety in non-alcoholic fatty liver disease: A systematic review and metanalysis. *British Journal of Clinical Pharmacology*. <https://doi.org/10.1111/bcp.14943>
- Einar Björnsson; Elin I. Jacobsen; Evangelos Kalaitzakis (2012). Hepatotoxicity associated with statins: Reports of idiosyncratic liver injury post-marketing. , 56(2), 0–380. <https://doi:10.1016/j.jhep.2011.07.023>
- El-Baz, F. K., Hussein, R. A., Abdel Jaleel, G. A. R., & Saleh, D. O. (2018). Astaxanthin-Rich Haematococcus pluvialis Algal Hepatic Modulation in DGalactose-Induced Aging in Rats: Role of Nrf2. *Advanced Pharmaceutical Bulletin*, 8(3), 523–528. <https://doi:10.15171/apb.2018.061>
- Feng Y et al (2016) Chlorogenic acid protects D-galactose-induced liver and kidney injury via antioxidation and antiinflammation effects in mice. *Pharm Biol* 54:1–8. <https://doi.org/10.3109/13880209.2015.1093510>
- Gao, J., Yu, Z., Jing, S., Jiang, W., Liu, C., Yu, C., ... Li, H. (2018). Protective effect of Anwulignan against D-galactose-induced hepatic injury through activating p38 MAPK–Nrf2–HO-1 pathway in mice. *Clinical Interventions in Aging*, Volume 13, 1859–1869. <https://doi:10.2147/cia.s173838>
- Gomes, A. S., Gadelha, G. G., Lima, S. J., Garcia, J. A., Medeiros, J. V. R., Havt, A., ... Souza, M. H. L. P. (2010). Gastroprotective effect of heme-oxygenase 1/biliverdin/CO pathway in ethanol-induced gastric damage in mice. *European Journal of Pharmacology*, 642(1-3), 140–145. <https://doi:10.1016/j.ejphar.2010.05.023>
- Hu, Z., Lausted, C., Yoo, H., Yan, X., Brightman, A., Chen, J., Wang, W., Bu, X., & Hood, L. (2014). Quantitative liver-specific protein fingerprint in blood: A signature for hepatotoxicity. In *Theranostics* (Vol. 4, Issue 2, pp. 215–228). <https://doi.org/10.7150/thno.7868>
- Huang CC, Chiang WD, Huang WC, Huang CY, Hsu MC, Lin WT (2013). Hepatoprotective effects of swimming exercise against D-galactose-induced senescence rat model. *Evid Based Complement Altern Med*. <https://doi.org/10.1155/2013/27543>
- Huisa, B. N., Stemer, A. B., & Zivin, J. A. (2010). Atorvastatin in stroke: A review of SPARCL and subgroup analysis. *Vascular Health and Risk Management*, 6(1), 229–236. <https://doi.org/10.2147/vhrm.s6795>

- Jabir, S. H., & Jaffat, H. S. (2018). Effects of atorvastatin drug in albino male rats. *Journal of Pharmaceutical Sciences and Research*, 10(11), 2924–2928.
- Ji M et al (2017). Comparison of naturally aging and D-galactose induced aging model in beagle dogs. *Exp Ther Med* 14:5881–5888
- Jiang, H., & Zheng, H. (2019). Efficacy and adverse reaction to different doses of atorvastatin in the treatment of type II diabetes mellitus. *Bioscience Reports*, 39(7), 1–10. <https://doi.org/10.1042/BSR20182371>
- Karahalil, Bensu; Hare, Emine; Koç, Göksel; Uslu, İrem; Şentürk, Kerem; Özkan, Yağmur (2017) .Hepatotoxicity associated with statins. *Archives of Industrial Hygiene and Toxicology*, 68(4). <https://doi:10.1515/aiht-2017-68-2994>
- Kawata, S., Yamasaki, E., Nagase, T., Inui, Y., Ito, N., Matsuda, Y., ... Matsuzawa, Y. (2001) .Effect of pravastatin on survival in patients with advanced hepatocellular carcinoma. A randomized controlled trial. *British Journal of Cancer*, 84(7), 886–891. <https://doi:10.1054/bjoc.2000.1716>
- Khidoyatova, M. R., Kayumov, U. K., Inoyatova, F. K., Fozilov, K. G., Khamidullaeva, G. A., & Eshpulatov, A. S. (2022). Clinical status of patients with coronary artery disease post COVID-19. *International Journal of Health & Medical Sciences*, 5(1), 137-144. <https://doi.org/10.21744/ijhms.v5n1.1858>
- Kong, S.-Z., Li, J.-C., Li, S.-D., Liao, M.-N., Li, C.-P., Zheng, P.-J., ... Hu, Z. (2018). Anti-Aging Effect of Chitosan Oligosaccharide on D-galactose-Induced Subacute Aging in Mice. *Marine Drugs*, 16(6), 181. <https://doi:10.3390/md16060181>
- Lei L, Ou L, Yu X (2016).The antioxidant effect of *Asparagus cochinchinensis* (Lour.) Merr. shoot in D-galactose induced mice aging model and in vitro. *J Chin Med Assoc* 79:205–211
- Li L et al (2005) Antioxidant activity of gallic acid from rose flowers in senescence accelerated mice. *Life Sci* 77:230–240. <https://doi.org/10.1016/j.lfs.2004.12.024>
- Lin X, Xia Y, Wang G, Xiong Z-Q, Zhang H, Lai F, Ai L (2018) *Lactobacillus plantarum* AR501 alleviates the oxidative stress of D-galactose-induced aging mice liver by upregulation of Nrf2-mediated antioxidant enzyme expression. *J Food Sci*.
- Liu H, Pei X, Wang J, Zhou Y, Wang L, Qi B (2018). Effect of loach paste on the liver and immune organs of D-galactoseinduced ageing mice. *Food Agric Immunol* 29:316–3
- Liu J, Chen D, Wang Z, Chen C, Ning D, Zhao S (2019). Protective effect of walnut on D-galactose-induced aging mouse model. *Food Sci Nutr* 7:969–976
- Luna, L. G., (1968). *Manual of histologic staining methods of the Armed Forces Institute of Pathology*. 3rd Edition, Mc Graw-Hill, New York.
- Mo ZZ et al (2017). Protective effect of SFE-CO₂ of *ligusticum chuanxiong* hort against D-galactose-induced injury in the mouse liver and kidney. *Rejuv Res* 20:231–243
- Mohammadi E, Mehri S, Bostan HB, Hosseinzadeh H (2018). Protective effect of crocin against D-galactose-induced aging in mice. *Avicenna J Phytomed* 8:14
- Muchova, L., Wong, R. J., Hsu, M., Morioka, I., Vitek, L., Zelenka, J., ... Stevenson, D. K. (2007). Statin treatment increases formation of carbon monoxide and bilirubin in mice: a novel mechanism of in vivo antioxidant protection. *Canadian Journal of Physiology and Pharmacology*, 85(8), 800–810. <https://doi:10.1139/y07-077>

- Mustafa T. A., Abdulah H. O., (2019). Histological Alterations Induced by Atorvastatin Therapeutic Doses in some Organs of Male Albino Rats. *Polytechnic Journal*. Vol. 9, No 1: PP13-16. Erbil Polytechnic University, Erbil, Kurdistan Region - F.R. Iraq. <https://doi:10.25156/ptj.v9n1y2019.pp13-16>
- Nam, Y., Bae, J., Jeong, J. H., Ko, S. K., & Sohn, U. D. (2017). Protective effect of ultrasonication-processed ginseng berry extract on the D-galactosamine/lipopolysaccharide-induced liver injury model in rats. *Journal of Ginseng Research*. <https://doi:10.1016/j.jgr.2017.07.007>
- Noureen S, Riaz A, Arshad M, Arshad N (2019) In vitro selection and in vivo confirmation of the antioxidant ability of *Lactobacillus brevis* MG 000874. *J Appl Microbiol* 126:1221–1232
- Panonnnummal R., Varkey J., (2014). Statins induced nephrotoxicity: a dose dependent study in albino rats. *Int J Pharm Pharm Sci* 6 (11), 401.406 -
- Reddy, A. Gopala; Rao, G. Srinivasa; Haritha, C.; Jyothi, K.; Reddy, G. Dilip, (2010). Interaction study on garlic and atorvastatin with reference to nephrotoxicity in dyslipidaemic rats. *Toxicology International*, 17(2), 90–93. <https://doi:10.4103/0971-6580.72678>
- Roller, J., Laschke, M. W., Scheuer, C., & Menger, M. D. (2010). Heme oxygenase (HO)-1 protects from lipopolysaccharide (LPS)-mediated liver injury by inhibition of hepatic leukocyte accumulation and improvement of microvascular perfusion. *Langenbeck's Archives of Surgery*, 395(4), 387–394. <https://doi:10.1007/s00423-010-0603-8>
- Sahebkar, A., Rathouska, J., Simental-Mendía, L. E., & Nachtigal, P. (2016). Statin therapy and plasma cortisol concentrations: A systematic review and metaanalysis of randomized placebo-controlled trials. *Pharmacological Research*, 103, 17–25. <https://doi.org/10.1016/j.phrs.2015.10.013>
- Saleh, D. O., Mansour, D. F., Hashad, I. M., & Bakeer, R. M. (2019). Effects of sulforaphane on D-galactose-induced liver aging in rats: Role of keap-1/nrf-2 pathway. *European Journal of Pharmacology*. <https://doi:10.1016/j.ejphar.2019.04.043>
- Salman A. H. (2021). Evaluation the role of vitamin D3 on some physiological and histopathological in liver fibrosis induced in male rats. MSc. thesis. biological dep. Sciences College Basrah University.
- Shahroudi MJ, Mehri S, Hosseinzadeh H. (2017). Anti-aging effect of *Nigella sativa* fixed oil on D-galactose-induced aging in mice. *J Pharmacopunct* 20:29
- Suryasa, I. W., Rodríguez-Gámez, M., & Koldoris, T. (2021). Get vaccinated when it is your turn and follow the local guidelines. *International Journal of Health Sciences*, 5(3), x-xv. <https://doi.org/10.53730/ijhs.v5n3.2938>
- Taghipour, Z., Kaviani, E., Kaeidi, A., Shamsizadeh, A., Hassanshahi, J., & Fatemi, I. (2019). Atorvastatin attenuates D-galactose-induced hepatorenal toxicity in mice: An experimental study with histopathological evaluations. *Physiology and Pharmacology (Iran)*, 23(1), 36–43.
- Wang H et al. (2018) Inorganic nitrate alleviates the senescence-related decline in liver function. *Sci China Life Sci*. <https://doi.org/10.1007/s11427-017-9207-x>
- Ward, N. C., Watts, G. F., & Eckel, R. H. (2019). Statin Toxicity: Mechanistic Insights and Clinical Implications. *Circulation Research*, 124(2), 328–350. <https://doi.org/10.1161/CIRCRESAHA.118.312782>
- Xu LQ et al (2016). Polydatin attenuates D-galactose-induced liver and brain damage through its anti-oxidative, anti-inflammatory and anti-apoptotic effects in mice. *Food Funct*. <https://doi.org/10.1039/c6fo01057a>

- Yang J, He Y, Zou J, Xu L, Fan F, Ge Z (2019). Effect of Polygonum Multiflorum Thunb on liver fatty acid content in aging mice induced by D-galactose. *Lipids Health Dis* 18:128.
- Zhuang Y, Ma Q, Guo Y, Sun L (2017) Protective effects of rambutan (*Nephelium lappaceum*) peel phenolics on H₂O₂-induced oxidative damages in HepG2 cells and Dgalactose-induced aging mice. *Food Chem Toxicol* 108:554– 562.