

How to Cite:

Kumar, M. N., Begum, B. S., & Iniya, R. (2022). A prospective randomized comparative study on erector spinae plane block and serratus anterior plane block in the postoperative pain management after breast surgeries. *International Journal of Health Sciences*, 6(S6), 1249–1256. <https://doi.org/10.53730/ijhs.v6nS6.10550>

A prospective randomized comparative study on erector spinae plane block and serratus anterior plane block in the postoperative pain management after breast surgeries

Dr. M. Nanda Kumar

Department of Anaesthesiology, K.A.P.V. Govt. Medical College, Trichy

Dr. B. Shakila Begum

Department of Anaesthesiology, Vinayaka Mission's Medical College and Hospital, Vinayaka Mission's Research Foundation (Deemed to be university)

Dr. R. Iniya*

*Corresponding author

Abstract---Erector spinae plane (ESP) block and serratus anterior plane (SAP) block promise effective thoracic analgesia compared with systemically administered opioids, but have never been compared in terms of terms of quality of recovery and overall morbidity after breast surgeries. Hence the present study designed to compare the efficacy and safety of the erector spinae plane block and serratus anterior plane block in the post-operative pain management in terms of duration of analgesia, time to 1st rescue analgesic, and incidence of PONV and patients satisfaction. The results proposed strongly that these are an alternative to other regional anaesthetic techniques with comparatively low or nil side effects. There is no incidence of post-operative nausea, vomiting and also not reported any pneumothorax.

Keywords---erector spinae plane block, serratus anterior plane block, PONV and patients satisfaction.

Introduction

Breast surgeries are common operative procedures, and Breast surgery results in increased incidence of acute and also chronic pain in 25–60% of patients, in which 55% of post mastectomy patients experience chronic pain persisting for months to years. There are many techniques existing for control of Perioperative

pain in breast surgery patients, including several novel regional anaesthesia techniques [1].

Regional anaesthesia techniques may provide better postoperative analgesia for patients undergoing breast surgery. The Erector spinae plane block (ESPB) is an interfascial plane block first described in 2016 by Forero et al as an effective treatment method for the treatment of thoracic neuropathic pain. Studies published thereafter have however concentrated on the use of ESPB for perioperative or postoperative analgesia. The first bilateral ESPB, described for postoperative analgesia in Laparoscopic ventral hernia surgery, was also reported from the same centre where ESPB was originally described [2].

The initial clinical findings suggested that ESPB injectant would spread to both the dorsal and ventral ramus of the spinal nerves, leading to blockage of both somatic and visceral pain, a effect similar to epidural analgesia [3].

During the evaluation of the block, it was used for post-operative analgesia for breast surgeries with good results [4, 5, 6]. Based on the above information an effort has been made to conduct a prospective randomised comparative study in where the patients undergoing breast surgeries under general anaesthesia were given USG guided Serratus Anterior Plane block (SAP) and Erector spinae plane block (ESPB) at the end of surgery and before extubation was done.

Method

Materials and Methods

Basic parameters of the study

A total number of 60 patients were scheduled for study. A written and informed consent was taken from all the patients or their relatives .A Complete pre anaesthetic evaluation was done on the day of surgery before procedure with investigations Haemoglobin, Random Blood sugar , Blood Urea, Serum Creatinine, Serum electrolytes, Chest X-ray, Electrocardiogram and other investigations were obtained on the basis of the condition of the patient .

Patient were kept Nil Per Oral for 10 hrs. 18 G I.V cannula secured in Pre - anaesthetic room All patients were premedicated with inj.Ranitidine 50mg iv, inj.Metaclpromide 10mg iv, 30 mins before in the preanaesthetic room, patient were shifted into the operation theatre. After positioning, monitors were connected and base line Heart rate,Spo2, NIBP, ECG,R espiratory rate were recorded, Inj.Glycopyrrolate 0.2mg iv, inj.midazolam 1mg iv and preoxygenation was given with a standard analgesic dose of inj.

Fentanyl 100mcg iv and patient was induced with inj. propofol 2 mg/kg, follwed by muscle relaxant inj.succinylcholine 2 mg/kg and intubated with appropriate size ET tube and prompt volatile anaesthetic, N2O, O2 will be given for maintenance of anaesthesia [7].

Monitoring of vital signs was instituted, that include Pulse oximetry, automated non-invasive blood pressure, ECG, Respiratory rate, ETCO2, and Heart rate throughout the procedure.

At the end of the surgery, before extubation the randomly allocated patient under the two groups received Serratus anterior plane block or Erector spinae plane block under ultrasound guidance (with a linear ultrasound transducer 10–12 MHz).

For SAP block the patient were placed in supine or lateral position (based upon convenience) the probe were placed over the mid-clavicular region in the thoracic cage, we identified the 2nd rib below the axillary artery & vein and the ribs were counted with the probe directed infer laterally till we identified the fifth rib in mid axillary line. The important muscles latissimus dorsi and serratus muscles were identified by ultrasound guidance at the level of fifth rib. An additional reference point we used the thoraco dorsal artery which help us to identify the plane superficial to the serratus muscle.

The block performed with 18-G needle introduced in-plane with the ultrasound probe as antero-posterior or postero-anterior direction after skin infiltration with 1% lignocaine 3 ml, the plane were identified and the needle placed superficial to the serratus anterior muscle or between the serratus anterior and latissimusdorsi and local anaesthetic (LA) 0.25% inj. bupivacaine

After procedure sterile dressing was done. Neuromuscular blockade was reversed and patient extubated and shifted to the post anaesthesia care unit. Before induction of anaesthesia, patients were explained how to use a Numerical pain Rating Scale (NPRS—0 with end-point labelled no pain to 10 worst conceivable pain) [8].

Primary outcome

The degree of postoperative pain assessed at 0, 2, 6, 12, 18h using the NPRS score.

Secondary outcome

1. Rate of patient tolerability to the procedure and overall pain satisfaction of patients follows. Satisfaction scores recorded on a 10-point scale, with zero being very unsatisfied and 10 being completely satisfied.
2. Time of rescue analgesic administered if NPRS score more than 4.

Statistical analysis

Statistical analysis was done using SPSS software version 17.0. If the P value is 0.000 to 0.010, it implies highly significant. If the P value is 0.011 to 0.050, it implies significant. If the P value is 0.051 to 1.000 it implies Not Significant [9].

Results

Demographic data

The two groups in our study were comparable in respect to their age, weight and height. There was no statistical difference between them.

Table 1. Age comparison among the group E and S

	Group	N	Mean	Standard Deviation	P value
Age in years	E	30	37.76	14.68	0.785
	S	30	36.63	14.57	

According to the above table, In Group E, the mean age was 37.76 ± 14.68 . In Group S, the mean age was 36.63 ± 14.57 . P value=0.785. The p values here are greater than 0.05, so the difference between age among two groups are not significant.

Weight comparison among the group E and S

	Group	N	Mean	Standard deviation	P value
Wt in kg	E	30	53	9.769	0.807
	S	30	53.5	5.393	

According to the above table, In Group E, the mean weight was 53 ± 9.769 , In Group S, the mean weight was 53.5 ± 5.393 , P value=0.807. The p values here are greater than 0.05, so the difference between weight among two groups are not significant.

Heart Rate comparison between group E and S

The mean values of pre op heart rate in the Group E and Group S were 79.26 ± 5.50 and 79.7 ± 6.53 respectively and P value 0.782 is statistically non-significant. The mean values of at the end of surgery heart rate in the Group E and Group S were 77.6 ± 6.13 and 78.2 ± 7.024 respectively and P value 0.755 is statistically non-significant. The mean values of 2nd hr post-operative heart rate in the Group E and Group S were 76.83 ± 4.480 and 78.23 ± 3.500 respectively and P value 0.183 is statistically non-significant. The mean values of 6th hr post-operative heart rate in the Group E and Group S were 77.76 ± 5.562 and 77.43 ± 4.272 respectively and P value 0.604 is statistically non-significant.

The mean values of 12th hr post-operative heart rate in the Group E and Group S were 77.96 ± 5.142 and 78.5 ± 6.468 respectively and P value 0.725 is statistically non-significant. The mean values of 18th hr post-operative heart rate in the Group E and Group S were 80.43 ± 7.80 and 82.3 ± 12.714 respectively and P value 0.796 is statistically non-significant. The Heart rate at various intervals after the surgery during the study is comparable as there is no statistically significant difference between two groups, the p values being >0.05 at all intervals.

Comparison of Numeric pain rating scale (NPRS) among the group E and S

The mean values of 2nd hr postoperative NPRS in the Group E and Group S were 1.3 ± 0.987 and 1.33 ± 0.922 respectively .and P value 0.893 is statistically non-significant. The mean values of 6th hr. postoperative NPRS in the Group E and Group S were 2.966 ± 0.9278 and 3.633 ± 1.159 respectively and P value 0.017 is statistically significant. The mean values of 12th hr postoperative NPRS in the Group E and Group S were 4.75 ± 1.165 and 6 ± 0.8717 respectively and P value 0.0417 is statistically significant. The mean values of 18th hr postoperative NPRS in the Group E and Group S were 5 ± 0.8366 and 7 ± 0.836 respectively and P value 0.007 is statistically significant. The NPRS score at 6, 12, 18 hr had P value <0.05 . In that Group E had significantly lower NPRS score than Group S.

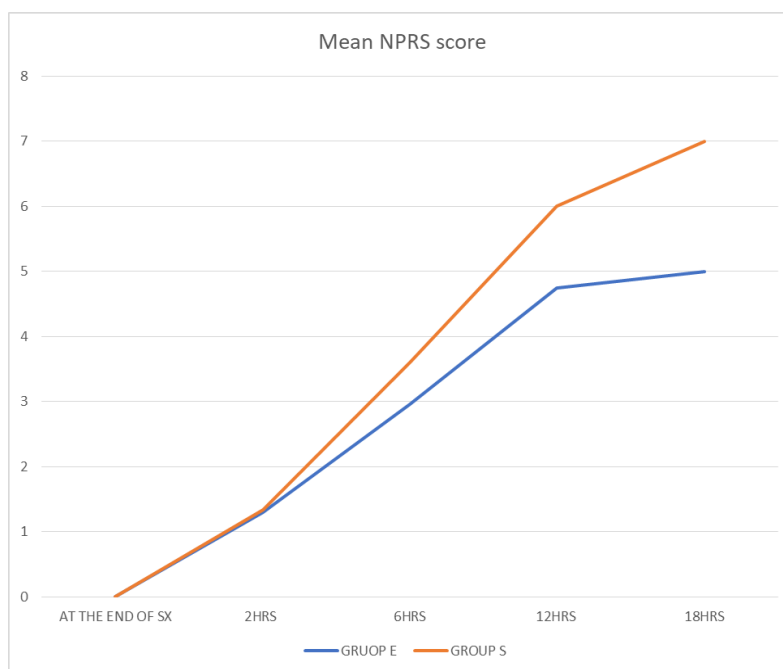


Figure – The mean NPRS score

Comparison of patient satisfaction score among the group E and S

	Group	N	Mean	Standard deviation	P value
Score	E	30	7.7	0.915	<0.0001
	S	30	6.533	0.681	

According to the above table, In Group E, the mean patient satisfaction score was 7.7 ± 0.915 . In Group S, the mean patient satisfaction score was 6.533 ± 0.681 . P value <0.0001 . The p values here are less than 0.05, so the difference between patient satisfactions among two groups are statistically significant.

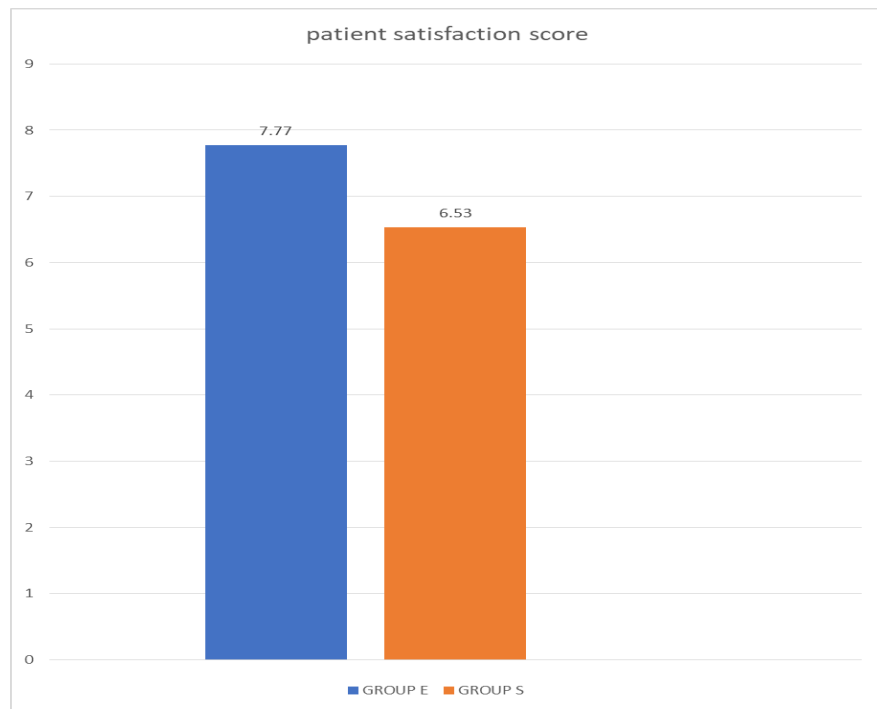


Figure – patient satisfaction score

Discussion

We have shown that injection of local anaesthetic into the fascial plane between serratus anterior muscle & Latissimus Dorsi muscle (SAP block) and Erector Spinae muscle & T5 transverse process (ESP block) provides predictable and relatively long-lasting pain relief, which would be better post-operative analgesic technique for surgical procedures performed on the breast [10,11]. We propose strongly that these are an alternative to other regional anaesthetic techniques with comparatively low or nil side effects. There is no incidence of post-operative nausea, vomiting and also not reported any pneumothorax [12].

The choice of regional anaesthetic technique will of course vary depending on practitioners and patients preferences, comorbidities and type of surgery. Possible techniques include: local wound infiltration (with or without wound catheter insertion). Pecs I and II blocks. Selective intercostal nerve blockade, thoracic paravertebral blockade, and thoracic epidural analgesia. Each of these techniques has advantages and disadvantages [13].

In general, local or wound infiltration was considered safe but limited in terms of duration of action, depending on the pharmacodynamics of the local anaesthetic agent used. More invasive techniques such as selective intercostal nerve blocks and thoracic paravertebral blockade are technically difficult when compared to USG guided interfascial plane blocks and may lead to pneumothorax or transient Horner's syndrome. These techniques have been shown to be associated with rapid rise in plasma concentrations of the local anaesthetic agents injected. In

addition, the central Neurological side-effect profiles associated with neuraxial blockade have been well documented precluding their routine use in the setting of day-care surgery.

Conclusion

Our results concluded that in post mastectomy patients, Erector spinae plane block and Serratus Anterior plane block, both provide effective analgesia to the post mastectomy patients. But when compared between these two blocks, Erector spinae plane block provides more effective and long duration of pain relief with good patient satisfaction score when compared with serratus Anterior plane block. Both blocks are similarly effective in reducing postoperative pain with lower incidence of complications (such as pneumothorax and postoperative nausea & vomiting) with less opioid consumption. And comparatively Erector spinae plane block was easier and less time consumes during perform than Serratus Anterior plane block. These newer findings are important to inform both current clinical practices needs still further future prospective randomized control studies in large patient population in order to support the results.

Conflict of interest

Authors do not have any conflict of interest.

References

1. Anuj Gupta,1,* Kirtipal Kaur,1 Sheeshpal Sharma,1 Shubham Goyal,2 Saahil Arora,1 and R.S.R Murthy1. CLINICAL ASPECTS OF ACUTE POST-OPERATIVE PAIN MANAGEMENT & ITS ASSESSMENT. *J Adv Pharm Technol Res.* 2010 Apr-Jun; 1(2): 97–108.
2. Auroy, Y., Narchi, P., Messiah, A., Litt, L., Rouvier, B., Samii, K. (1997). Serious complications related to regional anesthesia: results of a prospective survey in France. *Anesthesiology*, 87(3), 479–486.
3. Bonvicini D, Tagliapietra L, Giacomazzi A, Pizzirani E. Bilateral ultrasound-guided erector spinae plane blocks in breast cancer and reconstruction surgery. *J Clin Anesth* 2018;44:3-4.
4. Esther M. Pogatzki-Zahn, Daniel Segelcke, and Stephan A. Schug Postoperative pain—from mechanisms to treatment. *Pain Rep.* 2017 Mar; 2(2): e588
5. Gürkan Y, Aksu C, Kuş A, Yörükoğlu UH, Kılıç CT. Ultrasound guided erector spinae plane block reduces postoperative opioid consumption following breast surgery: A randomized controlled study. *J Clin Anesth* 2018;50:65-8.
6. Ivanusic, J, Konishi, Y, Barrington, MJ. A cadaveric study investigating the mechanism of action of erector spinae blockade. *Reg Anesth Pain Med* 2018;43:567-71.
7. Jesse Musokota Mumba, Freddy Kasandji Kabambi, Christian, Tshebeletso Ngaka Pharmacology of Local Anaesthetics and Commonly Used Recipes in Clinical Practice, DOI: 10.5772/67048
8. Khidoyatova, M. R., Kayumov, U. K., Inoyatova, F. K., Fozilov, K. G., Khamidullaeva, G. A., & Eshpulatov, A. S. (2022). Clinical status of patients with coronary artery disease post COVID-19. *International Journal of Health & Medical Sciences*, 5(1), 137-144. <https://doi.org/10.21744/ijhms.v5n1.1858>

9. Miller, Ronald D. *Miller's Anesthesia*. 7th ed. Philadelphia, PA: Churchill Livingstone/Elsevier, 2010. Vol. 1. pp 913-940. Ch. 30. ISBN: 978-0-4430-6959-8
10. Nair AS, Seelam S, Naik V, Rayani BK. Opioid- free mastectomy in combination with ultrasound – Guided erector spinae block: A series of five cases. *Indian J Anaesth* 2018;62:632-4.
11. Nouette-Gaulain, K., Capdevila, X., Rossignol, R. (2012). Local anesthetic 'in-situ' toxicity during peripheral nerve blocks: update on mechanisms and prevention. *Current Opinion in Anesthesiology*, 25(5), 589–595.
12. Ohgoshi Y, Ikeda T, Kurahashi K. Continuous erector spinae plane block provides effective perioperative analgesia for breast reconstruction using tissue expanders: A report of two cases. *J Clin Anesth* 2018;44:1-2.
13. Oksuz G, Bilgen F, Arslan M, Duman Y, Urfalioglu A, Bilal B. Ultrasound guided bilateral erector spinae block versus tumescent anesthesia for postoperative analgesia in patients undergoing reduction mammoplasty: A randomized controlled study. *Aesth Plast Surg* 2019;43:291-6.
14. Singh S, Kumar G, Akhileshwar. Ultrasound-guided erector spinae plane block for postoperative analgesia in modified radical mastectomy: A randomised control study. *Indian J Anaesth* 2019;63:200-4.
15. Suryasa, I. W., Rodríguez-Gámez, M., & Koldoris, T. (2021). The COVID-19 pandemic. *International Journal of Health Sciences*, 5(2), vi-ix. <https://doi.org/10.53730/ijhs.v5n2.2937>
16. Yuriah, S., Kartini, F., & Isnaeni, Y. (2022). Experiences of women with preeclampsia. *International Journal of Health & Medical Sciences*, 5(3), 201-210. <https://doi.org/10.21744/ijhms.v5n3.1901>