

How to Cite:

Mazumder, A., Das, S., Atri, A., Singh, K., & Singh, M. (2022). Immune thrombocytopenia: An updated review from etiopathophysiology, laboratory investigations and current therapy. *International Journal of Health Sciences*, 6(S5), 8499–8526. <https://doi.org/10.53730/ijhs.v6nS5.10626>

Immune thrombocytopenia: An updated review from etiopathophysiology, laboratory investigations and current therapy

Dr. Avijit Mazumder

Director & Professor, Noida Institute of Engineering & Technology (Pharmacy Institute), Greater Noida

Email: avijitmazum@yahoo.com

ORCID - 0000-0002-3053-8106

Dr. Saumya Das

Associate Professor, Noida Institute of Engineering & Technology (Pharmacy Institute), Greater Noida

Corresponding author email: awasthi.saumya22@gmail.com

ORCID – 0000-0002-8531-9963

Ayush Atri

Master of Pharmacy (Persuing) from Noida Institute of Engineering & Technology (Pharmacy Institute), Greater Noida, Bachelor Of Pharmacy, Raj Kumar Goel Institute Of Technology, Ghaziabad

Email: ayushatri06@gmail.com

ORCID 0000-0003-4499-6869

Komal Singh

Master of Pharmacy (Persuing) from Noida Institute of Engineering & Technology (Pharmacy Institute), Greater Noida, Bachelor Of Pharmacy, Raj Kumar Goel Institute Of Technology, Ghaziabad

Email: komalsinghgahlot440@gmail.com

ORCID- 0000-0001-7807-0357

Madhvi Singh

Master of Pharmacy (Persuing) from Noida Institute of Engineering & Technology (Pharmacy Institute), Greater Noida, Bachelor Of Pharmacy, Brahmanand Group Of Institutions, Bulandshahr

Email: madhvithakur12599@gmail.com

ORCID- 0000-0003-1396-7731

Abstract---An inherited condition with isolated thrombocytopenia, immune thrombocytopenia (ITP) is still unknown in terms of the cause. A primary or secondary ITP diagnosis is determined by whether or not an underlying treatable cause exists. Diagnosis of primary ITP

is based on the exclusion and hence does not have a gold standard test to validate it. Before classifying a patient as primary ITP, recent medication use, infections, lymphoproliferative illnesses, and connective tissue disorders should be checked out. An in-depth look at the most recent developments in ITP diagnostics and treatment is provided in this study. Our research was supported by GOOGLE Scholar, PUBMED, and ClinicalTrial.gov databases. Idiopathic thrombocytopenic purpura was also included in the search, as was "immune-mediated thrombocytopenia," "idiopathic thrombocytopenic purpura," and "isolated thrombocytopenia." It was found that more research is needed to better understand the underlying mechanisms of ITP. For example, corticosteroids have both short- and long-term side effects when used in the first place. In light of this, future research may need a rethinking of ITP treatment recommendations and the use of viable alternative drugs.

Keywords---Isolated Thrombocytopenia, Diagnosis, primary, immune-mediated.

Introduction

Immune thrombocytopenia (ITP) is an acquired autoimmune disorder that is characterized by an isolated low platelet count of less than $100 \times 10^9/L$ 2). Although the exact pathogenesis is unknown, it is believed to result from autoimmune destruction of platelets due to the formation of antiplatelet autoantibodies and decreased platelet production arising from defective megakaryopoiesis. As per the literature, both B- and T-cell immune responses play important role in ITP pathogenesis (Yuan *et al.*, 2019). Depending upon the underlying cause, ITP can be classified into two subtypes – primary ITP (when no secondary cause is found) and secondary ITP when there is an underlying disorder that is linked with autoimmune destruction of platelets. The latter includes infections (Human immunodeficiency virus infection (HIV), Hepatitis C (HCV), and *Helicobacter pylori*), autoimmune diseases (like systemic lupus erythematosus (SLE), rheumatoid arthritis (RA), antiphospholipid antibody syndrome (APS)), and lymphoproliferative disorders like chronic lymphocytic leukemia (CLL) (Cines *et al.*, 2009; Liebman, 2009). Most of the studies from developed countries have shown that 80% of cases of ITP are primary and the remaining 20% constitute secondary ITP. However, studies from developing countries suggest that secondary ITP is more common than primary (Kado & McCune, 2019; Sultan *et al.*, 2016). This heterogeneity may be due to geographical variation and a higher incidence of infections in developing countries.

According to the time duration of diagnosis, ITP can be divided into three phases: newly diagnosed (0–3 months), persistent (>3 months to 12 months), and chronic phase (>12 months) (Rodeghiero *et al.*, 2009). American society of hematology (ASH) and International Consensus have updated their guidelines in 2019 based on recent advances in ITP management (Neunert *et al.*, 2019; Provan *et al.*, 2019).

This review aims to summarize the contemporarily recommended diagnostic approach toward ITP and review the presently available treatment options.

Investigations in the clinic and laboratory to rule out other possible pathophysiological explanations for ITP

ITP is a diagnosis of exclusion and there is no gold standard test for its confirmation. Response to ITP-specific drugs (like corticosteroids and intravenous immune globulin (IVIG)) may support the diagnosis but does not fully exclude another disease with thrombocytopenia (Neunert *et al.*, 2019; Audia *et al.*, 2017). A detailed history, physical examination, and peripheral blood smear assessment by an experienced hematopathologist are crucial to diagnosing ITP. Apart from ITP, many other blood disorders can present with isolated thrombocytopenia (Provan *et al.*, 2019)

History and Physical Examination

A detailed history of bleeding manifestations (especially menorrhagia in females), the severity of bleeding, prior blood transfusion, and any recent drug intake is essential. The severity of bleeding is graded with standard scales like the ITP Bleeding Scale (IBLS), ITP-specific Bleeding Assessment Tool (ITP-BAT), and WHO bleeding Scale. Although more precise, the clinical applicability of ITP-BAT is difficult in day-to-day practice due to the complexity of this scale. Contrarily, the WHO bleeding scale is simple to use and is validated for use in ITP patients (Rodeghiero *et al.*, 2013; Fogarty *et al.*, 2012). A family history of thrombocytopenia should be inquired to rule out familial thrombocytopenia. Many such patients with familial thrombocytopenia also have associated physical abnormalities and mental retardation. History of alcohol consumption, toxin exposure, and jaundice should be documented to rule out underlying chronic liver disease (Neunert *et al.*, 2019; Provan *et al.*, 2010; Bastida *et al.*, 2019). Physical examination is crucial to diagnose specific disorders which can present with isolated thrombocytopenia (secondary ITP). Wet purpura may be the only sign of underlying thrombocytopenia (Mishra *et al.*, 2017). Pallor may be present due to underlying anemia caused by blood loss. Jaundice may suggest underlying chronic liver disease or autoimmune hemolytic anemia (Evans syndrome). The presence of lymphadenopathy, hepatosplenomegaly may be suggestive of lymphoproliferative disorders or acute leukemia (Neunert *et al.*, 2019; Provan *et al.*, 2019).

Laboratory Investigations

Isolated thrombocytopenia is the most common finding on routine hemograms in ITP patients. In addition, anemia may be present which is usually proportional to the magnitude of bleeding. If anemia is out of proportion to bleeding severity, other causes like nutritional deficiency should be ruled out. RBC indices (mean corpuscular volume (MCV) and red cell distribution width (RDW)) may provide clues regarding anemia arising from nutritional deficiency (vitamin B12, folic acid, and/or iron deficiency). Megaloblastic anemia can also present with thrombocytopenia. Peripheral blood smear should be checked by an expert pathologist (Ren *et al.*, 2003; Tseng *et al.*, 2014). Apart from isolated

thrombocytopenia, it generally shows no abnormality except large or giant platelets which may sometimes be found. Abnormalities on peripheral blood smear examination may help to diagnose other conditions inconsistent with ITP; like schistocytes in microangiopathic hemolytic anemia (MAHA), leukocyte inclusion bodies in myosin heavy chain 9-related disease (MYH-9), and blasts in acute leukemias (Wongrakpanich *et al.*, 2016; Balduini *et al.*, 2011; Hamad *et al.*, 2020). Liver function tests and renal function tests should be routinely performed. Abnormal liver functions may be present in chronic liver disease. Lactate dehydrogenase (LDH) and serum haptoglobin may be done if there is suspicion of concomitant hemolysis.

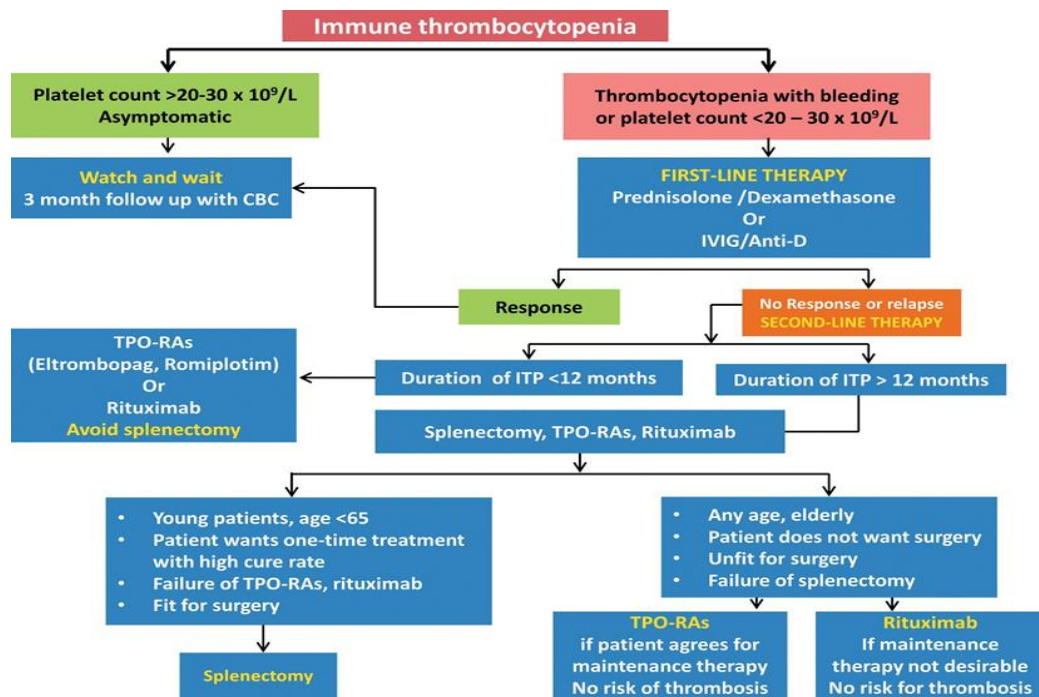


Fig.1- Approach to thrombocytopenia

Tests to rule out secondary ITP

Once the diagnosis of ITP has been established, the next step is to differentiate between primary and secondary ITP. Guidelines suggest that certain basic investigations should be performed in all ITP patients and consideration for additional investigations should be guided by geographical region.

Anti-nuclear antibodies (ANA)

A positive antinuclear antibody (ANA) test can be seen in 33% of adult primary ITP patients and it portends an increased risk of chronicity (Altintas *et al.*, 2007; Moulis *et al.*, 2020). Most of the guidelines do not advise routine ANA testing, and it should ideally be considered if the clinical picture suggests underlying connective tissue disorder-like SLE (Neunert *et al.*, 2019; Neunert & Cooper,

2018). In Asian countries, as the prevalence of SLE is high, ANA testing should be routinely performed in every patient with isolated thrombocytopenia (Heng *et al.*, 2011).

H. pylori testing

Urea breath test or the stool antigen test can be performed to detect *H. pylori* infection in ITP patients who present with dyspeptic symptoms, especially in countries where there is a high prevalence of *H. pylori*. Some studies have shown improvement in platelet count among ITP patients after *H. pylori*-specific treatment (Sheema *et al.*, 2017; Frdman *et al.*, 2015).

HIV, HCV, and HBV

HIV and HCV infections are well-established causes of secondary ITP. Thrombocytopenia can be present for several years before the onset of symptoms due to the basic disease. Treatment of underlying viral infection corrects thrombocytopenia in a significant proportion of such patients (Varma *et al.*, 2011; Franchini *et al.*, 2017). Hence, routine testing of HIV and HCV is performed in all ITP patients. Testing for hepatitis B virus (HBV) can be done in the regions with its high prevalence and before rituximab therapy (Joo *et al.*, 2017).

Bone marrow examination

Routine bone marrow investigation in a typical instance of ITP is not indicated. It can be considered if there is an uncertainty in clinical diagnosis, before splenectomy, or before commencing a new therapy. If completed, a bone marrow sample should be submitted for flow cytometry, and cytogenetic analysis to rule out lymphoproliferative diseases, myelodysplastic syndrome, and other primary bone marrow illnesses. A typical bone marrow aspirate of an ITP patient displays megakaryocyte hyperplasia with normocellular marrow (Tang *et al.*, 2017; Ahmad *et al.*, 2017).

Ancillary Investigations (Case-To-Case Basis)

Direct anti-globulin test (DAT)

One study revealed that up to 20% of ITP patients can have DAT positivity without evidence of hemolysis. However, in routine clinical practice, DAT testing is not advised. It must be performed in ITP patients with clinical or laboratory evidence of hemolysis, and before the use of anti-D therapy (Salama *et al.*, 1984).

Quantification of immunoglobulin levels

Routine assessment of immunoglobulin profile is not advised. However, it is indicated when the index of suspicion for an underlying primary immunodeficiency disorder is high, and it should be done before intravenous immunoglobulin therapy.

Blood group and Rh (D) typing

It must be performed before anti-D therapy (Salama *et al.*, 1984).

Coagulogram

It can be assessed if there is a suspicion of underlying disseminated intravascular coagulopathy (DIC), especially in hospitalized critically ill patients. In an outpatient setting, coagulogram testing has no role.

Anti-platelet antibodies

Anti-platelet antibodies to surface glycoproteins are observed in 50–60% of ITP patients. Testing for these antibodies has no role in routine clinical practice (McMillan, 2003). Old ELISA-based tests with low sensitivity and high specificity can be used in difficult cases to support the diagnosis of ITP. Newer techniques using glycoprotein-specific assays have better sensitivity and may be useful to guide ITP treatment in the future (McMillan, 2009; chan *et al.*, 2003; Sahu *et al.*, 2020).

Anti-phospholipid antibodies

Anti-phospholipid antibodies (ACA) and lupus anticoagulant (LA) have been found in 25 to 46 percent of individuals with ITP in various investigations. Treatment with ITP is unaffected by their existence (Stasi *et al.*, 1994; Pierrot *et al.*, 2008; Yang *et al.*, 2011). In the absence of any symptoms, regular testing is thus not advised.

Thyroid function tests and anti-thyroid peroxidase (Anti-TPO)

Mild thrombocytopenia is found in both hyperthyroidism and hypothyroidism, and it improves after achieving a euthyroid state. It is not clear whether autoimmune thyroid dysfunction is the cause of thrombocytopenia in ITP or incidentally related to ITP (Marta *et al.*, 2015; Loachimescu *et al.*, 2007; Cheung & Liebman, 2009). Although anti-TPO antibodies are commonly observed in ITP patients, they do not have any prognostic significance (Giordano *et al.*, 2019). Thyroid function tests should not be performed routinely in ITP patients (Neunert *et al.*, 2019). They can be performed in patients with clinical features of thyroid disease or in geographical areas where the prevalence of thyroid disorders is high.

Thrombopoietin level

Thrombopoietin level is normal in ITP patients and should not be routinely performed. It is increased in patients with bone marrow failure syndromes.

Platelet's indices

There is no standardisation or routine recommendation for using platelet indices such as mean platelet volume, platelet distribution width, and reticulated platelets to diagnose ITP. In ITP and MDS patients, Tang *et al.* looked at the relationship between MPV and platelet count. When it comes to ITP, the platelet count has a strong correlation with MPV, but the reverse is true. (Tang *et al.*, 2017; Giordano *et al.*, 2019)

Platelet function

Platelet function assessment (Thromboelastographic (TEG), rotational thromboelastometry (ROTEM), or Sonoclot) is helpful in the diagnosis and

treatment of ITP. However, these are not routinely recommended at present (Mishra *et al.*, 2018; Mishra *et al.*, 2017).

First-Line Therapy for Itp

The goals of treatment in ITP are: i) To achieve a safe platelet count ($>30 \times 10^9/L$) to stop active bleeding and prevent future bleeding, ii) To achieve the good health-related quality of life so that patient can live a normal life, and iii) To prevent adverse effects of ITP-specific therapy.

Glucocorticoids

Patients with acute ITP are often treated with glucocorticoids. Steroids' mode of action is still a mystery. Antibody-producing lymphocytes may be inhibited, as well as macrophages, which are responsible for platelet phagocytosis, by steroids.(Provan *et al.*, 2019; Mizutani *et al.*, 1992) Most common regimen is oral prednisone or prednisolone (dose 0.5 mg to 2 mg/kg/day) (Neunert *et al.*, 2019; Provan *et al.*, 2019; Provan *et al.*, 2010). Improvement in platelet count is generally seen in the initial 2 weeks. For patients achieving response (usually platelet count $>50 \times 10^9/L$), the corticosteroid should be tapered over the next 6–8 weeks. If there is no improvement by 2–4 weeks of treatment, the steroid should be tapered over the next 1–2 weeks. During tapering, platelet count may show a decreasing trend (Neunert *et al.*, 2019; Provan *et al.*, 2019; Provan *et al.*, 2010). High-dose pulse of dexamethasone (40 mg OD oral or IV daily for 4 days, repeated after 2–4 weeks, up to 3–4 cycles) can be used in place of oral prednisolone (Cheng *et al.*, 2003; Borst *et al.*, 2004). Multiple studies have compared the efficacy of prednisone and dexamethasone in ITP. A meta-analysis revealed that dexamethasone demonstrates a faster response (at 2 weeks) as compared to prednisolone, but there is no difference in outcomes at 6 months (Mithoowani *et al.*, 2016). Intravenous methylprednisolone pulse (1 gm daily for 3 days, or 15 mg/kg/day), followed by oral prednisone 1 mg/kg/day from day 4 to sustain the response, is also used in the setting of acute ITP (Godeau *et al.*, 2002; Godeau *et al.*, 1995).

Initial response to corticosteroids takes 2 to 14 days, with peak response usually between 1 and 4 weeks (Figure 2). Although two-thirds of ITP patients achieve an initial response to glucocorticoids, the sustained response is seen in only 30%-50% of patients. Steroid-refractory ITP patients are candidates for second-line treatment options (Neunert *et al.*, 2019; Provan *et al.*, 2019; Provan *et al.*, 2010; Neunert *et al.*, 2011; Neylpon *et al.*, 2003; Stasi *et al.*, 1995). Glucocorticoid-based therapy needs supervision as they are associated with various adverse effects (Table 2). Intolerance to corticosteroids due to side effects is one of the indications to change therapy (Guirdy *et al.*, 2009; Guirdy *et al.*, 2009). Calcium and vitamin D supplementation are recommended to reduce the risk of osteoporosis. Bone mineral density (BMD) should be monitored with DEXA-scan in patients on steroids for a prolonged duration (Buckley *et al.*, 2017). Patients with dyspeptic symptoms can be treated with proton-pump inhibitors or H2 antagonists (Messer *et al.*, 1983).

Immunomodulatory Drugs

Intravenous immunoglobulin (IVIG)

Because of its anti-inflammatory and immunomodulatory properties, intravenous immunoglobulin (IVIG) is used to treat a wide range of autoimmune conditions. Most commercial preparations include immunoglobulin G (>95 percent weight-to-weight) and are derived from a plasma pool of over 1000 healthy donors. Primary or secondary antibody deficits were initially treated with this medication. High-dose IVIG was originally shown to enhance platelet counts in children with ITP in 1981 by Imbach *et al.* (Imbach *et al.*, 1981). Since then, its efficacy in ITP is well established and it is used as first-line anti-ITP therapy, with or without steroids. IVIG blocks Fc receptors on phagocytic cells in the spleen and liver and prevents reticuloendothelial uptake of autoantibody-coated platelets. Another mechanism is the accelerated elimination of anti-platelet antibodies. The usual established dose is 1 gm/kg/ day for 2 days and it can be repeated at the same dose in non-responding patients. Initial high-dose IVIG has shown good response (67 vs. 21%) as compared to low dose, i.e., 0.5 mg/ kg/day (Lazarus & Crow, 2003; Lazarus, 2002).

Most ITP patients (70–80%) show improvement in 24 to 48 hours after IVIG and it is also used as a marker for diagnosis of ITP (Salib *et al.*, 2016). The response is transient for 2–6 weeks and repeated doses may be needed to maintain a safe platelet count. As the response is faster than corticosteroids, IVIG can be used in emergencies like active bleeding with severe thrombocytopenia, or patients who need an urgent invasive procedure. About 30% of ITP patients become refractory to IVIG over time (Provan *et al.*, 2010; Hong *et al.*, 2018). Adverse reactions to IVIG include headache, hypertension, allergic reactions, etc., during administration. More serious adverse reactions include anaphylaxis in IgA deficient individuals, hemolytic anemia, acute kidney injury, thrombosis, and transmission of bloodstream infections (Ammann *et al.*, 2016).

Anti-D immune globulin

The first-line treatment for ITP is anti-D immunoglobulin. An intravenous injection of 50 to 75 g/kg/dose of D antigen-targeted immunoglobulin is used to treat Rh-negative patients. Anti-D-coated RBCs occupy macrophages' Fc receptors, causing macrophage activation.(65). Hence, it can be exclusively given to Rh-positive ITP patients and is not effective in patients who have already undergone splenectomy (Cooper *et al.*, 2009). Response to anti-D therapy can be expected in 24 to 48 hours (like IVIG) and generally sustains for 3 – 4 weeks. Overall response rate is 65% (Provan *et al.*, 2010; Scaradavou *et al.*, 1997; Nainthani *et al.*, 2009). IVIG-like infusion reactions are the most common adverse effects; however, they can also cause hemolytic anemia from extravascular hemolysis of anti-D-coated RBCs and acute hemolytic transfusion reaction (AHTR) (Scaradavou *et al.*, 1997; Freiberg *et al.*, 1998). So, patients should be monitored for 4 to 6 hours after anti-D infusion for flank pain, hematuria, and fever. Life-threatening intravascular hemolysis, DIC, and acute renal failure leading to death have been reported with anti-D, making it a less preferred alternative vis-à-vis IVIG (Gaines, 2000; Hong *et al.*, 1998).

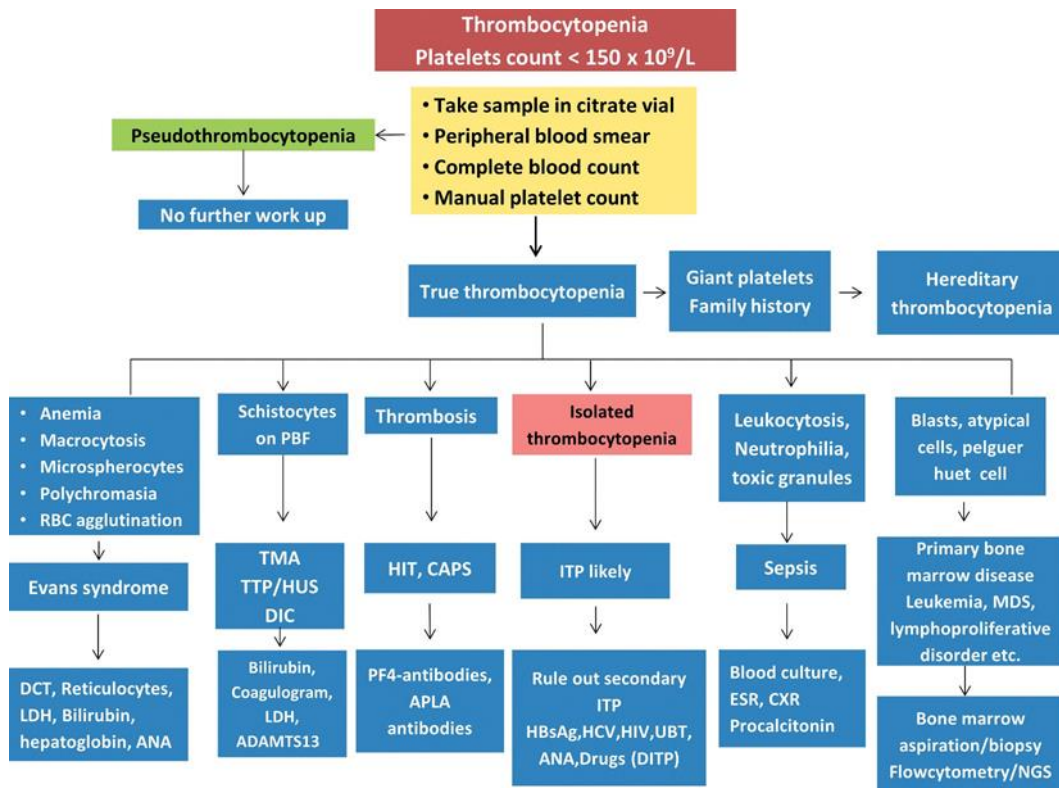


Fig.2- Treatment algorithm for immune thrombocytopenia.

Second-line therapy for ITP

In the majority of adult ITP patients, glucocorticoids or IVIG have an immediate effect, but the platelet count does not remain stable for lengthy periods of time or recur later in life. The second-line treatment choices for these individuals may be categorised as medical (rituximab, thrombopoietin receptor agonists (TPO-RAs)) and are followed by a well-informed and cooperative decision-making process when picking the second-line drugs for the patients who failed upfront therapy.

Rituximab

It is a chimeric monoclonal antibody against CD20 on the surface of B-lymphocytes. It decreases B-cell function through multiple mechanisms like direct apoptosis, antibody-dependent cytotoxicity (ADCC), complement-dependent cytotoxicity (CDC), augmentation of Th2 helper cells, and increase in regulatory T cells (Khellaf *et al.*, 2013). Its standard dose is 375 mg/m²/week (intravenous infusion) for 4 weeks. Similar efficacy has been achieved with alternative dosing schedules like 100 mg/week for 4 weeks, or 1000 mg on day 1 and day 15 (Neunert *et al.*, 2019; Provan *et al.*, 2019; Neunert *et al.*, 2018; Cragg *et al.*, 2005; Zaja *et al.*, 2010; Mishra *et al.*, 2020). Studies with rituximab in ITP have shown a response rate of 60–80% at 6 to 12 months, and 20–30% at 2–5 years (Provan *et al.*, 2019; Cheng *et al.*, 2011; Tran *et al.*, 2014; Miyakawa *et al.*, 2015; Marangon

et al., 2017; Ghanima *et al.*, 2015). Factors associated with poor response are the long duration of disease and failed previous attempts at treatment. Young female patients (<40 years) with newly diagnosed ITP show superior response to rituximab. Response rates among splenectomies and non-splenectomized patients are similar; however, relapses are frequent in splenectomized patients (Mishra *et al.*, 2020; Sys *et al.*, 2017; Pasa *et al.*, 2009; Hindilerden *et al.*, 2017; Qu *et al.*, 2020). Infusion-related reactions are common with rituximab; therefore, the first infusion should always be given following a test dose and premedication with paracetamol and antihistamines (Des). Long-term side effects include increased risk of infections, late-onset neutropenia, reactivation of hepatitis B, hypogammaglobulinemia, and very rarely, progressive multifocal leukoencephalopathy (PMLE) (Paul *et al.*, 2019). Testing for hepatitis B (HBsAg and anti-HBc (hepatitis-B core antibody)) is recommended before starting rituximab (Mishra *et al.*, 2020; Hindilerden *et al.*, 2017; Sahu *et al.*, 2019; Focosi *et al.*, 2019).

Thrombopoietin receptor agonists (TPO-RAs)

Thrombopoietin receptor agonists (TPO-RAs) are small molecules (peptide and non-peptide) that stimulate the production of megakaryocytes by activating the TPO receptors on bone marrow progenitor cells. Most patients with severe and symptomatic thrombocytopenia refractory to glucocorticoids or IVIG respond to TPO-RAs. They require continued therapy to sustain the response. TPO-RAs approved for ITP are eltrombopag, Romiplostim and avatrombopag.

Eltrombopag

Eltrombopag, a non-peptide oral medication licenced for chronic ITP, is usually begun at a dosage of 50 mg once day (maximum 75 mg/day). A lesser dosage might be prescribed to patients of Asian descent (25 mg once daily) (Tomiyama *et al.*, 2012; Mishra *et al.*, 2020). It should be taken 2 hours before or 4 hours after meals and drugs which contain polyanions (calcium supplements, antacids), for its maximum absorption (Saleh *et al.*, 2013). Platelet count starts increasing after 1–2 weeks of therapy. In previous studies, 40%–80% of ITP patients were able to achieve the target platelet count. After discontinuation, 10–30% ITP patients continued to remain in remission (Cheng *et al.*, 2011; Mishra *et al.*, 2020; Saleh *et al.*, 2013, Bussel *et al.*, 2009; Copper *et al.*, 2019). Short-term side effects include thrombocytosis, gastrointestinal discomfort, headache, and liver dysfunction. Liver function tests should be monitored regularly in patients on eltrombopag. Long-term and rare side effects include thrombosis, hepatic, and bone marrow fibrosis (Saleh *et al.*, 2013; Ghanima *et al.*, 2014). Some studies have shown worsening of renal failure when it is used in patients with systemic lupus erythematosus (Sperati & Streiff, 2010). Other studies did not show any major safety concerns with the drug (Ghanima *et al.*, 2014; Cheng, 2013).

Romiplostim

It is a peptide, i.e. a recombinant protein, that has a peptide with four binding sites for the TPO receptor, linked to an IgG1- Fc component (Newland *et al.*, 2006; Molimeux & Newland, 2010). It is given as a subcutaneous injection (1–10

$\mu\text{g}/\text{kg}/\text{week}$) (Cooper *et al.*, 2019; Kuter *et al.*, 2010; Cines *et al.*, 2017). Response rates and the onset of action with romiplostim are similar to eltrombopag (Table 2). The sustained remission after stopping romiplostim is observed in 10–30% of patients (Cooper *et al.*, 2019; Shirasugi *et al.*, 2011; Bidika *et al.*, 2020; Puravilai *et al.*, 2020). A recent study from the United States has shown an overall response rate of more than 90% with romiplostim, which inversely correlated with the duration of ITP (Kuter *et al.*, 2013). Mild headache, thrombocytosis, thrombosis, and reversible increase in bone marrow reticulin or collagen are the most common adverse effects (Janssens *et al.*, 2016).

Avatrombopag

It is an oral preparation-like eltrombopag and it is usually started at 20 mg daily. Unlike eltrombopag, there is no need for any dietary restriction, and it can be taken any time after meals (Provan *et al.*, 2019; Cooper *et al.*, 2019; Jurczak *et al.*, 2018; Dlugosz-Danecka *et al.*, 2019). As compared to the other two TPO-RAs, there is less clinical experience with eltrombopag. Usually, platelets start increasing after 1–2 weeks of therapy with an overall response of 50–80%, which is dose-dependent (Neunert *et al.*, 2019; Cooper *et al.*, 2019; Jurezak *et al.*, 2018; Dlugosz-Danecka *et al.*, 2019; Bussel *et al.*, 2014). Side effects similar to other TPO-RAs have been reported with eltrombopag which are easily manageable (Cooper *et al.*, 2019; Xu *et al.*, 2019). Switch between Thrombopoietin receptor agonists (TPO- RAs) – Switching between eltrombopag to romiplostim or vice versa has been shown promising results and can be done in clinical practice. The most common reasons for switching are side effects of the drug, failure of one drug, and patient preference (Khellaf *et al.*, 2013; Gonzalez-Porras *et al.*, 2015)

Splenectomy

It is an option for patients not responding to corticosteroids or IVIG. It was a popular approach in the past, but less preferred nowadays due to the availability of effective non-surgical therapeutic options (Sys *et al.*, 2017). The spleen is the major site of the platelet phagocytosis in ITP and its removal results in an improvement in platelet count. Splenectomy also removes lymphocytes which are responsible for the production of anti-platelet antibodies (Chater *et al.*, 2016; Rodeghiero *et al.*, 2018). Platelet count shows improvement in 1–8 weeks. In the short term, the response is seen in 80–90% of patients, and 60–70% of patients show sustained response over 5–10 years (Wu *et al.*, 2004). Younger patients respond better to splenectomy than older patients (usually >65 years); no other factor can predict the response (George *et al.*, 1996; Kojouri *et al.*, 2004; Ojima *et al.*, 2006; Fabris *et al.*, 2001).

Most guidelines suggest splenectomy after 12 to 24 months of ITP diagnosis as some of these patients have a chance of spontaneous remission. So, we can avoid unnecessary major surgical procedures in a small subgroup of ITP patients. As such low platelet count is not a contraindication for splenectomy, but it should be maintained more than $50 \times 10^9/\text{L}$ before the procedure, and it can be achieved by a short course of TPO- RAs or corticosteroids before splenectomy (Chen *et al.*, 2011; Zaja *et al.*, 2016; Kashiwagi *et al.*, 2020). Laparoscopic splenectomy is preferred over open splenectomy due to less procedural complications (0.2% vs

1%) and morbidity (less hospitalization, early mobility) with the laparoscopic approach. Presently, laparoscopic splenectomy is the standard procedure in most of the centers (Kojouri *et al.*, 2004; Duperier *et al.*, 2004; Aramaki *et al.*, 2003; Sotomayor-Ramirez, 2009). Procedural complications include infections, bleeding, thrombocytosis (9–12.9%), and 0.2% mortality risk during operation. Long-term complications include an increased risk of opportunistic infections (OPSI, lifetime risk 10%), arterial or venous thrombosis, and pulmonary hypertension. Old age is associated with more complications (Provan *et al.*, 2010; Sys *et al.*, 2017; Park *et al.*, 2016; Vianelli *et al.*, 2005; Tada *et al.*, 2018). Patients planned for splenectomy should be immunized against encapsulated organisms (*Streptococcus pneumoniae*, *Haemophilus influenzae*, and meningococcal), ideally 2 weeks before the surgery. They should also receive the annual seasonal influenza vaccine and all other vaccines as recommended for their age. Post-splenectomy patients should be started empirically on an empirical antibiotic in case of febrile illness and should receive prophylactic antibiotics during procedures that involve paranasal sinuses or respiratory tract (Gillis *et al.*, 1993; Buzele *et al.*, 2016; McCrae, 2013; Nazi *et al.*, 2013).

Drugs after First and Second-Line Therapy

Fostamatinib

For ITP patients who have failed first or second-line therapy or are unable to tolerate these medications, the FDA has authorised a new drug. TKI (tyrosine kinase inhibitor) is an oral medication that inhibits the activity of splenic tyrosine kinase in the body (SYK inhibitor) (Newland *et al.*, 2018; Niscola *et al.*, 2018). It is the active component (R406) that blocks signal transduction through Fc-activating receptors and the B-cell receptor and prevents phagocytosis of platelets coated with antibodies in the spleen. Its starting dose is 75 mg twice daily, which can be increased to 150 mg twice daily, depending upon the response (Moore *et al.*, 2019; Bussel *et al.*, 2018). The response rate varies from 18% to 43% in ITP patients previously treated with first and second-line drugs. Platelets usually start increasing in 1–2 weeks (Provan *et al.*, 2019; Copper *et al.*, 2019). Side-effects are mild and well-tolerated – like hypertension, liver dysfunction, nausea, and diarrhea. Blood pressure and liver functions tests need regular monitoring (Provan *et al.*, 2019; Copper *et al.*, 2019; Bussel *et al.*, 2019).

Immunosuppressive Therapy

Danazol

It is frequently used as a steroid-sparing agent for ITP patients who are either intolerant to or non-affording for second-line drugs. Usual dose is 600–800 mg/day (Provan *et al.*, 2019; Provan *et al.*, 2010; Ahm *et al.*, 1989). Published studies have shown response rates of 30–60% after 1–3 months. If there is no improvement in platelet count after 3 months of therapy, it can be stopped (Provan *et al.*, 2019; Provan *et al.*, 2010; Phillips *et al.*, 1990; Liu *et al.*, 2016). It is an androgenic drug and should not be used in patients with prostate cancer. Major side effects are acne, hirsutism, amenorrhea, and liver dysfunction (Provan *et al.*, 2019; Provan *et al.*, 2010; Liu *et al.*, 2016; Schiavotto *et al.*, 1993).

Dapsone

It is an oral sulfa drug with steroid-sparing action in ITP. It is started at a dose of 75–100 mg/day (Rattanathammethree *et al.*, 2017). It has been used in the past as a cheap second-line treatment option for ITP in developing countries (Provan *et al.*, 2010; Zaja *et al.*, 2012; VancineCalifani *et al.*, 2008). Platelet count starts improving after 3–4 weeks with an overall response rate of 30–60%. ITP patients who have already undergone splenectomy show inferior response to dapsone (Provan *et al.*, 2019; Copper *et al.*, 2019; VancineCalifani *et al.*, 2008; Khera *et al.*, 2020). Common side effects include gastrointestinal discomfort, headache, insomnia, methemoglobinemia, and hemolytic anemia in men with G6PD deficiency (Sahu *et al.*, 2020). It should not be used in patients who are allergic to sulfonamides (Copper *et al.*, 2019; Molineli *et al.*, 2019)

Azathioprine

It is used at a dose of 1–2 mg/kg/day (maximum 150 mg/day). Response rates vary from 30% to 60% and are usually observed within 6–12 weeks (Copper *et al.*, 2019; Chang *et al.*, 2018). Although it is well-tolerated, rarely patients may develop liver dysfunction and neutropenia. With long-term use, there is the risk of developing leukemia with this drug (Yenson *et al.*, 2008).

Mycophenolate mofetil (MMF)

It is an immunosuppressant drug, mainly used to prevent solid organ transplant rejection (Staaaz *et al.*, 2014). Its starting dose is 500 mg twice daily for 2 weeks which can be increased to 1 g twice daily. Improvement starts in 1–2 months and response can be seen in 30 to 60% of patients. Side effects are diarrhea, headache, increased risk of fungal infection, and increased risk of cancer (Copper *et al.*, 2019; Taylor *et al.*, 2015; Colovic *et al.*, 2011; Hou *et al.*, 2003).

Cyclosporin

In ITP patients, it can be taken alone or in combination with prednisone at a daily dosage of 2.5-3 mg/kg. In up to 80% of ITP patients, platelet count improvement has been observed, with a full response in 42% of patients. These include renal failure, hypertension, hirsutism and gum hypertrophy. For the sake of safety, it should be avoided in patients with renal failure, and therapeutic drugs should be closely monitored.(Emilia *et al.*, 1996; Emilia *et al.*, 2002; Kappers-Klunne *et al.*, 2001)

Cyclophosphamide

It is uncommonly used nowadays in ITP. It can be given either orally (1–2 mg/kg/day) for at least 3–4 months or intravenously (0.3–1 g/m²/every 2–4 weeks) in ITP patients who are refractory to first or second-line therapy. Clinical response is seen in 24–85% of patients. Side effects include hemorrhagic cystitis, renal dysfunction, fatigue, neutropenia, and a rarely increased risk of acute myeloid leukemia (Verlin *et al.*, 1976; Reiner *et al.*, 1995; Reid *et al.*, 1995; Krause *et al.*, 1982; Sahu *et al.*, 2016).

Vinca alkaloids (vincristine and vinblastine)

These drugs can achieve transient improvement in ITP with a variable response rate (10–75%). A weekly regimen for 2–3 weeks is commonly used (vincristine 1–2 mg/week and vinblastine 10 mg/week). Side effects include neuropathy, constipation, and local complications due to extravasation during infusion (Stirnemann *et al.*, 2016; Park *et al.*, 2016; Shvidel *et al.*, 2006).

Combination Therapy In Newly Diagnosed And Refractory Itp

It includes the use of more than one agent for the treatment of refractory ITP (in whom first and second-line therapies have failed) or newly diagnosed ITP (as first-line therapy). Doublet and triplet regimens in such settings have shown encouraging results. Studies have shown that upfront combination therapies comprising of recombinant TPO-RAs and steroids lead to superior outcomes in terms of response rates as compared to monotherapy (Zhou *et al.*, 2015; Arai *et al.*, 2018). However, it is important to note the difference between the real-world experience and differentiate it from the investigations and trials done in laboratory settings. Many patients when they get enrolled in trials, undergo washout periods in which they are not given any therapy for a few weeks and then treated in a naïve setting with a combination of investigational drugs while investigators watch what happens to the platelet count. Also, while investigating a combination treatment, another factor that deserves attention is that patient satisfaction and quality of life.

Triple Therapy

It includes low-dose rituximab (100 mg on days 7, 14, 21, and 28), high-dose oral dexamethasone (40 mg daily on days 1–4), and oral cyclosporin (2.5 to 3 mg/kg daily on days 1–28) for a total duration of 4 weeks. It is also called TT4, i.e. triple therapy for 4 weeks, and has a response rate of 60% at 6 months (Choi *et al.*, 2015). Another combination of oral azathioprine, cyclosporin, and mycophenolate has shown a response rate of 70%, but more than 50% of patients relapsed on subsequent follow-up (Arnold *et al.*, 2010; Figueroa *et al.*, 1993).

Doublet Regimen

Dexamethasone and rituximab combination or TO-RAs and dexamethasone have been tried in newly diagnosed ITP patients with a higher sustained response rate than dexamethasone alone (58% vs 37%) (Gudbrandsdottir *et al.*, 2013). Studies have also shown superior and faster response to combinations of IVIG and steroids than either of these drugs alone (Gudbrandsdottir *et al.*, 2013; Zaja *et al.*, 2010; Boruchov *et al.*, 2007). A recently conducted multicenter, UK-based, open-label, randomized controlled trial (The FLIGHT trial) compared combined MMF and corticosteroid versus corticosteroid alone and found it to be a more effective first-line ITP treatment. Although there were almost similar rates of significant adverse events, and bleeding events between the two groups, some aspects of QoL were noted to be worse in MMF plus steroid group. A recently concluded study (ClinicalTrials.gov Identifier: NCT00909077) compared high-dose dexamethasone versus high-dose dexamethasone in combination with rituximab. This was a

randomized phase III study involving 155 newly diagnosed patients with ITP. It was noted that patients with rituximab + dexamethasone had a sustained response at 6 months follow-up (i.e. platelets $\geq 50 \times 10^9/L$) when compared with the dexamethasone alone group (58% versus 37%, $P = .02$) (Gudbrandsdottir *et al.*, 2013). Similarly, Eltrombopag plus dexamethasone (Dose, Eltrombopag 50 mg PO days 5–32 Dexamethasone 40 mg PO days 1–4) (ClinicalTrials.gov identifier: NCT01652599). They found that 100% of patients got a response of platelet count $\geq 30 \times 10^9/L$ at the end of Day 33. Also, a sustained response of platelet count $\geq 50 \times 10^9/L$ at 6 months was noted in 75% of these patients. The combination treatment was well tolerated without any ill events of myelofibrosis, or thrombosis.

Supportive Care During Active Bleed

Platelet's transfusion

ITP is one of the most common indications for hematology consultation in an emergency (Nampoothiri *et al.*, 2017). Platelet transfusion can be used as a temporary measure to tackle active bleeding in an emergency. Patients should be started on definite therapy as early as possible (Goel *et al.*, 2019; Estcourt *et al.*, 2017; Zhang *et al.*, 2020). Platelet transfusion does not increase thrombotic risk (Goel *et al.*, 2015).

Anti-fibrinolytic drugs

IV or oral tranexamic acid (15–20 mg/kg q 8 hourly), epsilon aminocaproic acid (1–5 gm 6 hourly) can be used as a short-term measure in an emergency but the long-term benefit of these drugs is not clear (Wardrop *et al.*, 2013; Estcourt *et al.*, 2016).

Hormonal therapy

Norethisterone can be used to stop menstrual bleeding in females for a short duration till definite therapy starts working (Lethaby *et al.*, 2015; Bofill *et al.*, 2019).

Special Scenarios In ITP

ITP and pregnancy

In pregnancy, differential diagnoses for thrombocytopenia include gestational thrombocytopenia, pregnancy-related hypertensive disorders like eclampsia, HELLP syndrome (hemolysis, elevated liver enzymes, low platelet count). Once the diagnosis of ITP is established, the patient should be kept on close follow-up for bleeding with target platelet count $>30 \times 10^9/L$ till term. The mode of delivery is guided by the obstetrician's choice. For normal delivery, the platelet count should be kept $>50 \times 10^9/L$, and for the cesarean section, it should be maintained $>70 \times 10^9/L$ for safe spinal anesthesia. Drugs preferred in pregnancy are IVIG and corticosteroids. Patients are usually started on prednisolone at 20 mg daily and the patient is kept on a minimum dose to maintain target platelets to avoid unnecessary side effects. IVIG at dose 1–2 gm/kg can be used if a fast response is required near term. Anti-D can be also used in non-splenectomized patients after documenting negative direct Coombs test. In refractory cases, combination

therapies comprising of high-dose corticosteroid (dexamethasone) with IVIG or azathioprine, or cyclosporine with azathioprine can be used. The published experience with TPO-RAs in pregnancy is limited to case reports only. Rituximab increases the risk of immunosuppression in the newborn, so its use is not recommended. If a patient needs splenectomy for refractory ITP, it should be preferably performed during the second trimester. Vinca alkaloids, mycophenolate, and cyclophosphamide should not be used during pregnancy (Neurent *et al.*, 2019; Provan *et al.*, 2019; Provan *et al.*, 2010; Eslick & McLintock, 2020).

ITP and surgery

Most of the minor and major surgeries can be performed without any significant bleeding complication at platelet count $>50 \times 10^9/L$ and $>80 \times 10^9/L$, respectively. Neurosurgical intervention requires platelets count $>100 \times 10^9/L$ (Neurent *et al.*, 2019; Provan *et al.*, 2019; Provan *et al.*, 2010).

ITP and anticoagulation

For ITP patients who need anticoagulation for any reason, the platelet count should be maintained above $50 \times 10^9/L$ (Provan *et al.*, 2019; Provan *et al.*, 2010).

Secondary ITP

Once the cause of ITP has been detected, the treatment of the underlying disease should be started. Patients with HCV infection should be started with newer antiviral drugs. HIV- associated thrombocytopenia generally improves with anti-retroviral therapy. Patients with a positive urea breath test should be treated for *H. pylori* infection. If there is no improvement after treating the underlying cause, the patients can be treated as primary ITP with IVIG or corticosteroids (Neurent *et al.*, 2019; Provan *et al.*, 2010; Neurent *et al.*, 2011).

Upcoming Therapy/Clinical Trials

Newer drugs in ITP like Bruton Tyrosine kinase (BTK) inhibitors, anti-CD154 monoclonal antibody, and neonatal Fc Receptor (FcRn) are in phase 1/2 trials (Smith *et al.*, 2018; Dou & Yang, 2019). Rilzabrutinib (a BTK inhibitor) has shown good activity in refractory ITP patients (presented as abstract in ASH 2020). The details of newer drugs that are currently being investigated for ITP are described in Table 3.

Conclusion

ITP is a heterogeneous disorder with unclear pathogenesis. The majority of the adult ITP patients (80%) progress to the chronic phase and need long-term follow-up. ITP is a diagnosis of exclusion and secondary causes for thrombocytopenia should be ruled out. All patients do not need therapy. The goal of therapy is to achieve and maintain a safe platelet count so that the patients can live a normal life. Corticosteroids and IVIG are the preferred first-line drugs. The role of TPO-RAs is evolving as second-line treatment. Splenectomy may be reserved for the patient's refractory to medical treatment. This review is about the challenges in

the diagnosis and management of ITP. The current advancements are targeted to minimize the bleeding events and at the same time to keep the medication-related side effects to a minimum. It is important to note for the internists that bleeding events in ITP are not proportionally related to the severity of thrombocytopenia. Hence, there is the possibility that a severely thrombocytopenic patient can have a non-bleeding phenotype and alternatively, a moderately thrombocytopenic patient can have a bleeding phenotype. Most adult ITP patients progress to the chronic phase and need lifelong follow-up. Not all patients with ITP need therapy. Only those with platelet count less than $30 \times 10^9/L$ or bleeding with thrombocytopenia require treatment. The goal of treatment is to achieve a safe platelet count with no bleeding symptoms. Corticosteroid or IVIG/Anti-RhD is usually the first-line therapy that yields a good response. Thrombopoietin receptors agonist (TPO-RAs) and rituximab can be used if first-line drugs fail. Splenectomy is an excellent one-time procedure that yields a long-term cure; however, it is less preferred in the modern era and generally reserved for refractory cases. Other medications like danazol, dapsone, cyclosporine, mycophenolate mofetil can be used in patients who fail the previous two lines of therapy. Combination therapy with two or more drugs is also an option for relapsed/refractory cases. New drugs like Bruton's tyrosine kinase (BTK) inhibitors have shown excellent response in the phase 1/2 trial. Many investigations on new drugs and other treatment modalities are going on in various clinical trials and are expected to bring newer insight into the management of ITP.

References

- Abe Y, Wada H, Tomatsu H, *et al.* A simple technique to determine thrombopoiesis level using immature platelet fraction (IPF). *Thromb Res.* 2006;118(4):463–469.
- Ahmad Z, Durrani NU, Hazir T. Bone marrow examination in ITP in children: is it mandatory? *J Coll Physicians Surg Pak.* 2007;17 (6):347–349.
- Ahn YS, Rocha R, Mylvaganam R, *et al.* Long-term danazol therapy in autoimmune thrombocytopenia: unmaintained remission and age-dependent response in women. *Ann Intern Med.* 1989;111 (9):723–729.
- Altintas A, Ozel A, Okur N, *et al.* Prevalence and clinical significance of elevated antinuclear antibody test in children and adult patients with idiopathic thrombocytopenic purpura. *J Thromb Thrombolysis.* 2007;24(2):163–168.
- Ammann EM, Haskins CB, Fillman KM, *et al.* Intravenous immune globulin and thromboembolic adverse events: a systematic review and meta-analysis of RCTs. *Am J Hematol.* 2016;91(6):594–605.
- Arai Y, Jo T, Matsui H, *et al.* Comparison of up-front treatments for newly diagnosed immune thrombocytopenia -a systematic review and network meta-analysis. *Haematologica.* 2018;103(1):163–171.
- Aramaki M, Matsumoto T, Kitano S. (Laparoscopic and open splenectomy for idiopathic thrombocytopenic purpura). *Nihon Rinsho Japan J Clin Med.* 2003;61(4):599–603.
- Arnold DM, Nazi I, Santos A, *et al.* Combination immunosuppressant therapy for patients with chronic refractory immune thrombocytopenic purpura. *Blood.* 2010;115(1):29–31. .

- Audia S, Mahévas M, Samson M, *et al.* Pathogenesis of immune thrombocytopenia. *Autoimmun Rev.* 2017;16(6):620–632.
- Balduini CL, Pecci A, Savoia A. Recent advances in the understanding and management of MYH9-related inherited thrombocytopenias. *Br J Haematol.* 2011 Jul;154(2):161–174.
- Bastida JM, Benito R, Lozano ML, *et al.* Molecular Diagnosis of Inherited Coagulation and Bleeding Disorders. *Semin Thromb Hemost.* 2019;45(7):695–707.
- Bidika E, Fayyaz H, Salib M, *et al.* Romiplostim and Eltrombopag in Immune Thrombocytopenia as a Second-Line Treatment. *Cureus.* 2020;12(8):e9920.
- Bofill Rodriguez M, Lethaby A, Low C, *et al.* Cyclical progestogens for heavy menstrual bleeding. *Cochrane Database Syst Rev.* 2019;8 (8): Cd001016.
- Borst F, Keuning JJ, Van Hulsteijn H, *et al.* High-dose dexamethasone as a first- and second-line treatment of idiopathic thrombocytopenic purpura in adults. *Ann Hematol.* 2004;83(12):764–768.
- Boruchov DM, Gururangan S, Driscoll MC, *et al.* Multiagent induction and maintenance therapy for patients with refractory immune thrombocytopenic purpura (ITP). *Blood.* 2007;110 (10):3526–3531.
- Broudy VC, Lin NL. AMG531 stimulates megakaryopoiesis in vitro by binding to Mpl. *Cytokine.* 2004;25(2):52–60.
- Buckley L, Guyatt G, Fink HA, *et al.* American College of Rheumatology Guideline for the Prevention and Treatment of Glucocorticoid-Induced Osteoporosis. *Arthritis Rheumatol.* 2017;69 (8):1521–1537. . Hoboken, NJ. 2017
- Bussel J, Arnold DM, Grossbard E, *et al.* Fostamatinib for the treatment of adult persistent and chronic immune thrombocytopenia: results of two phases 3, randomized, placebo-controlled trials. *Am J Hematol.* 2018;93(7):921–930.
- Bussel JB, Arnold DM, Boxer MA, *et al.* Long-term fostamatinib treatment of adults with immune thrombocytopenia during the phase 3 clinical trial program. *Am J Hematol.* 2019;94(5):546–553.
- Bussel JB, Kuter DJ, Aledort LM, *et al.* A randomized trial of avatrombopag, an investigational thrombopoietin-receptor agonist, in persistent and chronic immune thrombocytopenia. *Blood.* 2014;123(25):3887–3894.
- Bussel JB, Provan D, Shamsi T, *et al.* Effect of eltrombopag on platelet counts and bleeding during treatment of chronic idiopathic thrombocytopenic purpura: a randomised, double-blind, placebo-controlled trial. *Lancet.* 2009;373(9664):641–648. . London, England
- Buzelé R, Barbier L, Sauvanet A, *et al.* Medical complications following splenectomy. *J Visc Surg.* 2016;153(4):277–286.
- Chan H, Moore JC, Finch CN, *et al.* The IgG subclasses of platelet-associated autoantibodies directed against platelet glycoproteins IIb/IIIa in patients with idiopathic thrombocytopenic purpura. *Br J Haematol.* 2003;122(5):818–824.
- Chang H, Tang TC, Hung YS, *et al.* Immune thrombocytopenia: effectiveness of frontline steroids and comparison of azathioprine, splenectomy, and rituximab as second-line treatment. *Eur J Haematol.* 2018;101(4):549–555.
- Chater C, Terriou L, Duhamel A, *et al.* Reemergence of Splenectomy for ITP Second-line Treatment? *Ann Surg.* 2016;264(5):772–777.
- Chen X, Peng B, Cai Y, *et al.* Laparoscopic splenectomy for patients with immune thrombocytopenia and very low platelet count: is platelet transfusion necessary? *J Surg Res.* 2011;170(2):e225–32.

- Cheng G, Saleh MN, Marcher C, *et al.* Eltrombopag for management of chronic immune thrombocytopenia (RAISE): a 6-month, randomised, phase 3 study. *Lancet*. 2011;377(9763):393–402.
- Cheng G. Thrombopoietin Receptor Agonists for the treatment of ITP. *Japan J Clin Hematol*. 2013;54(10):1915–1918.
- Cheng Y, Wong RS, Soo YO, *et al.* Initial treatment of immune thrombocytopenic purpura with high-dose dexamethasone. *N Engl J Med*. 2003;349(9):831–836.
- Cheung E, Liebman HA. Thyroid disease in patients with immune thrombocytopenia. *Hematol Oncol Clin North Am*. 2009;23 (6):1251–1260.
- Choi PY, Roncolato F, Badoux X, *et al.* A novel triple therapy for ITP using high-dose dexamethasone, low-dose rituximab, and cyclosporine (TT4). *Blood*. 2015;126(4):500–503.
- Cines DB, Liebman H, Stasi R. Pathobiology of secondary immune thrombocytopenia. *Semin Hematol*. 2009;46(1 Suppl 2): S2–14.
- Cines DB, Wasser J, Rodeghiero F, *et al.* Safety and efficacy of romiplostim in splenectomized and nonsplenectomized patients with primary immune thrombocytopenia. *Haematologica*. 2017;102(8):1342–1351.
- Colović M, Suvajdzic N, Colović N, *et al.* Mycophenolate mophetil therapy for chronic immune thrombocytopenic purpura resistant to steroids, immunosuppressants, and/or splenectomy in adults. *Platelets*. 2011;22(2):153–156.
- Cooper N, Ghanima W, Solomon CG. Immune Thrombocytopenia. *N Engl J Med*. 2019;381(10):945–955.
- Cooper N. Intravenous immunoglobulin and anti-RhD therapy in the management of immune thrombocytopenia. *Hematol Oncol Clin North Am*. 2009;23(6):1317–1327.
- Cragg MS, Walshe CA, Ivanov AO, *et al.* The biology of CD20 and its potential as a target for mAb therapy. *Curr Directions Autoimmunity*. 2005;8:140–174.
- Deshayes S, Khellaf M, Zarour A, *et al.* Long-term safety and efficacy of rituximab in 248 adults with immune thrombocytopenia: results at 5 years from the French prospective registry ITPrutux. *Am J Hematol*. 2019;94(12):1314–1324.
- Długosz-Danecka M, Zdziarska J, Jurczak W. Avatrombopag for the treatment of immune thrombocytopenia. *Expert Rev Clin Immunol*. 2019;15(4):327–339.
- Dou X, Yang R. Current and emerging treatments for immune thrombocytopenia. *Expert Rev Hematol*. 2019;12(9):723–732.
- Duperier T, Brody F, Felsher J, *et al.* Predictive factors for successful laparoscopic splenectomy in patients with immune thrombocytopenic purpura. *Arch Surg*. 2004;139(1):61–66. Chicago, Ill: 1960. discussion 6.
- Emilia G, Messori C, Longo G, *et al.* Long-term salvage treatment by cyclosporin in refractory autoimmune haematological disorders. *Br J Haematol*. 1996;93(2):341–344.
- Emilia G, Morselli M, Luppi M, *et al.* Long-term salvage therapy with cyclosporin A in refractory idiopathic thrombocytopenic purpura. *Blood*. 2002;99(4):1482–1485.
- Eslick R, McLintock C. Managing ITP and thrombocytopenia in pregnancy. *Platelets*. 2020;31(3):300–306.
- Estcourt LJ, Birchall J, Allard S, *et al.* Guidelines for the use of platelet transfusions. *Br J Haematol*. 2017;176(3):365–394.

- Estcourt LJ, Desborough M, Brunskill SJ, *et al.* Antifibrinolytics (lysine analogues) for the prevention of bleeding in people with haematological disorders. *Cochrane Database Syst Rev.* 2016;3(3): Cd009733.
- Fabris F, Tassan T, Ramon R, *et al.* Age as the major predictive factor of long-term response to splenectomy in immune thrombocytopenic purpura. *Br J Haematol.* 2001;112(3):637–640.
- Figueroa M, Gehlsen J, Hammond D, *et al.* Combination chemotherapy in refractory immune thrombocytopenic purpura. *N Engl J Med.* 1993;328(17):1226–1229.
- Focosi D, Tuccori M, Maggi F. Progressive multifocal leukoencephalopathy and anti-CD20 monoclonal antibodies: what do we know after 20 years of rituximab. *Rev Med Virol.* 2019;29(6): e2077.
- Fogarty PF, Tarantino MD, Brainsky A, *et al.* Selective validation of the WHO Bleeding Scale in patients with chronic immune thrombocytopenia. *Curr Med Res Opin.* 2012;28(1):79–87.
- Franchini M, Veneri D, Lippi G. Thrombocytopenia and infections. *Expert Rev Hematol.* 2017;10(1):99–106.
- Freiberg A, Mauger D. Efficacy, safety, and dose response of intravenous anti-D immune globulin (WinRho SDF) for the treatment of idiopathic thrombocytopenic purpura in children. *Semin Hematol.* 1998;35(1 Suppl 1):23–27.
- Frydman GH, Davis N, Beck PL, *et al.* Helicobacter pylori Eradication in Patients with Immune Thrombocytopenic Purpura: a Review and the Role of Biogeography. *Helicobacter.* 2015;20(4):239–251.
- Gaibullaeva, N. N. (2021). The role of clinical examination early diagnosis of glaucoma. *International Journal of Health & Medical Sciences*, 4(3), 333–337. <https://doi.org/10.31295/ijhms.v4n3.1745>
- Gaines AR. Acute onset hemoglobinemia and/or hemoglobinuria and sequelae following Rh(o)(D) immune globulin intravenous administration in immune thrombocytopenic purpura patients. *Blood.* 2000;95(8):2523–2529.
- George JN, Woolf SH, Raskob GE, *et al.* Idiopathic thrombocytopenic purpura: a practice guideline developed by explicit methods for the American Society of Hematology. *Blood.* 1996;88(1):3–40.
- Ghanima W, Geyer JT, Lee CS, *et al.* Bone marrow fibrosis in 66 patients with immune thrombocytopenia treated with thrombopoietin-receptor agonists: a single-center, long-term follow-up. *Haematologica.* 2014;99(5):937–944. .
- Ghanima W, Khelif A, Waage A, *et al.* Rituximab as second-line treatment for adult immune thrombocytopenia (the RITP trial): a multicentre, randomised, double-blind, placebo-controlled trial. *Lancet.* 2015;385(9978):1653–1661.
- Gillis S, Dann EJ, Berkman N, *et al.* Fatal Haemophilus influenzae septicemia following bronchoscopy in a splenectomized patient. *Chest.* 1993;104(5):1607–1609.
- Giordano P, Urbano F, Lassandro G, *et al.* Role of antithyroid auto-immunity as a predictive biomarker of chronic immune thrombocytopenia. *Pediatr Blood Cancer.* 2019;66(1):e27452.
- Godeau B, Chevret S, Varet B, *et al.* Intravenous immunoglobulin or high-dose methylprednisolone, with or without oral prednisone, for adults with untreated severe autoimmune thrombocytopenic purpura: a randomised, multicentre trial. *Lancet.* 2002;359(9300):23–29. . London, England

- Godeau B, Zini JM, Schaeffer A, *et al.* High-dose methylprednisolone is an alternative treatment for adults with autoimmune thrombocytopenic purpura refractory to intravenous immunoglobulins and oral corticosteroids. *Am J Hematol.* 1995;48(4):282–284.
- Goel R, Chopra S, Tobian AAR, *et al.* Platelet transfusion practices in immune thrombocytopenia related hospitalizations. *Transfusion.* 2019;59(1):169–176.
- Goel R, Ness PM, Takemoto CM, Goel R, Ness PM, Takemoto CM, Krishnamurti L, King KE, Tobian AA. Platelet transfusions in platelet consumptive disorders are associated with arterial thrombosis and in-hospital mortality. *Blood.* 2015;125(9):1470–1476.
- González-Porras JR, Mingot-Castellano ME, Andrade MM, *et al.* Use of eltrombopag after romiplostim in primary immune thrombocytopenia. *Br J Haematol.* 2015;169(1):111–116.
- Gudbrandsdottir S, Birgens HS, Frederiksen H, *et al.* Rituximab and dexamethasone vs dexamethasone monotherapy in newly diagnosed patients with primary immune thrombocytopenia. *Blood.* 2013;121(11):1976–1981. .
- Guidry JA, George JN, Vesely SK, *et al.* Corticosteroid side-effects and risk for bleeding in immune thrombocytopenic purpura: patient and hematologist perspectives. *Eur J Haematol.* 2009;83 (3):175–182.
- Guidry JA, Watson S, George JN, *et al.* Addendum to corticosteroid side effects and risk for bleeding in immune thrombocytopenic purpura: patient perspectives. *Eur J Haematol.* 2009;83(5):497–498.
- Hamad H, Sahu KK, Dunn S, *et al.* Rifampin Induced Thrombotic Thrombocytopenic Purpura. *Indian J Hematol Blood Transfus.* 2020;36(3):575–577.
- Heng LL, Caguioa P, Chin NS, *et al.* Chronic adult primary immune thrombocytopenia (ITP) in the Asia-Pacific region. *Int J Hematol.* 2011;94(2):142–149.
- Hindilerden F, Yönal-Hindilerden İ, Yenerel MN, *et al.* Rituximab Therapy in Adults with Refractory Symptomatic Immune Thrombocytopenia: Long-Term Follow-Up of 15 Cases. *Turk J Haematol.* 2017;34(1):72–80.
- Hong F, Ruiz R, Price H, *et al.* Safety profile of WinRho anti-D. *Semin Hematol.* 1998;35(1 Suppl 1):9–13.
- Hong J, Bang SM, Mun YC, *et al.* Efficacy and Safety of a New 10% Intravenous Immunoglobulin Product in Patients with Primary Immune Thrombocytopenia (ITP). *J Korean Med Sci.* 2018;33(19): e142.
- Hou M, Peng J, Shi Y, *et al.* Mycophenolate mofetil (MMF) for the treatment of steroid-resistant idiopathic thrombocytopenic purpura. *Eur J Haematol.* 2003;70(6):353–357.
- Imbach P, Barandun S, d'Apuzzo V, *et al.* High-dose intravenous gammaglobulin for idiopathic thrombocytopenic purpura in childhood. *Lancet.* 1981;1(8232):1228–1231. . London, England
- Ioachimescu AG, Makdissi A, Lichtin A, *et al.* Thyroid disease in patients with idiopathic thrombocytopenia: a cohort study. *Thyroid.* 2007;17(11):1137–1142.
- Janssens A, Rodeghiero F, Anderson D, *et al.* Changes in bone marrow morphology in adults receiving romiplostim for the treatment of thrombocytopenia associated with primary immune thrombocytopenia. *Ann Hematol.* 2016;95(7):1077–1087.

- Joo EJ, Chang Y, Yeom JS, *et al.* B infection is associated with an increased incidence of thrombocytopenia in healthy adults without cirrhosis. *J Viral Hepat.* 2017;24(3):253–258.
- Jurczak W, Chojnowski K, Mayer J, *et al.* Phase 3 randomised study of avatrombopag, a novel thrombopoietin receptor agonist for the treatment of chronic immune thrombocytopenia. *Br J Haematol.* 2018;183(3):479–490.
- Kado R, McCune WJ. Treatment of primary and secondary immune thrombocytopenia. *Curr Opin Rheumatol.* 2019;31(3):213–222.
- Kappers-Klunne MC, Van't Veer MB. Cyclosporin A for the treatment of patients with chronic idiopathic thrombocytopenic purpura refractory to corticosteroids or splenectomy. *Br J Haematol* 2001;114(1):121–125.
- Kashiwagi H, Kuwana M, Hato T, *et al.* Reference guide for management of adult immune thrombocytopenia in Japan: 2019 Revision. *Int J Hematol.* 2020;111(3):329–351.
- Khellaf M, Viallard JF, Hamidou M, *et al.* A retrospective pilot evaluation of switching thrombopoietic receptor-agonists in immune thrombocytopenia. *Haematologica.* 2013;98(6):881–887. .
- Khera S, Pramanik SK, Yanamandra U, *et al.* Dapsone: an Old but Effective Therapy in Pediatric Refractory Immune Thrombocytopenia. *Indian J Hematol Blood Transfus.* 2020;36(4):690–694.
- Kojouri K, Vesely SK, Terrell DR, *et al.* Splenectomy for adult patients with idiopathic thrombocytopenic purpura: a systematic review to assess long-term platelet count responses, prediction of response, and surgical complications. *Blood.* 2004;104 (9):2623–2634.
- Krause JR. Chronic idiopathic thrombocytopenic purpura (ITP) development of acute non-lymphocytic leukemia subsequent to treatment with cyclophosphamide. *Med Pediatr Oncol.* 1982;10 (1):61–65.
- Kuter DJ, Bussel JB, Newland A, *et al.* Long-term treatment with romiplostim in patients with chronic immune thrombocytopenia: safety and efficacy. *Br J Haematol.* 2013;161(3):411–423.
- Kuter DJ, Rummel M, Boccia R, *et al.* Romiplostim or standard of care in patients with immune thrombocytopenia. *N Engl J Med.* 2010;363(20):1889–1899.
- Lazarus AH, Crow AR. Mechanism of action of IVIG and anti-D in ITP. *Transfus Apher Sci.* 2003;28(3):249–255.
- Lazarus AH. Mechanism of action of IVIG in ITP. *Vox Sang.* 2002;83 (Suppl 1):53–55.
- Lethaby A, Hussain M, Rishworth JR, *et al.* Progesterone or progestogen-releasing intrauterine systems for heavy menstrual bleeding. *Cochrane Database Syst Rev.* 2015;4(6): Cd002126.
- Liebman HA. Recognizing and treating secondary immune thrombocytopenic purpura associated with lymphoproliferative disorders. *Semin Hematol.* 2009;46(1 Suppl 2): S33–6.
- Liu W, Gu X, Fu R, *et al.* The Effect of Danazol in Primary Immune Thrombocytopenia: an Analysis of a Large Cohort From a Single Center in China. *Clin Appl Thromb Hemost.* 2016;22(8):727–733.
- Marangon M, Vianelli N, Palandri F, *et al.* Rituximab in immune thrombocytopenia: gender, age, and response as predictors of long-term response. *Eur J Haematol.* 2017;98(4):371–377.
- Marta GN, De Campos FP. Immune thrombocytopenia and auto-immune thyroid disease: a controversial overlap. *Autops Case Rep.* 2015;5(2):45–48.

- McCrae KR. Better late than never? *Blood*. 2013;122(11):1844–1845.
- McMillan R. Antiplatelet antibodies in chronic adult immune thrombocytopenic purpura: assays and epitopes. *J Pediatr Hematol Oncol*. 2003;25(Suppl 1): S57–61.
- McMillan R. Antiplatelet antibodies in chronic immune thrombocytopenia and their role in platelet destruction and defective platelet production. *Hematol Oncol Clin North Am*. 2009;23 (6):1163–1175.
- Messer J, Reitman D, Sacks HS, *et al*. Association of adrenocortical steroid therapy and peptic-ulcer disease. *N Engl J Med*. 1983;309 (1):21–24.
- Mishra K, Jandial A, Malhotra P, *et al*. Wet purpura: a sinister sign in thrombocytopenia. *BMJ Case Rep*. 2017 Sep 1;2017.
- Mishra K, Jandial A, Sandal R, *et al*. Poor Platelet Function on Sonoclot Signature Is Associated with High Incidence of Bleeding in Severe Immune Thrombocytopenia. *Blood*. 2018;132(Supplement 1):4991.
- Mishra K, Kumar S, Jandial A, *et al*. Real-world Experience of Rituximab in Immune Thrombocytopenia. *Indian J Hematol Blood Transfus*. 2020 (accepted). <https://doi.org/10.1007/s12288-020-01351-3>
- Mishra K, Malhotra P, Jandial A, *et al*. Bleeding Risk Assessment By Sonoclot in Severe Immune Thrombocytopenia. *Blood*. 2017;13 (Supplement 1):2320. hio0
- Mishra K, Pramanik S, Jandial A, *et al*. Real-world experience of eltrombopag in immune thrombocytopenia. *Am J Blood Res*. 2020;10(5):240–251.
- Mithoowani S, Gregory-Miller K, Goy J, *et al*. High-dose dexamethasone compared with prednisone for previously untreated primary immune thrombocytopenia: a systematic review and meta-analysis. *Lancet Haematol*. 2016;3(10):e489–e96. .
- Miyakawa Y, Katsutani S, Yano T, *et al*. Efficacy and safety of rituximab in Japanese patients with relapsed chronic immune thrombocytopenia refractory to conventional therapy. *Int J Hematol*. 2015;102(6):654–661.
- Mizutani H, Furubayashi T, Imai Y, *et al*. Mechanisms of corticosteroid action in immune thrombocytopenic purpura (ITP): experimental studies using ITP-prone mice, (NZW x BXSB) F1. *Blood*. 1992;79 (4):942–947.
- Molinelli E, Paolinelli M, Campanati A, *et al*. Metabolic, pharmacokinetic, and toxicological issues surrounding dapsone. *Expert Opin Drug Metab Toxicol*. 2019;15(5):367–379.
- Molineux G, Newland A. Development of romiplostim for the treatment of patients with chronic immune thrombocytopenia: from bench to bedside. *Br J Haematol*. 2010;150(1):9–20.
- Moore DC, Gebru T, Muslimani A. Fostamatinib for the treatment of immune thrombocytopenia in adults. *Am J Health-system Pharm*. 2019;76(11):789–794.
- Moulis G, Comont T, Germain J, *et al*. Significance of antinuclear antibodies in primary immune thrombocytopenia: results of the CARMEN registry. *Blood Adv*. 2020;4(9):1974–1977.
- Naithani R, Kumar R, Mahapatra M, *et al*. Efficacy and safety of anti-D for treatment of adults with immune thrombocytopenia. *Platelets*. 2009;20(7):525–527.
- Nampoothiri RV, Singh C, Mishra K, *et al*. Immune thrombocytopenia is the commonest diagnosis on consultative hematology - a single centre experience. *Indian J Hematol Blood Transfus*. 2017 Nov; 33(Suppl 1): S104
- Nazi I, Kelton JG, Larché M, *et al*. The effect of rituximab on vaccine responses in patients with immune thrombocytopenia. *Blood*. 2013;122(11):1946–1953. .

- Neunert C, Lim W, Crowther M, *et al*. The American Society of Hematology 2011 evidence-based practice guideline for immune thrombocytopenia. *Blood*. 2011;117(16):4190–4207.
- Neunert C, Terrell DR, Arnold DM, *et al*. American Society of Hematology 2019 guidelines for immune thrombocytopenia. *Blood Adv*. 2019;3(23):3829–3866.
- Neunert CE, Cooper N. Evidence-based management of immune thrombocytopenia: ASH guideline update. *Hematol Am Soc Hematol Educ Program*. 2018;2018(1):568–575.
- Newland A, Caulier MT, Kappers-Klunne M, *et al*. An open-label, unit dose-finding study of AMG 531, a novel thrombopoiesis-stimulating peptibody, in patients with immune thrombocytopenic purpura. *Br J Haematol*. 2006;135(4):547–553.
- Newland A, Lee EJ, McDonald V, *et al*. Fostamatinib for persistent/ chronic adult immune thrombocytopenia. *Immunotherapy*. 2018;10(1):9–25.
- Neylon AJ, Saunders PW, Howard MR, *et al*. Clinically significant newly presenting autoimmune thrombocytopenic purpura in adults: a prospective study of a population-based cohort of 245 patients. *Br J Haematol*. 2003;122(6):966–974.
- Nicola P, Scaramucci L, Giovannini M. Spleen tyrosine kinase inhibition: a new promising approach to chronic and refractory immune thrombocytopenia. *Immunotherapy*. 2018;10(1):5–7.
- Ojima H, Kato T, Araki K, *et al*. Factors predicting long-term responses to splenectomy in patients with idiopathic thrombocytopenic purpura. *World J Surg*. 2006;30(4):553–559.
- Park YH, Yi HG, Kim CS, *et al*. Clinical Outcome and Predictive Factors in the Response to Splenectomy in Elderly Patients with Primary Immune Thrombocytopenia: a Multicenter Retrospective Study. *Acta Haematol*. 2016;135(3):162–171. .
- Park YH, Yi HG, Lee MH, *et al*. Clinical efficacy and tolerability of vincristine in splenectomized patients with refractory or relapsed immune thrombocytopenia: a retrospective single-center study. *Int J Hematol*. 2016;103(2):180–188.
- Pasa S, Altintas A, Cil T, *et al*. The efficacy of rituximab in patients with splenectomized refractory chronic idiopathic thrombocytopenic purpura. *J Thromb Thrombolysis*. 2009;27(3):329–333.
- Paul F, Cartron G. Infusion-related reactions to rituximab: frequency, mechanisms, and predictors. *Expert Rev Clin Immunol*. 2019;15(4):383–389.
- Phillips M. Danazol and idiopathic thrombocytopenic purpura. *Ann Intern Med*. 1990;112(6):474–475.
- Pierrot-Deseilligny Despujol C, Michel M, Khellaf M, *et al*. Antiphospholipid antibodies in adults with immune thrombocytopenic purpura. *Br J Haematol*. 2008;142(4):638–643.
- Provan D, Arnold DM, Bussel JB, *et al*. Updated international consensus report on the investigation and management of primary immune thrombocytopenia. *Blood Adv*. 2019;3(22):3780–3817.
- Provan D, Stasi R, Newland AC, *et al*. International consensus report on the investigation and management of primary immune thrombocytopenia. *Blood*. 2010;115(2):168–186. .
- Puavilai T, Thadanipon K, Rattanasiri S, *et al*. Treatment efficacy for adult persistent immune thrombocytopenia: a systematic review and network meta-analysis. *Br J Haematol*. 2020;188(3):450–459.

- Qu M, Zhou J, Yang SJ, *et al.* Efficacy and safety of rituximab for minors with immune thrombocytopenia: a systematic review and meta-analysis. *J Int Med Res.* 2020;48(10):300060520962348.
- Rattanathammethee T, Theerajangkaphichai W, Rattarittamrong E, *et al.* The Efficacy of Colchicine and Dapsone Combination Therapy in Relapsed Immune Thrombocytopenia. *Hematol Rep.* 2017;9 (1):7034.
- Reid DM, Shulman NR. Pulse cyclophosphamide to treat idiopathic thrombocytopenic purpura. *Blood.* 1995;86(1):414–415.
- Reiner A, Gernsheimer T, Slichter SJ. Pulse cyclophosphamide therapy for refractory autoimmune thrombocytopenic purpura. *Blood.* 1995;85(2):351–358.
- Ren DQ, Gao H, Li ZC. (Prognostic significance of peripheral blood cell and bone marrow megakaryocyte counts in patients with idiopathic thrombocytopenic purpura). *Zhongguo Shi Yan Xue Ye Xue Za Zhi.* 2003;11(2):199–201.
- Rodeghiero F, Michel M, Gernsheimer T, *et al.* Standardization of bleeding assessment in immune thrombocytopenia: report from the International Working Group. *Blood.* 2013;121(14):2596–2606. .
- Rodeghiero F, Stasi R, Gernsheimer T, *et al.* Standardization of terminology, definitions and outcome criteria in immune thrombocytopenic purpura of adults and children: report from an international working group. *Blood.* 2009;113(11):2386–2393.
- Rodeghiero F. A critical appraisal of the evidence for the role of splenectomy in adults and children with ITP. *Br J Haematol.* 2018;181(2):183–195.
- Sahu KK, Jindal V, Anderson J, *et al.* Current Perspectives on Diagnostic Assays and Anti-PF4 Antibodies for the Diagnosis of Heparin-Induced Thrombocytopenia. *J Blood Med.* 2020;11:267–277.
- Sahu KK, Lal A, Mishra AK, *et al.* Methemoglobinemia in Transplant Recipient Patients: future of Dapsone as Pneumocystis carinii Pneumonia Prophylaxis. *Prog Trans.* 2020;30(1):71–72. . Aliso Viejo, Calif
- Sahu KK, Petrou N, Cohn Z, *et al.* Rituximab-induced late-onset neutropenia. *BMJ Case Rep.* 2019;12(12):12.
- Sahu KK, Prakash G, Khadwal A, *et al.* Case of Hemorrhagic Cystitis in Allogeneic Hematopoietic Stem Cell Transplant Patient. *Indian J Hematol Blood Transfus.* 2016;32(Suppl 1):196–200.
- Salama A, Kiefel V, Amberg R, *et al.* Treatment of autoimmune thrombocytopenic purpura with rhesus antibodies (anti-Rh0(D)). *Blut.* 1984;49(1):29–35.
- Saleh MN, Bussel JB, Cheng G, *et al.* Safety and efficacy of eltrombopag for treatment of chronic immune thrombocytopenia: results of the long-term, open-label EXTEND study. *Blood.* 2013;121 (3):537–545.
- Salib M, Clayden R, Clare R, *et al.* Difficulties in establishing the diagnosis of immune thrombocytopenia: an agreement study. *Am J Hematol.* 2016;91(8): E327–9.
- Scaradavou A, Woo B, Woloski BM, *et al.* Intravenous anti-D treatment of immune thrombocytopenic purpura: experience in 272 patients. *Blood.* 1997;89(8):2689–2700. .
- Schiavotto C, Castaman G, Rodeghiero F. Treatment of idiopathic thrombocytopenic purpura (ITP) in patients with refractoriness to or with contraindication for corticosteroids and/or splenectomy with immunosuppressive therapy and danazol. *Haematologica.* 1993;78(6 Suppl 2):29–34.

- Sheema K, Ikramdin U, Arshi N, *et al.* Role of Helicobacter pylori Eradication Therapy on Platelet Recovery in Chronic Immune Thrombocytopenic Purpura. *Gastroenterol Res Pract.* 2017; 2017:9529752.
- Shirasugi Y, Ando K, Miyazaki K, *et al.* Romiplostim for the treatment of chronic immune thrombocytopenia in adult Japanese patients: a double-blind, randomized Phase III clinical trial. *Int J Hematol.* 2011;94(1):71–80.
- Shvidel L, Sigler E, Shtalrid M, *et al.* Vincristine-loaded platelet infusion for the treatment of refractory autoimmune hemolytic anemia and chronic immune thrombocytopenia: rethinking old cures. *Am J Hematol.* 2006;81(6):423–425.
- Smith B, Kiessling A, Lledo-Garcia R, *et al.* Generation and characterization of a high affinity anti-human FcRn antibody, rozanolixizumab, and the effects of different molecular formats on the reduction of plasma IgG concentration. *mAbs.* 2018;10 (7):1111–1130.
- Sotomayor-Ramírez RK. Efficacy and safety of laparoscopic splenectomy: a review of 14 adult cases using the lateral approach. *Boletín de la Asociación Médica de Puerto Rico.* 2009;101(2):43–49.
- Sperati CJ, Streiff MB. Acute renal failure in a patient with antiphospholipid syndrome and immune thrombocytopenic purpura treated with eltrombopag. *Am J Hematol.* 2010;85(9):724–726.
- Staatz CE, Tett SE. Pharmacology and toxicology of mycophenolate in organ transplant recipients: an update. *Arch Toxicol.* 2014;88 (7):1351–1389.
- Stasi R, Stipa E, Masi M, *et al.* Long-term observation of 208 adults with chronic idiopathic thrombocytopenic purpura. *Am J Med.* 1995;98(5):436–442.
- Stasi R, Stipa E, Masi M, *et al.* Prevalence and clinical significance of elevated antiphospholipid antibodies in patients with idiopathic thrombocytopenic purpura. *Blood.* 1994;84(12):4203–4208.
- Stirnemann J, Kaddouri N, Khellaf M, *et al.* Vincristine efficacy and safety in treating immune thrombocytopenia: a retrospective study of 35 patients. *Eur J Haematol.* 2016;96(3):269–275.
- Sultan S, Ahmed SI, Murad S, *et al.* Primary versus secondary immune thrombocytopenia in adults; a comparative analysis of clinical and laboratory attributes in newly diagnosed patients in Southern Pakistan. *Med J Malaysia.* 2016;71(5):269–274.
- Suryasa, I. W., Rodríguez-Gámez, M., & Koldoris, T. (2022). Post-pandemic health and its sustainability: Educational situation. *International Journal of Health Sciences*, 6(1), i-v. <https://doi.org/10.53730/ijhs.v6n1.5949>
- Sys J, Provan D, Schauwvlieghe A, *et al.* The role of splenectomy in autoimmune hematological disorders: outdated or still worth considering? *Blood Rev.* 2017;31(3):159–172.
- Tada K, Ohta M, Saga K, *et al.* Long-term outcomes of laparoscopic versus open splenectomy for immune thrombocytopenia. *Surg Today.* 2018;48(2):180–185. .
- Tang YT, He P, Li YZ, *et al.* Diagnostic value of platelet indices and bone marrow megakaryocytic parameters in immune thrombocytopenic purpura. *Blood Coagul Fibrin.* 2017;28(1):83–90. .
- Taylor A, Neave L, Solanki S, *et al.* Mycophenolate mofetil therapy for severe immune thrombocytopenia. *Br J Haematol.* 2015;171 (4):625–630.
- Tomiyama Y, Miyakawa Y, Okamoto S, *et al.* A lower starting dose of eltrombopag is efficacious in Japanese patients with previously treated chronic immune thrombocytopenia. *J Thromb Haemost.* 2012;10(5):799–806.

- Tran H, Brighton T, Grigg A, *et al.* A multi-center, single-arm, open-label study evaluating the safety and efficacy of fixed-dose rituximab in patients with refractory, relapsed, or chronic idiopathic thrombocytopenic purpura (R-ITP1000 study). *Br J Haematol.* 2014;167(2):243–251.
- Tseng V, Morgan AS, Leith CP, *et al.* Efficient assessment of peripheral blood lymphocytosis in adults: developing new thresholds for blood smear review by pathologists. *Clin Chem Lab Med.* 2014;52 (12):1763–1770.
- Vancine Califani SM, De Paula EV, Ozelo MC, *et al.* Efficacy and safety of dapsone as a second-line treatment in non-splenectomized adults with immune thrombocytopenic purpura. *Platelets.* 2008;19(7):489–495.
- Varma S, Kumar S, Garg A, *et al.* Hepatitis C virus infection among patients with chronic immune thrombocytopenic purpura in the northern India. *J Clin Exp Hepatol.* 2011;1(2):68–72.
- Verlin M, Laros RK Jr., Penner JA. Treatment of refractory thrombocytopenic purpura with cyclophosphamide. *Am J Hematol.* 1976;1 (1):97–104.
- Vianelli N, Galli M, De Vivo A, *et al.* Efficacy and safety of splenectomy in immune thrombocytopenic purpura: long-term results of 402 cases. *Haematologica.* 2005;90(1):72–77.
- Wardrop D, Estcourt LJ, Brunskill SJ, *et al.* Antifibrinolytics (lysine analogues) for the prevention of bleeding in patients with hematological disorders. *Cochrane Database Syst Rev.* 2013;(7): Cd009733. DOI:10.1002/14651858.CD009733.pub2.
- Ware RE, Zimmerman SA. Anti-D: mechanisms of action. *Semin Hematol.* 1998;35(1 Suppl 1):14–22.
- Wongrakpanich S, Salahuddin M, Mittar P. An abnormal peripheral blood smear and altered mental status. *Cleve Clin J Med.* 2016;83 (9):643–644.
- Wu JM, Lai IR, Yuan RH, *et al.* Laparoscopic splenectomy for idiopathic thrombocytopenic purpura. *Am J Surg.* 2004;187(6):720–723.
- Xu H, Cai R. Avatrombopag for the treatment of thrombocytopenia in patients with chronic liver disease. *Expert Rev Clin Pharmacol.* 2019;12(9):859–865.
- Yang YJ, Yun GW, Song IC, *et al.* Clinical implications of elevated antiphospholipid antibodies in adult patients with primary immune thrombocytopenia. *Korean J Intern Med.* 2011;26(4):449–454.
- Yenson PR, Forrest D, Schmiegelow K, *et al.* Azathioprine-associated acute myeloid leukemia in a patient with Crohn's disease and thiopurine S-methyltransferase deficiency. *Am J Hematol.* 2008;83(1):80–83.
- Yuan YP, Yang X, Chen YJ. Research Advances on the Pathogenesis of Primary Immune Thrombocytopenia–Review. *Zhongguo Shi Yan Xue Ye Xue Za Zhi.* 2019;27(5):1706–1710.
- Zaja F, Baccarani M, Mazza P, *et al.* Dexamethasone plus rituximab yields higher sustained response rates than dexamethasone monotherapy in adults with primary immune thrombocytopenia. *Blood.* 2010;115(14):2755–2762. .
- Zaja F, Barcellini W, Cantoni S, *et al.* Thrombopoietin receptor agonists for preparing adult patients with immune thrombocytopenia to splenectomy: results of a retrospective, observational GIMEMA study. *Am J Hematol.* 2016;91(5): E293–5.
- Zaja F, Marin L, Chiozzotto M, *et al.* Dapsone salvage therapy for adult patients with immune thrombocytopenia relapsed or refractory to steroid and rituximab. *Am J Hematol.* 2012;87(3):321–323.

- Zaja F, Vianelli N, Volpetti S, *et al.* Low-dose rituximab in adult patients with primary immune thrombocytopenia. *Eur J Haematol.* 2010;85(4):329–334.
- Zhang MK, Xu TQ, Zhang XJ, *et al.* Thrombocytopenia in 737 adult intensive care unit patients: a real-world study of associated factors, drugs, platelet transfusion, and clinical outcome. *SAGE Open Med.* 2020;8:2050312120958908.
- Zhou H, Xu M, Qin P, *et al.* A multicenter randomized open-label study of rituximab plus rhTPO vs rituximab in corticosteroid-resistant or relapsed ITP. *Blood.* 2015;125(10):1541–1547.