

**How to Cite:**

Jaiswal, P., Dixit, A., Kakodia, P. S., & Yadav, A. R. (2022). Comparative study of ropivacaine and ropivacaine with dexmedetomidine in ultrasound-guided transversus abdominis plane (TAP) block for post operative analgesia in laparoscopic cholecystectomies. *International Journal of Health Sciences*, 6(S5), 8605–8613. <https://doi.org/10.53730/ijhs.v6nS5.10637>

# **Comparative study of ropivacaine and ropivacaine with dexmedetomidine in ultrasound-guided transversus abdominis plane (TAP) block for post operative analgesia in laparoscopic cholecystectomies**

**Dr. Priyanka Jaiswal**

Senior Resident, Department of Anaesthesiology, Shyam Shah Medical College, Rewa, Madhya Pradesh

**Dr. Amey Dixit**

Senior Resident, Department of Anaesthesiology, Shyam Shah Medical College, Rewa, Madhya Pradesh

**Dr. Pradyumna Singh Kakodia**

Senior Resident, Department of Anaesthesiology, N.S.C.B Medical College, Jabalpur, Madhya Pradesh

**Dr. Abhay Raj Yadav \***

Assistant professor, Department of Anaesthesiology, Shyam Shah Medical College, Rewa, Madhya Pradesh

\*Corresponding Author

**Abstract**--Background and aims: TAP block is an effective way to provide postoperative analgesia .TAP block using ropivacaine alone has not been consistently proven to be effective in alleviating pain after laparoscopic surgeries. The study aimed to compare the combination of dexmedetomidine and ropivacaine to ropivacaine alone in TAP block for laparoscopic cholecystectomy patients for post operative analgesia. Materials and Methods: 60 patients of ASA health status I or II, were divided equally into 2 groups. Groups R received bilateral US- TAP blocks with 20 mL 0.375% Ropivacaine and Group RD received, 20 ml 0.375% ropivacaine with 50µg dexmedetomidine. Each patient was assessed in the PACU for first 24 hr for pain duration of analgesia, and need for rescue analgesic. Results: The mean of VAS pain score was least in group RD compared to group R and statistically significant ( $P < 0.05$ ).The total rescue analgesia ( tramadol ) consumption in 24 h after surgery was (116.6±37.9) mg in group RD against (160±67.4) mg in group R, which was also statistically significant ( $P < 0.05$ ). Duration of analgesia was greater in

group RD ( $7.7 \pm .53$ ) compared to group R ( $4.5 \pm .56$ ). Conclusion: Addition of dexmedetomidine to ropivacaine in TAP block prolongs postoperative analgesia and reduces opioid consumption without any major adverse effects.

**Keywords**---Dexmedetomidine, laparoscopic cholecystectomy, postoperative analgesia, subcostal transversusabdominis block, visual analogue scale.

## Introduction

Generally laparoscopic cholecystectomies are less painful, many patients complain of pain after the operation.<sup>1</sup> Several methods have been used to control the postoperative pain after laparoscopic cholecystectomies, such as intravenous patient-controlled analgesia, patient-controlled thoracic epidural analgesia, and the intraperitoneal injection of local anaesthetics.<sup>2</sup> In addition, the intraoperative use of low-pressure pneumoperitoneum techniques and a warmed air supply can reduce postoperative pain scores.<sup>3</sup>

The transversusabdominis plane (TAP) block was first defined by Rafi in 2001,<sup>4</sup> and it is newer modality as part of the multimodal analgesic therapy after abdominal surgery.<sup>5</sup> The TAP block produces a sensorial block via local anaesthetic infiltration, between the internal oblique muscle and transverse abdominis muscle, by targeting the innervating spinal nerves in this plane. This block affects thoracic intercostal nerves 7–12, the ilio-inguinal nerve, the iliohypogastric nerve and lumbar nerves 1–3 in the lateral cutaneous branches<sup>3</sup>. When compared with the conventional TAP block technique, ultrasound-guided TAP (US-TAP) block, which provides direct ultrasonographic visualization of the anatomy during the spreading the local anaesthetic, so it become more effective technique for performing a TAP block<sup>3</sup>. Complication should be minimized by performing the theUS- TAP BLOCK because the precise location of needle and diffusion of local anaesthetics can be observed directly. Our study evaluated the effects of US – TAP block on post operative pain relief by comparing ropivacaine and ropivacaine with dexmedetomidine in patients undergoing laproscopic cholecystectomies.

## Materials and Method

This study design was prospective, randomised and controlled. After getting approval from “Institutional Ethics Committee” it was conducted in a tertiary care centre from April 2019 to March 2020. we included Patients undergoing laparoscopic cholecystectomies between 18 – 65 years age group and ASA physical status grade I and grade II patients while patients of psychological disorder, severe systemic disease, pregnant women and the condition which are contraindicated for TAP block were excluded from our study

A detailed history of all selected patients was taken. A thorough pre-anaesthetic evaluation including the airway assessment was performed. The patients were explained about the entire procedure to be done and informed consent was taken

from them. They were also educated about the Visual Analogue Scale (VAS) for pain (0=no pain, 10=worst pain imaginable) and patient's satisfaction scale. Thereafter, they were shifted to the operation theatre. Monitor was attached and baseline parameters viz heart rate, systolic and diastolic blood pressure, mean arterial pressure, SpO<sub>2</sub>, EtCO<sub>2</sub>, ECG tracings were recorded. Intravenous line was secured. Full resuscitation equipment's were kept ready. After obtaining informed consent, the patients were randomly assigned to two groups using the sealed enveloped method. Demographic characteristics were being recorded including age, sex, height and weight.

**Group R** (ropivacaine group, n=30) patient received bilateral ultrasound guided-transversus abdominis plane (TAP) block with 0.375% ropivacaine (plain) and

**Group RD** (ropivacaine + dexmedetomidine, n=30) patient received bilateral ultrasound guided-transversus abdominis plane (TAP) block with 0.375% ropivacaine plus 50 mcg of dexmedetomidine.

In the operating room after routine monitoring and preoxygenation the patients were given iv fentanyl (2mcg / kg) as premedication, anaesthesia was induced with iv propofol (2mg/kg), succinyl choline (2mg/kg) was utilized to facilitate tracheal intubation. Anaesthesia was maintained with nitrous oxide (60%) and isoflurane (0.5-1%) in oxygen. The intra abdominal pressure was maintained at around 12 mm of Hg in all group patients throughout procedure.

At the end of surgery, under full asepsis, ultrasound-guided transversus abdominis plane (TAP) block was performed using a mid axillary approach, under real time guidance with a high frequency ultra sound probe (MINDRAY DC 30). A bilateral TAP block was performed using in plane technique, by using an insulated 20 gauge, 17 degree bevelled locoplex needle of length 50 mm. When the tip of needle was located in the space between the internal oblique and transverses abdominis muscle, 20 ml of 0.375 % plain ropivacaine or 20 ml of 0.375% plain ropivacaine with 50mcg dexmedetomidine was injected gradually after negative aspiration, under direct ultrasonographic visualization. We have given inj. diclofenac 75mg i/v and inj. paracetamol 1gm i/v infusion to all the patients (institutional analgesia protocol).

After completion of the surgical procedure and block, patients were transferred to the post anaesthesia care unit (PACU). Pain severity was assessed employing a Visual Analogue Scale. This assessment was performed in the PACU at 0, 2, 4, 8, 12, 18 and 24 hours after completion of surgery. All patients were asked to give scores for their pain at rest.

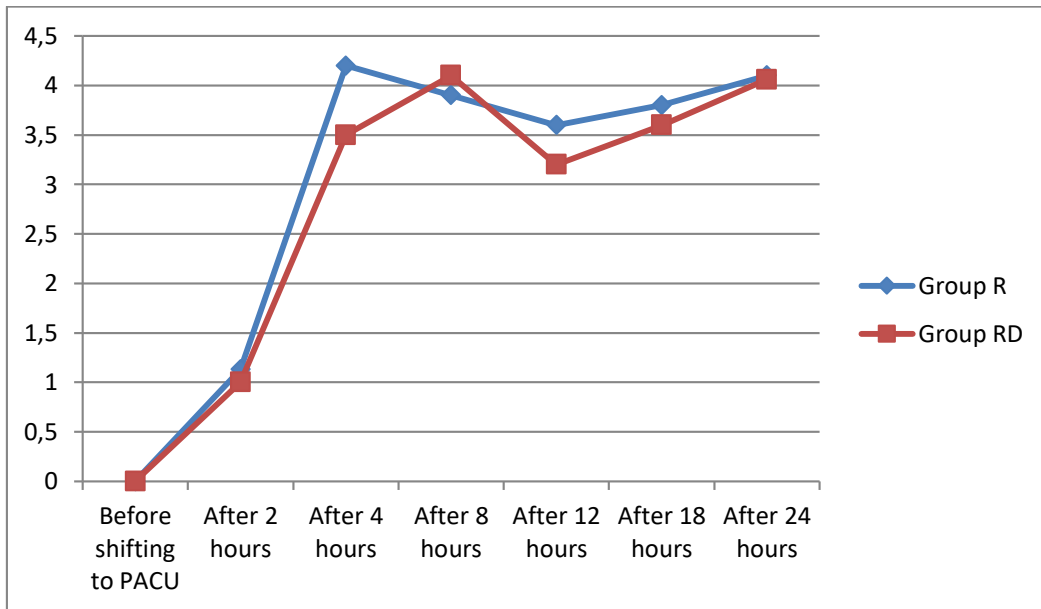
If the patients still complains of pain even after the administration of institutional postoperative analgesic regimen or VAS score was >4, intravenous tramadol at an incremental dose of 2mg/kg was given as rescue analgesia. The time to first onset of pain and the time of first request for analgesia during the first 24 hours were noted. (The time of TAP block to time of first rescue analgesia was considered as the duration of post-operative analgesia in our study.) The total consumption of tramadol over 24 hours was noted. Any sign of adverse effects of the technique like local site infection, hematoma formation local anaesthetic toxicity due to intravascular injection of anaesthetic noted.

Each patient was also assessed using a 5-point patient's satisfaction scale to evaluate the level of postoperative analgesic satisfaction. The study ended 24 hours after TAP block.

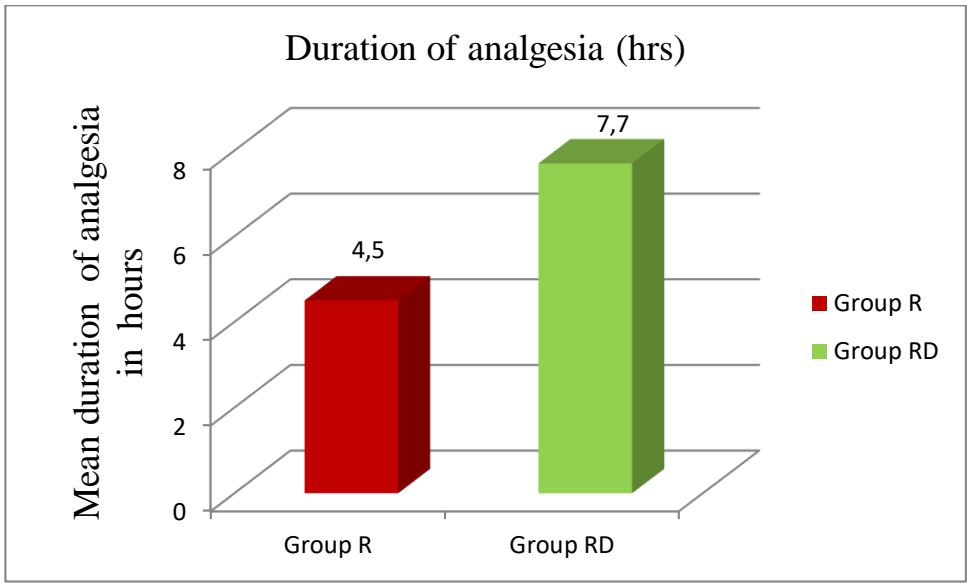
### Observations and Results

All recorded data were tabulated and statistically analysed by appropriate statistical test (ANOVA,chi-square test, student unpaired t test ). Result was analyzed using Graph Pad Prism version 7.0.

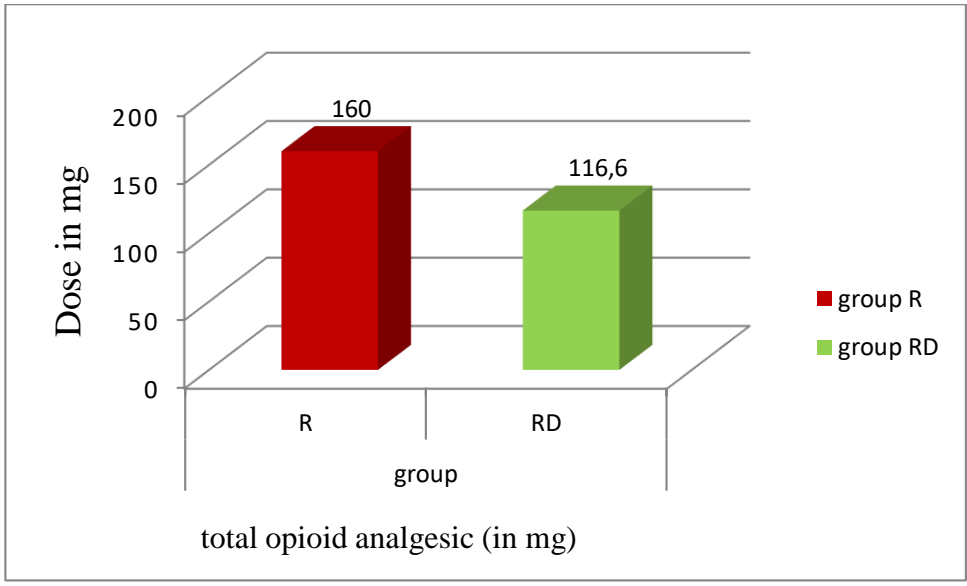
Results are as follows:



Graph 1- Vas score at different time interval in different groups



Graph 2 -Duration of analgesia between two groups



Graph 3-Total opioid requirement (in 24 hours) between two groups

Table 1:- Patient's Satisfaction Score

			Group R	Group RD	Total	P value
patient's satisfaction score	Highly dissatisfied	N	0	0	0	<.0001
		%	0.0%	0.0%	0.0 %	
	Dissatisfied	N	4	2	6	
		%	6.6%	3.3%	10.0%	
	Neither satisfied nor dissatisfied	N	1	0	1	
		%	1.6%	0.0%	1.6%	
Satisfied	N	13	5	18		
	%	21.6%	8.3%	30.0%		
Highly satisfied	N	12	23	35		
	%	20.0%	38.3%	58.33%		
Total		N	30	30	60	
		%	100.0%	100.0%	100.0%	

## Discussion

The demographic parameters like age, height, weight and sex distribution were comparable between Group R and Group RD. In our study, the duration of analgesia was  $4.5 \pm 0.56$  hours in Group R and  $7.7 \pm 0.53$  hours in Group RD. The difference between the two pair of groups were statistically significant (p value  $< 0.05$ ). our study similar to Xu L et al.<sup>6</sup> (2018), and they found duration of sensory blockade and first time of PCIA activation in the R+D group were respectively longer and later than in the R group ( $P < 0.05$ ). Similarly Bansal P et al.<sup>7</sup> (2020) found that addition of dexmedetomidine to ropivacaine resulted in a longer mean time to initial reporting of significant postoperative pain (6.6 vs. 5.03 h;  $P = 0.01$ ) and time to initial rescue analgesia (7.8 vs. 6.47 h;  $P = 0.03$ ) when compared with ropivacaine alone. Similarly one more study done by Sun Q et al.<sup>8</sup> (2017), and they found addition of dexmedetomidine to LA significantly prolonged the duration of the TAP block (WMD, 3.33; 95% CI, 2.85 to 3.82;  $P < 0.001$ ) compare to control group (local anaesthetic group).

The total opioids requirement (tramadol) in first 24 hrs post operatively was lower in Group RD in compare to Group R which was statistically significant . similar to our study Xu L et al.<sup>6</sup> (2018) found that total amount of sufentanil administered during the first 24 hours in the R+D group was significantly less than in the R group ( $P < 0.05$ ). similarly Sarvesh B et al.<sup>9</sup> (2018) found consumption of morphine over 24-h period is significantly less in Group (18 ml of ropivacaine + 5 µg/kg dexmedetomidine in 2ml NS) RD (14.5 mg) as compared to Group R (28.5 mg) (18 ml ropivacaine + 2ml NS).

We found that the average of mean VAS score in first 24 hrs was  $3.45 \pm 0.61$  in Group R and  $3.33 \pm 0.55$  in Group RD. similar to Our study Xu L, et al.<sup>6</sup> (2018) did a randomized study to evaluate efficacy of US-guided transversus abdominis plane block and rectus sheath block with ropivacaine and dexmedetomidine in elderly high-risk patients and found that the sensory blockade duration and the time to

first PCIA pump activation in the R+D group were longer than that of the R group ( $P < 0.05$ ). VAS scores at rest and during activity in the R+D group were lower than those in the R group at 2, 6, and 12 h after surgery ( $P < 0.05$ ). Similar to our result Sun Q et al.<sup>8</sup> (2017) found that the addition dexmedetomidine of significantly decrease pain scores eight hours postoperatively at rest (WMD,  $-0.78$ ; 95% CI,  $-1.27$  to  $-0.30$ ;  $P = 0.001$ ), 4 hours postoperatively on movement (WMD,  $-1.13$ ; 95% CI,  $-1.65$  to  $-0.60$ ;  $P < 0.001$ ). One more study done by Pan W et al.<sup>10</sup> (2020) found the sensory block duration and analgesia was statistically significant in the RD group compared with the R group ( $P < 0.05$ ).

We assessed Patient's Satisfaction Score at 24 hrs after surgery, using a 5-Point Patient's Satisfaction Scoring system to evaluate the level of postoperative analgesic satisfaction. Our assessment revealed that the no. of highly satisfied patients in Group R and Group RD was 12 and 23 respectively. Similarly, the no. of highly dissatisfied patients was nil in Group R and Group RD.

Dexmedetomidine is known to produce side effect such as bradycardia, hypotension, and sedation especially at higher doses. In our study, there were incidences of bradycardia following the administration of dexmedetomidine opposite to the Group R. This effect persisted from 2 hour to around 4 hour, but not associated with any hemodynamic instability. This bradycardia might be due to the postsynaptic activation of central  $\alpha_2$  ARs leading to decreased sympathetic activity and decreased heart rate. Similar to Our study Sarvesh B et al.<sup>9</sup> (2018) also found incidences of bradycardia following the administration of dexmedetomidine opposite to the control group. This effect persisted for 240 min, but not associated with any hemodynamic instability. Elnabtiy AM et al.<sup>11</sup> (2018) also reported bradycardia among patients of Group BD, in their study with an incidence of 11.5%.

The important outcome of our study is that the addition of dexmedetomidine to ropivacaine in TAP block provides prolonged postoperative analgesia and better pain control than ropivacaine alone, without any unwanted adverse effects. The duration of postoperative analgesia was prolonged, VAS was lower, patient's satisfaction score was improved and the need for rescue opioids (tramadol) was less when dexmedetomidine was added to ropivacaine.

### **Limitations**

There are few limitations of our study:-

1. The post-operative pain, which is a subjective experience and can be difficult to quantify objectively and compare.
2. The disadvantage of TAP block is the inability to block visceral pain, which can be substantial.

### **Conclusion**

This study concluded that bilateral ultrasound-guided TAP block is a better modality for post-operative analgesia after laparoscopic cholecystectomy when compare to control group (institutional analgesia). And addition of dexmedetomidine to ropivacaine was found to be superior to ropivacaine alone,

when given in TAP block after cholecystectomy for post-operative analgesia in first 24 hours as reflected by a lower mean VAS score, longer duration of analgesia, higher patient's satisfaction score along with lesser consumption of (tramadol) opioids.

## Reference

1. Bansal P, Sood D. Effect of dexmedetomidine as an adjuvant to ropivacaine in ultrasound-guided transversusabdominis plane block for post-operative pain relief in cesarean section. *Journal of Obstetric Anaesthesia and Critical Care*. 2018 ;8(2):79-82.
2. Carney J, McDonnell JG, Ochana A, Bhinder R, Laffey JG. The transversusabdominis plane block provides effective postoperative analgesia in patients undergoing total abdominal hysterectomy. *AnesthAnalg* 2008;107:2056-60
3. El-Dawlatly AA, Turkistani A, Kettner SC, Machata AM, Delvi MB, Thallaj A, et al. Ultrasound-guided transversusabdominis plane block: Description of a new technique and comparison with conventional systemic analgesia during laparoscopic cholecystectomy. *Br J Anaesth* 2009;102:763-7.
4. Elnabtity AM, Ibrahim M. Intraperitonealdexmedetomidine as an adjuvant to bupivacaine for postoperative pain management in children undergoing laparoscopic appendectomy: A prospective randomized trial. *Saudi journal of anaesthesia*. 2018 ;12(3):399-405.
5. Gaibullaeva, N. N. (2021). The role of clinical examination early diagnosis of glaucoma. *International Journal of Health & Medical Sciences*, 4(3), 333-337. <https://doi.org/10.31295/ijhms.v4n3.1745>
6. Mankikar MG, Sardesai SP, Ghodki PS. Ultrasound-guided transversusabdominis plane block for post-operative analgesia in patients undergoing caesarean section. *Indian J Anaesth* 2016;60:253-7.
7. McDonnell JG, O'Donnell B, Curley G, Heffernan A, Power C, Laffey JG. The analgesic efficacy of transversusabdominis plane block after abdominal surgery: A prospective randomized controlled trial. *AnesthAnalg* 2007;104:193-7.
8. Pan W, Liu G, Li T, Sun Q, Jiang M, Liu G, Ma J, Liu H. Dexmedetomidine combined with ropivacaine in ultrasound-guided transversusabdominis plane block improves postoperative analgesia and recovery following laparoscopic colectomy. *Experimental and Therapeutic Medicine*. 2020 ;19(4):2535-42.
9. Rafi AN, author. Abdominal field block: A new approach via the lumbar triangle. *Anaesthesia*. 2001;56:1024-6
10. Sarvesh B, Shivaramu BT, Sharma K, Agarwal A. Addition of Dexmedetomidine to Ropivacaine in subcostal transversusabdominis plane block potentiates postoperative analgesia among laparoscopic cholecystectomy patients: a prospective randomized controlled trial. *Anesthesia, Essays and Researches*. 2018 ;12(4):809-813.
11. Sun Q, Liu S, Wu H, Ma H, Liu W, Fang M, Liu K, Pan Z. Dexmedetomidine as an adjuvant to local anesthetics in transversusabdominis plane block: a systematic review and meta-analysis. *The Clinical journal of pain*. 2019 ;35(4):375-384.

12. Suryasa, I. W., Rodríguez-Gómez, M., & Koldoris, T. (2021). Get vaccinated when it is your turn and follow the local guidelines. *International Journal of Health Sciences*, 5(3), x-xv. <https://doi.org/10.53730/ijhs.v5n3.2938>
13. Xu L, Hu Z, Shen J, McQuillan PM. Efficacy of US-guided transversusabdominis plane block and rectus sheath block with ropivacaine and dexmedetomidine in elderly high-risk patients. *Minerva anesthesiologica*. 2017 ;84(1):18-24.