

**How to Cite:**

Nivetha, M., Dixit, A., Jaiswal, P., Dwivedi, R., & Yadav, A. S. (2022). Effectiveness of three-in-one nerve block for post-operative analgesia after hip hemiarthroplasty. *International Journal of Health Sciences*, 6(S5), 9633–9643. <https://doi.org/10.53730/ijhs.v6nS5.10734>

## **Effectiveness of three-in-one nerve block for post-operative analgesia after hip hemiarthroplasty**

**Dr. Nivetha M**

Postgraduate student, Department of Anaesthesiology, Shyam Shah Medical College, Rewa, MP, India

**Dr. Amey Dixit**

Senior resident, Department of Anaesthesiology, Shyam Shah Medical College, Rewa, MP, India

**Dr. Priyanka Jaiswal**

Senior resident, Department of Anaesthesiology, Shyam Shah Medical College, Rewa, MP, India

**Dr. Rajeev Dwivedi\***

Professor, Department of Anaesthesiology, super speciality hospital Shyam Shah Medical College, Rewa, MP, India

\*Corresponding Author

**Dr. Avtar Singh Yadav**

Professor, Department of Anaesthesiology, Shyam Shah Medical College, Rewa, MP, India

**Abstract**--Background and aims: Hip fractures typically affect elderly patients with multiple co-morbidities. Pain control can be difficult, requiring intensive nursing and physician care as elderly patients may manifest cardiovascular and respiratory complications from opiate administration. The aim of the study was to compare three in one (3-in-1) nerve block with control regarding its analgesic efficacy in patients following hip hemiarthroplasty surgeries. Materials and Methods: Sixty patients of ASA status I or II undergoing hip hemiarthroplasty surgeries under subarachnoid block were divided into 2 groups to receive 3-in-1 nerve block (Group 1) and Control (Group 2). Each patient was assessed for VAS score, tramadol consumption postoperatively in the PACU. Results: There was significant difference between the group 3-in-1 nerve block and control group regarding the postoperative analgesia, total rescue analgesia consumption in 24 h postoperative. The mean VAS score at 2, 4, 6, 8 h and total rescue analgesia consumption in 24 h were higher in

control group which was statistically significant (p value<0.05). Conclusion: Three in one nerve block provide better postoperative analgesia after hip hemiarthroplasty surgeries when compare to control.

**Keywords**---Three in one nerve block, Postoperative analgesia, hemiarthroplasty.

## **Introduction**

Hip fracture is a common fracture type in the adult population which occupies hospital beds mostly and has high morbidity<sup>1</sup>. Trauma and pain trigger a complicated stress response characterized by inflammatory and hormonal changes that might result in immune suppression, impairing wound healing and fracture repair and hence impeding mobility in persons with already compromised muscle function.<sup>2</sup> Post-operative pain after hip replacement surgery may potentially hinder post-operative physiotherapy and early mobilization<sup>3</sup>. Patients who will undergo total hip surgeries are usually elderly and they have limited cardiac and pulmonary reserve.

Most commonly used post-operative analgesics after hip replacement surgeries are opioids, NSAIDS, epidural analgesia and peripheral nerve blocks. Lumbar plexus blockade provides high quality analgesia as the femoral nerve supplies the anterior hip joint capsule as well as the proximal femur, the quadriceps, iliacus and pectineus muscles. Lumbar plexus block is superior to systemic morphine administration and has less adverse effects compared to epidural anaesthesia<sup>1</sup>. 3-in-1 nerve block is commonly used for anesthesia and analgesia in hip surgeries. It involves visual identification of the femoral nerve sheath and subsequent infiltration of anesthetic. This nerve block is a simple, safe and time efficient maneuver providing rapid and effective anesthesia.<sup>4-7</sup> 3-in-1 nerve block was first proposed by Winnie et al who considered that the femoral, lateral femoral cutaneous and obturator nerve could be blocked at the same time based on the theory that fascial sheath which extends up to the lumbar plexus.

Bin Yu et al.<sup>8</sup> conducted a prospective study demonstrated that 3-in-1 nerve block could achieve a success rate of 81% block of the femoral nerve, 96% of lateral femoral cutaneous nerve and 4% of the obturator nerve. In 1989, ultrasonography was first utilized to confirm the location of the needle and observe the spread of local anaesthetic while performing nerve blocks. Subsequently, ultrasound-guided blocks have become increasingly popular with clinicians due to the precise action and faster onset of the block. In view of our current study, we planned to compare the practicality, analgesic efficacy, complications of ultrasound guided three in one nerve block in elderly patient undergoing hip hemiarthroplasty.

## **Material Method**

This prospective, randomized and controlled study was carried out in the Department of Anaesthesiology, Shyam Shah Medical College, Madhya Pradesh,

from March 2020 to February 2021, after getting clearance from Institutional Ethics Committee. 60 adult patients of both sex between the age group of 50-75 years with an ASA grade I and II were included in study. Patients who refused to give consent, patients who were suffering from psychological illnesses such as language impairment, mental disease, or dementia, patients with significant systemic diseases like asthma, diabetes, hypertension, and cardiovascular disease, and patients contraindications to 3-in-1 nerve block were excluded from study. The patients fulfilling the selection criteria were randomized using a computer-based randomization software, in two groups of 30 patients each.

**Group 1 (3 in 1 Block)** received USG guided three in one nerve block with 30 ml of 0.2% ropivacaine at the end of the surgery.

**Group 2 (Control)** received only a standard analgesic regimen.

A detailed history of all selected patients was taken. A thorough pre-anaesthetic evaluation including the airway, back of the patient and site of block assessment were performed. The patients were explained about the entire procedure, informed consent was taken, in a language of their understanding. They were also educated about the visual analogue scale (VAS) and patient's satisfaction scale. Thereafter, they were shifted to the operation theatre. Intravenous line was secured. Monitors was attached and baseline parameters viz heart rate, systolic and diastolic blood pressure, mean arterial pressure, SpO<sub>2</sub>, ECG tracings were recorded. Subarachnoid block with Inj. bupivacaine (0.5%) heavy 2.5ml at L3-L4 spinal level via 25-gauge Quincke's spinal needle in sitting position was given to all patients. Standard hemodynamic monitoring was done.

In patients belonging to Group 1, and patient was kept in supine position with legs slightly abducted the skin over the femoral crease was disinfected. The ultrasound is placed to the right of the patient's bed, ultrasound probe is placed on the patient groin with the probe indicator pointing towards the patient's right. The inguinal ligament was noted as a linear hyperechoic structure, and as the probe is slide caudad, the large femoral vein and the non-compressible femoral artery were identified. Lateral to these structures, the femoral nerve sheath was visualized and appears as a hyperechoic triangular structure. A small skin wheal over the target site was made, needle was inserted 2 cm distal to the inguinal ligament in a lateral to medial direction at a 30-degree angle. Once the needle comes into view on the ultrasound monitor, the tip is positioned as close as possible to the femoral nerve and aspiration can be done to insure there was no infiltration into a vessel. After a negative aspiration, 30 ml of 0.25% ropivacaine is injected with necessary needle reposition.

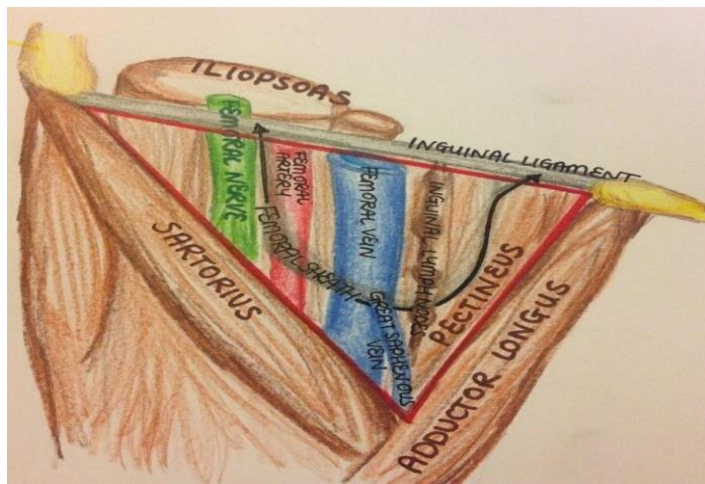


Figure 1: Femoral triangle anatomy

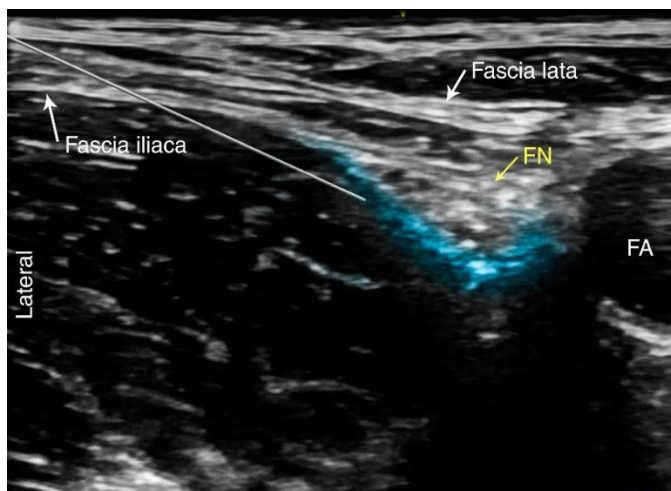


Figure 2: USG guided 3-in-1 nerve block

After completion of the surgical procedure and block, patients were transferred to the post anaesthesia care unit (PACU). Pain severity was assessed employing a Visual Analogue Scale. VAS score was recorded at 0, 2, 4, 6, 8, 12, 18 and 24 hours after block. When VAS score became more than 4 or the patient first demand for analgesia that time was noted. Inj. tramadol 100 mg IV was given as rescue analgesic. At the end of 24 h, duration of analgesia and total tramadol consumption was noted.

Any signs of adverse effects of the technique like local site infection, hematoma formation, local anaesthetic toxicity due to intravascular injection of anaesthetic agents (like dizziness, tinnitus, perioral numbness and tingling, lethargy, seizures, signs of cardiac toxicity like atrioventricular conduction block, arrhythmias, myocardial depression and cardiac arrest) were noted and prompt action were taken in case such situations. Neurological assessment was

performed in all the patients before hospital discharge. The study ended 24 hours after block placement.

### **Statistical analysis**

All recorded data were tabulated and statistically analysed by appropriate statistical test (ANOVA, post hoc tukey's HSD test and chi-square test). The data collected was analyzed, continuous variables were presented as mean with standard deviation (SD) and categorical variables were presented as frequency and percentages. Student's t-test was used for testing the significance of mean in both the groups. Qualitative data was analyzed using Chi- square test. All the statistical results were considered significant at p value < 0.05

## Results

From table 1 there was no significant difference between the groups with respect to demographic variables such as age, height, sex, duration of surgery.

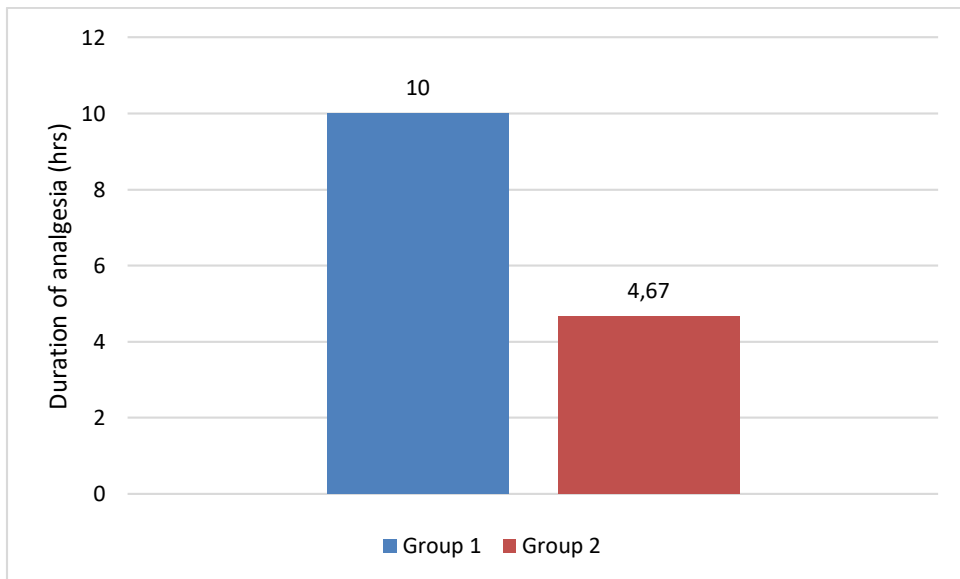
Table 1: Demographic and surgical data of the patients

Parameters	Group 1	Group 2	P value
Age in years (Mean $\pm$ SD)	60 $\pm$ 5	59 $\pm$ 5	0.454
Height in cm (Mean $\pm$ SD)	160 $\pm$ 8	162 $\pm$ 7	0.373
Sex ratio (F:M)	25.05.00	23.07	0.814
Duration of surgery (in mins) (Mean $\pm$ SD)	136.1 $\pm$ 9	134 $\pm$ 16	0.53

From table 2 duration of analgesia was longer in group 1 compare to group 2 and difference was statistically significant. ( $p < 0.0001$ )

Table 2: Duration of analgesia

Parameters	Group 1	Group 2	P value
Duration of analgesia (in hours) (Mean $\pm$ SD)	10 $\pm$ 3.02	4.67 $\pm$ 1.32	<0.0001

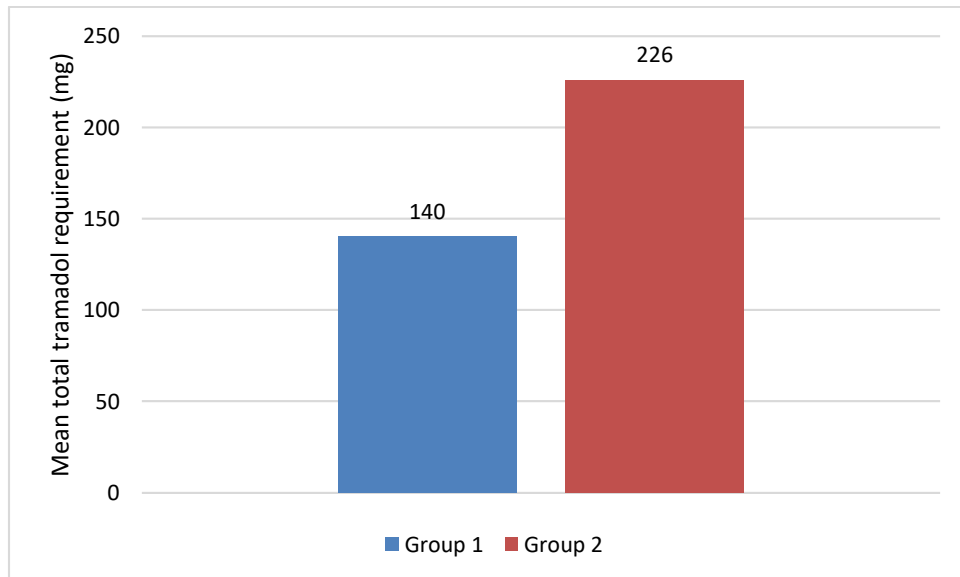


Graph 1: Comparison of duration of analgesia between two groups

From table 3 evident that the mean first rescue analgesic (tramadol) requirement was higher in group 2 compare to group 1 and difference was statistically significant. ( $p < 0.0001$ )

Table 3: Total tramadol requirement (in first 24 hours)

Parameters	Group 1	Group 2	P value
Total tramadol requirement (mg)	140 ± 62.1	226 ± 63	<0.0001

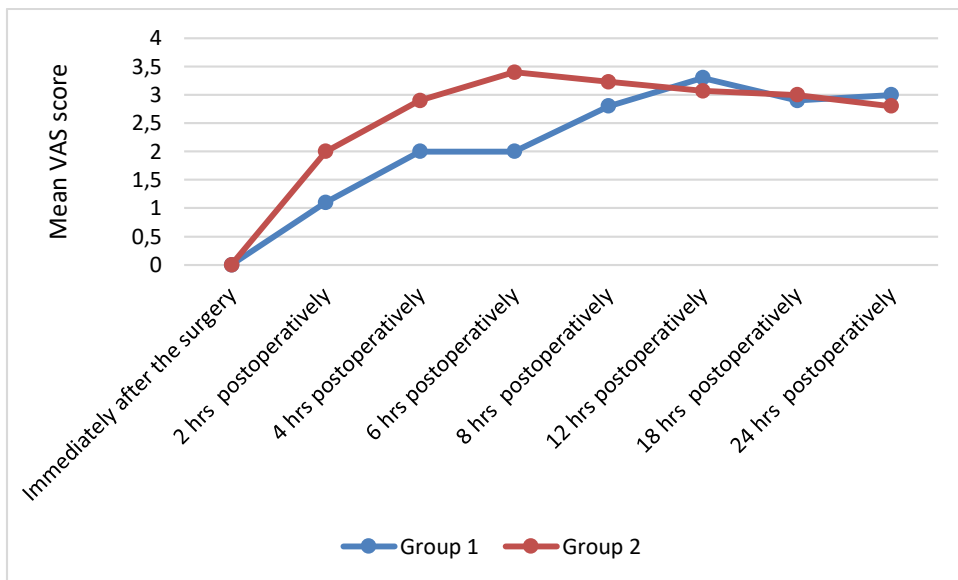


Graph 2: Total tramadol requirement between two groups

From table 4 evident that VAS score was higher in group 2 compare to group 1 at 0,2,4,8 hours and difference was statistically significant. ( $p < 0.0001$ ). At 12, 18 and 24 hours difference become statistically comparable.

Table 4: VAS score at different time interval

Parameters	Group 1 (Mean±SD)	Group 2 (Mean±SD)	P value
Immediately after the surgery	0	0	-
2 hrs postoperatively	1.1 ± 0.9	2 ± 1	<0.0001
4 hrs postoperatively	2 ± 0.5	2.9 ± 1.2	<0.0001
6 hrs postoperatively	2 ± 0.4	3.4 ± 1	<0.0001
8 hrs postoperatively	2.8 ± 0.8	3.23 ± 0.7	0.033
12 hrs postoperatively	3.3 ± 1	3.07 ± 0.91	0.25
18 hrs postoperatively	2.9 ± 0.9	3 ± 0.9	0.58
24 hrs postoperatively	3 ± 0.9	2.8 ± 0.7	0.23



Graph 3: Comparison of VAS score between two groups

We assessed the Patient's Satisfaction Scale score 24 hours after surgery, using a 5-Point Patient's Satisfaction Score to evaluate the level of postoperative analgesia satisfaction (Table 5). The difference in the patient satisfaction score between groups was statistically significant ( $p$ -value  $<0.0001$ ). There were no significant adverse effects or complications noted in any of the two groups.

Table 5: Patient satisfaction score

Patient satisfaction scale score	Group 1		Group 2		p-values
	N	%	N	%	
Highly Satisfied	11	36.7%	0	0	$<0.0001$
Satisfied	12	40%	6	20.0%	
Neither Satisfied nor Dissatisfied	5	16.7%	6	20.0%	
Dissatisfied	2	6.7%	14	46.7%	
Highly Dissatisfied	0	0	4	13.3%	
TOTAL	30	100%	30	100%	

## Discussion

Multimodal analgesia with nerve block has been advised to minimize difficulties and undesirable effects associated with spinal anaesthesia and intravenous opioid analgesia during the post-operative phase after lower limb joint arthroplasty. The 3-in-1 nerve block is one of the most prevalent nerve block procedures utilized for anaesthesia and analgesia in hip surgery.

Jerrold et al.<sup>9</sup> conducted a study comparing fascia iliaca and three-in-one nerve blocks in peripheral nerve blocks have grown in popularity as a technique for treating pain after lower-extremity surgical operations. There were no variations

in analgesic needs or pain ratings. The 3-in-1 nerve block group reported a more rapid onset of anaesthesia.

Our study aimed to relieve patients' pain while having a negligible impact on muscular strength. In the first 24 hours, the average mean VAS score was  $3.07 \pm 0.98$  in Group 1, and  $2.8 \pm 0.71$  in Group 2. This research discovered a significant difference in VAS ratings between patients receiving 3-in-1 nerve block and control, showing that the 3-in-1 block had higher analgesic effectiveness. Dureja et al.<sup>10</sup> before the surgery, the pain was measured using the VAS scale with passive hip flexion in both groups, i.e. (8-9). After 30 minutes, Group F had two (2-3) while Group D had six (5-7). When these groups were compared, the difference was statistically significant.

Pandya et al.<sup>7</sup> (2014) recorded Visual Analog Scale (VAS) values throughout rest and treatment. They discovered difference in sensory or motor blockade between the two groups. Yun et al.<sup>11</sup> (2009) in the 3-in-1 block group, the visual analogue scale score was lower ( $P=0.001$ ), and patient acceptability was higher than in the intravenous alfentanil group. The time required for the first rescue analgesia (FRA) was significantly higher in Group 1 ( $10.00 \pm 3.02$ ) h than in Group 2 ( $4.67 \pm 1.32$ ) h ( $p < 0.05$ ). In comparison to Group 2, Group 1 had a significantly longer duration of analgesia ( $p < 0.05$ ).

In our study, the total tramadol requirement in the first 24 hours post-operatively was ( $140 \pm 62$ ) mg in Group 1 and ( $226.6 \pm 63.9$ ) mg in Group 2. The necessity for tramadol was greater in Group 3 than in Group 1, which was statistically significant ( $p$  value 0.05). Similar results were observed in Pandya et al. in 2014 in their study meantime for first demand of rescue analgesic was (duration of analgesia) was  $11.93 \pm 3.02$  hours in three in one group.<sup>11</sup>

In a study by Fletcher et al.<sup>12</sup> patients receiving 3-in-1 nerve blocks recorded a faster time to reach the lowest pain score 2.88 hours versus 5.81 hours for control patients receiving intravenous morphine. Also, nerve block recipients required significantly less morphine per hour to control their pain 0.49 mg/hr versus 1.2 mg/hr.

In our study, group 1 patients were highly satisfied than group 2, no patients were satisfied in group 3. Similar results were reported by Mcrae et al.<sup>13</sup> where patients in the 3-in-1 group experienced a greater decrease in their median pain score ( $p=0.025$ ) than those in the control group.

## **Conclusion**

Three in one nerve block provide better postoperative analgesia after hip hemiarthroplasty surgeries when compare to control.

## References

1. Antonis MS, Chandwani D, McQuillen K. Ultrasound-guided placement of femoral 3-in-1 anesthetic nerve block for hip fractures. *Academic Emergency Medicine*. 2006;13:S122–3.
2. Deniz S, Atım A, Kürklü M, Çaycı T, Kurt E. Comparison of the postoperative analgesic efficacy of an ultrasound-guided fascia iliaca compartment block versus 3 in 1 block in hip prosthesis surgery. *Agri*. 2014 Jan 1;26(4):151-7.
3. Dureja J, Chaudhry G, Surya, Dureja S. Comparison of fascia iliaca compartment block with intramuscular diclofenac sodium acute pain relief in emergency room in patients with fracture femur. *Int J Contemp. Med* 2016;3(4):1119-1122.
4. Fletcher AK, Rigby AS, Hayes FL. Three-in-one femoral nerve block as analgesia for fractured neck of femur in the emergency department: a randomized, controlled trial. *Annals of Emergency Medicine*. 2003;41:227–33.
5. Khidoyatova, M. R., Kayumov, U. K., Inoyatova, F. K., Fozilov, K. G., Khamidullaeva, G. A., & Eshpulatov, A. S. (2022). Clinical status of patients with coronary artery disease post COVID-19. *International Journal of Health & Medical Sciences*, 5(1), 137-144. <https://doi.org/10.21744/ijhms.v5n1.1858>
6. Marhofer P, Schrogendorfer K, Koinig H, Kapral S, Weinstable C, Mayer N. Ultrasoundographic guidance improves sensory block and onset time of three-in-one blocks. *Anesthesia and Analgesia*. 1997;85:854–7.
7. McRae PJ, Bendall JC, Madigan V, Middleton PM. Paramedic-performed fascia iliaca compartment block for femoral fractures: a controlled trial. *J Emerg Med* 2015;48(5):581-9.
8. Möller T, Benthaus S, Huber M, Bentrup I, Schofer M, Eberhart L, WULF H, MORIN A. A randomized and observer blinded comparison of continuous femoral block and fascia iliaca compartment block in hip replacement surgery. *Journal of Anesthesia & Clinical Research*. 2013;4.
9. O'Donnell BD, Mannion S. Ultrasound-guided femoral nerve block, the safest way to proceed? *Reg Anesth Pain Med*. 2006;31:387–8.
10. Pandya M, Jhanwar S. Comparative study of fascia iliaca compartment block and three in one block for post-operative analgesia in patients undergoing lower limb orthopedic surgeries. *Indian J Pain*. 2014;28(3):129
11. Shukla U, Jahan M, Naaz S, Srivastava S. USG guided femoral nerve block vs fascia iliaca compartment block as post-operative analgesia in hip fracture patients. *International Journal of Research in Medical Sciences*. 2018 Sep;6(9):3057.
12. Snoeck MM, Vree TB, Gielen MJ, Lagerwert AJ. Steady state bupivacaine plasma concentrations and safety of a femoral “3-in-1” nerve block with bupivacaine in patients over 80 years of age. *International Journal of Clinical Pharmacology and Therapeutics*. 2003;41:107–13.
13. Suryasa, I. W., Rodríguez-Gámez, M., & Koldoris, T. (2021). Get vaccinated when it is your turn and follow the local guidelines. *International Journal of Health Sciences*, 5(3), x-xv. <https://doi.org/10.53730/ijhs.v5n3.2938>
14. Wallace JB, Andrade JA, Christensen JP, Osborne LA, Pellegrini JE. Comparison of fascia iliaca compartment block and 3-in-1 block in adults undergoing knee arthroscopy and meniscal repair. *AANA J*. 2012;80(4 Suppl):S37-44.

15. Yu B, He M, Cai GY, Zou TX, Zhang N. Ultrasound-guided continuous femoral nerve block vs continuous fascia iliaca compartment block for hip replacement in the elderly: A randomized controlled clinical trial (CONSORT). *Medicine*. 2016;95(42).