

How to Cite:

Solanki, K., Barai, D., Gupta, A., Reddy, D. R. M., & Patel, K. (2022). Correlation of findings of CT and MRI in skull lesions. *International Journal of Health Sciences*, 6(S5), 10188–10198.
<https://doi.org/10.53730/ijhs.v6nS5.10768>

Correlation of findings of CT and MRI in skull lesions

Kunal Solanki

Professor, Department of Radiodiagnosis, S.B.K.S Medical Institute & Research Centre, Sumandeep Vidyapeeth, Pipariya, Waghodia, Vadodara, Gujarat, India

Durgaprasad Barai*

Resident, Department of Radiodiagnosis, S.B.K.S Medical Institute & Research Centre, Sumandeep Vidyapeeth, Pipariya, Waghodia, Vadodara, Gujarat, India
*Corresponding author

Akshay Gupta

Resident, Department of Radiodiagnosis, S.B.K.S Medical Institute & Research Centre, Sumandeep Vidyapeeth, Pipariya, Waghodia, Vadodara, Gujarat, India

D Reddi Mithun Reddy

Resident, Department of Radiodiagnosis, S.B.K.S Medical Institute & Research Centre, Sumandeep Vidyapeeth, Pipariya, Waghodia, Vadodara, Gujarat, India

Kundan Patel

Resident, Department of Radiodiagnosis, S.B.K.S Medical Institute & Research Centre, Sumandeep Vidyapeeth, Pipariya, Waghodia, Vadodara, Gujarat, India

Abstract--Introduction: Skull vault lesions are often asymptomatic and are usually discovered incidentally during computed tomography or magnetic resonance imaging of the brain. Calvarial lesions can be benign or malignant. Calvarial lesions may arise from skull bones or can be secondary to invasion of skull vault from brain or scalp based lesions. Objectives: The aim of this study is to study the role of CT and MRI in evaluating skull vault lesions. Material and methods: 50 patients with skull vault lesions were considered in our study. The patients underwent CT and MRI scans of head. Results: Among 50 patients, most common skull vault lesions were Skull metastases, osteoma and epidermoid cyst. Chordoma, osseous hemangioma and intrasosseous meningioma were the least encountered lesions. Conclusion: This article has demonstrated that CT and MRI have complementary roles in determining the nature of skull lesions. CT is the most accurate method for evaluating bone destruction of the inner and outer tables while MRI is best to assess marrow involvement, soft tissue component and invasion of adjacent tissues.

Keywords---CT, MRI, skull, osseous, calvarial, calcification.

Introduction

Frontal, temporal, parietal and occipital, zygoma and sphenoid bones make up the skull vault. It is made up of inner and outer tables, with diploic space between them ^[1]. Calvarial lesions may arise from skull bones or can be secondary to invasion of skull vault from brain or scalp based lesions. Most of the calvarial lesions are benign but it is important to know imaging features of malignant lesions as they require aggressive management.

Skull lesions can be lytic or sclerotic, single or multiple with varied composition; they may arise from osteogenic, chondrogenic, fibrogenic, vascular and/or other elements of bone. Calvarial lesions are radiologically evaluated with CT and MRI. Plain radiographs play a lesser role, but are useful in the assessment and follow-up of lytic lesions such as multiple myeloma; it may also be the initial modality on which a lesion is found^[2]. The differential diagnosis of calvarial lesions is important in deciding management if the lesion needs biopsy, conservative treatment or surgical intervention. In this article, we will review the imaging features of the skull lesions detected in my study.

Material and Methods

This was a non-interventional, cross sectional study of 50 patients undergoing CT and MRI scan of head in Dhiraj hospital from from July 1, 2021 to March 30, 2022. Each patient's hospital number, age, sex, chief complains, past medical and surgical history, renal status for contrast study were noted. Confidentiality of the patient's information were maintained.

Inclusion criteria-

- Patients undergoing CT and MRI scan of head for complains of headache, clinical suspicion of skull lesion, known case of skull lesion

Exclusion criteria-

- Patients who gave negative consent for the study.
- Uncooperative patients
- Patients in whom CT scan is contraindicated, eg. Pregnancy

Description of tools -

- Siemens 16 Slice CT
- Siemens 1.5 tesla MRI

Along with axial images, coronal plane multiplanar reformation (MPR) images were reconstructed.

Results

In my study the number of cases I encountered are as follows

Cases	Number	%
Fibrous dysplasia	5	10
Osteoma	7	14
Langerhans cell histiocytosis	3	6
Osseous hemangioma	2	4
Intraosseous meningioma	2	4
Paget disease	3	6
Multiple myeloma	3	6
Chordoma	2	4
Metastases	10	20
Epidermoid cyst	7	14
Dermoid cyst	6	12
Total cases	50	100

Most common lesions encountered were metastases 10 (20%), osteoma 7 (14%), epidermoid cyst 7 (14%). Chordoma, osseous hemangioma and intraosseous meningioma were the least encountered lesions.

3 cases of Paget's disease were encountered with none of them showing sarcomatous transformation.

Most of the encountered lesions originated from within the calvaria whereas meningioma invade the skull vault secondarily.

Multiple lesions were more frequent in some malignant conditions, such as multiple myeloma and metastases.

Discussion

A good knowledge of normal anatomy and normal variants are important for recognition of calvarial lesions and their pathologic characteristics. There are no specific features of many of these lesions, however topographic and imaging characteristics (sclerotic or lytic or mixed, solitary or multiple, diffuse or focal) along with clinically relevant data (sex, age, history of trauma, history of surgery, neoplastic lesion) can help to narrow down the differentials.

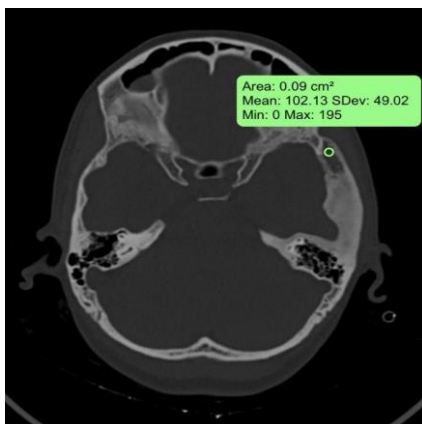
Radiological characteristics to evaluate skull lesion

Site of origin	Diploe, outer table, inner table, scalp
Number	Solitary, multiple
Size	Large, small
Margin	Ill defined, well defined, wide or narrow zone of transition
Bone destruction pattern	Moth eaten, geographic, permeated
Periosteal reaction	Interrupted, uninterrupted
Local extension	Extracranial, intracranial
Matrix type	Cartilage or bone forming, connective tissue, fatty/cystic/ hemorrhagic component

Individual lesions:

1. Fibrous dysplasia

Fibrous dysplasia is a developmental anomaly which involves replacement of normal bone marrow by fibroosseous tissue. CT scan showed ground-glass matrix (HU + 70 to 130) appearance which is characteristic for fibrous dysplasia. Intralesional calcification was seen in few patients. On MRI the lesion appeared hypointense on T1 and hyperintense on T2 depending upon fibrous tissue, cellular, cystic and hemorrhagic components. Variable post contrast enhancement was noted. Frontal and temporal bones were commonly involved.

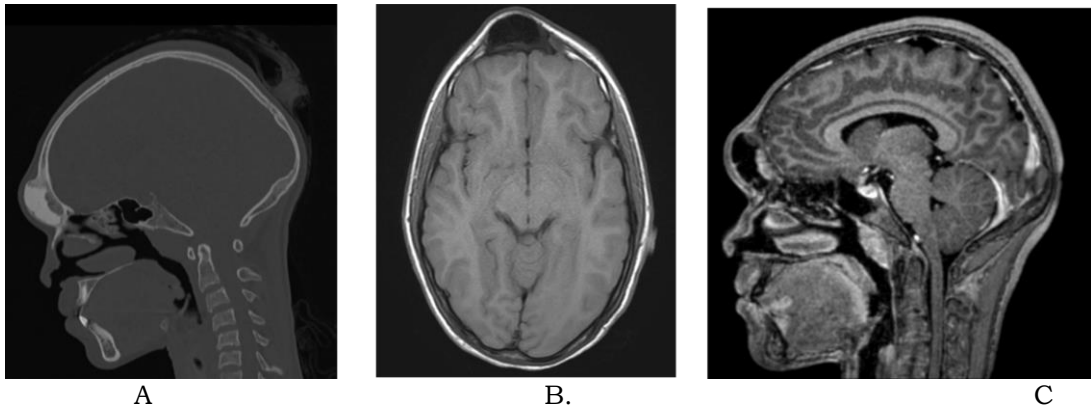


Fibrous dysplasia

Axial CT image with bone window shows expanded mass localized in squamous part of left temporal bone with characteristic ground glass matrix.

2. Osteoma

Osteoma is a juxta-cortical tumour made up of well-differentiated compact or cancellous bone [1]. On CT, it appeared as a well-defined homogenous and sclerotic lesion. Few of the lesions were seen extending into the ethmoid and frontal sinuses. On MRI, the lesion appeared hypointense on T1 with variable appearance on T2 depending on the amount of compact and cancellous bone.

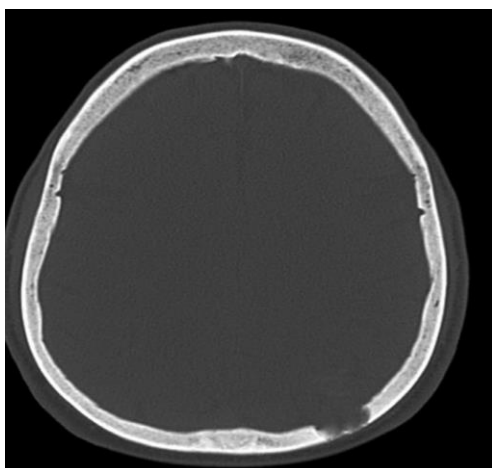


Osteoma

Sagittal head CT image(a) show a juxta-cortical lesion along the outer table of the frontal bone. Axial T1-weighted (b) and sagittal post-contrast T1-weighted (c) images depict the sclerotic/osteoblastic nature of this lesion. The lesion shows well-defined margins without significant enhancement.

3. Langerhans cell histiocytosis

Eosinophilic granuloma is the most common form of LCH which mainly affects the skull [6]. Frontal and parietal regions were commonly involved. On radiographs, there may be one or multiple well-defined punched-out osteolytic lesions [4]. On CT, LCH appeared as an osteolytic lesion with bevelled edges and a button sequestrum. In some cases multiple lytic lesions coalesce giving appearance of geographic map. Soft tissue component along with extradural and extracranial extension was also seen. On MRI it appeared iso to hypointense on T1 and hyperintense on T2 with enhancement on postcontrast images with extensive bone marrow edema.

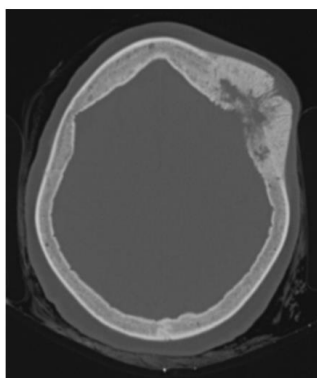


Langerhans cell histiocytosis.

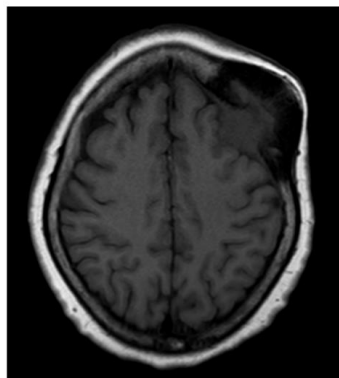
Axial CT scan of skull demonstrate an osseous destructive lesion in the left occipital calvarium with bevelled edges

4. Osseous Hemangioma

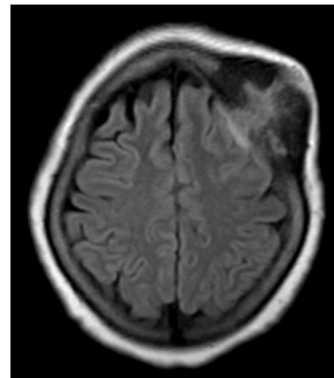
The skull is the second most frequent location, after the spine and commonly involves frontal and parietal bones [3]. CT showed a lytic lesion with intralesional spicules, surrounded by sclerosis in some and showed homogenous post contrast enhancement. Osseous hemangioma on MRI appears isointense on T1 and hyperintense on T2 with centripetal contrast enhancement. Few hypo to hyperintense spots were seen within lesion due to fat or iron.



A



B



C

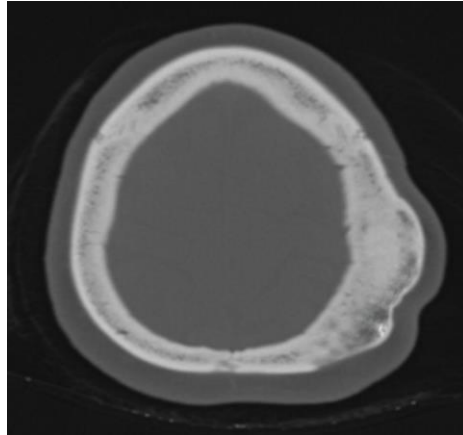
Osseous hemangioma.

Axial CT image (A) shows a well circumscribed osteolytic lesion with intralesional spicules.

The lesion appears isointense on T1 Axial T1 weighted MR image(B) and enhances intensely after administration of contrast medium (C).

5. Intraosseous Meningioma

Intraosseous meningioma is the most common type of primary extradural meningiomas^[4] CT scan showed osteosclerotic lesion with irregular and spiculated margins. On MRI the lesion appears hypointense on T1 and variable on T2 and does not show significant post contrast enhancement. Few of the lesions showed meningeal enhancement.

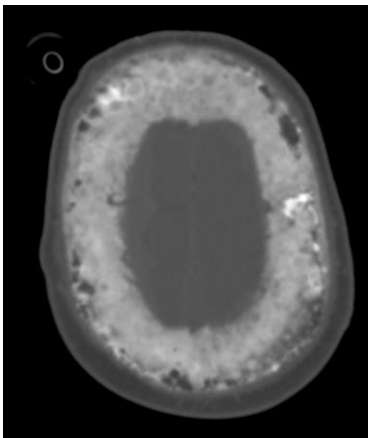


Intraosseous meningioma.

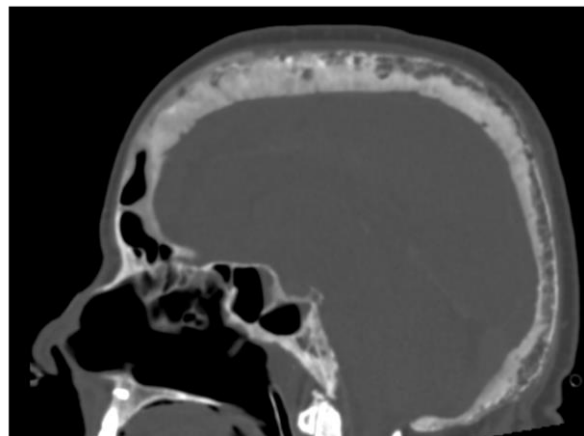
Axial CT image shows sclerotic lesion of left parietal bone.

6. Paget Disease

Paget disease of the bone is a chronic metabolic bone disorder characterized by excessive abnormal bone remodeling. Lytic lesions, coarsened trabeculae and bony enlargement was seen on CT depending on the stage of the lesion. On MRI, dominant signal similar to that of fat was noted followed by speckled appearance (low signal on T1 and high signal on T2). One of the case showed platybasia or basilar impression which is a complication of Paget disease.



A



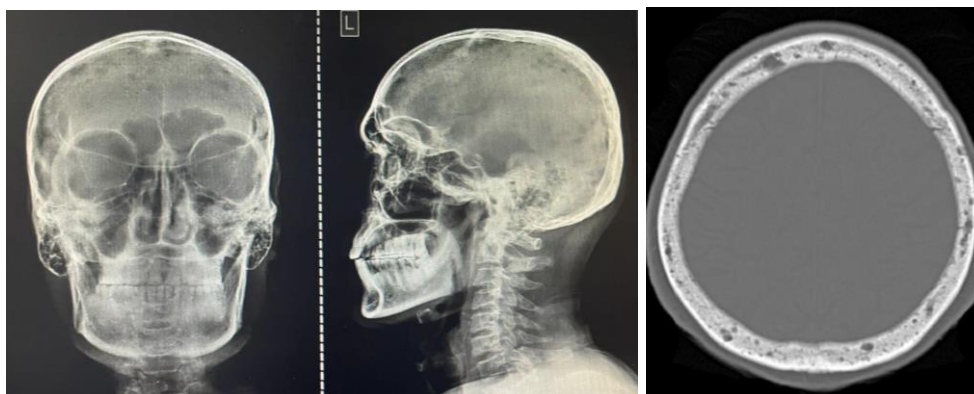
B

Paget disease

Axial and sagittal head CT (a, b) images show increased cortical density and trabecular thickening.

7. Multiple myeloma

Multiple myeloma is a malignant bone marrow disorder characterised by monoclonal proliferation of plasma cells. [1] Skull x ray showed punched-out osteolytic lesions. These lesions may coalesce. Bone marrow involvement was observed on MRI with salt and pepper pattern being the most common. On CT they appeared as multiple lytic lesions with no sclerotic rim. On MRI the lesion appeared hypointense on T1, hyperintense on T2 and showed post contrast enhancement.

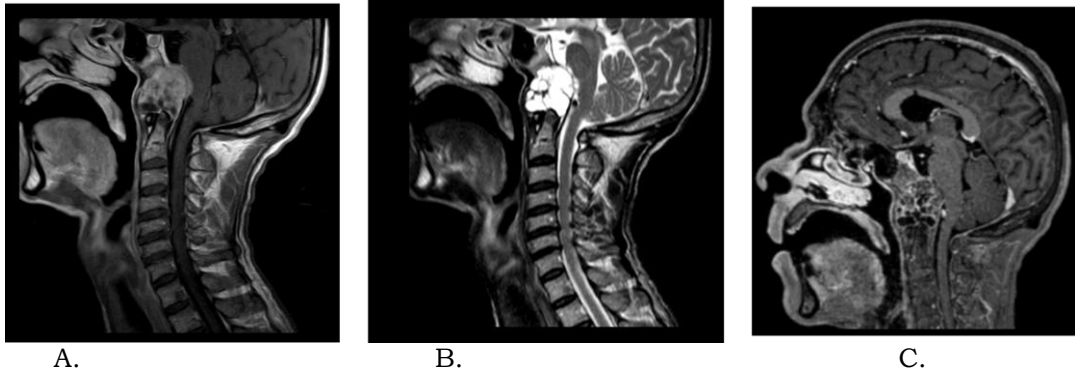


Multiple myeloma

Radiograph and CT scan shows multiple small round osteolytic lesions ("punched-out" lesions) relatively uniform in size.

8. Chordoma

Chordoma is a malignant, locally aggressive tumour that originates from remnants of the notochord [5]. On MRI chordomas appeared as intermediate to hypointense on T1 with a small foci of hyperintensity in a case representing intratumoral hemorrhage. Heterogeneous enhancement with honeycomb pattern was observed on post contrast imaging. On CT it appeared as a lytic, expansile destructive lesion.



Clival chordoma

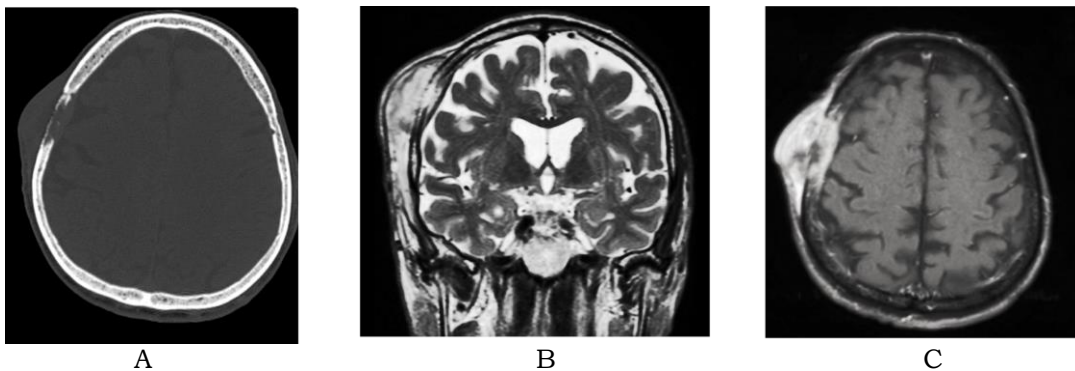
Intermediate signal on Sagittal T1 weighted image (A)

Hyperintense on Sagittal T2 weighted image (B)

Heterogeneous avid enhancement with homeycomb pattern on post contrast image(C)

9. Metastases

Calvarial metastases are usually secondary to breast, lung, prostate, kidney and thyroid cancer in adults and to neuroblastoma or sarcomas in children.^[6] Metastases may have an osteolytic, sclerotic or mixed pattern depending on the primary tumour. Lytic lesions were commonly observed. Sclerotic metastases were found in a patient with prostate cancer. On MRI metastatic lesions appeared iso to hypointense on T1 with post contrast enhancement. Dural invasion and intracranial extension was noted on MRI in 5 cases.



Metastasis

Axial CT bone window image (A) shows lytic, widely necrotic, lesion with intra- and extracranial extension involving right parietal bone.

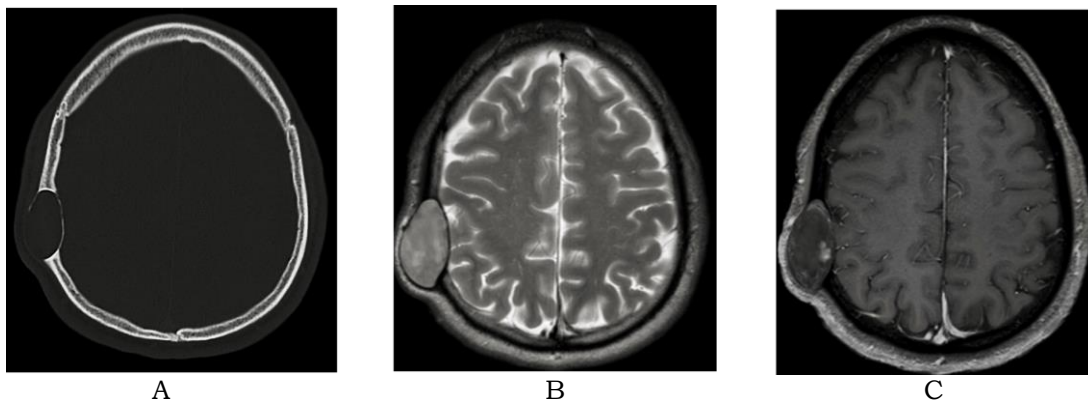
Coronal T2w image(B) and post contrast MRI image (C) shows extraosseous spread on both intra- and extracranial aspects, with dural displacement and thickening.

10. Epidermoid and Dermoid Cysts

These lesions occur secondary to congenital or posttraumatic epidermal or dermal inclusions within the dipole.

Epidermoid cyst-

On CT, they appear as well-demarcated osteolytic lesions with sclerotic borders and expansion into inner and outer tables. On MRI the lesion shows fluid like signal and high signal on DWI without any significant post contrast enhancement.



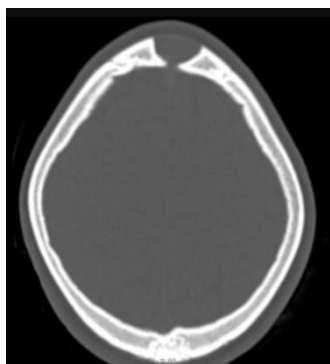
Epidermoid cyst

Axial head CT shows an expansile lesion in the right parietal bone with thinning of the inner and outer tables.

Lesion appears hyperintense on Axial T2-weighted image (b), and shows minimal enhancement on post contrast image (c)

Dermoid cyst-

Dermoid cyst usually involves midline mainly around anterior fontanelle. It appeared similar to epidermoid cyst on CT with intralesional calcifications and extension into the adjacent soft tissues. On MRI they had variable appearance with thick capsular enhancement on contrast imaging.



Dermoid cyst

Axial CT head image shows a dermoid cyst in the frontal region.

Conclusion

This article has demonstrated that CT and MRI have complementary roles in determining the nature of skull lesions. CT is best for evaluating bone destruction of the inner and outer tables, if the lesion is sclerotic or lytic and evaluating mineralised tumour matrix. MRI is best to assess marrow involvement of diploe, soft tissue component and invasion of adjacent tissues. Benign lesions mostly have well defined borders with a narrow transition zone and sclerotic margins. Malignant lesions have features like poorly defined margins with wide transition zone and aggressive periosteal reaction and often they have soft tissue component. Bony destruction with intracranial or extracranial extension are common with malignant lesions.

References

1. Arana E, Martí-Bonmati L (1999) CT and MR imaging of focal calvarial lesions. *AJR Am J Roentgenol* 172:1683–1688
2. Colas L, Caron S, Cotton A (2015) Skull vault lesions: a review. *AJR Am J Roentgenol* 205:840–847
3. Garfinkle J, Melan ç on D, Cortes M, Tampieri D (2011) Imaging pattern of calvarial lesions in adults. *Skeletal Radiol* 40(10):1261–1273
4. Jani, J. R., Bajamal, A. H., Utomo, S. A., Parenrengi, M. A., Fauzi, A. A., Utomo, B., & Dwihapsari, Y. (2021). Correlation between magnetic resonance imaging (MRI) and dynamic mechanical analysis (DMA) in assessing consistency of brain tumor. *International Journal of Health & Medical Sciences*, 4(2), 260-266. <https://doi.org/10.31295/ijhms.v4n2.1737>
5. Lloret I, Server A, Taksdal I (2009) Calvarial lesions: a radiological approach to diagnosis. *Acta Radiol* 50:531–542
6. Suryasa, I. W., Rodríguez-Gámez, M., & Koldoris, T. (2021). Get vaccinated when it is your turn and follow the local guidelines. *International Journal of Health Sciences*, 5(3), x-xv. <https://doi.org/10.53730/ijhs.v5n3.2938>
7. Yal ç in Ö, Yildirim T, Kizilkili ç O et al (2007) CT and MRI findings in calvarial non-infectious lesions. *Diagn Interv Radiol* 13:68–74
8. Younghee Y, Woon-Jin M, Hyeong SA, Joon C, Myung HR (2016) Imaging findings of various calvarial bone lesions with a focus on osteolytic lesions. *J Korean Soc Radiol* 74(1):43–54