



Managing the Penetrated Traumatic Spinal Injury by an Airgun Shot: A Case Report from Dr. Soetomo Hospital, Surabaya, Indonesia



Januardi Rifian Jani ^a, Eko Agus Subagio ^b

Manuscript submitted: 9 January 2021, Manuscript revised: 27 February 2021, Accepted for publication: 19 March 2021

Corresponding Author ^b

Abstract



Keywords

*airgun shot;
breathing problem;
patient;
penetrated traumatic
spine injury;
vertebral body;*

Penetrated Traumatic Spinal Injury by Airgun Shot are rare events. As a result, handling this case is both, thrilling and challenging. We present a case of a penetrated traumatic spinal injury from an airgun, as well as a summary of the literature on how to treat them. A 9-year-old boy was taken to hospital after being shot in the right side of his front neck with an air rifle. The patient had been shot from a distance with an upfront direction. The patient had no breathing problem but complained of pain during swallowing. The patient was conscious, alert, and oriented. There was no breathing distress. The head and neck Computed Tomography Scan displayed a foreign body with metal-density at the vertebral body of the first thoracal and discontinuity of the esophageal wall. Debridement and exploration surgery have successfully released the bullet. Repair trachea had been performed. Postoperatively, the patient had no complications. We can conclude that a foreign body at the spine, especially in the vertebral body of the cervical, can be effectively and safely released by exploration surgery.

*International Journal of Health Sciences © 2021.
This is an open access article under the CC BY-NC-ND license
(<https://creativecommons.org/licenses/by-nc-nd/4.0/>).*

Contents

Abstract.....	46
1 Introduction	47
2 Materials and Methods.....	47
3 Results and Discussions.....	49
4 Conclusion	50

^a Dr. Soetomo Surabaya, Indonesia/Resident of the Department of Neurosurgery, Faculty of Medicine, Airlangga University, Surabaya, Indonesia

^b Neurosurgeon, Spine Division Physician, Faculty of Medicine, Airlangga/RSU Dr. Soetomo, Surabaya, Indonesia

Acknowledgments.....	50
References	51
Biography of Authors.....	52

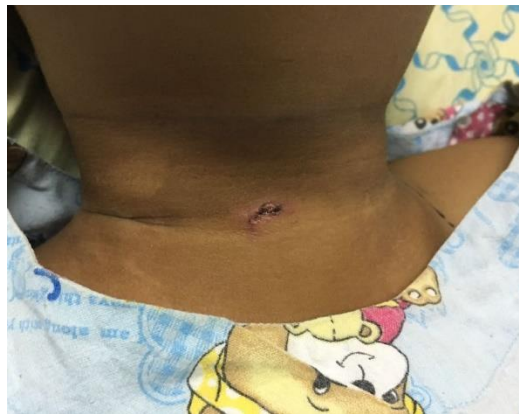1 Introduction

Most spinal cord injuries (SCI) result from machine accidents and falls; however, spinal cord injuries (PSI) represent 13-17% of injuries. This makes PSI the 3rd most fundamental cause of spinal cord injury, being close enough to a car crash on the road and falling from a height (Patil et al., 2015). On the other hand, infiltrating neck wounds represent approximately 5% to 10% of all confirmed injuries. Given the close relationship of various fundamental designs in the neck, entry wounds can cause injury to important vascular and neurological constructs such as those of the throat and throat. Compressed air firearms entering spinal cord injury cases provide an exciting and uncommon imaging finding that shows set shots in the patient's spinal waterway without neurological exchange (Bigder et al., 2015).

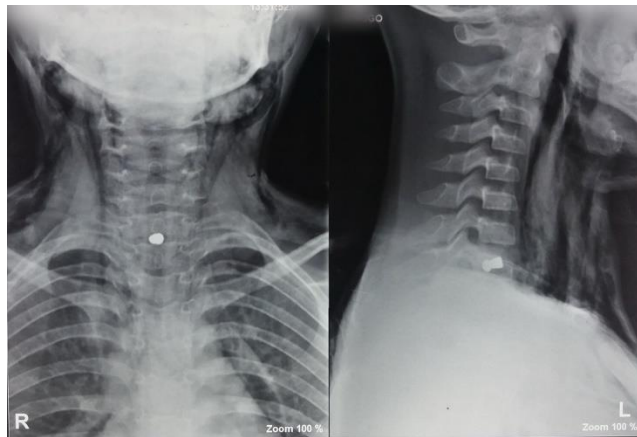
Spinal line injuries can be catastrophic as they can cause severe neurovascular confusion, such as myelopathy, radiculopathy, and contamination of the focal sensory system. In a written survey, recent reports of pneumatic nail injuries have confirmed history of injury (Chen et al., 2018; Connell et al., 2003; Marino et al., 1999). The foreign body of the spine is identified by one or another injury or iatrogenic wound. Snails, blade ends, Kirschner wires, needles, glass or wood pieces, or cotton pads have all been identified as foreign bodies retained in spinal trenches (Yoshioka et al., 2012; Oliver et al., 2012; Demetriades et al., 1996). The plank is trying because care must be taken to avoid injury to the spinal strings, leaving nerve roots such as the vertebral and carotid pathways. The patient should be examined for cerebrospinal fluid, disease, and vascular injury in the postoperative period. Here we report an unusual case of infiltrating horrendous spinal cord injuries via air gunfire and administration.

2 Materials and Methods

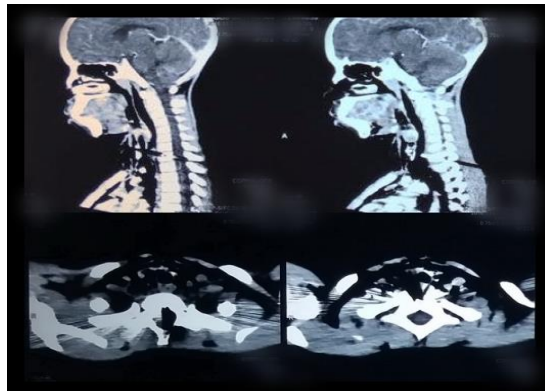
A 9-year-old boy offended the medical clinic after being fired by an air rifle in the right side of his front neck. The patient was shot from inaccessible to the point. The patient has no breathing problems except whining pain when swallowing. The patient is conscious, alert, and on. There is no suffering breathing. On the actual Assessment of the neck's very front, a gunshot wound of 0.5 cm section was found with idle dying (Figure 1).



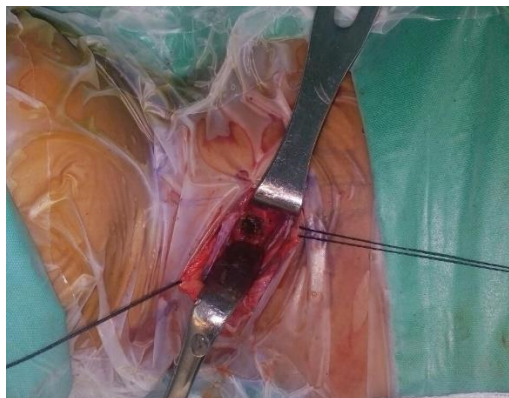No gunshot wounds leave a projectile inside the neck. On cervical x-ray examination, a bullet was found as a foreign body inside corpus vertebra thoracal 1 ([Figure 2](#)).



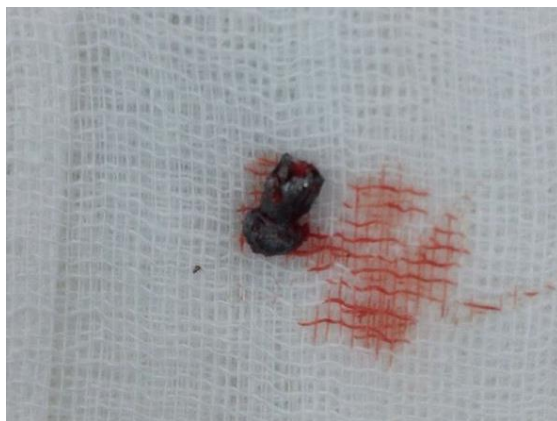The head and neck computed tomography scan displayed a foreign body with metal-density at a vertebral body of corpus vertebrae thoracal one and discontinuity of esophageal wall ([Figure 3](#)).



In this case, the patient underwent emergency surgery. Debridement and exploration surgery have successfully released the bullet that is repairing trachea had been performed ([Figure 4](#)).



Bullet successfully extracted from corpus vertebra T1 ([Figure 5](#)).



Postoperatively, the patient was confined to the intensive care unit for three days and treated in the standard care room for seven days. The patient was given medical analgesics and antibiotics for seven days post operations. The patient had no complications and no neurological deficit.

Figure Legend

- Figure 1 : The anterior aspect of the neck, a 0.5 cm entry gunshot wound was found with inactive bleeding.
- Figure 2 : Cervical x-ray examination was found a bullet as foreign body inside corpus vertebra thoracal 1.
- Figure 3 : The head and neck CT- scan displayed a foreign body with metal-density at vertebral body of corpus vertebrae thoracal 1 and discontinuity of esophagal wall.
- Figure 4 : Debridement and exploration surgery was successfully release the bullet.
- Figure 5 : Bullet successfully extracted from corpus vertebra T1

3 Results and Discussions

They are penetrating traumatic spine injuries associated with high mortality. There is a high probability of permanent neurological dysfunction. Vascular injury and high risk of infection are other complications that also become morbidity inpatient with penetrating traumatic essential to improve patient penetrating traumatic spine injury. A challenging aspect of the surgical management of penetrating traumatic spine injury is selecting appropriate surgical candidates.

Etiologically, over 90% of SCI cases are awful and are brought about by the degree of, for instance, vehicle crashes, remorselessness, sports, or falls. There was a reported male-to-female extent of 2: 1 for SCI, which is more typical in grown-ups than youngsters. Demographically, men are, for the most part, influenced ahead of schedule. Late adulthood (third and eighth long periods of life), while ladies are at a higher danger during adolescence (15-19 years) and the seventh decade of their lives (Stein & Knight, 2017; Blair et al., 2012). More experienced grown-ups than 60 years with SCI had a lot of more regrettable results than more youthful patients, and their wounds were, for the most part, the aftereffect of falls and complex age-related changes. (Hachem et al., 2017).

The air rifle has been viewed as a lethal weapon since actual occasions. They are prepared to cause perilous wounds—Lesbians II of Egypt utilized vital air to fire around 250 BC. Air rifles are known as wind stacks and are utilized noticeable all-around supply connected to the firearm's barrel. These weapons were utilized in the Napoleonic clashes in the late seventeenth and mid-eighteenth hundreds (Ceylan et al., 2002; Paramita et al., 2018). The cutting-edge rifle can move pellets past 1100 ft/s (330 m/s) at the sound speed and produce commotion like a 22-type rimfire rifle. They can make a heaving pace of 350 ft/s or more. The oil introduced in the barrel (dieseling) and is lit by the passing pellets' glow creates a blast that gives more

significant speed and genuine penetration ability to the pellets. The typical fire utilized in air rifles is the central diabolo pellet. This is a joker's shot emitting at the base, with an assortment of head styles. The ejected base is expected to build course solidness (Abad et al., 2009).

Compressed air firearms entering severe spinal cord injuries can cause troublesome analytical and restorative difficulties. Their and the board's Assessment remains debatable. Some specialists recommend necessary neck examinations, while others believe in careful specialized mediation. The generally accepted agreement is that these wounds should be monitored regularly. Most importantly, flight routes must be regulated and cardio cerebral perfusion maintained. After that, an in-depth assessment of the injury's location and seriousness should be made (Broniatowski & Tucker, 1986).

Foreign bodies can cause severe blood vessel injury; similarly, careless removal of products can result in hazardous releases. Before a carefully planned expulsion, radiological examinations should be requested. Plain radiographs, CT scans, and MRI tests help determine the damage's type and location before surgery. They also have information about the causes of uncertainty.

Plain radiographs and CT examinations help configure the pellets and set up our methodology for careful evacuation. This prevents unnatural drying and evacuation of the pellets for the visually impaired. Several authors have suggested a non-mediated strategy in pellet wounds in the neck (Gupta et al., 2011). CT forms the best research methodology in such new settings. Violent living systems can be described as a whole, and robustness choices can be made more impartially. CT myelography is another option in this case, but whether it makes sense in an emanant setting is questionable. Spinal CT shows both the shot and the resting of the right lamina (passage point) clear, and then the injury is considered stable. Spinal infiltration injury is the third most basic reason for spinal line injury, and further radiological details consistently (important recreational, sagittal, and three-dimensional) should be entirely concentrated (Kumar et al., 2011).

Fast examinations are justified for dynamic mortality, and scientific assessments should be performed for hemodynamically stable patients. The clinical result relies upon the earnestness and zone of pain and may incorporate the deficiency of part or the entirety of the clear harm and machine work beneath the degree of injury. Lower chest wounds can cause paraplegia, though wounds at the cervical level are related to quadriplegia (Wilson et al., 2012). SCI ordinarily influences the cervical string level (half), with without a doubt the most standard level influenced is C5. Various wounds incorporated the chest (35%) and lumbar area (11%). With the improvement of being late in a medical procedure and patient thought, SCI patients regularly experience these horrific injuries and live moderately long after the fundamental injury C5 (Hachem et al., 2017).

4 Conclusion

Foreign body at the spine, especially in the vertebral body of the cervical or upper thoracic, is a rare and challenging case. A detailed and thorough examination before the operation is the key to successful therapy. The foreign body can be effectively and safely released by exploration surgery.

Acknowledgments



We thank all friends and other parties who have supported this project, especially the Ministry of Education and Research and Technology, for funding and support so that we can finish well on our project topic, "Managing Traumatic Spinal Injury That Penetrates With An Airgun Shot: A Case Report from Dr. Soetomo Surabaya, Indonesia."

References

- Abad, S., McHenry, I. D., Carter, L. M. and Mitchell, D. A. (2009) 'Carotid artery injury from an airgun pellet: A case report and review of the literature', *Head and Face Medicine*, 5(1), pp. 1–5. doi: 10.1186/1746-160X-5-3.
- Blair, J. A., Possley, D. R., Petfield, J. L., Schoenfeld, A. J., Lehman, R. A., Hsu, J. R., & Skeletal Trauma Research Consortium. (2012). Military penetrating spine injuries compared with blunt. *The Spine Journal*, 12(9), 762-768. <https://doi.org/10.1016/j.spinee.2011.10.009>
- Bigder, M., Zeiler, F. and Berrington, N. (2015) 'Nail-gun Injury through the Spinal Canal', *The Canadian journal of neurological sciences. Le journal canadien des sciences neurologiques*, 42(3), pp. 203–204. doi: 10.1017/cjn.2015.17.
- Broniatowski, M. and Tucker, H. M. (1986) 'Penetrating injuries of the neck', *Postgraduate Medicine*, 80(1), pp. 155–160. doi: 10.1080/00325481.1986.11699457.
- Ceylan, H., McGowan, A. and Stringer, M. D. (2002) 'Air weapon injuries: A serious and persistent problem', *Archives of Disease in Childhood*, 86(4), pp. 234–235. doi: 10.1136/ad.86.4.234.
- Connell, R. A., Graham, C. A., & Munro, P. T. (2003). Is spinal immobilisation necessary for all patients sustaining isolated penetrating trauma?. *Injury*, 34(12), 912-914. [https://doi.org/10.1016/S0020-1383\(03\)00070-6](https://doi.org/10.1016/S0020-1383(03)00070-6)
- Chen, C. W., Yang, S. C., Liu, K. T. and Wu, Y. H. (2018) 'Foreign body in the thoracic spine due to a nail gun penetrating injury A case report', *Medicine (United States)*, 97(52), pp. 5–7. doi: 10.1097/MD.00000000000013870.
- Demetriades, D., Asensio, J. A., Velmahos, G., & Thal, E. (1996). Complex problems in penetrating neck trauma. *Surgical Clinics of North America*, 76(4), 661-683. [https://doi.org/10.1016/S0039-6109\(05\)70475-8](https://doi.org/10.1016/S0039-6109(05)70475-8)
- Gupta, B., Gulati, A. and Gupta, D. (2011) 'A Rare Presentation of Pellet Injury in the Neck', *ISRN Surgery*, 2011, pp. 1–3. doi: 10.5402/2011/306126.
- Hachem, L. D., Ahuja, C. S. and Fehlings, M. G. (2017) 'Assessment and management of acute spinal cord injury: From point of injury to rehabilitation', *The Journal of Spinal Cord Medicine*, 40(6), pp. 665–675. doi: 10.1080/10790268.2017.1329076.
- Imokawa, H., Tazawa, T., Sugiura, N., Oyake, D. and Yosino, K. (2003) 'Penetrating neck injuries involving wooden foreign bodies: the role of MRI and the misinterpretation of CT images', *Auris Nasus Larynx*, 30, pp. 145–147. doi: 10.1016/S0385-8146(02)00130-X.
- Kumar, A., Pandey, P. N., Ghani, A. and Jaiswal, G. (2011) 'Penetrating spinal injuries and their management', *Journal of Craniovertebral Junction and Spine*, 2(2), pp. 57–61. doi: 10.4103/0974-8237.100052.
- Marino, R. J., Ditunno Jr, J. F., Donovan, W. H., & Maynard Jr, F. (1999). Neurologic recovery after traumatic spinal cord injury: data from the Model Spinal Cord Injury Systems. *Archives of physical medicine and rehabilitation*, 80(11), 1391-1396. [https://doi.org/10.1016/S0003-9993\(99\)90249-6](https://doi.org/10.1016/S0003-9993(99)90249-6)
- Oliver, M., Inaba, K., Tang, A., Branco, B. C., Barmparas, G., Schnüriger, B., ... & Demetriades, D. (2012). The changing epidemiology of spinal trauma: a 13-year review from a Level I trauma centre. *Injury*, 43(8), 1296-1300. <https://doi.org/10.1016/j.injury.2012.04.021>
- Paramita, D. P., Adiatmika, I. G. P., Kuswardhani, T., & Mustika, I. W. (2018). Physiological and psychosocial change and the need of health intervention model for elderly. *International Journal of Health Sciences*, 2(2), 61-67.
- Patil, R., Jaiswal, G. and Gupta, T. (2015) 'Gunshot wound causing complete spinal cord injury without mechanical violation of spinal axis: Case report with review of literature', *Journal of Craniovertebral Junction and Spine*, 6(4), p. 149. doi: 10.4103/0974-8237.167855.
- Stein, D. M. and Knight, W. A. (2017) 'Emergency Neurological Life Support: Traumatic Spine Injury', *Neurocritical Care*, 27(S1), pp. 170–180. doi: 10.1007/s12028-017-0462-z.
- Wilson, J. R., Cadotte, D. W. and Fehlings, M. G. (2012) 'Clinical predictors of neurological outcome, functional status, and survival after traumatic spinal cord injury: a systematic review', *Journal of Neurosurgery: Spine*, 17(Suppl1), pp. 11–26. doi: 10.3171/2012.4.AOSPINE1245.
- Yoshioka, K., Kawahara, N., Murakami, H., Demura, S., Matsuda, M., Tomita, K., et al. (2012) 'A Glass Foreign Body Migrating into the Lumbar Spinal Canal: A Case Report', *Journal of Orthopaedic Surgery*, 20(2), pp. 257–259. doi: 10.1177/230949901202000226.

Jani, J. R., & Subagio, E. A. (2021). Managing the penetrated traumatic spinal injury by an airgun shot: A case report from Dr. Soetomo Hospital, Surabaya, Indonesia. *International Journal of Health Sciences*, 5(1), 46-52. <https://doi.org/10.29332/ijhs.v5n1.1082>

Biography of Authors

	<p>dr. Januardi Rifian Jani was born in Sumenep, 27 January 1988. He graduated from Medical Faculty, Airlangga University, Surabaya in 2012. And now, he is pursuing a specialist education program in Department of Neurosurgery, Dr. Soetomo Hospital, Airlangga University, Surabaya - Indonesia <i>Email: jfi.ns.sby@gmail.com</i></p>
	<p>Dr. Eko Agus Subagio, dr., Sp.BS (K) Spine was born in Malang, 2 September 1964. He is the staff of the Spine Section of Neurosurgery Department, Dr. Soetomo Hospital, Airlangga University, Surabaya - Indonesia <i>Email: easnsurg@yahoo.com</i></p>