

How to Cite:

Das, S., Singh, V. D., Bind, A., Anamika, A., Gupta, S. P., & Kumar, R. (2022). Evaluation of antiulcer, antioxidant potency of manuka honey and cinnamon powder mixture in Wistar rats using experimental rat models. *International Journal of Health Sciences*, 6(S6), 6259–6268. <https://doi.org/10.53730/ijhs.v6nS6.10979>

Evaluation of antiulcer, antioxidant potency of manuka honey and cinnamon powder mixture in Wistar rats using experimental rat models

Dr. Saumya Das

Noida Institute of Engineering and Technology (Pharmacy Institute), 19
Knowledge Park-II, Institutional Area Greater Noida- 201306 Uttar Pradesh, India

Dr. Veena D. Singh

Noida Institute of Engineering and Technology (Pharmacy Institute), 19
Knowledge Park-II, Institutional Area Greater Noida- 201306 Uttar Pradesh, India

Amit Bind

Noida Institute of Engineering and Technology (Pharmacy Institute), 19
Knowledge Park-II, Institutional Area Greater Noida- 201306 Uttar Pradesh, India
***Corresponding author email:** bindamit04@gmail.com

Anamika

Noida Institute of Engineering and Technology (Pharmacy Institute), 19
Knowledge Park-II, Institutional Area Greater Noida- 201306 Uttar Pradesh, India

Dr. Satya Prakash Gupta

Sardar Patel Post Graduate Institute of Dental and Medical Science Lucknow,
Uttar Pradesh, India

Roshan Kumar

Dev Bhoomi Institute of Pharmacy and Research, Dehradun, Uttarakhand, India

Abstract--Inflammation of the lining of the stomach is one of the most prevalent health problems that people face. In this study, the effects of herbal medication on the digestive system were examined in relation to the use of the cold-water immersion technique. **Material & Methods:** Male albino 6-week-old albino rats weighing 200-250 g each were used in the investigation. For three months, the animals were housed in the animal facility of the NIET Pharmacy Institute at 20°C (3°C) and 50-60% relative humidity. Researchers discovered non-lethal cold-water immersion in a small sample of six rats that caused stomach ulcers. After an 18-hour fasting, rats were immersed in ice-cold water. Researchers were able to examine the mucosa by isolating the stomach of rats. **Result:** In a model of cold-water immersion,

honey has a unique effect on ulcer severity.esomeprazole is a medication used to treat acid reflux. According to phytochemical screening, the presence of flavonoids, triterpenes, and the antioxidant capacity of the crude drug mixture enhances antioxidant status and promotes mucus production. These elements may be responsible for the protective effect on stomach ulcer treatment. Conclusion: The content of flavonoids and triterpenes of honey and cinnamon powder mixture should be analyzed. Cinnamomum zeylanicum Nees and unprocessed Manuka honey require further study.

Keywords--antioxidant, gastrointestinal, natural active component, complementary drug, rodent animal.

Introduction

Gastric ulcers have long been regarded a frequent condition affecting people of all ages, but especially adolescents. Also, relapse is highly likely (80 percent at 1st year and 100 percent in the 2nd year of treatment). Using H2-receptor antagonists for a year and not eradicating ulcers are two further problems So researchers have been exploring for ways to improve existing pharmaceuticals or produce new, better, cheaper, and healthier ones. New therapies and natural products are tested for gastroprotective effects utilizing a cold water-induced gastric ulcer model [1]. Cold water increases neutrophil infiltration, which is an immediate inflammatory response to the injury. Then comes a rush of reactive oxygen species (ROS), which increases the amount of oxygen required by numerous cell components [2]. A change in cytokine balance in the stomach mucosa promotes inflammation [3]. For example, the cytokine TNF- has been linked to stomach ulcer formation in cold water [4]. It is rich in flavonoids. Flavonoids are polyphenolic chemicals that have anti-inflammatory, antimicrobial, and anti-ulcerogenic actions. Cinnamon is used by herbalists worldwide for its bioactive benefits. Cinnamon, a lauraceae family member, has been used medicinally and as a food flavoring since ancient times. Inflammatory, antibacterial and antioxidant properties of cinnamon have led to its use in gastrointestinal problems.[5]



Fig 1. Cinnamon powder and Manuka honey

Material and Methods

The study used 24 albino wistar rats 7-weeks old weighing 200-250gms. The animals were kept in the Noida Institute of Engineering and Technology (Pharmacy Institute) animal house for three months at 20°C ±(3°C) and 50-60% relative humidity. The animals had free access to food and water. Manuka honey and cinnamon powder were procured on 25 November 2020 from Khari Baoli market, Delhi, India. Esomeprazole purchased from apollo pharmacy Greater Noida (Uttar Pradesh) cinnamon powder was made from air-dried powdered cinnamon bark.

Animals grouping

Cold water immersion stress induced ulcer model

Albino wistar rats were separated in 4 groups of 7 weeks age, 200-250gms. 6 albino wistar rats in each group.

- **GROUP I-** Control group -Treatment with vehicle (normal saline) alone, p.o
- **GROUP II-** Esomeprazole 25mg/kg is the recommended dose.
- **Group III-** Mixture of manuka honey and cinnamon powder (200mg/kg) in 0.1% Tween 80, taken in 1:1, given p.o
- **Group IV-** Mixture of manuka honey and cinnamon powder (400 mg/kg) in 0.1% Tween 80 taken in 1:1, given p.o

Experimental procedures

Wistar rats weighing 200-250gms were used and they were fasted for 16 hours, then administered test compound orally. Rats were placed individually in restrained cages vertically, and then immersed in water upto the xiphoid process at 22°C for 16 hours. Rats were removed from the cages, dried and then injected Evan's blue (30mg/kg) I.V via the tail vein and ten minutes later they were sacrificed. The stomach was removed and ligated at both ends, it is filled with normal saline and kept overnight. On the next day the stomach was opened along the greater curvature and examined for ulcerative lesions. Acidity of gastric juice was determined by using pH meter apparatus. Gastric juices were centrifuged at 500 rpm for 5 minutes, then separated and measured volume by graduated cylinder. The stomach of the sacrificed rats was taken and immersed in 10% formalin solution and stained with hematoxylin and eosin stain for histopathological examination. There was measurements of gastric pH, total acidity and free acidity, as well as gastric lesions, ulcer index, histological characteristics were also observed.

Histopathological examination

Hematoxylin and eosin (H & E) stain was used for light microscopy to examine tissue samples from each rat's stomach. The samples were fixed in 10% neutral buffered formalin solution for 24 hours.

Statistical analysis

Data are expressed as mean \pm S.E.M. (*) $p < 0.05$, (**) $p < 0.01$, and (***) $p < 0.001$ (One-way ANOVA followed by “Tukey’s multiple comparison post hoc tests), using graph pad prism. Version 16 of SPSS (Statistical package for Social Sciences).

Table 1
Drugs, dosing and observation parameter of cold-water immersion stress induced ulcer model

Screening model/ Animal used	No. of group	Drugs, Dose, Route	Duration	Observation parameters
Cold water immersion stress induced ulcer model/ albino wistar rats	Group 1: Control group (Normal saline)	Treated with vehicle alone (normal saline), p.o	2 days for each animal	Determination of gastric juice acidity: The pH meter instrument will be used to determine the acidity of the gastric juice.
	Group 2: Standard drug treated group.	(Esomeprazole) 25mg/kg I.P		Determination of gastric juice volume: For five minutes, gastric juices were centrifuged at 500 rpm to separate them, and the volume in graduated cylinders is then measured.
	Group 3: Test group 1 (low dose)	Mixture of manuka honey and cinnamon powder (200mg/kg) in 0.1% Tween 80, taken in 1:1, given p.o		Histopathological examination: Rat stomachs were removed and placed in 10% formalin solution before being stained with hematoxylin and eosin stain for further examination and analysis.
	Group 4: Test group 2 (high dose)	Mixture of manuka honey and cinnamon powder (400mg/kg) in 0.1% Tween 80, taken in 1:1, given p.o		Statistical analysis: Data were expressed as mean \pm S.E.M. (*) $p < 0.05$, (**) $p < 0.01$, and (***) $p < 0.001$ (One-way ANOVA followed by “Tukey’s multiple comparison post hoc tests).

Results and Discussion

In cold water immersion induced stress model the animals were immersed in cold water for 18 hours upto xiphoid process, resulted gastric lesion in control and

treated rats. The stomach membrane is easily and quickly penetrated by cold water, so this study compared Manuka honey, Cinnamon powder mixture along with esomeprazole to analyze which had better anti-ulcer and antioxidant benefit in rat ulcer and oxidative stress model induced by cold water immersion. The result of the present study showed significant changes in the ulcer length of test group treated rats at 200 mg/kg body weight and 400 mg/kg body weight of Manuka honey and Cinnamon powder respectively. The results of cold-water immersion stress model were found to be $4.12 \pm 0.1\text{mm}$ and $3.45 \pm 0.23\text{mm}$, respectively as compared to control and standard group of rats i.e., 7.86 ± 0.50 and 1.50 ± 0.59 , as shown in table 2. The pH of gastric juice in the control group was found to be very low i.e., 4.69 ± 0.30 and for test groups of rats at 200 mg/kg body weight and 400 mg/kg body weight of Manuka honey and Cinnamon powder were found to be the 5.60 ± 0.32 , 7.59 ± 0.26 , respectively as compared to standard group 8.72 ± 0.25 , as shown in table 3.

The result of present studies showed changes in the volume of gastric juice of test group of rats at 200 mg/kg body weight and 400 mg/kg body weight of Manuka honey and Cinnamon powder were found to be of 4.12 ± 0.62 , 2.10 ± 0.53 respectively as compared to control and standard group of rats i.e., 5.68 ± 0.69 and 5.3 ± 0.15 respectively, as shown in table 4. The rats treated with Manuka honey and Cinnamon powder decreased the intensity of gastric mucosal damage induced by cold water immersion. The % protection of gastric lesion was more than (75.63%) in the groups of animals received Manuka honey and Cinnamon powder 400 mg/kg when compare to 200mg/kg body weight.

Table 2
Effect of cold-water immersion stress ulcer model on gastric ulcer length

Groups	Number of animals (n)	Gastric ulcer length in (mm)
Control group	6	7.86 ± 0.50
Standard group (Esomeprazole) 25mg/kg i. p	6	$1.50 \pm 0.59^{***}$
Manuka honey and cinnamon powder (200mg/kg) b. w	6	4.12 ± 0.15
Manuka honey and cinnamon powder (400mg/kg) b. w	6	$3.45 \pm 0.23^{**}$

Data are expressed as mean \pm S.E.M. (*) $p < 0.05$, (**) $p < 0.01$, and (***) $p < 0.001$ (One-way ANOVA followed by "Tukey's multiple comparison post hoc tests).

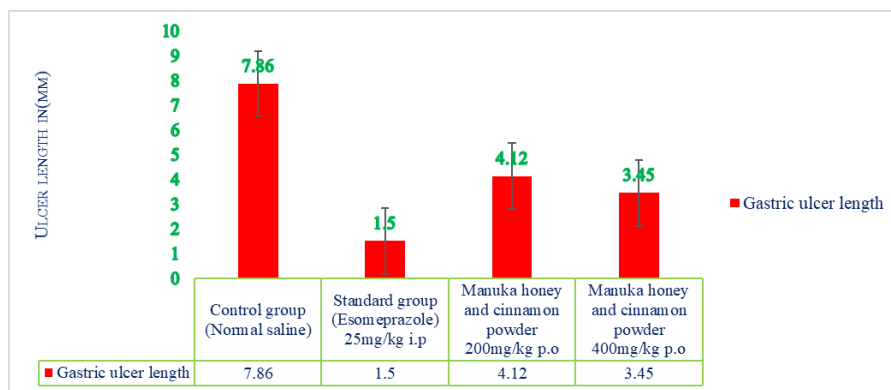


Fig 2. Effect of cold-water immersion stress ulcer model on gastric ulcer length (mm)

Table 3
Effect of cold-water immersion stress ulcer model on pH of gastric juice

Groups	Number of animals (n)	pH of gastric juice
Control group	6	4.69 ± 0.30*
Standard group (Esomeprazole) 25mg/kg i. p	6	8.72 ± 0.25**
Manuka honey and cinnamon powder (200mg/kg) b. w	6	5.60 ± 0.32
Manuka honey and cinnamon powder (400mg/kg) b. w	6	7.59 ± 0.26**

Data are expressed as mean ± S.E.M. (*) $p < 0.05$, (**) $p < 0.01$, and (***) $p < 0.001$ (One-way ANOVA followed by "Tukey's multiple comparison post hoc tests).

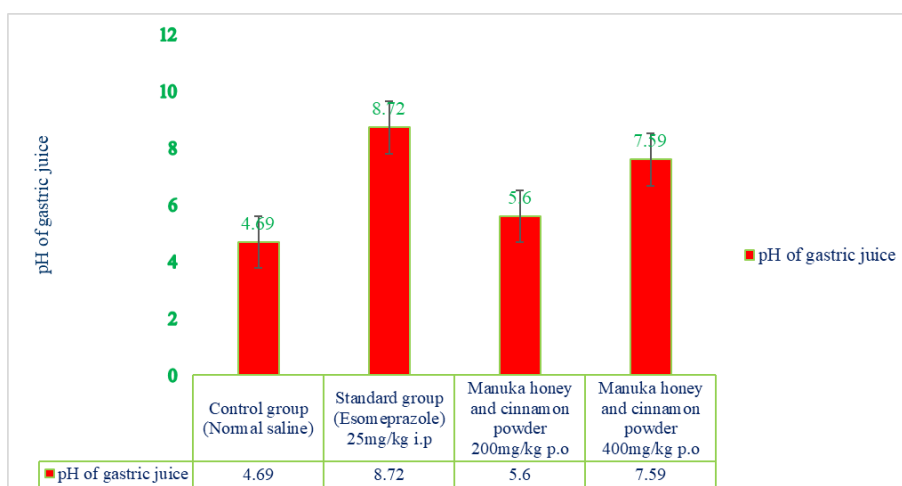


Fig 3. Effect of cold-water immersion stress ulcer model on pH of gastric juice

Table 4
Effect of cold-water immersion stress ulcer model on gastric juice volume

Groups	Number of animals (n)	Gastric juice volume in (cm ³)
Control group	6	5.68 ± 0.69*
Standard group (Esomeprazole) 25mg/kg i. p	6	1.53 ± 0.15
Manuka honey and cinnamon powder (200mg/kg) b. w	6	4.12 ± 0.62**
Manuka honey and cinnamon powder (400mg/kg) b. w	6	2.10 ± 0.53**

Data are expressed as mean ± S.E.M. (*) p < 0.05, (**) p < 0.01, and (***) p < 0.001 (One-way ANOVA followed by "Tukey's multiple comparison post hoc tests).

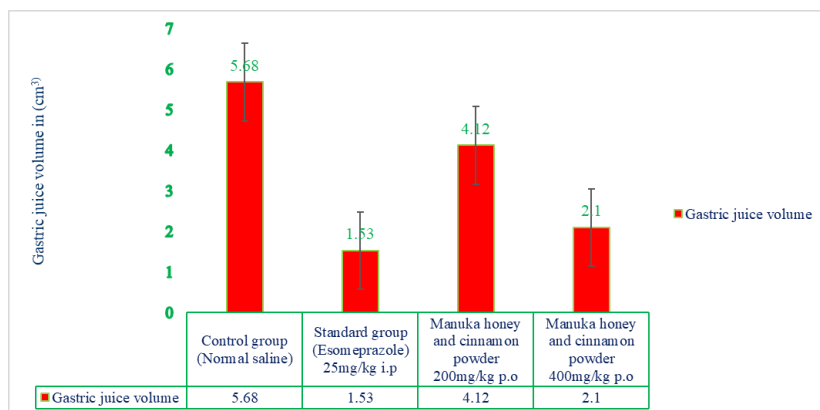
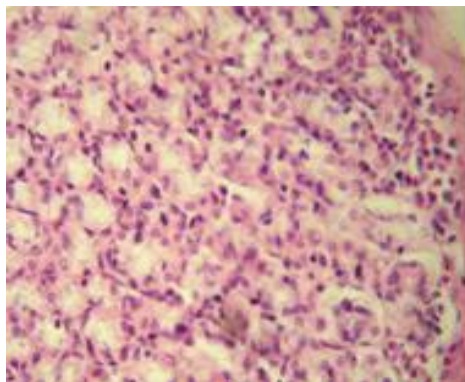
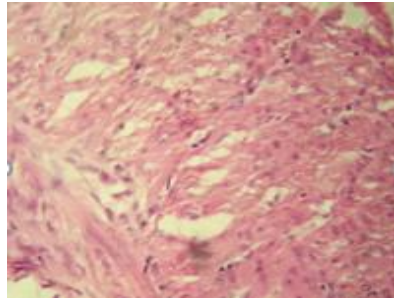


Fig 4. Effect of cold-water immersion stress ulcer model on gastric juice volume

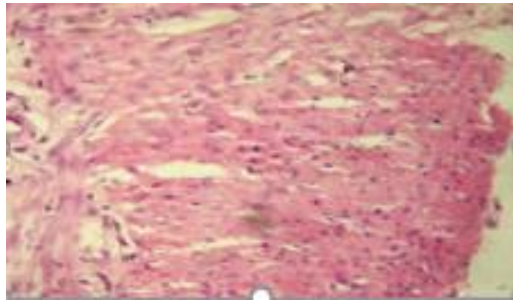
Histopathological studies of cold-water immersion stress ulcer model



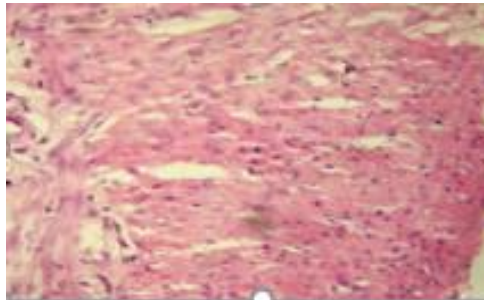
A. Control group (Normal saline) (Esomeprazole)



B. Standard group 25mg/kg i.p



C. Manuka honey and Cinnamon powder 200mg/kg p.o



D. Manuka honey and Cinnamon powder 400mg/kg p.o

Fig 5. Cold water immersion stress induced model, Manuka honey and Cinnamon powder has unique impacts on the reduction in severity of gastrointestinal ulcer

Researchers use the cold-water model to simulate and assess the dangers of drinking cold water. The stomach's inflammatory lesions and numerous tissues' oxidative damage rank among the most serious side effects. The effects of cold-water hazards are managed using anti-invasion and anti-defense strategies.^[6] However, due to their expense and potential for side effects, proton pump inhibitors (PPIs), a class of anti-secretory medications, have gained widespread acceptance as the best option for treating ulcers. Recently, efforts have been made to identify efficient natural alternatives to conventional therapies. Numerous researchers have investigated the anti-ulcerative and antioxidant properties of various spices and plant extracts.^[7] In this study, the anti-ulcer and antioxidant effects honey were compared to those of esomeprazole in a rat ulcer and oxidative stress model induced by cold water. Because cold water quickly and easily penetrates the stomach membrane.

The observed gross and microscopic stomach lesions in the present investigation confirmed that mucosal permeability was increased and vasoactive products were released, which results in gastric lesions and ulceration. The application of cold water caused numerous biochemical and histological changes in the tissues that were the subject of the study. According to preliminary studies, drinking cold water causes the liver to become hepatotoxic, and this effect is supported by changes in the histopathology of the stomach. Unusually high liver enzyme levels and an imbalance between antioxidants and oxidants point to severe cellular damage and tissue necrosis. The documented hyperglycemia of cold water-intoxicated rats is supported by the finding that short-term or acute cold-water intake causes hyperglycemia, possibly as a result of a decrease in glucose uptake and a reduction in insulin-mediated glucose utilization. This could serve as a visual representation of the pathological and gross stomach injuries that have been documented. Reactive oxygen species (ROS) and lipid peroxidation are both involved in the pathophysiology of cold water-induced stomach lesions and oxidative damage, according to research.^[8]

The extensive metabolism of cold water by the liver's microsomal oxidizing mechanism results in potentially toxic and dangerous metabolites like free hydroperoxyl radicals and superoxide anion. The accumulation of ROS and the antioxidant system's failure to remove them compromise cell integrity. Various studies demonstrated the oxidative effects of cold water, which are supported by an increase in MDA and a decrease in the quantity of endogenous antioxidants in the tissues under investigation.^[9] This might be due to the fact that cold water can cause tissue damage by raising ROS and LPO, both of which raise MDA production. ROS, which are essential for defending cells from damage brought about by cold water, weaken and exhaust the antioxidant defense systems. Flavonoids have antioxidant and anti-ulcer properties.^[10] This study suggested that these active chemicals may increase mucus production and mucosal glycoproteins, decrease acid output, and counteract the ROS-induced distortion of the gastrointestinal lumen. Esomeprazole therapy can lessen the ulcerative and oxidizing effects of exposure to cold water. PPIs, which are known to cause hypergastrinemia, activate pancreatic beta cells.^[11] This may be the result of gastrin-mediated mechanisms, hydroxyl radical ($\bullet\text{OH}$), which is what gives esomeprazole its anti-ulcerative and ameliorative effects, is scavenged by the drug's antioxidant properties, which have also been proven.

Conclusion

Comparing the crude drug mixture of *Manuka honey* and *Cinnamomum zeylanicum nees* powder to the standard medication Esomeprazole, the current study found that it has greater anti-ulcer and antioxidant efficacy. According to phytochemical screening, the presence of flavonoids, triterpenes, may be responsible for anti-oxidant capability, as well as improving antioxidant status and mucus formation. These factors may be responsible for the protective effect on gastric ulcer treatment. The suggested crude drug mixture of *Cinnamomum zeylanicum Nees* and unprocessed *Manuka honey* might make a good subject for additional clinical trials.

References

1. H. P. Rang, Pharmacology, Churchill Livingstone, Edinburgh, UK, 2003.
2. K. R. DeVault and N. J. Talley, "Insights into the future of gastric acid suppression," *Nature Reviews Gastroenterology and Hepatology*, vol. 6, no. 9, pp. 524–532, 2009.
3. K. S. Mota, G. E. N. Dias, M. E. F. Pinto et al., "Flavonoids with gastroprotective activity," *Molecules*, vol. 14, no. 3, pp. 979–1012, 2009.
4. Kusumawati, A. H., Wulan, I. R., & Ridwanuloh, D. (2020). Formulation and physical evaluation sheet mask from red rice (*Oryza Nivara*) and virgin coconut oil (*Cocos Nucifera* L). *International Journal of Health & Medical Sciences*, 3(1), 60-64. <https://doi.org/10.31295/ijhms.v3n1.148>
5. M. C. Brucker and M. A. Faucher, "Pharmacologic management of common gastrointestinal health problems in women," *Journal of Nurse-Midwifery*, vol. 42, no. 3, pp. 145–162, 1997.
6. P. Arda-Pirincci, S. Bolkent, and R. Yanardag, "The role of zinc sulfate and metallothionein in protection against ethanolic induced gastric damage in rats," *Digestive Diseases and Sciences*, vol. 51, no. 12, pp. 2353–2360, 2006.
7. S. Patel and S. Cichello, "Manuka honey: an emerging natural food with medicinal use," *Natural Products and Bioprospecting*, vol. 3, pp. 121–128, 2013.
8. S. W. Park, T. Y. Oh, Y. S. Kim et al., "Artemisia asiatica extracts protect against Cold water injury in gastric mucosa of rats," *Journal of Gastroenterology and Hepatology*, vol. 23, no. 6, pp. 976–984, 2008.
9. S.-H. Chen, Y.-C. Liang, J. C. J. Chao et al., "Protective effects of Ginkgo biloba extract on the Coldwater gastric ulcer in rats," *World Journal of Gastroenterology*, vol. 11, no. 24, pp. 3746– 3750, 2005. [5] S. I. Abdelwahab, M. M. E. Taha, M. A. Abdulla et al., "Gastroprotective mechanism of *Bauhinia thonningii* Schum," *Journal of Ethnopharmacology*, vol. 148, no. 1, pp. 277–286, 2013.
10. Suryasa, I. W., Rodríguez-Gámez, M., & Koldoris, T. (2021). Get vaccinated when it is your turn and follow the local guidelines. *International Journal of Health Sciences*, 5(3), x-xv. <https://doi.org/10.53730/ijhs.v5n3.2938>
11. Y. Du, W. Zhao, L. Lu et al., "Study on the antiulcer effects of *Veronicastrum axillare* on gastric ulcer in rats induced based on tumor necrosis factor- α (TNF- α) and endothelin-1 (ET-1)," *Asian Pacific Journal of Tropical Biomedicine*, vol. 3, no. 12, pp. 925–930, 2013.
12. Y. Kato, N. Umeda, A. Maeda, D. Matsumoto, N. Kitamoto, and H. Kikuzaki, "Identification of a novel glycoside, leptosin, as a chemical marker of manuka honey," *Journal of Agricultural and Food Chemistry*, vol. 60, no. 13, pp. 3418–3423, 2012.