

**How to Cite:**

Rajamanickom, A., Prasanth, S. T., Palanisamy, K. K., & Bikkad, P. (2022). A rare case study of myxoid chondrosarcoma in 4th metacarpal hand. *International Journal of Health Sciences*, 6(S5), 11369–11376. <https://doi.org/10.53730/ijhs.v6nS5.11002>

## **A rare case study of myxoid chondrosarcoma in 4<sup>th</sup> metacarpal hand**

**Dr. Arun Rajamanickom**

Assistant Professor, Department of Orthopedics, Vmkv Medical College Salem

**Dr. S. Thaya Prasanth**

Junior resident, Department of orthopedics, Vmkv Medical College Salem

**Dr. Kathirvel Kumaran Palanisamy**

MS, DNB, MCH (Surgical Oncology), Vmkv Medical College Salem

**Dr. Pranit Bikkad**

Junior Resident, Department Of Orthopedics, Vmkv Medical College Salem

**Abstract**---Background: myxoid chondrosarcoma (MC) is a rare soft tissue tumor that typically affects the lower limbs of men between the ages of 50 and 60. EMC of the Metacarpals is rare of rarest with a high risk of local recurrence and distant metastasis. A planned surgical excision in sarcoma referral centers (SRCs) is mandatory to obtain the best outcome. The role of chemotherapy (CHT) and Radiotherapy (RT) on soft tissue chondrosarcoma is still under study. Case presentation: A 53-year-old male patient presented to our hospital with a history of swelling in the left hand for 6 months. Radiological and histological study reveals diagnosis of extra skeletal chondrosarcoma. Wide surgical excision was done using cryotherapy in form of liquid nitrogen. Biopsy was taken from the site and sent to immunohistochemistry which proved the diagnosis. A Kirschner wire embedded with polymethylmethacrylate cement was placed in defect site and checked for movements. imaging exams did not reveal distant metastasis or residual disease. Local radiotherapy was administered with a total dose of 50 Gy and adjuvant chemotherapy was given. No relapse occurred in a 12-months post-operative follow up. **Conclusions:** The case here described suggests the importance of patient's management in SRCs. A planned combined treatments with both surgery and RT seems to be the best choice to improve local control. Surgical excision with reconstruction 4<sup>th</sup> metacarpal followed by local radiotherapy and adjuvant chemotherapy to be promising within this specific histotype.

**Keywords**---myxoid chondrosarcoma, metacarpal hand, surgical excision.

## **Introduction**

Chondrosarcomas is a group of rare bone cancer tumors that begin in your cartilage. Cartilage is soft connective tissue that allows movement between your bones and joints. The chondrosarcoma normally starts in the bones but can occasionally develop in the soft tissue next to the bones. Chondrosarcoma most frequently develops in the shoulder, hip, and pelvis. In the spine's bones, it might happen less often.<sup>1</sup>

Most chondrosarcomas are slow-growing and may not initially manifest many signs and symptoms. Some uncommon kinds of cancer can be challenging to treat because they develop quickly and are very likely to spread to other parts of the body.<sup>2</sup>

The most frequent benign cartilaginous bone tumours that develop in the medullary cavity of the hand's tiny bones are enchondromas. In contrast, chondrosarcomas are less prevalent in the little hand bones than they are in the pelvic, proximal femur, and humerus. Rarely do enchondromas develop into chondrosarcomas. Multiple enchondromatosis exhibits this change more frequently than single lesions, however even this occurrence is uncommon in the hands. Even in low-grade hand chondrosarcomas, radical excision is advised due to the high risk of recurrences associated with restricted surgical techniques such as curettage.<sup>3</sup> Myxoid chondrosarcoma of the hand or wrist has only seldom been documented, and the instances that have been are especially skeletal in appearance.

## **Case Presentation**

### **History**

A 53-year-old male patient presented to our hospital with a history of swelling and pain in the left hand for over 6 months. The Patient on detailed evaluation and History of the condition revealed that the swelling was gradual, insidious in onset and became gradually swelling became progressive for over a span of 5 to 6 years. In the initial phase of the swelling it was not associated with any kind of Pain hence the patient also did not bother to turn up in the hospital for the evaluation of the swelling. In past 6 to 8 months the swelling is associated with the pain which is severe in nature and gets relived by the medication. The Swelling was not associated with any kind of constitutional symptoms.

### **Clinical examination**

On Clinical examination of the patient the swelling was noted in the left hand around the 4<sup>th</sup> metacarpal bone measuring around 5\*5\*4.5 cms encroaching up to 5<sup>th</sup> metacarpal and surrounding soft tissues. The swelling was ovoid in shape and the surface was smooth with well defined borders as shown in figure 1.

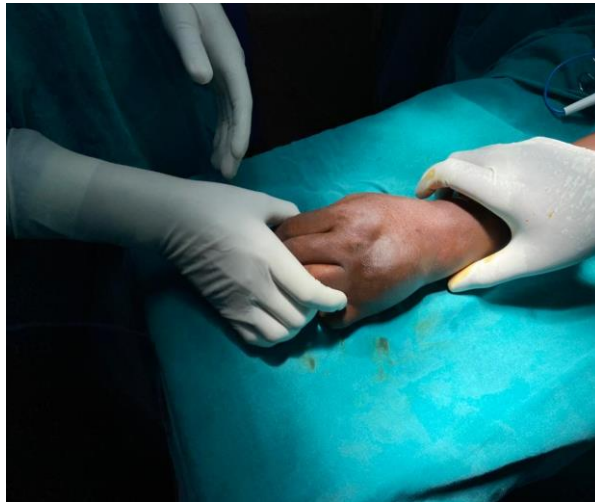

Figure 1: Clinical Photograph of the Swelling before the surgery

The fingers and the surrounding area around the swelling was found to be well vascularized and no surgical marks of previous operation or any injury was visible. The consistency of the swelling was found to be variable from hard to tender with irregular thickening around the borders. The underlying bone of metacarpal could not be palpable separately and the overlying skin was shiny with dilated veins. There was some restriction of movements at 4<sup>th</sup> and 5<sup>th</sup> Metacarpophalangeal joint.

### Investigation

X ray of the left hand in oblique and anterior posterior view was taken and the findings showed irregular moth eaten appearance and erosion of the underlying 4<sup>th</sup> metacarpal and 5<sup>th</sup> Metacarpal bone was seen with bone expansion and cortical destruction and soft tissue extension as shown in figure 2 .

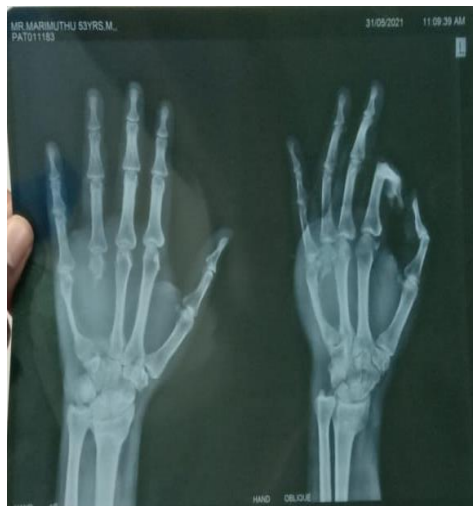

Figure 2: X Ray of the involved area

On further evaluation the swelling with the MRI investigation there was complete destructive lytic erosion lesion involving 4<sup>th</sup> metacarpal shaft and also associated with signal lobulated soft tissue mass measuring 5.0\*4.7\*4.2\* cms at the level of destruction with the extension into 4<sup>th</sup> to 5<sup>th</sup> intermetatarsal space causing scalloping and remodeling of lateral aspect of 5<sup>th</sup> Metacarpal shaft. Soft tissue lesion was heterogeneous hypo intensive in T1W heterogeneous hyperintense in T2W. Dorsally the lesion is contacting the deeper aspect of the related extensor tendon and on volar aspect contacting related to flexor tendons. Osseous lesions were found to be aggressive and benign in nature.

On Further subjecting the patient for biopsy the histopathological report mentioned of microscopic features of fragmented neoplasm which are arranged in lobules and separated by fibromuscular stroma. The neoplastic cells are pleomorphic spindle to ovoid with moderate eosinophilic cytoplasm. The nucleus were hyperchromatic, bizarre, multinucleate and vesicular with nucleoli. The Lobules shows myxoid background and areas of necrosis was also seen. The Final impression of the histopathology was myxoid Sarcoma of the Fourth Metacarpal bone.

### **Surgery**

Wide surgical excision was done using cryotherapy in form of liquid nitrogen. Biopsy was taken from the site and sent to immunohistochemistry which proved the diagnosis. A Kirschner wire embedded with polymethylmethacrylate cement was placed in defect site and checked for movements. Imaging examination did not reveal distant metastasis or residual disease. Local radiotherapy was administered with a total dose of 50 Gy and adjuvant chemotherapy was given. No relapse occurred in a 12-months post-operative follow up

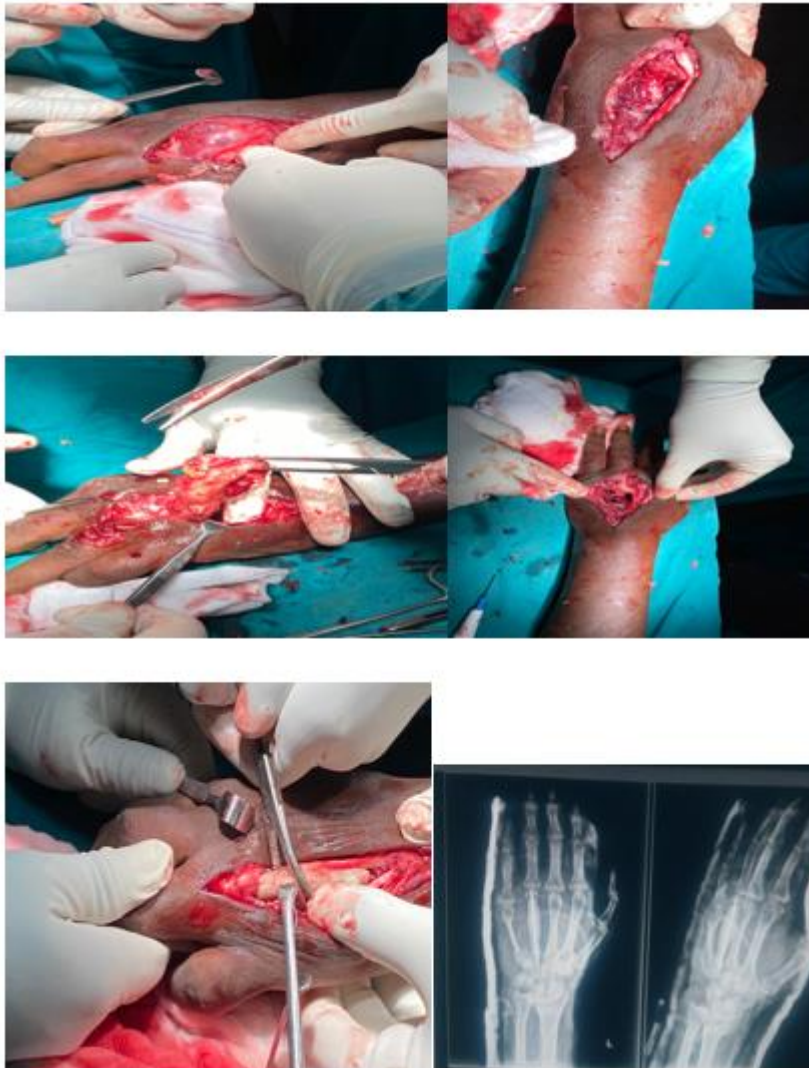


Figure 3: Surgical Approach and the outcome of the surgery.

### Discussion

Osteosarcoma commonly affects youngsters and begins in the bone. Chondrosarcoma commonly affects adults and begins in the cartilage. Healthcare professionals can treat osteosarcoma with chemotherapy and surgery while treating chondrosarcoma with surgery alone.<sup>4</sup> Since chondrosarcoma often grows slowly, it may not initially manifest any symptoms. When they manifest, chondrosarcoma signs and symptoms may include Swelling, pain and restricted movements .<sup>4</sup>

Growing older is one factor that might raise the risk of chondrosarcoma. Chondrosarcoma can affect anybody, however it most frequently affects middle-aged and older individuals. The body develops noncancerous bone growths

(enchondromas) as a result of other bone illnesses such as Ollier's disease and Maffucci's syndrome. These growths can occasionally develop into chondrosarcomas.<sup>5</sup>

About 10% of primary malignant bone tumours are chondrosarcomas, which are most common in the fifth and sixth decades of life. 3:1 is the male to female ratio.<sup>6</sup> Although they can arise anywhere, the majority do so in the pelvis, proximal femur, and humerus.<sup>2</sup> Primary central chondrosarcomas, which account for 85% of conventional chondrosarcomas, and secondary peripheral chondrosarcomas, which account for the remaining 15% .<sup>2,6</sup> A very aggressive lesion, chondrosarcoma affects the hand's metacarpal bone. For the diagnosis of chondrosarcoma, indicators such as painful swelling that lasts for a long time in the elderly, cortical uneven thickening, disruption, and soft tissue expansion are helpful.<sup>7</sup>

With a frequency of less than 1.5 percent to 3.2 percent of all chondrosarcomas, primary chondrosarcomas are uncommon in the hand.<sup>8</sup> Chondrosarcomas have been identified in the phalanges, metacarpals, trapezium, and trapezoid of the hand.<sup>2</sup> Although still uncommon, metacarpal involvement .<sup>9</sup> In the review of literature done by Nekkanti S et al <sup>10</sup>a total of 32 cases of skeletal myxoid chondrosarcoma were studied and the mean age of presentation from these cases was found to be 42 years which is almost near to the age group of our case. Out of these 32 cases most of them had lesions in the femur and only 3 cases were reported in that study which involved hand and wrist.

Though most of the studies opined about wide dissection of the lesion is the best treatment and the study done by Hitchon H et al<sup>11</sup> and Enzinger F M et al<sup>12</sup> also opined that little success has been documented with use of chemotherapy and radiation in controlling myxoid chondrosarcoma tumor. Whereas in our study we found contrasting results to their opinion and with no relapse of the symptom even after 12 months post surgery thus proving the above statement wrong. In a case described by Wirbel and Remberger,<sup>13</sup> a chondrosarcoma of the right hand's first metacarpal bone was originally misdiagnosed radiographically as an enchondroma and was traditionally treated with curettage and bone grafting. After a final histological analysis, chondrosarcoma was determined to be the cause, and the metacarpal bone was widely removed. To prevent local recurrence or metastasis, the metacarpal bone was then rebuilt utilising corticocancellous bone transplant and plate fixation.

A single enchondroma was discovered at the right hand's index finger by Demireli et al.<sup>7</sup> The lesion was identified as an intermediate grade chondrosarcoma emerging subsequent to the prior solitary enchondroma seven months later when the tumour reappeared and became destructive. In order to prevent metastasis or local recurrence, the tumour underwent extensive excision.

## **Conclusion**

Hand chondrosarcomas are quite uncommon. In addition, there are surprisingly few examples of enchondromas developing into chondrosarcomas that have been reported in the literature. However, excision of an enchondroma must be carried

out as quickly as feasible while bearing in mind this unlikely probability. Compared to enchondroma, chondrosarcoma needs more aggressive therapy right away. A painful swelling in the hand that lasts for a long time in the elderly, together with cortical uneven thickening, destruction, and soft tissue extension, are helpful markers for the diagnosis of chondrosarcoma in addition to histological findings.

## References

1. Canale, Beaty. Campbell's Operative Orthopaedics. 11th ed. 2007;vol. 22. 907e910.
2. Chaudhary S, Singh D, Sen R. Chondrosarcoma of Distal Radius- A case report and brief review of literature. Webmed Central Orthopaedics. 2010;1:WMC 001274,1-9.
3. Chondrosarcoma.Disease and Condition. Patient care and health information.Mayo Clinic. (Internet){ Assesed on 2022 June 25}. Avilable from <https://www.mayoclinic.org/diseases-conditions/chondrosarcoma/symptoms-causes/syc-20354196>
4. Demireli P, Cavdar DK, Vural S, Ovali GY, Ozalp T. Secondary chondrosarcoma arising from a solitary enchondroma at the index finger of the right hand- a case report. Turkish Journal of Pathology. 2006;22:53-6
5. Enzinger FM, Shiraki M. Extra skeletal myxoid chondrosarcoma. An analysis of 34cases. Hum Pathol. 1972;3:421-35.
6. Higinbotham NL, Phillips RF, Farr HW, Hustu HO. Chordoma. Thirtyfive-year study at Memorial Hospital. Cancer. 1967; 20:1841-50.
7. Hitchon H, Nobler MP, Wohl M, Levy W. The radiotherapeutic management of chordoid sarcoma. Am J Clin Oncol. 1990;13:208-213.
8. Kavitha KP, Savithri MC, Ramani KC, Puthoor D. Periosteal chondrosarcoma of the metacarpal bone- Report of a rare entity. Australasian Medical Journal. 2012;5,11,589- 92.
9. Knigavko, O., Baranova, N., Bausov, I., Dolzhenko, M., & Lantukhova, N. (2022). Organizing treatment in emergency health care facilities during COVID-19 pandemic conditions in Eastern European countries. International Journal of Health Sciences, 6(1), 149–159. <https://doi.org/10.53730/ijhs.v6n1.3582>
10. Muller PE, Durr HR, Nerlich A, PellengahrC, Maier M, et al . Malignant transformation of a benign enchondroma of the hand to secondary chondrosarcoma with isolated pulmonary metastasis. Acta Chir Belg. 2004;104:341-4.
11. Nekkanti S, Ravikiran, Mrutyunjaya, Varun K. A rare case of skeletel myxoid chondrosarcoma of the 5th metacarpal managed by surgical reconstruction using a novel technique Journal of Bone and Soft Tissue Tumors Sep - Dec 2017;2(3):3-6.
12. Nelson DL, Abdul-Karim FW, Carter JR, Makley JT. Chondrosarcoma of small bones of the hand arising from enchondroma. J Hand Surg. 1990;15 A:655e659
13. Rosai J, Ackerman LV. Bones and Joints. In: Rosai J ed. Rosai and Ackerman's Surgical Pathology, 10th edn, St. Louis; Mosby Elsevier: 2011, pp 2013-104
14. Suryasa, I. W., Rodríguez-Gámez, M., & Koldoris, T. (2021). Get vaccinated

- when it is your turn and follow the local guidelines. *International Journal of Health Sciences*, 5(3), x-xv. <https://doi.org/10.53730/ijhs.v5n3.2938>
15. Wirawan, I. G. B. (2018). Surya Namaskara benefits for physical health. *International Journal of Social Sciences and Humanities*, 2(1), 43-55. <https://doi.org/10.29332/ijssh.v2n1.78>
  16. Wirbel RJ, Remberger K. Conservative surgery for chondrosarcoma of the first metacarpal bone. *Acta Orthopaedica Belgica*. 1999;65:226-9