

How to Cite:

Baiomy, A. A. B. A., El-Sayed, A. K., Gawish, A., & Elsayed, S. A. (2022). Clinical and radiological comparison of a dynamic implant valve vs a hydraulic maxillary sinus lift augmentation technique with simultaneous implant insertion. *International Journal of Health Sciences*, 6(S4), 10605–10617. <https://doi.org/10.53730/ijhs.v6nS4.11198>

Clinical and radiological comparison of a dynamic implant valve vs a hydraulic maxillary sinus lift augmentation technique with simultaneous implant insertion

Abdel Aziz Baiomy Abdullah Baiomy

Department Oral and Maxillofacial Surgery, Faculty of Dental Medicine, Al-Azhar University, Assuit, Egypt

Corresponding author email: Abdelazizbaiomy@azhar.edu.eg

Amany Khalifa El-Sayed

Department of Oral and Maxillofacial Surgery, Faculty of Oral & Dental Medicine, Modern University for Technology & Information, Cairo, Egypt

Abeer Gawish

Department of Periodontology, Faculty of Dentistry, Sinai University, Sinai, Egypt

Shadia A. Elsayed

Department of Oral and Maxillofacial Surgery, Faculty of Oral & Dental Medicine for Girls, Al-Azhar University Cairo, Egypt

Email: shadiaelsayed@azhar.edu.eg

Abstract---The study aimed to compare between dynamic implant valve (DIVA) and the crestal ballooning techniques in elevating the maxillary sinus membrane (MSM) in conjunction with simultaneous implantation. Patients and methods: 20-patient prospective clinical cohort study. Ages ranged from 42 to 53 years, and had atrophic edentulous maxillae in the posterior region. To determine maxillary sinus status, patients were investigated utilizing intraoral clinical photographs and CBCT series. Closed Sinus Lifting done and compared between DIVA and ballooning techniques on patients who were randomly separated into two equal groups. The predicted research variables were intraoperative primary stability and level of sinus membrane lift. The main outcome factors were secondary implant Osseointegration stability (ISQ) and the amount of bone height gain. Results: Before surgery, the DIVA and Balloon groups had mean bone heights of $5.8 \pm 0.67\text{mm}$ and $6.8 \pm 0.86\text{mm}$, which increased significantly to 12.8 ± 0.53 and 10.8 ± 0.67 after 6 months postoperatively. ISQ for DIVA and Balloon groups were 39.0 ± 2.16 and

40.0±2.16 preoperatively, respectively, and increased to 71.7±1.60 and 70.4±1.27 nine months postoperatively which was significantly higher at 3 months in DIVA group. Conclusion: the CAS-Kit and DIVA techniques for maxillary sinus lifting are successful, atraumatic, and safe, with DIVA exceeding CAS-Kit in terms of vertical bone height obtained.

Keywords---sinus membrane, bone height, crestal approach, direct implant valve, balloon technique.

Introduction

Implant surgery is complicated by atrophy of the residual maxillary ridge and decreased bone densitometric properties. This is attributable in part to the accelerated alveolar bone resorption and maxillary sinus pneumatization following tooth extraction.¹⁻⁴ A maxillary sinus lift (MSL) technique was created to address such anatomical and physiological problems, and it is now commonly used in oral surgery clinics. Depending on the remaining residual ridge, the lateral or crestal technique is employed to elevate the maxillary sinus membrane (MSM).⁵⁻⁸ Tatum⁸ first proposed a crestal technique for sinus membrane lift elevation in 1986. Summers,⁹ proposed the osteotomy technique, which uses a crestal approach in a straightforward, conservative, and minimally invasive approach than the lateral surgical technique. However, there are some disadvantages to this approach, including the fact that the osteotomy technique is highly dependent on the clinician's expertise and that MSM perforation can occur during malleating¹⁰. Furthermore, after malleating, the osteotomy approach causes problems such as headache and vertigo.^{11,12}

Therefore, other surgical techniques and equipment have been created¹³. Among these surgical methods, devices that used hydraulic pressure which revealed a minimal risk of sinus membrane perforation as well as convenience of use. One of these devices, the CAS-Kit, was created for crestal approach MSM elevation using a specific drilling system and hydraulic pressure. According to studies,¹⁴ employing CAS-Kit, a high-speed drills with a specific blades, rapid and safe sinus membrane elevation could be achieved even at the sinus septum, lowering the danger of sinus membrane perforation. The hydraulic lifter in the CAS kit, on the other hand, was not a very convenient. As a result, investigators concluded that sinus lift devices need to be improved or developed further to make them safer and more user-friendly^{9,15}.

Direct-Implant-Valve Approach (DIVA) was recently manufactured using an internal sealing screw for bone augmentation supply system and potential endoscopic direct monitoring via its channel. DIVA was used when implant needed to be combined with MSL and/or bone augmentation¹⁵. A small number of studies evaluated DIVA's efficacy in crestal MSL with simultaneous implant insertion to other techniques that used hydraulic pressure for MSL and simultaneous implant insertion¹⁶. As a result, the goal of this study was to objectively compare DIVA and CAS- Hydraulic Kit for immediate implant insertion in the posterior atrophic maxillary ridge.

Patients and Methods

The current study was a randomized clinical trial that ran from July 2019 to July 2021 at Al-Azhar University's Assiut Branch's, Faculty of Dental-Medicine, Department of Oral and Maxillofacial Surgery (OMS). It included 20 patients (nine men and eleven females) ranging in age from 42 to 53 years.

Criteria for inclusion and exclusion

Healthy patients with no history or clinical signs of any systemic disorders that may compromise implant bone osseointegration, or maxillary sinus condition were included in the present study. Patients had a sub-antral distance $\leq 8\text{mm}$ and a missing posterior maxillary teeth were also included. Systemically administered anticoagulants, bisphosphonates, steroids, or immunosuppressant medications were all excluded. Patients with a sinus infection (chronic sinusitis, retention cyst, mucocele, tumour, polyp) or a history of previous sinus surgery, or smoking were excluded. The study eliminated patients who were undergoing head and neck radiation or who exhibited bruxism, parafunctional habits, and/or a lack of stability in the posterior occlusion.

Grouping and randomization technique of patients

All patients completed an informed consent form after being fully informed about the study methodology, treatment plan, and alternative therapeutic alternatives. On the day of the procedure, patients were randomly assigned into two equal groups using Randomizer.org software. The study was carried out in agreement with the Helsinki Declaration, and the Al-Azhar University Ethics Committee provided its approval (AUAREC20210609-12 approval code).

Group I: The DIVA system (Palto – Germany) was used to do a crestal sinus lift.

Group II: A CAS crestal sinus lift kit (Osstem Implant Co., Busan, Korea) was used.

Instruments and materials

The DIVA kit has the following features

DIVA Implant was included in the DIVA box. The implant (Ti-6Al-4V ELI) had an internal sealing screw that could be used for endoscopic direct monitoring as well as drug distribution through its channel. Internal Screw Driver: This screw driver was inserted inside the DIVA smart implant and is removed once the DIVA device had reached primary stability. Its principal function was to keep bone particles out of the DIVA channels. The second valve screw: at the end of the process, it was placed into the DIVA device to completely seal the implant. Screw Driver was used to insert and remove the valve screws from the DIVA device. At the end of the sinus lift surgery, cover screw was used to cap the DIVA device. Disposable Syringe was used to inject saline into the sinus using the DIVA device. IV Cannula was used instead of the fluid adapter when the DIVA smart implant was placed at the back of the mouth or in areas where the mouth opening is too small.

The CAS kit has the following features

Two types of drills are included in the CAS kit. The initial drilling is done with a twist drill that can be attached to a stopper. Stoppers with lengths ranging from 2.0mm-12.0mm were included. The twist drill has a maximum depth of 2.0mm from the sinus membrane and the recommended speed was 1,000–1,500 rpm. The CAS drill is the other sort of special drill. Due to the conical shape of the CAS drill tip, a conical hole is created in the bone after. The hydraulic lifter is connected to a 1.0-mL syringe filled with saline solution. In the case of a single implant, a saline solution of 0.2–0.3 mL elevates the membrane by around 3.0 mm. The bone carrier and the bone condenser were utilised to fill the hole with bone graft.

Sinus augmentation with a bone graft

The maxillary sinus was grafted in both groups using the gel form bone grafting material Tricalcium phosphate sterile resorbable bone substitute in hyaluronic acid (Genoss Company, Korea)

Preoperative evaluation

Preoperative intraoral examination and maxillary sinus evaluation were performed for all patients. Pre-operative CBCT was used to determine the present bone height (RBH) beneath the sinus lining. During implant bed preparation, digital periapical radiographs were also collected. A surgical guide template made of clear acrylic and a metal sleeve were used to determine implant placement prior to surgery.

Operative technique

To ensure complete anesthesia of the surgical site, a posterior and middle superior alveolar nerve block, as well as a larger palatine nerve block, were administered using (2% Lignocaine with 1:100,000 adrenaline). An alveolar crestal horizontal incision combined with a sulcular incision of adjacent teeth was made. Alveolar bone was exposed when the muco-periosteal envelope flap was lifted. Pilot drill was guided by a surgical guide template.

Group one (DIVA group): A 2mm drill was applied after the pilot drill to go up to 1mm from the sinus floor. A 2.7mm curved osteotome was utilized after drilling to achieve a 1mm level from the sinus floor. This technique compresses the crestal bone, resulting in a bone disc that is then transferred to the sinus via the implant apex and slow ratcheting. The implant was placed into the bone until primary stability achieved (Fig 1a, b & c). The internal screw was then removed. By irrigating with 1 cc of saline through the internal port. The DIVA injection adaptor was used to infuse gel type bone substitute into the inner channel space (Fig.1d&e). Wound closure was accomplished with a non-absorbable (4/0) black silk suture.

Group II (CAS-Kit): A pilot drill was used after exposing alveolar bone, followed by a 2mm drill, stopping 1mm inferior to sinus floor (according to CBCT imaging)

(Fig.2a). The drill's diameter was increased in steps, taking into account the diameter of the implant to be inserted. The drill was connected to a stopper of the same height as the premeasured height of residual bone before final drilling, and the MSM was elevated. To assess for penetration through the MSM, a depth gauge was inserted. To raise the MSM, the hydraulic lifter was put into the drilled hole and 0.3mL saline solution was steadily administered with a 1.0mL syringe (Fig.2 b & c). Following the implantation of a gel form bone grafting substance. A bone condenser was then used to pack the bone graft into the osteotomy bed and push it. The dental implants were put after the needed amount of bone replacement was placed for elevation (Fig2d&e). Dental implants (ROOTTS implant, SWESS Dental Inc) with lengths of 10 and 12 mm and diameters of 3.7 to 5 mm were put into the osteotomy site using a hand screw driver until the coronal first thread of the implant was embedded in the bone. The wound was closed with non-absorbable black silk suture gauge (4/0).

Postoperative care

Cold packs instruction were given to the patients and to maintain proper dental hygiene after the surgery. For 7 days after surgery, patients were given augmentin (625 amoxicillin trihydrate, 125 mg clavulanic corrosive, GSK Glaxo Smith kline, Egypt) twice a day. Ibuprofen 600mg (Brufen kahira pharma& CHEM. IND.CO. Cairo-Egypt) was administered twice daily for 1 to 3 days following the surgical procedure as an anti-inflammatory and pain-relieving medicine. Chlorhexidine mouthwash (Antiseptol Kahira CO. for pharm. and Chem.,IND organisation, Cairo, Egypt) was used twice daily for three weeks following surgery.

Follow up clinical assessment

For the first week after implant placement, daily follow-up was undertaken, followed by weekly follow-up for the first month for any signs of infection, discomfort, edoema, or other post-operative problems. Probing Depth (PD) was measured using a William's probe at four points around implants, from the crest of the gingival edge to the bottom of the gingival sulcus. Changes in Implant Stability Quotient (ISQ): Primary stability was measured immediately after implant placement and at 6 months for each implant using Osstell (Osstell AB Stampgatan 14, Goteborg, Sweden).

Radiographic Evaluation

CBCT images were captured prior to surgery (baseline time), then 3, 6, and 12 months after surgery to assess crestal bone loss and bone density at the bone graft-implant border.

Measuring crestal bone height

In coronal section, a straight line was drawn from the buccal marginal bone level around the dental implant to the point of junction with the axial orientation and perpendicular to it. The height achieved was measured in millimetres. The same thing happened on the lingual side. In the sagittal section, the technique was repeated on the mesial and distal sides.

Measuring bone density

In coronal section, a straight line was drawn from the buccal marginal bone around the implant to the apical end of the implant, just parallel to the implant; the mean bone density obtained was recorded in HU (making use of the ROI tool present in the software). On the lingual side, the exact procedure was used. . In the sagittal section, the technique was repeated on the mesial and distal sides. Following that, the average bone density around the dental implant was calculated.

Statistical analysis

The data was gathered, tabulated, and statistically analysed using the Statistical Package for Social Sciences (SPSS) version 25. The frequency distribution and descriptive statistics were analyzed. An unpaired t test was used to compare the groups. For comparisons within groups, a paired t test was performed. P 0.05 was considered as statistically significant. The Microsoft Excel 2019 application was used to create the graphs.

Results

This study included 20 adult patients ranging in age from 42 to 53 years (mean 47.5 years). Nine patients had unilateral sinus lift, while eleven had bilateral treatments. The total number of sinus lift sites treated was 42, with a total of 42 dental implants used. During the first three months after implant insertion, two implants (one in each group) were lost in two patients. The data from these two patients (2 locations, 2 implants) were all excluded from the evaluations. During surgery, one patient had a perforated sinus membrane, resulting in nasal leakage (blood and bone graft residuals). Short-term postoperative symptoms included benign paroxysmal positional vertigo and sinusitis in two patients. Mild infraorbital ecchymosis were reported as minor post-operative problems that healed on their own without the need for intervention. There were no long-term post-operative problems such chronic sinusitis, mucocoele, or oroantral fistula in any of the cases.

Probing Depth measurement (PD)

At 6 months, the mean probing depth in the DIVA group was $2.07\text{mm} \pm 0.33$, which climbed to $3.3\text{mm} \pm 0.20$ after 12 months. At 6 months, the mean probing depth in the CAS-Kit group was $1.77\text{mm} \pm 0.16$, which increased to $2.5\text{mm} \pm 0.03$ after 12 months (Fig.3). When comparing the 12 month observation interval to the 6 and 9 month observation intervals in two groups, the paired t-test revealed a high statistically significant difference. By the end of the study, all groups' probing depth had increased gradually. The unpaired-test was used to compare probing depth between groups, and no differences were found after six, nine, and twelve months of observation. In two groups, the probing depth increased, although it remained within the acceptable range ($\leq 3\text{mm}$).

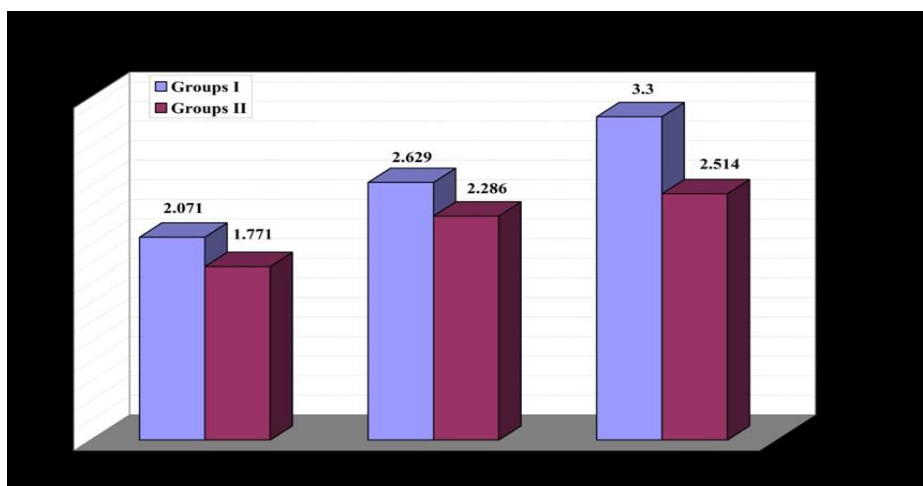


Fig 3: Bar chart showing probing depth between groups at different intervals

Implant Stability Quotient (ISQ)

The mean ISQ values in both groups increased during the observation period. At the time of implantation, the DIVA group's mean ISQ value was 39.00 ± 2.16 , and the CAS-Kit group's mean ISQ value was 40.00 ± 2.12 , according to RFA measurements. During the observation period, the mean ISQ values in both groups increased. At the last study's interval, the mean ISQ value in the DIVA group was 71.71 ± 1.60 , and 70.43 ± 1.27 in the CAS-Kit group. Immediately after implant insertion, there were no statistically significant differences in primary stability between the two groups. At 3 months following implantation, the only significant difference in mean ISQ values between the two groups was seen ($P=0.001$)(Table I).

Vertical bone height

After 6 months postoperatively, there were statistically significant difference in the amount of vertical bone height gained between the two groups. The DIVA group increased $12.8\text{mm} \pm 0.53$ of vertical bone height, while the CAS-Kit group acquired $10.8\text{mm} \pm 0.67$. A paired t-test demonstrated that the difference in pre-operative versus post-operative vertical bone height was highly statistically significant in all groups. At immediate placement, the mean vertical bone height in the CAS-Kit group was $6.8 \text{ mm} \pm 0.86$, which increased to $10.8 \text{ mm} \pm 0.67$. The mean vertical bone height in group DIVA was $5.8 \text{ mm} \pm 0.67$ at the start of the study and increased to $12.8 \text{ mm} \pm 0.53$ after that. An unpaired-test was used to evaluate the pre-operative and post-operative vertical bone heights of the two groups, revealing a highly statistically significant difference between the two groups. (Table II).

Bone Density Measurement Changes (BD)

The paired t-test revealed a progressive increase in bone density measurements in both groups over the period of the study's observation periods. The mean value of bone density in the DIVA group was 472.7 ± 54.14 at immediate placement and increased to 667.7 ± 63.26 after 6 months, with the difference between groups

emerging highly statistically significant at 3, and 6 months when compared to immediate placement.

The mean value of bone density in the CAS-Kit group was 466.1 ± 42.64 at immediate placement and increased to 654 ± 57.54 after 6 months, with the difference within the group being highly statistically significant at 3, 6, and 12 months as compared to immediate placement. When comparing groups using the unpaired-test, there was no statistically significant difference at all intervals (Table II).

Discussion

Inadequate bone volume in the posterior area of the maxillae is a common problem that clinicians must resolve, especially with the rising prevalence of sinus pneumatization in our communities¹⁷, especially if the patient refuses a removable prosthetic solution and requires an implant-supported prosthesis. The jawbone must have enough bone to support dental implants for them to be successful¹⁸. Several surgical methods can be performed to grow bone in the posterior maxilla in preparation for implant insertion. One of them is maxillary sinus lifting. Sinus lift is a well-known procedure for restoring vertical bone height in the posterior maxilla.^{19,20}

The closed crestal approach is less invasive than the open lateral approach, with a smaller flap design and less extensive osteotomy. As a result, patients tolerate crestal surgery better than lateral sinus access, and problems are less common. Despite the fact that the transcresal sinus lifting method is performed blindly, sinus membrane perforation is claimed to be less common than with the lateral approach and this was supported by our study findings⁴

After 9 months of implant implantation, RFA measurements utilising Osstell revealed that implant stability increased during the healing period, with mean ISQ values of 71.71 ± 1.60 for DIVA implants and 70.43 ± 1.27 for CAS-Kit implants. This conclusion was consistent with numerous studies that found an increase in implant stability during the healing period when SFE operations were performed concurrently. The strength of osseointegration is usually determined by implant stability.^{11,12,14,15,21} The mean initial ISQ values at surgery in both groups were 39.00 ± 2.16 and 40.00 ± 2.12 , respectively, in this sample. The ISQ levels at the time of operation are low when compared to the values at 6 months, which are 70.43 and 68.71. This is consistent with Turkyilmaz & McGlumphy's²¹ study, which found that RFA values were highly linked with the amount of bone-to-implant contact.

These findings could be explained by a correlation between the amount and distribution of bone grafts around dental implants, as gel form bone graft was resorbed and replaced by natural bone in group I, resulting in a circular symmetric distribution around DIVA implant as seen in periapical x-ray examination during the study. On the other hand, CAS-Kit group had uncontrolled directioning of bone graft insertion so made a wide area distribution in horizontal plane only not in vertical one. In the same point, the mean amount of bone graft materials that was used 0.80 ± 0.23 while in DIVA group was

0.51+_0.13 which was clinically important so, the membrane liability to perforate and (or folded) due to overfilling was possible in CAS - kit group, table. On the other hand, membrane in case of DIVA group, there were no membrane folding or perforation due to sequential insertion and stabilization of membrane by tenting effect that made need for less amount of bone graft injection.

After 3 months, the DIVA group had a mean vertical bone height of 13.28mm+0.50, while the CAS - kit group had a mean vertical bone height of 11.39mm+0.60, which was clinically significant. In group I, the necessary vertical bone height was obtained via sequential implant insertion and progressive membrane dissection by saline injection through the implant, as well as simultaneous gel form bone transplant. These results were comparable to those of Yassin et al²², who reported a vertical bone height of 7mm after membrane elevation in an animal study.

In group II, however, due to multiple balloon device entrances, multiple inflation and deflation to cause membrane dissection (prolonged time), and then injection of gel form bone graft materials followed by implant insertion, bone graft distribution was unequal, resulting in horizontal rather than vertical direction²³. This could explain the current findings, which reveal that although the two procedures did not differ in terms of bone density changes or implant stability scores, the DIVA group obtained significantly higher bone height than the closed ballooning approach group.

Conclusion

Despite the small sample size of the current investigation, the results demonstrated that the DIVA approach was a more successful and safe procedure for increasing alveolar bone height without generating substantial membrane perforation or other complications than the CAS- hydraulic Kit.

References

1. Abdelqader Altaweel A, Aziz Baiomy Abdullah Baiomy A, Abdel-Hameed Elsayed S. Effect of Nano-hydroxyapatite and platelet-rich fibrin covered by the amniotic membrane on osseointegration after mandibular piezoelectric ridge splitting. *Saudi Dent J*. 2021;33(1):27-33. doi:10.1016/j.sdentj.2019.11.008
2. Al-Moraissi EA, Alkhutari AS, Abotaleb B, Altairi NH, Del Fabbro M. Do osteoconductive bone substitutes result in similar bone regeneration for maxillary sinus augmentation when compared to osteogenic and osteoinductive bone grafts? A systematic review and frequentist network meta-analysis. *Int J Oral Maxillofac Surg*. 2020;49(1):107-120. doi:10.1016/j.ijom.2019.05.004
3. Aprianto, D. R., Parenrengi, M. A., Utomo, B., Fauzi, A. A., & Subagyo, E. A. (2022). Autograft and implant cranioplasty in pediatric patients. *International Journal of Health & Medical Sciences*, 5(1), 129-136. <https://doi.org/10.21744/ijhms.v5n1.1852>
4. Bernardello F, Massaron E, Spinato S, Zaffe D. Two-stage crestal sinus elevation by sequential drills in less than 4 mm of residual ridge height: A

- clinical and histologic case report. *Implant Dent.* 2014;23(4):378-386. doi:10.1097/ID.0000000000000120
5. Boyne PJ, James RA. Grafting of the maxillary sinus floor with autogenous marrow and bone. *J Oral Surg.* 1980;38(8):613-616. <http://europepmc.org/abstract/MED/6993637>.
 6. El-Prince O, Ragab H. Comparison Between Maxillary Sinus Lifting in Combination With Implant Placement With Versus Without Bone Grafts (Clinical and Radiographic Study). *Egypt Dent J.* 2020;66(1):113-122. doi:10.21608/edj.2020.77522
 7. Elsayed SA, Alolayan AB, Alahmadi A, Kassim S. Revisited maxillary sinus pneumatization narrative of observation in Al-Madinah Al-Munawwarah, Saudi Arabia: A retrospective cross-sectional study. *Saudi Dent J.* 2019;31(2):212-218. doi:10.1016/j.sdentj.2018.11.002
 8. Guo T, Gulati K, Shen Z, Han P, Fan Z. Therapeutic outcomes of non-grafted and platelet concentrations-grafted transcrestal maxillary sinus elevation (TSFE): a systematic review and meta-analysis. *Sci Rep.* 2020;10(1):1-12. doi:10.1038/s41598-020-62407-y
 9. Hazzaa HHA, El-Kilani NS, Elsayed SAE, Abd El Massieh PM. Evaluation of Immediate Implants Augmented with Autogenous Bone/Melatonin Composite Graft in the Esthetic Zone: A Randomized Controlled Trial. *J Prosthodont.* 2019;28(2):e637-e642. doi:10.1111/jopr.12631
 10. Heinemann F, Hasan I, Bourauel C MT. Bone stability around dental implants: Treatment related factors. *Ann Anato.* 2015;199:3-8.
 11. Helal R, Elsayed S, Mohamed F, Saleh H, Khalifa F. Evaluation of the Effect of Bovine Bone Graft on the Preservation of Buccal Plate of Extracted Socket. *Al-Azhar Dent J Girls.* 2016;3(1):17-22. doi:10.21608/adjg.2016.5065
 12. Jin H-Y, Teng M-H, Wang D, et al. Modified Disk-Up Sinus Reamer for Sinus Floor Elevation and Simultaneous Implant Placement: An Animal Study with Miniature Pigs. *J Investig Surg.* 2020;33(6):520-529. doi:10.1080/08941939.2018.1545881
 13. Maspero C, Farronato M, Bellincioni F, et al. Three-dimensional evaluation of maxillary sinus changes in growing subjects: a retrospective cross-sectional study. *Materials (Basel).* 2020;13(4). doi:10.3390/ma13041007
 14. Nahlieli O, Zagury A, Michaeli E, Bruck N, Nahlieli DD, Casap N. Four-years' experience with dynamic implants with internal port for minimally invasive sinus elevation. *Quintessence Int (Berl).* 2016;47(8):669-675.
 15. Nandal S, Ghalaut P, Nandal D. Inadequate vertical bone dimension managed by indirect sinus grafting technique and simultaneous implant placement. *Natl J Maxillofac Surg.* 2016;7(2):213. doi:10.4103/0975-5950.201355
 16. Peñarrocha-Diago M, Rambla-Ferrer J, Perez V, Pérez-Garrigues H. Benign paroxysmal vertigo secondary to placement of maxillary implants using the alveolar expansion technique with osteotomes: a study of 4 cases. *Int J Oral Maxillofac Implants.* 2008;23(1):129-132. <http://www.ncbi.nlm.nih.gov/pubmed/18416423>.
 17. Ritter A, Rozendorn N, Avishai G, Rosenfeld E, Koren I, Soudry E. Preoperative Maxillary Sinus Imaging and the Outcome of Sinus Floor Augmentation and Dental Implants in Asymptomatic Patients. *Ann Otol Rhinol Laryngol.* 2019;129(3):209-215. doi:10.1177/0003489419883292
 18. Saker M, Ogle O. Benign Paroxysmal Positional Vertigo Subsequent to Sinus Lift via Closed Technique. *J Oral Maxillofac Surg.* 2005;63:1385-1387.

- doi:10.1016/j.joms.2005.05.296
19. Song DS, Kim CH, Kim BJ, Kim JH. Tenting effect of dental implant on maxillary sinus lift without grafting. *J Dent Sci.* 2020;15(3):278-285. doi:10.1016/j.jds.2020.05.008
 20. Sonoda T, Yamamichi K, Harada T, Yamamichi N. Effect of staged crestal maxillary sinus augmentation: A case series. *J Periodontol.* 2020;91(2):194-201. doi:10.1002/JPER.18-0632
 21. Summers RB. A new concept in maxillary implant surgery: the osteotome technique. *Compendium.* 1994;15(2):152, 154-156, 158 passim; quiz 162. <http://europepmc.org/abstract/MED/8055503>.
 22. Suryasa, I. W., Rodríguez-Gámez, M., & Koldoris, T. (2021). Health and treatment of diabetes mellitus. *International Journal of Health Sciences*, 5(1), i-v. <https://doi.org/10.53730/ijhs.v5n1.2864>
 23. Tarun Kumar A, Anand U. Maxillary sinus augmentation. *J Int Clin Dent Res Organ.* 2015;7(3):81. doi:10.4103/2231-0754.172935
 24. Turkyilmaz I, McGlumphy EA. Influence of bone density on implant stability parameters and implant success: A retrospective clinical study. *BMC Oral Health.* 2008;8(1):1-8. doi:10.1186/1472-6831-8-32
 25. Yassin Alsabbagh A, Alsabbagh MM, Darjazini Nahas B, Rajih S. Comparison of three different methods of internal sinus lifting for elevation heights of 7 mm: an ex vivo study. *Int J Implant Dent.* 2017;3(1). doi:10.1186/s40729-017-0103-5

Figure legends

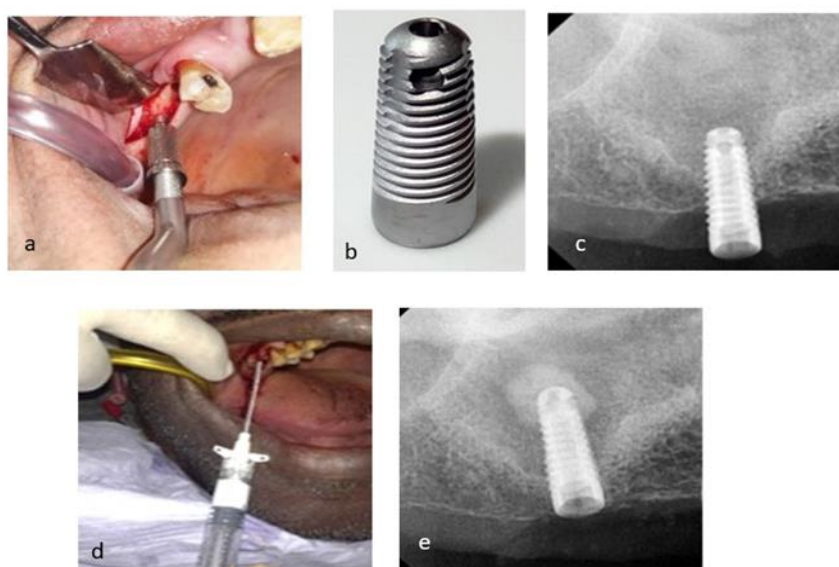


Figure 1: (a) Osteotome-induced fracture of the sinus floor (b) DIVA implant (c) A radiographic view of the DIVA implant being inserted. d) Bone graft injection by DIVA implant (e) A radiographic picture of the sinus floor with a bone graft at the apex of the DIVA implant.

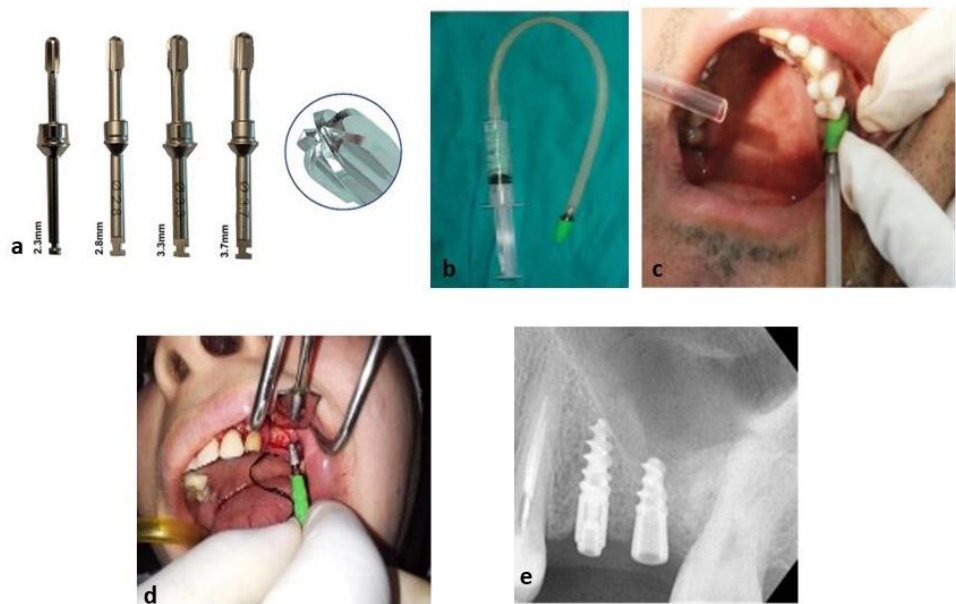

Figure 2: (a) CAS Kit osteotomy drills (b) CAS Kit hydraulic lifter (c) hydraulic lifter placed in osteotomy site (d) dental implant placement in prepared osteotomy location (e) A radiographic picture of the sinus floor with a bone graft at the apical region of the implant.

Table I: Illustrating mean \pm SD values of ISQ scores among studied groups at two evaluation periods, along with significance level using paired & unpaired t-test

	Group	Preoperative	3months	6months	9 months	3 months Vs Preoperative	3 months Vs 6 months	9 months Vs 6 months
ISQ scores		Mean \pm SD	Mean \pm SD	Mean \pm SD	Mean \pm SD	P-Value	P-Value	P-Value
	DIVA	39.00 \pm 2.16	69.07 \pm 1.69	70.43 \pm 2.37	71.71 \pm 1.60	0.00**	0.253	0.11
	CAS-Kit	40.00 \pm 2.12	54.57 \pm 4.12	68.71 \pm 2.69	70.43 \pm 1.27	0.00**	0.00**	0.11
	GII Vs GI	0.40	0.001**	0.231	0.121			

Table II: Illustrating mean \pm SD values of bone density measurements and alveolar ridge height among studied groups at two evaluation periods, along with significance level using paired & unpaired t-test

	Group	Preoperative	3months	6months	3 months Vs Preoperative	6 months Vs 3 months
alveolar ridge height		Mean \pm SD	Mean \pm SD	Mean \pm SD	P-Value	P- Value
	DIVA	5.8 \pm 0.67	13.28 \pm 0.50	12.8 \pm 0.53	0.00**	0.00**
	CAS- Kit	6.8 \pm 0.86	11.39 \pm 0.60	10.8 \pm 0.67	0.00**	0.00**
	GII Vs GI	0.03*	0.00**	0.00**		
Bone Density scores	DIVA	472.7 \pm 54.14	574.6 \pm 31.77	667.7 \pm 63.26	0.00**	0.00**
	CAS- Kit	466.1 \pm 42.64	578.0 \pm 23.55	654.0 \pm 57.54	0.001**	0.00**
	GII Vs GI	0.811	0.820	0.680		