

How to Cite:

Ibrahimi, Z. A. A. R. A., Alsalame, H. A. A.-A., & Jawad, Z. N. (2022). Estimation the protective role of *Andrographis paniculata* aqueous extracts on nephrotoxicity in male rabbits treated with butylated hydroxytoluene (BHT). *International Journal of Health Sciences*, 6(S8), 1775–1789. <https://doi.org/10.53730/ijhs.v6nS8.11638>

Estimation the protective role of *Andrographis paniculata* aqueous extracts on nephrotoxicity in male rabbits treated with butylated hydroxytoluene (BHT)

Zahraa Abed Alhussein Rahi Al Ibrahimi

Researcher in Department of Biology, College of Education for Pure Sciences, Kerbala University, Kerbala, Iraq

Corresponding author email: zahraa.abedalhussein@s.uokerbala.edu.iq

Heba A. Abd-alsalam Alsalame

Assistant prof. Department of Biology, College of Education for pure Sciences, Kerbala University, Kerbala, Iraq

Email: hiba.alwaan@uokerbala.edu.iq

Zainab Nizar Jawad

Assistant prof. Department of Biology, College of Education for pure Sciences, Kerbala University, Kerbala, Iraq

Email: zainab.n@uokerbala.edu.iq

Abstract--This study is aimed at knowing the protective role of aqueous extract of *Andrographis paniculata* on the toxic effects induced by butylated hydroxytoluene (BHT) in domestic male rabbits. The study was conducted in College of Education for Pure Sciences / Univ. of Karbala from November 2021 until February 2022. Forty adult male rabbits have been used, which were divided randomly into four equal groups (10 animals/group), the first group (G1) was administered with 1ml/kg of corn oil and considered to be the control group. The second group (G2) administrated 1mg/kg of the BHT, the third group (G3) had administrated 100mg/kg of *A. paniculata*, whereas animals of 4th group (G4) administrated 1mg/kg of the BHT and 100mg/kg of *A. paniculata* extract orally for a month daily. Fasting Blood samples were collected after the end of the experimentation for the purpose of studying the concentration of the following parameters: Albumin, Urea, Uric acid, superoxide dismutase (SOD), Reduced Glutathione (GSH) and Malondialdehyde (MDA). The results showed that oral administration of BHT caused a significant increase ($P < 0.01$) in concentrations of Urea, Uric acid, and MDA, while there was a significant reduction ($P < 0.01$) in concentration of Albumin

and GSH in comparison with the control group .The group that was treated with *A. paniculata* extract had shown a significant increase ($P<0.01$) in concentration of Albumin and GSH, while there has been a significant decrease ($P<0.01$) in concentration of MDA and Urea. With no significant difference ($P<0.01$) in concentrations of Uric acid and SOD. The experiment also showed that oral administration of BHT with *A. paniculata* aqueous extract caused no significant differences ($P<0.01$) in the GSH, MDA, SOD, Albumin, Urea concentration, and Uric acid .Histological examination had shown that oral administration of BHT for 30 days caused clear degenerative changes in kidney tissue with congestion and atrophy of the urinary glomerulus, in addition, to an increase in Bowman's capsule space and destruction of the urinary tubules with the shedding of the inner lining of the urinary tubules. It is concluded from this study that BHT causes clear pathological effects on the kidneys and confirms that treatment with 100mg/kg of *A. paniculata* aqueous extract has protective role against damage caused by BHT in male rabbits.

Keywords---aqueous extract, BHT, male rabbits.

Introduction

Butylated hydroxytoluene (BHT) is a white crystalline substance (EFSA, 2012) with the chemical formula $C_{15}H_{24}O$, molecular weight 220.36g/mol, the melting point of 70 degrees Celsius, trade symbol E 321. It is a lipophilic compound (Husøy *et al.*, 2019), BHT is one of the most common antioxidants used in many applications to this day (Higgins *et al.*, 2019), small amounts of preservatives are added for the purpose of improving quality of taste and prolong the shelf life of food during its production and to protect food from spoilage or rancidity (Pandey & Kumar, 2021; Zamzam *et al.*, 2019). Butylhydroxytoluene (BHT) is an important compound and one of the food additives that is widely used in the food industry. It is a phenolic derivative with antioxidant properties that prevent the self-oxidation of non-organic compounds. (Sharma & Singh, 2019), oxidation is a big and dangerous problem facing the food manufacturing process because it has a clear impact on food quality and negatively affects the flavor, color, taste and smell of food as well as reduces the nutritional value In manufactured foods (Alebic & Richter, 2021), BHT is one of the most common food additive types that are used in order to improve the taste of food, and it is a substance that was approved by the US Food and Drug Administration (FDA) and has been recognized as being classified by the European Union as safe when utilized in small amounts, and based on the recommendations of The Food and Agriculture Organization of US and the World Health Organization (WHO), daily BHT intake in foods must limit to 0-0.125mg/kg, while acceptable range for BHT by the European Economic Community has been specified as 0-0.05mg/kg (Ghosh *et al.*, 2020), the incorrect and excessive use of synthetic phenolic antioxidants is one of the causes of cytotoxicity, carcinogenicity, endocrine disrupting effects and oxidative stress induction (Xu *et al.*, 2021).humans are exposed to these chemicals in food, and with the increase in their use for longer periods, many health problems that threaten the life of the individual appear (Pandey & Kumar,

2021), as it has been confirmed that BHT accumulates in fatty tissues and causes a disturbance in metabolism. Diet (Mean *et al.*, 2018) has also been found it causing many pulmonary disorders and acute poisoning (Liu *et al.*, 2016). Some doses of BHT can also cause adenomas. In addition to increasing the weight of glands such as the thyroid gland, BHT can also interfere with the activity of vitamin K-dependent blood clotting factors in mice (Derks *et al.*, 2021). also affects the rate of hormonal regulation (Pop *etal.*,2018)

Andrographis paniculata can be defined as an annual herbaceous plant that grows in India and Sri Lanka that is commonly cultivated in regions of Asia and utilized as a traditional herbal remedy in Hong Kong, Malaysia, Indonesia and Philippines (Firdous *et al.*, 2020). It was also used in ancient traditional medicine around the world (Sharma & Sharma, 2018), *Andrographis* contains a high percentage of saponins, alkaloids, terpenoids, phenols, flavonoids, and tannins (Nagajothi *et al.*, 2018). About 135 compounds have been isolated from this plant, including 40 flavonoids, 82 terpenes, and three steroids, in addition to 10 other compounds in the plant (Aminah *et al.*, 2021). *Andrographolide* contains many phytochemicals, including *andrographolide*. It is a dicyclic diterpene lactone and is considered the biologically active substance in the plant (Ketterman *et al.*, 2020). The activity of this main compound is because it contains aliphatic hydrogen groups on C11 carbon atoms that could act as hydrogen donor and thus displace free radicals (ANDRIANI *et al.*, 2018), and contains several other major active compounds in the leaves such as *neoandrographolide* and *14-deoxy-12-hydroxyandrographolide* as well as *14-deoxyandrographolide* (Lim *et al.*, 2021). The plant also contains the compounds *Andrographosterin* and *stigmasterol* (Rasool *et al.*, 2018), *Andrographidine*, *apigenin*, and *luteolin* (Rafi *et al.*, 2020). Which is why, in the present work, the mai focus is investigating effects of BHT on kidney tissue and function and effects of *A. paniculata* against kidney failure induced by BHT.

Materials and Methods

Experience design

Forty local male rabbits have been used, divided to 4 groups (10 animals/group): the 1st group has been orally dosed with 1 ml of corn oil and, a control group was made, the 2nd group has been orally dosed with a dose of 1mg/kg of the BHT, the 3rd group has been orally dosed with 100mg/ kg of *A. paniculata* aqueous extract, group IV dosed orally with 1mg/kg of BHT + 100mg/kg of *A. paniculata* aqueous extract. Blood samples were drawn after 30 days, the blood was placed in special tubes, and the serum has been separated by a centrifuge at 3000rpm for 15 minutes to measure the following parameters: Albumin, Urea, Uric acid, SOD, MDA and Reduced GSH. The Bromocresol Green BCG method was used to determine the level of albumin using spectrophotometry (Hallbach *et al.*, 1991; Tiez, 2006), and the level of urea and uric acid in serum have been measured by the use of colorimetric enzymatic method by (Patton & Crouh, 1977). The Plasma concentration of GSH and SOD were measured by ELISA utilizing commercially available kits, MDA concentration has been measured based on the thiobarbituric acid (TBA) reaction by Muslih *etal.* (2001).

Preparation of the aqueous extract

Twenty grams of dry powder has been mixed with 400ml of the distilled water, and an electric grinder was used and left at room temperature for 24 hours. Several layers of medical gauze were used to filter the mixture, after that, centrifuged at 3000rpm. For 10min., the extract has been filtered with filter paper to obtain a clear solution. An electric oven was used to dry the extract at a temperature of 40 °C and kept in refrigerator until use (Hernandez *et al.*, 1994). The above method was adopted for the preparation of *A. paniculata* extract, with some modifications, as follows: The dry leaves were crushed well using an electric grinder and soaked in distilled water for 24 hours with constant stirring and filtered using layers of medical gauze and pieces of soft and clean cloth. Then poured into Clean and sterilized glassware for drying it on fan air only, then keeping the extract in the refrigerator until it is used.

Results and Discussion

Effect of BHT on Urea, Uric acid, and albumin

The results showed that oral administration of BHT led to considerable ($P<0.01$) increase in urea and uric acid concentrations and a significant ($P<0.01$) reduction in albumin concentration, This is in agreement with (Ben Amara *et al.*, 2020; Farag *et al.*, 2006).

Table (1) Effects of butyl hydroxytoluene and aqueous extract of *A. paniculata* on the urea, uric acid, and albumin in male rabbits

	Urea (mo/l)	Uric acid (mg/dl)	Albumin (g/d)
G1 Control	0.14 ±5.62 A	1.16±42.25 A	5.36± 0.26 A
G2 1 mg/kg BHT	8.98±0.25 B	79.72±2.47 B	2.91± 0.16 B
G3 100 mg/kg Andrographis	5.06± 0.14 C	40.88±1.36 A	6.98±0.11 C
G4 1 mg/kg BHT+10 mg/kg Andrographis	5.64±0.14 A	38.05±1.73 A	4.17±0.15 A
LSD	0.5144	5.0377	1.5255

mean ± standard error, n = 10/ group. The different letters are an indication of the presence of significant differences vertically under the probability level $P<0.01$

Urea is the final product of the metabolism of proteins, as this substance is absorbed into the renal tubules, and the kidneys secrete it and reduce its concentration in the blood. Increased urea levels in blood reflect the kidney's functional damage. Oxidative stress plays a crucial and important role in kidney disease; it enhances renal injury by damaging the molecular components of the

kidney through the activities of intracellular and extracellular reactive oxygen radicals (Zeghib & Boutlelis, 2021). Uric acid is another important indicator of renal injury and may participate in inflammatory pathways that promote injury, as it participates in being a catalyst for oxidative, as it is a catalyst for inflammation and an activator of immune responses, and thus it has been linked to kidney diseases and injuries, the increase in uric acid to can cause inflammation of the cells of the urinary tubules, and its interaction with oxidants is also considered one of the reasons for the generation of many free radicals with significant destructive effects on the cells and renal tubules (Hahn *et al.*, 2017). It was also found that the levels of urea and uric acid are an indicator of the occurrence of necrosis of the renal tubes and kidney failure (Laaroussi *et al.*, 2021). In the current study, BHT caused an increase in urea and uric acid levels and this is because of the oxidative stress that occurred, as the excessive production of radicals affects Free radicals after exposure to BHT lead to oxidative stress in the kidneys, and this became evident through the high percentage of MDA, which is an indicator of the formation of free radicals and the increase in the lipid peroxidation that changes the integrity of cell membranes. These free radicals could be directly derived from the BHT or be a product of the metabolism of this compound in the cytochrome P450 system, and this is accompanied by the depletion of natural antioxidants in the kidneys, and consequently, renal failure occurs, and the proportion of urea and uric acid in blood rises. In the blood (Ben Amara *et al.*, 2020). Albumin is an important protein in the body's defense mechanisms. It works to reduce inflammation, protects against oxidative stress, and carries numerous hormones, drugs, biologically active elements, iron, fatty acids, and bilirubin. Its levels could decrease in the blood as a result of the acceleration in the metabolism, malnutrition, or decreased synthesis in the liver. It was found that a low concentration of albumin predicts a kidney injury (Özgür *et al.*, 2021). When harmful substances enter the kidneys, they are filtered in glomerulus, then reabsorbed later in nearby tubules, and after that, remain in the tubular cells and thus may result in renal toxicity, The deficiency in albumin may indicate the loss of this component in the urine and an increase in its excretion from the kidney, as a result of injury to the glomeruli and tubes and the weakness of the kidney's work (Poosa & Vanapatla, 2020).

Effect of *A. paniculata* extract on Urea, Uric acid, and albumin

The results showed that oral administration of *Andrographis* extract led to no significant differences ($P < 0.01$) in concentration of the urea and uric acid, With no significant difference ($P < 0.01$) in the rate of albumin concentration, This agreement with (Singh *et al.*, 2009; Sharma *et al.*, 2022; Bardi *et al.*, 2014). *A. paniculata*, with its antioxidant properties, works to get rid of free radicals and oxidative stress and repair kidney damage and the resulting injury caused by BHT. The polyphenols and flavonoids in *A. paniculata* have been shown to reduce uric acid levels by acting as antioxidants and reducing free radicals. *A. paniculata* and its active components, including flavonoids, inhibit many oxidation enzymes, including xanthine oxidase, cyclooxygenase, and other enzymes, thus regulating the level of uric acid in the blood (Cicero *et al.*, 2021; Mehmood *et al.*, 2019; Irawan *et al.*, 2022). The absence of a significant difference in concentration of albumin in the blood after using *A. paniculata* extract indicates the role of the plant as a protective and antioxidant substance. Rich phytochemicals, especially active

antioxidant compounds, work to regulate kidney functions and what is related to them. However, albumin is produced in the liver. However, when kidney damage occurs, a defect may occur in the reabsorption of this protein, which allows the excretion of albumin in the urine, and here the plant extracts, in turn, act as a protective device for the kidneys, repairing the damage caused and regulating kidney functions and excretion processes (Rajasekaran, 2019).

Effect of BHT on GSH, MDA, SOD

Results in the table (2) indicate that oral administration with 1 mg/kg BHT (G2) led to a significant increase ($P < 0.01$) in concentration of MDA and significant decrease ($P < 0.01$) in concentration of reduced glutathione GSH and SOD compared with control group (G1). The existence of the antioxidant enzymes in the organism's body effectively prevents oxidative processes and reduces the production of free radicals, thus reducing lipid peroxidation. They have an important impact on the maintenance of balance between oxidation process and the antioxidant defense systems. Any imbalance in this process leads to excessive accumulations of the ROS and lipid peroxidation in cells and oxidation of membranous phospholipids (Hao & Liu, 2019). ROS attack fatty acids in membranes and contribute to various cellular damages. Reactive aldehydes such as Malondialdehyde (MDA) are produced (Venmathi Maran et al., 2022), which is the end product of lipid peroxidation, so it may be said that the increased generation of free radicals caused Oxidative damage. Once animals experience certain problems, elevated levels of free radicals begin to form, especially ROS, and when ROS production bypasses body's natural anti-oxidant defense mechanisms, it leads to damaging cell wall, DNA, mitochondria, and functional proteins. One of the body's antioxidant systems is glutathione (GSH) and superoxide dismutase (SOD) (Min et al., 2018). glutathione (GSH) contains the SH thiol group, the presence of this group is very important in protecting oxidative processes, as it works to interact with hydroxyl radicals, peroxy nitrite, and single oxygen. It acts as an electron donor to associate with the radicals and turn them into water, as the SH group is oxidized. Glutathione disulfide, which is the oxidized form of glutathione, which is two molecules of GSH linked together by the enzyme GPx glutathione peroxidase, then re-converted (oxidized GSSG) to the reduced form of GSH again by the enzyme Glutathione reductase (GSH-RD) and cofactor Nicotinamide adenine dinucleotide phosphate (NADPH) (Vairetti et al., 2021). Whereas the superoxide dismutase (SOD) converts superoxide radicals into oxygen, thus reducing its harmful effect on tissues and oxidative stress. It is an important indicator of hepatocyte damage (Sannasimuthu *et al.*, 2018). Antioxidant enzymes such as SOD participate in the removal of dangerous free radicals. They play an important role in helping the body to get rid of toxins as a result of exposure to BHT, which has a toxic effect as a result of the generation of the dangerous free radicals capable of interacting with large biomolecules and its role in necrosis and damage of body tissues like the liver and others tissues (Kagan *et al.*, 1990). The changes occurring in antioxidant enzymes in this study may be due to the exposure of animals to BHT through the high percentage of MDA, which reflects the failure of the antioxidant defense to counter the damage caused by ROS, meaning that ROS produced exceeded the scavenging ability of antioxidants and the occurrence of oxidative stress, which caused significant

damage to cellular components, which in turn led to the depletion of GSH and SOD enzymes (Hegab *et al.*, 2021).

Table (2) Effects of butyl hydroxytoluene and *A. paniculata* aqueous extract on concentration of GSH, MDA and SOD in domestic male rabbits

	GSH	MDA	SOD
G1 Control	17.16±0.23 A	0.36±0.01 A	72.10±1.57 A
G2 1 mg/kg BHT	10.62±0.76 B	0.80±0.04 B	36.50±2.52 B
G3 100 mg/kg Andrographis	21.68±0.64 C	0.30±0.01 C	70.50±1.04 A
G4 1 mg/kg BHT+10 mg/kg Andrographis	19.20±0.49 D	0.37±0.01 A	73.40±1.49 A
LSD	1.6488	0.0776	5.0097

mean ± standard error, n = 10/ group. The different letters are an indication of the presence of significant differences vertically under the probability level P<0.01

Effects of *A. paniculata* on concentration of GSH, MDA, and SOD

The results showed that oral administration with a dose of 100mg/kg of *A. paniculata* extract led to a considerable (P<0.01) increase of the concentration of the GSH and a significant (P<0.01) decrease in the concentration of the MDA, with no significant difference (P<0.010) in the GSH concentration. This agrees with (Subramaniam *et al.*, 2015; Rajendrakumar *et al.*, 2020; Owoade *et al.*, 2022; Nasir *et al.*, 2013).

The decrease in MDA levels after treatment with aqueous extract of *A. paniculata* is due to its role in reducing lipid peroxidation caused by free radicals, which causes depletion of antioxidants and makes organs susceptible to oxidative damage. MDA formation is a late stage of fat oxidation and a clear toxic indicator (Hidayat & Wulandari, 2021). The increase of concentration of antioxidants following the treatment with the aqueous extract may be due to its role in renewing the synthesis of these antioxidants or due to the metabolic reduction of the toxic substance and thus reduce the increased generation of free radicals, which may reduce liver injuries due to its content of important compounds such as flavonoids and alkaloids (Nasir *et al.*, 2013). *A. paniculata* is highly effective in activating the antioxidant defense by reducing free radicals, and it is also involved in protecting mitochondria, inhibiting oxidative enzymes, and activating antioxidant enzymes. It has been observed that nuclear factor-erythroid-2 related factor 2 (Nrf-2) is involved in regulating anti-oxidant defense system in cells and regulating this factor by andrographioid extract and its active compound. Andrographioid is important in the regulation of The redox system by acting to activate a variety of genes involved in defense of antioxidants (Mussard *et al.*,

2019) Nrf2 regulates genes coding for antioxidants and detoxification enzymes. Under alkaloid conditions, Nrf2 is inactive in the cytoplasm and binds to the Kelchlike ECH association protein 1 (Keap1) activator molecule to form the Nrf2-Keap1 complex. Then, Nrf2 is degraded rapidly by ubiquitin-proteasome pathway. Signals from the ROS and electrophilic elements cause Nrf2 to dissociate from Keap1, then move to the nucleus and bind to antioxidant response element (ARE) or electrical response elements. The electrophile response element (EpRE) is located in promoter region of genes encoding antioxidants and detoxification enzymes (Nuriansyah *et al.*, 2019). The plant extract may also have a role in stimulating the increase in the transcription of various antioxidants, detoxification enzymes, and various proteins, as it stimulates the activity of GSH, SOD, and Nicotinamide adenine dinucleotide phosphate (NADPH) and other important antioxidants (Choi *et al.*, 2014). Thus, it can be said that the active compounds in *Andrographis* extract work to increase the number of nuclear Nrf2 and link it to other elements, which increases the work of genes that play a significant role in the synthesis of antioxidants and increase their activity (Chen *et al.*, 2014).

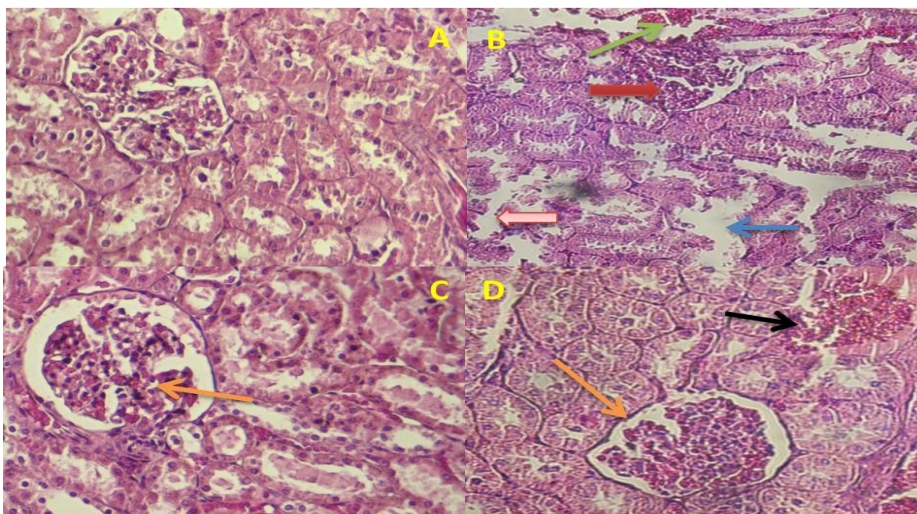
Effect of BHT on kidney tissue

The results of the histological examination showed that oral administration of BHT led to congestion and atrophy of the urinary glomerulus, in addition to the destruction of the urinary tubules and degenerative changes in the renal tissue, this agreement with (Ben Amara *et al.*, 2020). The most significant destructive renal effects result from exposure to foreign substances or drugs, toxins, and induction of the oxidative stress. This may be followed by activation of different factors and pathways influencing and involved in kidney tissue damage, for example, nuclear factor kappa B (NF-kB) or increased production of the inflammatory cytokines like the Tumor necrosis factor and IL-6. Those changes could result in an imbalance between those inflammatory factors and cell's antioxidant defense, eventually leading to serious disorders and disease (Molaei *et al.*, 2021). The body's exposure to the BHT has led to kidneys being greatly affected due to the toxicity. This kidney injury is linked to the liver as well because the kidneys also participate in the metabolism of BHT in the body, where the metabolism of BHT occurs in the liver through The cytochrome P450 system in which BHT metabolizes different types of sulfate and conjugated glucuronic acid, forming metabolites including BHT-quinone methide, which can covalently bind with cell components and produce various effects. The results of the various metabolites are subsequently excreted in urine and feces and through the bile, where these hepatic metabolites can bind to the kidney microsomes and thus have a toxic effect on kidneys (Nakagawa & Tayama, 1988; Meyer *et al.*, 1989). Through the secretion of these phenolic derivatives and metabolites into the convoluted tubules of nephron via anion transport. By the same mechanism used in xenobiotic metabolites, this can lead to active accumulation through the blood to the renal tubules, as well as reabsorption of water along the nephron, to increase the concentrations of BHT derivatives in the functional units of the kidney, where BHT causes obvious nephrotoxicity (Aprilia *et al.*, 2018). It has become clear that the excessive generation of ROS causes damage to kidney tissues by promoting lipid peroxidation, membrane damage, DNA and protein modification, and ROS causes depletion of the antioxidant system in kidney

tissues. The kidney is an organ that is highly susceptible to damages that are caused by ROS may be because of the availability of long-chain poly-unsaturated fatty acids in formation of renal lipids (Ozbek, 2012), and tissue damage in the kidney may be due to the activity of pro-inflammatory cytokines like the TNF- α . Inflammation-stimulating cytokines may cause nephropathy through secretion from renal glomerular membrane (Alayunt et al., 2019).

Effects of the *A. paniculata* extract on kidney tissue

The results of tissue examination showed that oral administration of *Andrographis* extract caused the normal structure of the glomerulus and urinary tubules with the appearance of congestion in some parts of the urinary tubules, which is in agreement with (Padmalochana & Dhanarajan, 2017). It has been proven that *A. paniculata* and its active compounds improve renal cell injury and the rate of renal filtration, as well as improve the functions and structure of the glomeruli and renal tubules significantly. The increase in inflammatory and oxidative reactions within the kidneys stimulated toxicity, in an attempt to control free radicals and oxidative stress, this leads to the depletion of renal antioxidants. *A. paniculata* extract reduces oxidative damage and protects the kidneys by raising the antioxidant system and activating the transcription factor that transcribes antioxidant genes (Nrf2). After it is activated, it moves to nucleus, binds to responsive element of antioxidants and stimulates transcription and gene expression of antioxidants, thus reducing nephrotoxicity (Adeoye *et al.*, 2019). As mentioned, inflammation could have an important impact on the pathogenesis of kidney injury through a series of processes such as increased stimulation of the NF- κ B pathway. The plant extract works here to control the nuclear factor pathway that mediates renal injury and regulate other pathways that cause cellular injury, as well as reduced renal expression of pro-inflammatory cytokines like TNF- α and its receptors, TNF may produce reactive oxygen species. It coordinates the activation of many chemicals and cytokines in the kidneys that work and attract inflammatory cells. The extract also reduces the infiltration of macrophages and lymphocytes in the kidneys, which shows the role of *A. paniculata* extract in restoring the structure of the kidney and repairing tissue damage (Ragendrakumar *et al.*, 2020).



Figure(1) shows a histological section of the kidney in male rabbits with hematoxylin and eosin stain (H&E 200X) (A). Histological section of kidney tissue in the control group, the normal structure of glomerulus and urinary tubules is observed. (B) effect of oral administration with 1 mg/kg of BHT for 30. It was noted blood congestion (green arrow) and glomerulosclerosis (red arrow), in addition to an increase in Bowman's space and destruction of urinary tubules (blue arrow) with Disruption of the inner lining of the urinary tubules (pink arrow) (C) effect of oral administration 100 mg/kg *A. paniculata* aqueous extract, the normal structure of the glomerulus was noted (orange arrow) (D) effect of oral administration of 1mg/kg of BHT with 100mg/kg of *A. paniculata* aqueous extract, it is noted that the normal structure of the glomerulus (orange arrow) with a little blood congestion (black arrow)

References

- Adeoye, B. O., Oyagbemi, A. A., Asenuga, E. R., Omobowale, T. O., & Adedapo, A. A. (2019). The ethanol leaf extract of *Andrographis paniculata* blunts acute renal failure in cisplatin-induced injury in rats through inhibition of Kim-1 and upregulation of Nrf2 pathway. *Journal of basic and clinical physiology and pharmacology*, 30(2), 205-217.
- Alayunt, Ö. N., Aksoy, L., Karafakioğlu, Y. S., & Sevimli, S. (2019). Assessment of anti-inflammatory and antioxidant properties of safranal on CCI 4-induced oxidative stress and inflammation in rats. *Anais da Academia Brasileira de Ciências*, 91.
- Alebic, I., & Richter, R. C. (2021). Evaluation of chewing gum and cereal products as a potential source of butylated hydroxytoluene (BHT) toxicity in Children. *J Undergrad Chem Res*, 20, 27-29.
- Aminah, N. S., Tun, K. N. W., Kristanti, A. N., Aung, H. T., Takaya, Y., & Choudhary, M. I. (2021). Chemical constituents and their biological activities from Taunggyi (Shan state) medicinal plants. *Heliyon*, 7(2), e06173.
- ANDRIANI, A., NOVRIANY, V., SUSENO, G., EFFIANA, E., & Fitrianingrum, I. (2018). Hepatoprotective effect of methanol extract of sambiloto leaves

- (*Andrographis paniculata*) against malondialdehyde levels in liver tissues of paracetamol-induced Wistar rat. *Nusantara Bioscience*, 10(2), 87-90.
- Aprilia, V., Bhima, S. K. L., & Ismail, A. (2018). Pengaruh Pemberian Butylated Hydroxytoluene (2, 6-Di-Tert-Butyl-4-Methylphenol) Per Oral Dosis Bertingkat Terhadap Gambaran Histopatologis Ginjal. *DIPONEGORO MEDICAL JOURNAL (JURNAL KEDOKTERAN DIPONEGORO)*, 7(2), 1154-1165.
- Bardi, D. A., Halabi, M. F., Hassandarvish, P., Rouhollahi, E., Paydar, M., Moghadamtousi, S. Z.,... & Abdulla, M. A. (2014). *Andrographis paniculata* leaf extract prevents thioacetamide-induced liver cirrhosis in rats. *PloS one*, 9(10), e109424.
- Ben Amara I, Ben Saad H, Cherif B, et al.(2020). Evaluation of Biological Properties, Health Benefits and Protective Effects of Kefir against Cytotoxicity and Genotoxicity Induced by Butylated Hydroxytoluene (BHT) In Vivo. *Res Rev Biosci*,15(1):149.
- Chen, H. W., Huang, C. S., Li, C. C., Lin, A. H., Huang, Y. J., Wang, T. S.,... & Lii, C. K. (2014). Bioavailability of andrographolide and protection against carbon tetrachloride-induced oxidative damage in rats. *Toxicology and applied pharmacology*, 280(1), 1-9.
- Choi B, Kang KS, Kwak MK. (2014).Effect of redox modulating Nrf2 activators on chronic kidney disease. *Molecules*, 19: 12727-59.
- Cicero, A. F., Fogacci, F., Cincione, R. I., Tocci, G., & Borghi, C. (2021). Clinical effects of xanthine oxidase inhibitors in hyperuricemic patients. *Medical Principles and Practice*, 30(2), 122-130.
- Derks, H. J. G. M., Groen, C., Olling, M., & Zeilmaker, M. J. (2021). Extrapolation of toxicity data in risk assessment. In *Food Safety and Toxicity* (pp. 241-254). CRC Press.
- EFSA Panel on Food Additives and Nutrient Sources added to Food (ANS). (2012). Scientific Opinion on the re-evaluation of butylated hydroxytoluene BHT (E 321) as a food additive. *EFSA Journal*, 10(3), 2588.
- Farag, R. S., Mahmoud, E. A., Basuny, A. M., & Ali, R. F. (2006). Influence of crude olive leaf juice on rat liver and kidney functions. *International journal of food science & technology*, 41(7), 790-798.
- Firdous, J., Latif, N. A., Mona, R., Mansor, R., & Muhamad, N. (2020). *Andrographis paniculata* and its endophytes: a review on their pharmacological activities. *Res J Pharm Technol*, 13(4), 2029-2032.
- Ghosh, C., Singh, V., Grandy, J., & Pawliszyn, J. (2020). Development and validation of a headspace needle-trap method for rapid quantitative estimation of butylated hydroxytoluene from cosmetics by hand-portable GC-MS. *RSC Advances*, 10(11), 6671-6677.
- Hahn, K., Kanbay, M., Lanaspá, M. A., Johnson, R. J., & Ejaz, A. A. (2017). Serum uric acid and acute kidney injury: a mini review. *Journal of advanced research*, 8(5), 529-536.
- Hallbach, J.; Hoffman, G. E., and Guder, W. G. (1991). Over estimation of albumin heparinized plasma. *Clin. Chem.* 22(5):616-622.
- Hao, M., & Liu, R. (2019). Molecular mechanism of CAT and SOD activity change under MPA-CdTe quantum dots induced oxidative stress in the mouse primary hepatocytes. *Spectrochimica Acta Part A: Molecular and Biomolecular Spectroscopy*, 220, 117104.
- Hegab, D., Mohammed, A., Metwally, M., Ghoneim, M., & Abou-Hadeed, A. (2021). Ethoxyquin and Butylated Hydroxyl Toluene Induced Hepatotoxic

- Effect Via Apoptosis, Oxidative Stress in Rats: Tissue Injury-Related CYP1A1 Gene Expression. *Zagazig Veterinary Journal*, 49(4), 456-470.
- Hernandez, M.; Lopez, R.; Abanas, R.M.;V and Arias, A.(1994) .Antimicrobial activity of visnea mocanera leaf extracts .j. *Ethno pharma cology* ,41 ;115-119.
- Hidayat, R., & Wulandari, P. (2021). Effects of *Andrographis paniculata* (Burm. F.) Extract on Diabetic Nephropathy in Rats. *Reports of Biochemistry & Molecular Biology*, 10(3), 445.
- Higgins, C. L., Filip, S. V., Afsar, A., & Hayes, W. (2019). Evaluation of thermal and oxidative stability of three generations of phenolic based novel dendritic fuel and lubricant additives. *Reactive and Functional Polymers*, 142, 119-127.
- Husøy, T., Andreassen, M., Lillegaard, I. T. L., Mathisen, G. H., Rohloff, J., Starrfelt, J.,... & Bruzell, E. M. (2019). Risk assessment of butylated hydroxytoluene (BHT). Opinion of the Panel on Food Additives, Flavourings, Processing Aids, Materials in Contact with Food, and Cosmetics of the Norwegian Scientific Committee for Food and Environment. VKM Report.
- Irawan, C., Sukiman, M., Putri, I. D., Utami, A., Zalni, M. I. K., & Putri, R. K. (2022). Optimization of Ultrasound-Assisted Extraction of *Andrographis paniculata* Nees Leaves, Phytochemical Screening, Total Phenolic Content and Anti-Gout Potential Activity. *Pharmacognosy Journal*, 14(2).
- Kagan, V. E., Serbinova, E. A., & Packer, L. (1990). Generation and recycling of radicals from phenolic antioxidants. *Archives of biochemistry and biophysics*, 280(1), 33-39.
- Ketterman, A. J., Wongtrakul, J., & Saisawang, C. (2020). Phytochemical andrographolide modulates NF- κ B and JNK in human neuroblastoma SH-SY5Y cells, a cell model for Parkinson's disease. *Heliyon*, 6(6), e04121.
- Laaroussi, H., Bakour, M., Ousaaïd, D., Ferreira-Santos, P., Genisheva, Z., El Ghouizi, A.,... & Lyoussi, B. (2021). Protective effect of honey and propolis against gentamicin-induced oxidative stress and hepatorenal damages. *Oxidative Medicine and Cellular Longevity*, 2021.
- Lim, A. M. T., Oyong, G. G., Tan, M. C. S., Shen, C. C., Ragasa, C. Y., & Cabrera, E. C. (2021). Quorum quenching activity of *Andrographis paniculata* (Burm. f.) Nees andrographolide compounds on metallo- β -lactamase-producing clinical isolates of *Pseudomonas aeruginosa* PA22 and PA247 and their effect on lasR gene expression. *Heliyon*, 7(5), e07002.
- Liu, Y., Wang, Q., Ma, X., Chen, Y., Sun, L., Duan, Y., & Han, J. (2016). Activation of LXR inhibits the Development of Pulmonary Carcinomas Induced by 3-Methylcholanthrene and Butylated Hydroxytoluene. *The FASEB Journal*, 30, 1099-2.
- Mean, S., Değer, Y., & Yildirim, S. (2018). Effects of butylated hydroxytoluene on blood liver enzymes and liver glutathione and glutathione-dependent enzymes in rats. *Bulgarian Journal of Veterinary Medicine*, 21(4).
- Mehmood, A., Ishaq, M., Zhao, L., Safdar, B., Rehman, A. U., Munir, M.,... & Wang, C. (2019). Natural compounds with xanthine oxidase inhibitory activity: A review. *Chemical biology & drug design*, 93(4), 387-418.
- Min, Y. N., Z. Y. Niu, T. T. Sun, Z. P. Wang, P. X. Jiao, B. B. Zi, P. P. Chen, D. L. Tian, and F. Z. Liu. (2018). Vitamin E and vita- min C supplementation improves antioxidant status and immune function in oxidative-stressed breeder roosters by up-regulating expression of GSH-Px gene. *Poult. Sci.* 97:1238-1244.

- Molaei, E., Molaei, A., Abedi, F., Hayes, A. W., & Karimi, G. (2021). Nephroprotective activity of natural products against chemical toxicants: The role of Nrf2/ARE signaling pathway. *Food Science & Nutrition*, 9(6), 3362-3384.
- Muslih, B.; Mizil, Y. O. & Al-Nimer, M. S. (2001). Detection The level of peroxynitrite, and related with antioxidant status in the serum of patients with acute myocardial infraction. *Nat. J. Chem.*, (4):625-637.
- Mussard, E., Cesaro, A., Lespessailles, E., Legrain, B., Berteina-Raboin, S., & Toumi, H. (2019). Andrographolide, a natural antioxidant: an update. *Antioxidants*, 8(12), 571.
- Nagajothi, S., Mekala, P., Raja, A., & Senthilkumar, A. (2018). *Andrographis paniculata*: qualitative and quantitative phytochemical analysis. *Journal of Pharmacognosy and Phytochemistry*, 7(4), 1251-1253.
- Nakagawa, Y., & Tayama, K. (1988). Nephrotoxicity of butylated hydroxytoluene in phenobarbital-pretreated male rats. *Archives of toxicology*, 61(5), 359-365.
- Nasir, A., Abubakar, M. G., Shehu, R. A., Aliyu, U., & Toge, B. K. (2013). Hepatoprotective effect of the aqueous leaf extract of *Andrographis paniculata* Nees against carbon tetrachloride-induced hepatotoxicity in rats. *Nigerian Journal of Basic and applied sciences*, 21(1), 45-54.
- Nuriansyah, M.; Mahyarudin and Andriani. (2019) Uji Efek Hepatoprotektor Andrographolide terhadap Kadar Glutasion Jaringan Hepar Tikus *Rattus Norvegicus* Galur Wistar yang Diinduksi Karbon Tetraklorida (CCl₄). *Jurnal Mahasiswa PSPD FK Universitas Tanjungpura*, 5(2).
- Owoade, A. O., Alausa, A. O., Adetutu, A., & Owoade, A. W. (2022). Protective effects of methanolic extract of *Andrographis paniculata* (Burm. f.) Nees leaves against arsenic-induced damage in rats. *Bulletin of the National Research Centre*, 46(1), 1-11.
- Ozbek, E. (2012). Induction of oxidative stress in kidney. *International journal of nephrology*, 2012.
- Özgür, Y., Akin, S., Yilmaz, N. G., Gücün, M., & Keskin, Ö. (2021). Uric acid albumin ratio as a predictive marker of short-term mortality in patients with acute kidney injury. *Clinical and Experimental Emergency Medicine*, 8(2), 82.
- Padmalochana, K., & Dhanarajan, M. S.(2017). Nephroprotective Potential Compounds from Leaves Extracts of *Andrographis Paniculata*. *Texila International Journal of Basic Medical Science*, Volume 2, Issue 2
- Patton, C. J., & Crouh, S. R. (1977). Urea colorimetric endpoint determination urease-Berthelot reaction. *Annal. Chem*, 49, 464-469.
- Poosa, M., & Vanapatla, S. R. (2020). Protective effect of *Antigonon leptopus* (Hook et. Arn) in cadmium induced hepatotoxicity and nephrotoxicity in rats. *Clinical Phytoscience*, 6(1), 1-8.
- Pop, A., Drugan, T., Gutleb, A. C., Lupu, D., Cherfan, J., Loghin, F., & Kiss, B. (2018). Estrogenic and anti-estrogenic activity of butylparaben, butylated hydroxyanisole, butylated hydroxytoluene and propyl gallate and their binary mixtures on two estrogen responsive cell lines (T47D-Kbluc, MCF-7). *Journal of Applied Toxicology*, 38(7), 944-957.
- Rafi, M., Devi, A. F., Syafitri, U. D., Heryanto, R., Suparto, I. H., Amran, M. B.,... & Lim, L. W. (2020). Classification of *Andrographis paniculata* extracts by solvent extraction using HPLC fingerprint and chemometric analysis. *BMC Research Notes*, 13(1), 1-6.

- Rajasekaran, M. (2019). Nephroprotective effect of *Costus pictus* extract against doxorubicin-induced toxicity on Wistar rat. ||| Bangladesh Journal of Pharmacology |||, 14(2), 93-100.
- Rajendrakumar, T., Rao, S., Satyanarayana, M. L., Narayanaswamy, H. D., Byregowda, S. M., & Purushotham, K. M. (2020). Cisplatin induced histopathological changes in the liver and its amelioration by *Andrographis paniculata*. The Pharma Innovation Journal, 9(5): 46-56.
- Rajendrakumar, T., Suguna, R., Satyanarayana, M. L., Narayanaswam, H. D., Byregowda, S. M., & Purushotham, K. M. (2020). Ameliorative effect of *Andrographis paniculata* against oxidative damage caused by cisplatin in rat kidney. Pharma Innov, 9(3), 356-359.
- Rasool, U., Parveen, A., & Sah, S. K. (2018). Efficacy of *Andrographis paniculata* against extended spectrum β -lactamase (ESBL) producing *E. coli*. BMC complementary and alternative medicine, 18(1), 1-9.
- Ratnawati, I. G. A. A., Suandayani, N. K. T., & Sutapa, G. N. (2019). The linearity of x-ray devices radiation output and its relationship with patient thickness. *International Journal of Physical Sciences and Engineering*, 3(3), 1-6. <https://doi.org/10.29332/ijpse.v3n3.351>
- Sagita, M. B., Turchan, A., Utomo, B., Fauzi, A. A., & Fauziah, D. (2022). Expression malondialdehyde (MDA) of brain after injury with the extract of kencur (*Kaempferia Galanga* L): Experimental study wistar rats. *International Journal of Health & Medical Sciences*, 5(1), 114-121. <https://doi.org/10.21744/ijhms.v5n1.1848>
- Sannasimuthu, A., Kumaresan, V., Pasupuleti, M., Paray, B. A., Al-Sadoon, M. K., & Arockiaraj, J. (2018). Radical scavenging property of a novel peptide derived from C-terminal SOD domain of superoxide dismutase enzyme in *Arthrospira platensis*. *Algal research*, 35, 519-529.
- Sharma, M., & Singh, A. (2019). Changes in Ultrastructure of Crossbred Bovine Spermatozoa in Butylated Hydroxytoluene Supplemented Semen. *Int J Livest Res*, 9, 64-69.
- Sharma, S., & Sharma, Y. P. (2018). Comparison of different extraction methods and HPLC method development for the quantification of andrographolide from *Andrographis paniculata* (Burm. f.) Wall. ex Nees. *Annals of Phytomedicine*, 7(1), 119-130.
- Sharma, V., Sharma, R., & Sharma, V. L. (2022). *Andrographis paniculata* mitigates first-line anti-tubercular drugs-induced nephrotoxicity in Wistar rats. *Biomarkers*, 1-13.
- Singh, P., Srivastava, M. M., & Khemani, L. D. (2009). Renoprotective effects of *Andrographis paniculata* (Burm. f.) Nees in rats. *Upsala Journal of Medical Sciences*, 114(3), 136-139.
- Subramaniam, S., Hedayathullah Khan, H. B., Elumalai, N., & Sudha Lakshmi, S. Y. (2015). Hepatoprotective effect of ethanolic extract of whole plant of *Andrographis paniculata* against CCl₄-induced hepatotoxicity in rats. *Comparative Clinical Pathology*, 24(5), 1245-1251.
- Suryasa, I. W., Rodríguez-Gómez, M., & Koldoris, T. (2021). Get vaccinated when it is your turn and follow the local guidelines. *International Journal of Health Sciences*, 5(3), x-xv. <https://doi.org/10.53730/ijhs.v5n3.2938>
- Tietz, N. W. (2006). *Clinical Guide to Laboratory Test*. 4th ed., Saunders. pp.86-71.

- Vairetti, M., Di Pasqua, L. G., Cagna, M., Richelmi, P., Ferrigno, A., & Berardo, C. (2021). Changes in glutathione content in liver diseases: An update. *Antioxidants*, 10(3), 364.
- Venmathi Maran, B. A., Iqbal, M., Gangadaran, P., Ahn, B. C., Rao, P. V., & Shah, M. D. (2022). Hepatoprotective Potential of Malaysian Medicinal Plants: A Review on Phytochemicals, Oxidative Stress, and Antioxidant Mechanisms. *Molecules*, 27(5), 1533.
- Xu, X., Liu, A., Hu, S., Ares, I., Martínez-Larrañaga, M. R., Wang, X.,... & Martínez, M. A. (2021). Synthetic phenolic antioxidants: Metabolism, hazards and mechanism of action. *Food Chemistry*, 353, 129488.
- Zamzam, N. S., Abdel Rahman, M. H., & Abdel Ghani, M. F. (2019). Environmentally evaluated new HPLC/UV method for the simultaneous determination of acesulfame-k, butylated hydroxytoluene, and aspartame and its degradant in chewing gum. *Journal of AOAC International*, 102(6), 1892-1900.
- Zeghib, K., & Boutlelis, D. A. (2021). Food Additive (Sodium benzoate)-induced Damage on Renal Function and Glomerular Cells in Rats; Modulating Effect of Aqueous Extract of *Atriplex halimus* L. *Iranian Journal of Pharmaceutical Research: IJPR*, 20(1), 296.