

**How to Cite:**

Dubey, P., Rohatgi, S., Khan, F., Nirhale, S., Rao, P., Naphade, P., Gitay, A., Gupta, S., & Kotaru, V. S. (2022). Longitudinally extensive transverse myelitis with aquaporin-4 antibody after herpes zoster: A case report. *International Journal of Health Sciences*, 6(S7), 2023–2028. <https://doi.org/10.53730/ijhs.v6nS7.11744>

# Longitudinally extensive transverse myelitis with aquaporin-4 antibody after herpes zoster: A case report

**Prashant Dubey**

DM Resident Department of Neurology, Dr DY Patil Medical College, Hospital and Research Centre, Dr DY Patil Vidyapeeth, Pune, Maharashtra, India  
Corresponding Author email: [drprashantdubey70@gmail.com](mailto:drprashantdubey70@gmail.com)

**Sharesh Rohatgi**

Professor and Head Department of Neurology, Dr DY Patil Medical College, Hospital and Research Centre, Dr DY Patil Vidyapeeth, Pune, Maharashtra, India

**Furqan Khan**

DM Resident Department of Neurology, Dr DY Patil Medical College, Hospital and Research Centre, Dr DY Patil Vidyapeeth, Pune, Maharashtra, India

**Satish Nirhale**

Professor Department of Neurology, Dr DY Patil Medical College, Hospital and Research Centre, Dr DY Patil Vidyapeeth, Pune, Maharashtra, India

**Prajwal Rao**

Associate Professor Department of Neurology, Dr DY Patil Medical College, Hospital and Research Centre, Dr DY Patil Vidyapeeth, Pune, Maharashtra, India

**Pravin Naphade**

Assistant Professor Department of Neurology, Dr DY Patil Medical College, Hospital and Research Centre, Dr DY Patil Vidyapeeth, Pune, Maharashtra, India

**Advait Gitay**

DM Resident Department of Neurology, Dr DY Patil Medical College, Hospital and Research Centre, Dr DY Patil Vidyapeeth, Pune, Maharashtra, India

**Sahil Gupta**

DM Resident Department of Neurology, Dr DY Patil Medical College, Hospital and Research Centre, Dr DY Patil Vidyapeeth, Pune, Maharashtra, India

**V.V. Sravya Kotaru**

DM Resident Department of Neurology, Dr DY Patil Medical College, Hospital and Research Centre, Dr DY Patil Vidyapeeth, Pune, Maharashtra, India

**Abstract**--Varicella zoster virus (VZV) is human neurotropic virus. It becomes latent in dorsal root ganglia; it may reactivate and can cause dermatological manifestations; most common is herpes zoster. Several neurological disorders can occur such as encephalitis, meningitis, myelitis and neuropathy. Longitudinally extensive transverse myelitis is infrequent. The association of AQP4 antibody with Varicella zoster has been documented in few case reports. Here we report a case of young woman who developed longitudinally extensive transverse myelitis with positive AQP4 antibody titers following varicella zoster infection.

**Keywords**---Aquaporin- 4 Antibody, Longitudinal Extensive Transverse Myelitis, Herpes zoster.

## Introduction

Longitudinally extensive transverse myelitis (LETM) refers to inflammatory intramedullary lesion extending over at least three vertebral bodies. It is an uncommon severe neurological complication which is usually seen in immunocompetent individuals<sup>1</sup>, with very few cases reported in immunocompromised ones.<sup>2-4</sup> In some patients, Varicella Zoster induced LETM has been associated with anti-aquaporin-4 antibody serology indicating association to neuromyelitis optica spectrum disorder.<sup>5-8</sup>

## Clinical Summary

We report a case of LETM in a 22 year old female patient who presented with the complaints of acute onset weakness in all the four limbs with bladder and bowel involvement. One month ago, there were painful vesicular eruptions on the outer aspect of left breast. She was diagnosed with Herpes zoster and treated with a ten-day course of oral acyclovir (800 mg five times a day). There were no visual complaints.

On neurologic examination patient was conscious and cooperative. Vision was normal. Fundus examination revealed normal optic discs. Other cranial nerves were normal. She had quadriparesis with grade 1/5 power in both lower extremities and grade 2/5 power in both upper limbs. Deep tendon reflexes were increased in the upper and lower extremities and both plantar reflexes were extensor. Touch and pain were impaired below T2 dermatome. Joint position and vibration sense was impaired upto both anterior superior iliac spines.

## Pathological Finding

Laboratory investigations like complete blood cell count, liver enzymes, creatinine and urinalysis were normal. ESR, C-reactive proteins were raised. Serological tests for brucellosis hepatitis B and C, herpes simplex virus, cytomegalovirus, Epstein-Barr virus, human immunodeficiency virus was negative. Serum anti-VZV antibodies test was positive and CSF anti-VZV antibodies were negative. Anti

nuclear antibody test was negative and Anti-Aquaporin -4 antibodies was strongly positive. Cranial MRI was normal. Cervical MRI demonstrated longitudinally extensive T2-hyperintense signal from C1 to C4 level which was enhancing after contrast administration. Visual Evoked potentials were normal.

### Management and Outcome

The patient was diagnosed as anti aquaporin-4 associated longitudinally extensive transverse myelitis (NMO) and was given 5-day course of intravenous methylprednisolone. As there was little improvement in her clinical status, she underwent 7 cycle of plasmapheresis. She showed gradual improvement and after 3 months she was able to walk with support, had normal sensation in her legs and normal sphincter functions.

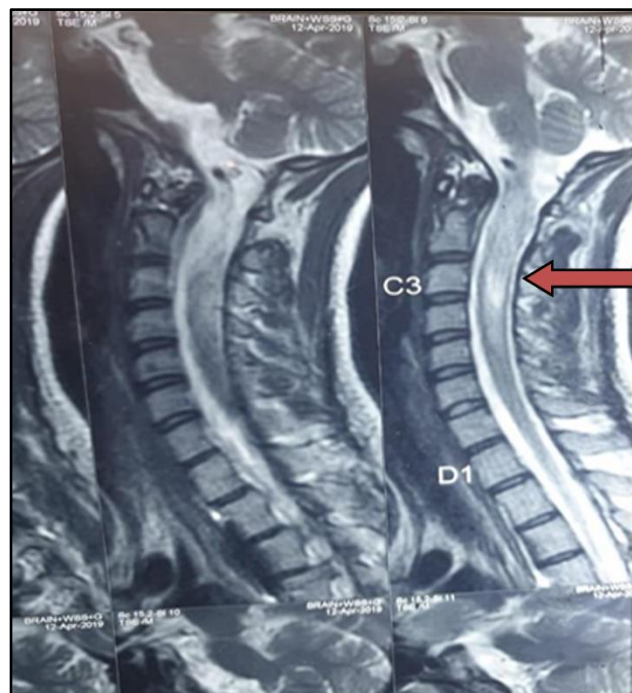

Fig 1: MRI-Cervical Spine demonstrating T2 hyperintensities from C1 to C4 level.

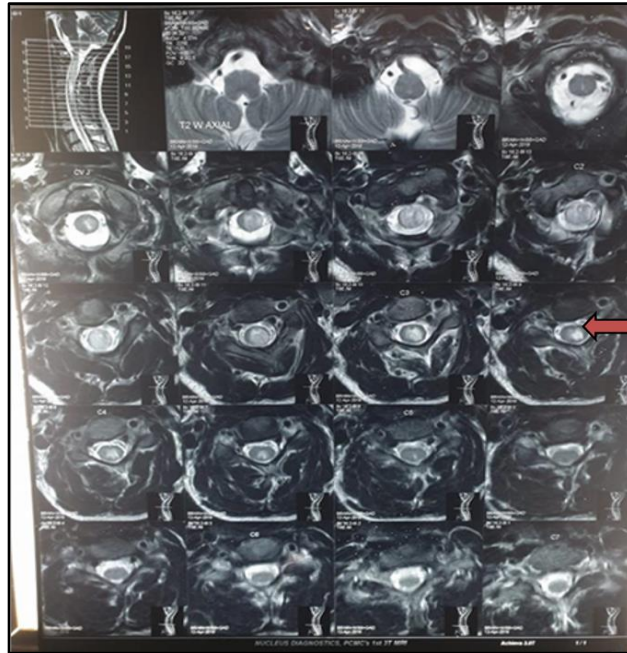


Fig 2: MRI-Axial section of cervical spine showing T2 hyperintense signal from C1 to C4.

### Discussion

LETM is a variant of acute transverse myelitis and is defined by continuous lesions involving three or more spinal cord segments. It has acute calamitous onset and outcome is poor and is commoner in immunocompetent patients. In few cases, LETM-VZV may affect healthy immunocompetent cases. Very few cases of Aquaporin 4 antibodies positive LETM have been described.<sup>15</sup> Its occurrence was first described in Japan in 2011, the patient was immunocompetent with P-ANCA glomerulonephritis, which followed herpes zoster infection and had irregularly disseminated moth-eaten appearance of spinal cord on MRI.<sup>2</sup> One case was described in Brazil in a young male, in whom symptoms started after one week of rash and the MRI findings were similar to those of NMOSD.<sup>3</sup>

The pathogenesis of LETM-VZV is unclear. Myelitis is thought to be due to direct invasion of virus showing Cowdry type A intranuclear inclusions in spinal root ganglia and positive immunostaining for VZV antigens based on postmortem data.<sup>9-11</sup> A vascular and allergic hypothesis has also been proposed to intervene but to a lesser extent.<sup>9,12-14</sup>

The post infection auto immune reactions can be molecular mimicry between agent causing infection and antigens of central nervous system and inflammatory processes secondary to microbial superantigens.<sup>12</sup>

The basis of diagnosis is based on serum (VZV IgG and IgM) and CSF (VZV IgG and/or VZV DNA) markers. In this case serum VZV antibody was positive but not in CSF suggesting no intrathecal production of VZV antibodies.

Molecular mimicry has been thought to be due to B-cells activation which causes production of antibody which recognize both the microbial and the self-AQP4 epitopes. Alternatively, damage to the AQP4-rich tissue by microbes, lead to the stimulation of AQP4-specific T and B-cells. In our case, we hypothesize that AQP4-abundant spinal cord tissue damage was due to the anti AQP4-IgG antibodies following VZV infection.

### **Conclusion**

VZV can cause myelitis due to direct invasion of cord, due to intrathecal production of VZV antibodies or production of anti Aquaporin 4 antibodies.

### **References**

1. Amlie-Lefond C, Jubelt B. Neurologic manifestations of varicella zoster virus infections. *Curr Neurol Neurosci Rep.* 2009 Nov;9(6):430-4. doi: 10.1007/s11910-009-0064-z.
2. Tajima, Y Mito, Longitudinally disseminated spinal cord lesions (moth-eaten appearance) in varicella-zoster myelitis. *Intern. Med.* 2011; 50: 2059–2060.
3. Fernandes B.F.S, Santos G, Carmona K.C, Vale T.C, Caramellin P. Varicella-zoster virus longitudinally extensive myelitis in an immunocompetent patient. *Rev. Bras. Neurol.* 2014; 50: 1–3.
4. Lee J.E, Lee S, Kim K.H, Jang H.R, Park Y.J, Kang J.S., Han S.Y. A case of transverse myelitis caused by varicella zoster virus in an immunocompetent older patient. *Infect. Chemother.* 2016; 48: 334–337.
5. Mathew, T, Thomas K, Shivde S, Venkatesh S, Rockey S.M, Post herpes zoster infection neuromyelitis optica spectrum disorder. *Mult. Scler. Relat. Disord.* 2017; 18: 93–94.
6. Heerlein K, Jarius S, Jacobi C, Aquaporin-4 antibody positive longitudinally extensive transverse myelitis following varicella zoster infection. *J. Neurol. Sci.* 2009; 276: 184–186.
7. Suda M, Tsutsumiuchi M, Uesaka Y, Hayashi N. A case of anti aquaporin-4 antibody positive myelitis with hyperhidrosis, following herpes zoster. *Rinsho Shinkeigaku* 2017; 57: 26–28.
8. Park J.S, Hwang S.J, Shin. A recurrent longitudinally extensive transverse myelitis with Aquaporin-4 (AQP4) antibody after herpes zoster. *J. Neurol. Sci.* 2013; 334: 69–71.
9. Hung C.H, Chang K.H, Kuo H.C, Huang C.C, Liao M.F, Tsai Y.T, Ro L.S. Features of varicella zoster virus myelitis and dependence on immune status. *J. Neurol. Sci.* 2012; 318: 19–24.
10. Wang, Y.; Yu, C.Y.; Huang, L.; Han, Y.Y.; Liu, Y.M.; Zhu, J. Acute longitudinal and hemorrhagic myelitis caused by varicella-zoster virus in an immunocompetent adolescent. *Neurologist* 2015;19: 93–95.
11. Hogan E.L, Krigman M.R, Herpes zoster myelitis: Evidence for viral invasion of spinal cord. *Arch. Neurol.* 1973; 29: 309–313.

- 12-Gilden D, Nagel M.A, Mahalingam R, Mueller N.H, Clinical and molecular aspects of varicella zoster virus infection. *Future Neurol.* 2009; 4: 103–117.
13. Kerr D.A, Ayetey H, Immunopathogenesis of acute transverse myelitis. *Curr. Opin. Neurol.* 2002; 15: 339–347.
14. Outteryck O, Deramecourt V, Bombois S, VZV-related myelitis: A pathophysiological hypothesis. *Rev. Neurol.* 2007; 163: 89–92.
15. Nagel, M.A.; Gilden, D. Complications of varicella zoster virus reactivation. *Curr. Treat. Options Neurol.* 2013, 15, 439–453.
16. Suryasa, I. W., Rodríguez-Gámez, M., & Koldoris, T. (2021). Health and treatment of diabetes mellitus. *International Journal of Health Sciences*, 5(1), i-v. <https://doi.org/10.53730/ijhs.v5n1.2864>