

How to Cite:

Prasad, N., Bidkar, S. V., Keshini, K., Nagasaireddy, N., Baig, F. A. H., Jawarker, R., & Rajesh, D. (2022). Bone resorption post open reduction and internal fixation of mandibular condylar head fractures: An original research. *International Journal of Health Sciences*, 6(S7), 2615–2620. <https://doi.org/10.53730/ijhs.v6nS7.11917>

Bone resorption post open reduction and internal fixation of mandibular condylar head fractures: An original research

Dr. N. Prasad

Associate professor, Department of Oral and Maxillofacial Surgery, Government Dental College and Hospital, Afzalgunj, Hyderabad
Corresponding Author email: drprasadosm@gmail.com

Dr. Sudhakar Vikramrao Bidkar

Professor And HOD, Dept. Of Oral & Maxillofacial surgery, Aditya Dental College, Beed, Maharashtra. drsvbidkar
Email: os@rediffmail.com

Dr. Keshini

MP, MDS, Senior Lecturer, Department of Oral and Maxillofacial Surgery, Coorg Institute of Dental Sciences, Coorg, Karnataka
Email: keshini.mp@gmail.com

Dr. Nagasaireddy

Senior lecturer, Dept of oral and maxillofacial surgery, Vishnu dental college, Bhimavaram, AP
Email: nagasaireddy555@gmail.com

Dr. Fawaz Abdul Hamid Baig

Assistant professor. Dept of Oral and Maxillofacial surgery, King Khalid University College of Dentistry, Abha, KSA
Email: fbik@kku.edu.sa

Dr. Rohie Jawarker

MDS, Consultant Oral and Maxillofacial Surgeon, Allahabad, UP
Email: rohie90j@gmail.com

Dr. Damarasingu Rajesh

OMFS, PhD Scholar, Dept of OMFS, Narsinhbhai Patel Dental College and Hospital, Sankalchand Patel University, Visnagar, Gujarat
Email: rajeshoralsurgeon@gmail.com

Abstract--Introduction: The various changes after ORIF and the internal fixation of condylar head fractures are available for a less

follow up period only. Hence in this study we evaluated bone resorption after open reduction and internal fixation of condylar head fractures of the mandible. **Materials and Methods:** A retrospective analysis of patients who underwent open reduction and internal fixation of condylar head fractures was conducted. The bone resorption on the condylar head was measured after removal of osteosynthesis material by segmenting and superimposing of the postoperative 3D radiologic follow-up exam (T2) over the initial intraoperative cone-beam computed tomography (T1). **Results:** We observed that in the total of 150 patients, the mean follow-up time was 25.6 months. The mean bone resorption on the condylar head is -5.16% of segmented condylar head. There was no correlation of clinical outcome and bone resorption. **Conclusions:** The mean bone resorption rate of -5.16% in the intermediate-term follow-up time is comparable to findings of other studies with short-term follow-up time. The bone resorption is seen in the first few months postoperative and is lower in the next months.

Keywords---Bone Resorption, Open Reduction, Internal Fixation, Condylar Head Fractures.

Introduction

The management of condylar fractures is debated. Closed reduction approaches have demonstrated better long-term maximal mouth opening (MMO) without the risk for facial nerve injury or mastication. Open reduction and internal fixation (ORIF) offer the potential to restore the preinjury anatomic relationships, stabilize the fracture, enable rapid fracture healing and evade prolonged maxillomandibular fixation.¹⁻⁵ Although different types of plates for the fixation of condylar process fractures have been defined in the literature no comparative analysis amongst these different fixation systems has been described. The miniplate is used most often, followed by the microplate. Miniplate osteosynthesis has been the standard fixation system used for open treatment of mandibular fractures during the past few decades. Miniplates deliver functionally stable fixation of condyle fractures, and several studies have demonstrated good clinical and radiological results.⁴⁻⁹ Microplates for internal fixation were introduced in the late 1980s¹⁰ and offer many advantages over miniplates, such as requiring less manipulation, being more malleable and easier to adapt to the shape of the bone, being less likely to cause iatrogenic damage, and carrying a lower rate of major complications.¹⁰ The application of microplate fixation systems for the repair of isolated unilateral or bilateral condylar fractures without comminution or bony defects has also been previously stated. Hence in this study we evaluated bone resorption after open reduction and internal fixation of condylar head fractures of the mandible.

Material and Methods

We conducted a retrospective study at the department of the oral and maxillofacial surgery. The study included the cases of the condylar head or neck

fractures operated at the department for the last 10 years 2011 to 2021. Both the microplates system and miniplates system were used. Both the unilateral fractures, bilateral fractures and the subcondylar fracture, were included in the study. A pre-treatment CT scan determined condylar process fracture. The protocol for the ORIF surgery was followed as per the guidelines. ORIF via a 3-cm preauricular incision was done by from the inferior aspect of the zygomatic arch. The fracture was fixed using miniplate or microplate system fixation techniques. If there was sufficient space for placement of a plating system, either miniplates or microplates were chosen for rigid fixation. Otherwise, the displaced condylar head was fixed with either miniscrew (2.0 mm) or microscrew (1.3 mm) similar to lag screw fashion. Light intermaxillary fixation guided by rubber bands was applied in the early postoperative period. The patients underwent routine clinical follow-up at least 1, 3, 6, and 12 months postoperatively. The MMO and occlusion were assessed clinically and recorded. Postoperative CT scans obtained at least 6 months after surgery and also later were assessed for bone resorption. The radiographic results were scored on a scale of 1 to 4 according to the classification scheme proposed by proposed by Iizuka et al. The data obtained were compared at various time periods keeping the $p < 0.05$ as significant.

Results

A total of 150 condylar fractures were diagnosed preoperatively. The mean age of our patients was 27 ± 4 years. The mean duration of follow-up was 25.6 months. The age, sex ratio, presence of concomitant mandibular and/or maxillary fractures, duration of follow-up, and time from injury to intervention did not differ significantly between the miniplate and microplate groups. Malocclusion was the most common complication in both groups, and the rates of complications did not differ significantly between the groups.

The primary measure of postoperative function in all patients was the MMO. There was significant difference between the two types of the systems. **Figure 1** The primary radiographic outcome measure was bone resorption. The microplate group demonstrated significantly higher scores with less bone resorption than the miniplate group at all follow-up time points, including 6 months (3.24 vs 2.81, $P = 0.011$), 12 months (3.72 vs 2.64, $P = 0.032$), 24 months (3.71 vs 2.79, $P = 0.025$), and 36 months (3.71 vs 2.75, $P = 0.041$) after ORIF (Table 1).

Table 1. Comparison of Radiographic Condylar Resorption Scores by Plating System

6 mo	Period of Follow-up				
		12 mo	24 mo	36 mo	48 mo
No.	MeanNo.	MeanNo.	MeanNo.	MeanNo.	MeanNo.
	Scor	Scor	Scor	Scor	Scor
	e	e	e	e	e
Condyle	(SD)	(SD)	(SD)	(SD)	(SD)
s	s	s	s	s	s

Microplate fixation	3.24 (0.59)	3.72 (0.49)	3.72 (0.44)	3.71 (0.48)	3.66 (0.50)
Miniplate fixation	2.79 (0.98)	2.67 (1.12)	2.79 (1.12)	2.75 (1.04)	2.43 (1.27)
<i>P</i> = 0.011		<i>P</i> = 0.032	<i>P</i> = 0.025	<i>P</i> = 0.045	<i>P</i> = 0.041

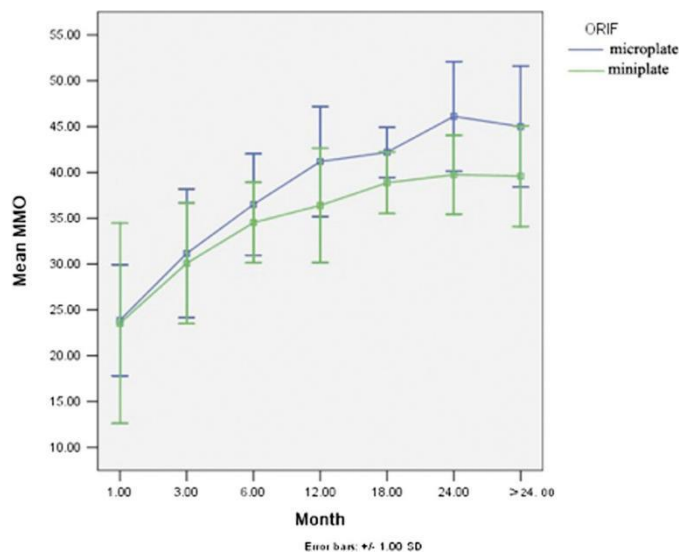


Figure 1. Comparison of maximal mouth opening (MMO) between microplate and miniplate fixation.

Discussion

The observations of our study show that the microplates are valuable in the treatment of intracapsular condylar head fractures by ORIF. Microplates allow the surgeon to be more conservative as they are small and rigid at the same time.^{4,5,9} In our study there were no significant variations in complications was observed between condylar neck fractures treated with microplate and miniplate fixation.

No significant difference in the malocclusion was noted between the two over the period of the follow up in our study. The functional outcome, was better in the microplate group during the total follow-up period, although not significant. We believe the key cause of the gradual manifestation of this difference to be the slow recovery of neuromuscular function. Nevertheless, as in the previous studies^{9,10} the difference became statistically significant beginning 1 year after surgery and continued so throughout our follow-up period.

We also noted that microplates showed a lead over miniplates was in the amount of postoperative bone resorption. While miniplates have usually been used for the

repair of condylar process fractures, there have been studies of resorption of the condylar head after ORIF with these plates. In 1991, Iizuka et al.⁴ reported 13 cases of high condylar fractures treated by ORIF and miniplate fixation that showed postoperative radiographic signs of severe bone resorption and osteoarthritis. Correct condylar reduction and tridimensional stabilization can thus prevent poor postoperative remodeling.⁵ Eventually, the cause of condylar resorption is most likely multifactorial, with the use of miniplate system fixation resulting in both more extensive detachment of the periosteum and greater tissue damage due to the intrinsic influence of stronger hardware.

There were few limitations in our study. The follow up period of all the participants was different. Some of the participants were followed up for only 9 months post surgery. Microplates need lower manipulation during placement, attain a higher degree of adaptation to the fracture site, and permit occlusal self-adjustment. Also, the condylar resorption may be due to the lower vascular supply and an adequate reduction, may bring about good results.

Conclusion

We observed that the maximum of the bone resorption occurs in 4-6 months period. In prevention of negative sequelae of protruding implants, timing of osteosynthesis material removal after this period of high bone remodeling activity is recommended. Further studies are needed to confirm our observations.

References

1. Yang WG, Chen CT, Tsay PK, et al. Functional results of unilateral mandibular condylar process fractures after open and closed treatment. *J Trauma*. 2002;52:498Y503.
2. Ellis E 3rd, McFadden D, et al. Surgical complications with open treatment of mandibular condylar process fractures. *J Oral Maxillofac Surg*. 2000;58:950Y958.
3. Gerbino G, Boffano P, Tosco P, et al. Long-term clinical and radiological outcomes for the surgical treatment of mandibular condylar fractures. *J Oral Maxillofac Surg*. 2009;67:1009Y1014.
4. Iizuka T, Lindqvist C, Hallikainen D, et al. Severe bone resorption and osteoarthritis after miniplate fixation of high condylar fractures. A clinical and radiologic study of thirteen patients. *Oral Surg Oral Med Oral Pathol*. 1991;72:400Y407.
5. Hlawitschka M, Loukota R, Eckelt U. Functional and radiological results of open and closed treatment of intracapsular (diacapitular) condylar fractures of the mandible. *Int J Oral Maxillofac Surg*. 2005;34:597Y604.
6. Choi BH, Yi CK, Yoo JH. Clinical evaluation of 3 types of plate osteosynthesis for fixation of condylar neck fractures. *J Oral Maxillofac Surg*. 2001;59:734Y737; discussion 738.
7. Sauerbier S, Schon R, Otten JE, et al. The development of plate osteosynthesis for the treatment of fractures of the mandibular body: a literature review. *J Craniomaxillofac Surg*. 2008;36:251Y259.

8. Benech A, Arcuri F, Baragiotta N, et al. Retroauricular transmeatal approach to manage mandibular condylar head fractures. *J Craniofac Surg.* 2011;22:641Y647.
9. He D, Yang C, Chen M, et al. Modified preauricular approach and rigid internal fixation for intracapsular condyle fracture of the mandible. *J Oral Maxillofac Surg.* 2010;68:1578Y1584.
10. Luhr HG. A micro-system for cranio-maxillofacial skeletal fixation. Preliminary report. *J Craniomaxillofac Surg.* 1988;16:312Y314.
11. Suryasa, I. W., Rodríguez-Gómez, M., & Koldoris, T. (2022). Post-pandemic health and its sustainability: Educational situation. *International Journal of Health Sciences*, 6(1), i-v. <https://doi.org/10.53730/ijhs.v6n1.5949>