

**How to Cite:**

Vibha, H., Mrunalini, V., Surelee, C., & Simren, B. (2022). Effectiveness of pulpotomy vs root canal treatment on postoperative pain and the treatment outcome in the management of permanent mature posterior teeth with symptomatic irreversible pulpitis: A systematic review and meta-analysis. *International Journal of Health Sciences*, 6(S7), 2634–2657.  
<https://doi.org/10.53730/ijhs.v6nS7.11920>

# **Effectiveness of pulpotomy vs root canal treatment on postoperative pain and the treatment outcome in the management of permanent mature posterior teeth with symptomatic irreversible pulpitis: A Systematic Review and Meta- analysis**

**Dr. Hegde Vibha**

M.D.S, H.O.D And Professor, Department Of Conservative Dentistry And Endodontics, Y.M.T Dental College And Hospital, Kharghar 7400465066  
Correspondence email: [vibhahegde26@gmail.com](mailto:vibhahegde26@gmail.com)

**Dr. Vaidya Mrunalini**

M.D.S, Professor, Department Of Conservative Dentistry And Endodontics, Y.M.T Dental College And Hospital, Kharghar

**Dr. Chavan Surelee**

B.D.S, Post-Graduate Student, Department Of Conservative Dentistry And Endodontics, Y.M.T Dental College And Hospital, Kharghar

**Dr. Bhatia Simren**

B.D.S, Post-Graduate Student, Department Of Conservative Dentistry And Endodontics, Y.M.T Dental College And Hospital, Kharghar

**Abstract---**Aim and objective: The objective of the present systematic review is to evaluate the success of pulpotomy in mature permanent teeth presented with irreversible pulpitis. Methodology: The following databases were searched: MEDLINE, EMBASE, Cochrane Library, CINAHL Complete, Scopus, and ClinicalTrials.gov. We included studies published in the English language only. However, narrative reviews and case reports/series were excluded. The first electronic and hand search yielded a total of 210 articles. After going through extensive screening and eligibility process, only thirteen articles were finally selected for the review. The follow-up period ranged from 1 to 10years. A Meta- analysis of two randomized clinical trials was performed using RevMan 5.4 (RevMan 5.4, The Nordic Cochrane Centre, Copenhagen). Results: Randomized controlled trials which compared pulpotomy with

the root canal treatment reported comparable success of pulpotomy. All the other studies have also shown comparable clinical and radiographic success of pulpotomy. Conclusion: Pulpotomy can be considered an alternative option for mature permanent teeth with irreversible pulpitis.

**Keywords**---Irreversible pulpitis, pulpotomy, root canal treatment.

## Introduction

With the introduction of novel bioactive materials and evidence-based knowledge of biological mechanisms of the pulp-dentin complex; a new endodontic treatment paradigm centered on tissue preservation has emerged leading to lesser invasive procedures being explored in managing pulpal diseases. (1) The basic goal of all restorative operations is to preserve the vitality of the dental pulp whenever possible, and hence, the viability of minimally invasive approaches of vital pulp therapies such as direct pulp capping, partial and full pulpotomy options in the management of carious exposures in symptomatic teeth with reversible and irreversible pulpal involvement due are being investigated.

(2) Preservation of the vital pulp aids in maintaining its proprioceptive, reparative, innervative, vascular, and defensive functions; all of which aid in the protection against damaging stimuli. (3)

However, these newly explored concepts have had their roots deep in the history of endodontology. Seltzer and Bender while describing the pathobiology of the dentinopulpal complex stated that not all pulpal inflammatory reactions result in permanent damage to the pulp. In fact, chronic inflammation is sometimes regarded as "frustrated repair" wherein if the caries lesion is eliminated or becomes arrested inflammation undergoes resolution and healing occurs. Consequently, a major goal of restorative dentistry should be to rid the dentin of bacteria so that the inflamed pulp may heal. This is the rationale for the use of vital pulp therapy. (4)

Appropriate caries management within vital pulp therapy aims to remove the microbial irritation and prevent new bacterial insult by placing a seal of dental biomaterial to protect exposed dentine and pulp from external stimuli. Therapeutically, vital pulp therapy is quicker, less technically complex, and less invasive than pulpectomy and root canal treatment (RCT), while also reducing unwanted effects such as discoloration, fracture, or residual periapical inflammation. (5) Moreover, conventional root canal therapy has certain disadvantages, being time-consuming, expensive, and requiring multiple visits making the teeth susceptible to fractures due to loss of tooth structure. (6) The vast infrastructure, exclusive armamentarium, and high level of skill demanded by the treatment make it more challenging.

The indications of vital pulp therapy have been clearly outlined in the literature. Teeth having pulpal exposure that can be controlled effectively within 30 seconds to 1 minute, those having limited pulpal pathology as indicated by milder

preoperative pain, no involvement of periapical areas or bone loss are ideal for these procedures. Histopathologically, the spread of caries is restricted to the coronal portion of the pulp and is easy to isolate and remove without disturbing the radicular pulpal tissue. It is therefore important to identify each case for its own merits and demerits followed by a selection of the correct treatment protocol. (7)

Traditionally, severe symptoms are associated with irreversible pulpitis in which the pulp condition has little chance to revert to normal after the removal of the irritants, and, therefore, root canal therapy is indicated. However, several studies have shown that mature teeth with symptomatic irreversible pulpitis are capable of regeneration, and vital pulp therapy need not be restricted to young or asymptomatic teeth. (6,8) Furthermore, the presence of spontaneous or severe preoperative pain does not always indicate that the pulp is not capable of repair (9), and deep carious lesions are not unconditionally related to an irreversible pattern of pulpal pathology. However, a partial or full pulpotomy is indicated in such cases rather than simply capping the exposed pulp (10), and the ability to control bleeding after amputation has been suggested as the critical point in terms of the expected outcome.

The choice of pulpotomy agent is an important decisive factor that can influence the success rate of this technique. An ideal endodontic biomaterial for vital pulp therapy must be biocompatible and antibacterial, able to provide a biological and microbial seal, and promote the regeneration of the dentine-pulp complex.

Multiple randomized control trials and clinical studies have since been undertaken to evaluate the success rate of Vital pulp therapy as a treatment modality for permanent teeth with irreversible pulpitis, through clinical and radiographic measures. However, there is still a controversy regarding the ideal treatment for such cases due to the lack of comparative literature. Thus, this systematic review aims to

compare vital pulp therapy vs RCT in management of symptomatic irreversible pulpitis for relief in post-operative pain and its success rate in the long term to help clinicians have a better understanding and help solve the dilemma.

Thus,

The problem was specified according to the PICO format. The following research question defined the problem:

**Is pulpotomy (intervention) as effective as root canal treatment (comparator) in relieving pain (outcome) of symptomatic irreversible pulpitis and its treatment outcome in permanent mature posterior teeth (population)?**

## **Materials and Methodology**

### **Protocol And Registration:**

The research protocol is designed according to the PRISMA (Preferred Reporting Items for Systematic Review and Meta-Analyses) guidelines 2009. The protocol of

this systematic review was registered with the International Prospective Register of Systematic Review (PROSPERO CRD42021276892).

Two reviewers performed a principal comprehensive search by accessing electronic databases like MEDLINE, EMBASE, Cochrane Library, CINAHL Complete, Scopus, and ClinicalTrials.gov for relevant literature published up to November 2021. Additionally, grey literature was also searched for relevant data. Different search strategies were used to identify publications using Free terms and medical descriptors (e.g., MeSH terms) like “pulpitis”, “irreversible”, “pulpotomy” and “vital pulp therapy”, connected by a Boolean operator “AND” (e.g., PubMed search strategy: “Irreversible” AND “pulpitis” AND “Pulpotomy” [Mesh] OR “pulpotomy”). Specific inclusion and exclusion criteria were used to select studies for review.

### **Inclusion Criteria:**

- \_ Publications were in English, with full text available in either soft or hard copy.
- \_ Study designs included were either randomized controlled trials; single arm clinical trials; or retrospective studies;
- \_ Studies that performed partial or full pulpotomy were included;
- \_ Studies that selected a population comprising permanent mature posterior teeth;
- \_ Studies with a pulpal diagnosis of symptomatic irreversible pulpitis in the selected sample;
- \_ Studies that measured the outcome based on postoperative pain measured using VAS or NRS scales; Radiographic and clinical success rates were measured with a specific criterion;
- \_ Studies which assessed postoperative pain on an hourly basis;
- \_ Studies with long-term outcomes had a follow-up of 6 months or more for the success rate estimation;

### **Exclusion Criteria:**

- \_ Studies published in languages other than English;
- \_ Study designs like case series, in-vitro studies, animal studies, human histological studies, cohorts, or narrative reviews;
- \_ Studies that had a sample comprising of deciduous, permanent immature, or anterior teeth;
- \_ Studies which performed procedures other than pulpotomy such as direct or indirect pulp capping;

- \_ Studies having a pulpal diagnosis of asymptomatic irreversible pulpitis, reversible pulpitis or, non- vital pulp and pulp necrosis;
- \_ Studies having teeth with the preoperative presence of root resorption or calcifications;
- \_Studies having teeth with severe preoperative pain or teeth with large periapical lesions;
- \_Studies which included teeth not indicated for root canal treatment.

### PICOS Search Strategy Flowchart

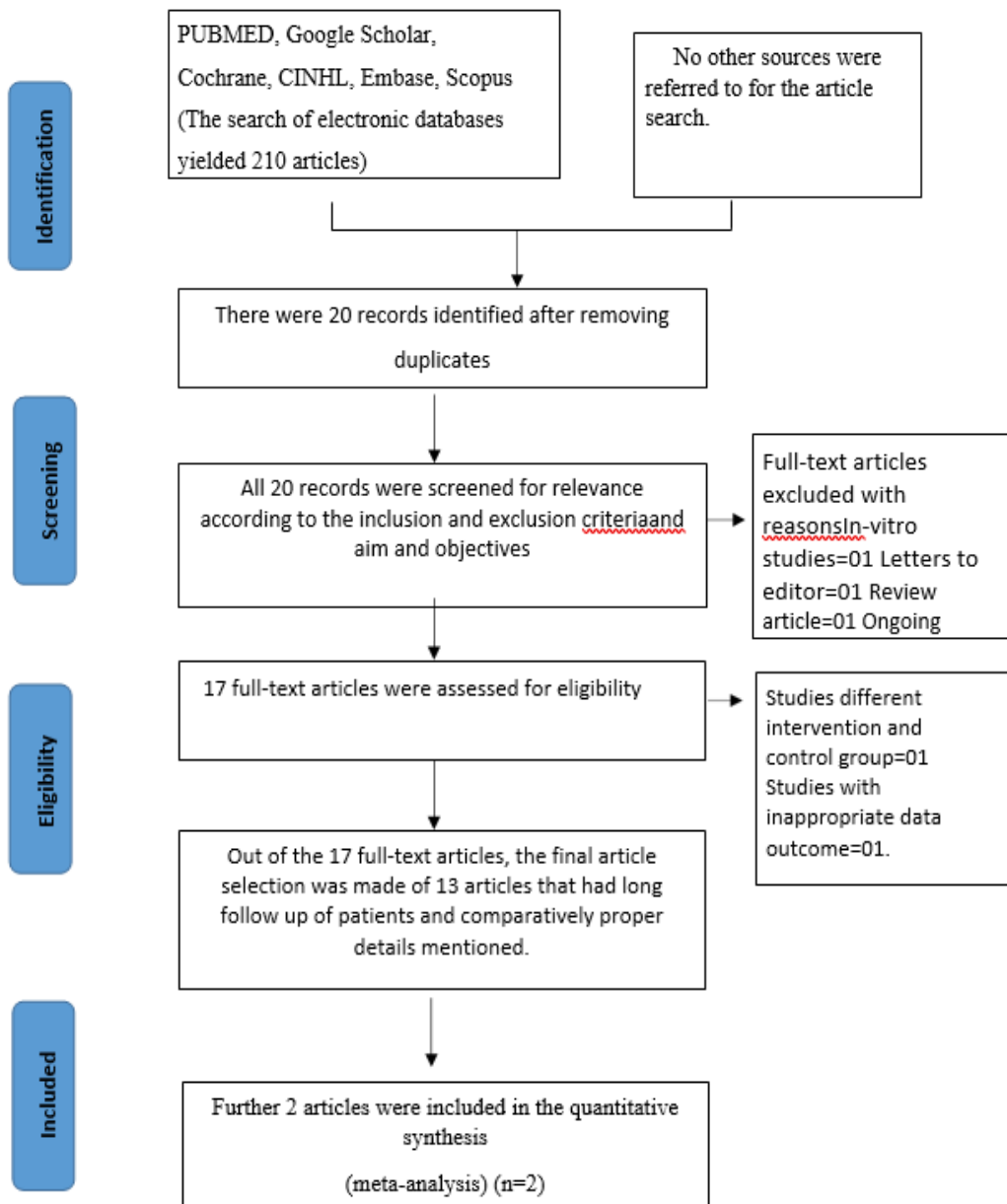


Figure 1: PRISMA flow chart

Table 1: Characteristics of included studies

Sr. no	Author (Year)	Sample Size	Age group	Diagnoses	Control procedure	Intervention procedure	Method of haemostasis	Pulpotomy agent	Pain assessment method	Short term follow-up	Long term follow-up	Results
1.	Asgary et al. 2010	407	9-65 yrs	Symptomatic irreversible pulpitis	Root canal treatment	Full pulpotomy	Cotton pellet and normal saline	Calcium enriched mixture (CEM)	NRS	3, 4, 5, 6, and 7 days	Upto 5 years	Pulpotomy with CEM reduced postop pain and percussion pain as compared to single visit RCT
2.	B. Eren et al. 2018	66	18-60 yrs	Symptomatic irreversible pulpitis with or without apical	Root canal treatment	Partial and Full pulpotomy	Dry cotton pellet and light pressure	Zinc oxide eugenol (ZOE)	VAS	1, 3, and 7 days		The total pulpectomy group reported greater reductions in pain intensity

				periodontitis								than the pulpotomy group between Days 0 and 7, Days 1 and 3, Days 1 and 7
3.	Galani et al. 2017	54		Irreversible pulpitis	Root canal treatment	Full pulpotomy	Cotton pellet and 2.5% NaOCl	MTA	VAS	1,2,3,4,5,6,7days		85% success rate in pulpotomy group, 87.5% in RCT group. Difference was insignificant
5.	Taha et al. 2017	50	>20 yrs	Irreversible pulpitis		Full pulpotomy	Cotton pellet and 2.5% NaOCl	CH/MTA			6months, 1 and 2 yrs	MTA pulpotomy is successful in 80% of cases as a permanent treatment option for

												irreversible pulpitis
6.	Uesrich ai et al 2019	67	6-18 yrs	Irreversible pulpitis		Partial pulpotomy	Cotton pellet and 2.5% NaOCl	MTA/ Biodentine			Every 6 months for 6 yrs	Both cements were successful (90%) in treating irreversible pulpitis
7.	Singh et al. 2020	60		Irreversible pulpitis		Full pulpotomy	Sterile saline solution	CH/MTA/ PRF	NRS	24h, 7days	1, 3, 6months, 1yr	A nonsignificant difference was observed in pain intensity recorded at numerical rating scale and success rate at baseline, 24h, 1 week, 1 month, 3 months, 6

												months, and 1 year.
8.	Bagheri et al. 2019	54		Symptomatic Irreversible pulpitis		Full pulpotomy		MTA/ Dexamethasone	VAS	6h,12h,18h,24h, 487 days		MTA pulpotomy severely reduced post-operative pain
9.	Kohli et al. 2020	60	18-35 yrs.	Symptomatic irreversible pulpitis with apical periodontitis	Root canal treatment	Full pulpotomy	Cotton pellet and 2.5% NaOCl	MTA	NRS	24h,48h,72h	6 months, 1yr	Pulpotomy reduces post operative pain and can be an alternative to RCT
10.	Kumar et al. 2016	54		Irreversible pulpitis		Full pulpotomy		MTA/ CH/ PRF	NRS	24h, 7days	6 months, 1 yr	Pulpotomy has acceptable clinical success in treating irreversible pulpitis

11.	Oudeimat et al. 2015	23	7-13 yrs.	Irreversible pulpitis		Full pulpotomy	5% NaOCl	MTA			3, 6months, 1 yr	MTA pulpotomy is successful in treating irreversible pulpitis
12.	Kunert et al. 2015	273	8-79 yrs.	Irreversible pulpitis		Full pulpotomy	Distilled water	CH			1yr, 2yrs, 3yrs, 5yrs, 10yrs	Pulpotomy may be a successful treatment at any age, and not only for young permanent teeth.
13.	Linsuwanon et al 2016	66	7-68 yrs.	Irreversible pulpitis		Full pulpotomy	2.5% NaOCl	MTA			8-62 months	MTA pulpotomy is successful in treating cariously exposed teeth

### Risk of Bias Within Studies:

The Risk of bias within the studies was evaluated independently by two review researchers. The studies were classified as low risk of bias, unclear and high-risk bias. The following domains were assessed.

**Table 2: Risk of bias for included studies**

Sr. no	Author (Year)	TYPE OF STUDY	Random sequence generation (selection bias)	Allocation concealment (selection bias)	Blinding of participants (performance bias)	Blinding of outcome (detection bias)	Incomplete outcome data (attrition bias)	Selective reporting (reporting bias)
1	Asgary (2010)	RCT	Yes	Yes	Yes	Yes	Yes	No
2	B. Eren (2018)	RCT	Yes	Yes	Yes	Yes	Unclear	No
3	Galani (2017)	RCT	Yes	Yes	Unclear	Yes	Yes	No
4	Eghbal (2020)	RCT	Yes	Yes	No	Yes	Yes	No
5	Taha (2017)	RCT	Yes	Unclear	Unclear	Unclear	No	No
6	Uesrichai (2019)	RCT	Yes	No	Yes	Yes	Unclear	No
7	Kumar (2016)	RCT	Yes	Yes	Yes	Yes	Unclear	No
8	Bagheri (2019)	RCT	Unclear	Unclear	Unclear	Unclear	Yes	No
9	Koli (2020)	RCT	Yes	Yes	Yes	Yes	No	No
10	Queidem at (2015)	Clinical trial	No	No	No	No	Unclear	No
11	Singh (2020)	Clinical study	No	No	No	No	Unclear	No

## Results

### Study Characteristics:

Thirteen articles were selected after screening the above-mentioned number of articles by two independent reviewers. Following careful examination, each data parameter related to the study or the selection criteria was discussed by the reviewers. Any discrepancies in opinion were resolved by the third reviewer. The data provided in the selected studies were recorded in the data extraction sheets (Table 1). The studies included in the review were performed between 2010 and 2020. The studies were in-vivo clinical trials performed on adult patients with ages ranging from 6-79 years and one retrospective study. Pre-operative pulpal status when assessed among the studies included in this review was found to be symptomatic irreversible pulpitis without periapical involvement in 12 studies, except in one study where it was symptomatic irreversible pulpitis with apical periodontitis (46) Five studies performed root canal treatment as the control procedure in the randomized clinical trials either in one-visit or two-visits (28,34,41-42,45) The remaining studies were either single-arm clinical studies or retrospective studies which performed only the intervention procedure of partial or full pulpotomy. All studies included mature permanent molars in the study population. In pulpotomy, full pulpotomy was performed by 11 studies, except for two studies that performed partial pulpotomy (32,41). Three studies achieved hemostasis using light pressure with a moist cotton pellet dipped in normal saline (28,32,34). This is a traditional method that has been used to control bleeding in pulpotomy procedures. Six articles used Sodium hypochlorite as the haemostatic agent (49,69-70,72,74,76) Five out of these used it at a concentration of 2.5% (49,69,70,72,74) while one study used a concentration of 5% NaOCl (74) Ten studies used MTA as the pulpotomy agent of choice, either as a comparator to other agents or as a single group (8,25,32,34,39,42-45,47). Calcium hydroxide was used in three studies (8,45-46) biodentine was used as a pulpotomy agent in one study (32) Calcium-enriched mixture (CEM)

in two studies (28,32) and some newer materials like PRF (25,45) dexamethasone (39) and Zinc oxide eugenol (ZOE) (41) were also used as pulpotomy agents for regenerative dentinal bridge formation. The pulpotomy agents were placed in the pulp chamber from 1.5mm-3mm thicknesses. Follow-up of postoperative pain ranged from 6hrs to 7 days and was recorded using a visual analog scale (VAS) or Numerical Rating Scale (NRS). Long-term follow-up periods ranged from 1 month to 10years which evaluated the swelling, periapical status, radiographic status, and other symptoms.

On short-term analysis for alleviating postoperative pain, pulpotomy showed a success rate of 80-95% when evaluated over for 1 week. Long-term follow-ups also showed non-significant differences in the success of pulpotomy as a treatment modality for symptomatic irreversible pulpitis when compared to the gold-standard treatment of root canal therapy.

Meta-analysis was conducted on 2 studies that qualified with the required data outcome that could be analysed quantitatively. The other studies were excluded as the data reported could not be analysed (which was not in mean+/-sd format).

The results are depicted as a forest plot in Figure.2,3 & 4.

**Table 3: An overview of the results**

Author	Study type	Sample size	Intervention	Material used	Results
Asgary	RCT	409	Pulpotomy	CEM	Successful
B. Eren	RCT	66	Partial and full pulpotomy	ZOE	Successful
Galani	RCT	54	Pulpotomy	MTA	Successful
Eghbal	RCT	550	Pulpotomy	MTA/CEM	Successful
Taha	RCT	50	Pulpotomy	CH/MTA	Successful
Uesrichai	RCT	67	Partial pulpotomy	MTA/ Biodentine	Successful
Singh	Clinical study	60	Pulpotomy	CH/MTA/PRF	Successful
Bagheri	RCT	54	Pulpotomy	MTA/Dexamethasone	Successful
Kohli	Prospective study	60	Pulpotomy	MTA	Successful
Kumar	RCT	54	Pulpotomy	CH/MTA/PRF	Successful
Qudeimat	Preliminary study	23	Pulpotomy	MTA	Successful

Kunert	Retrospective study	273	Pulpotomy	CH	Successful
Linsuwanont	Retrospective study	66	Pulpotomy	MTA	Successful

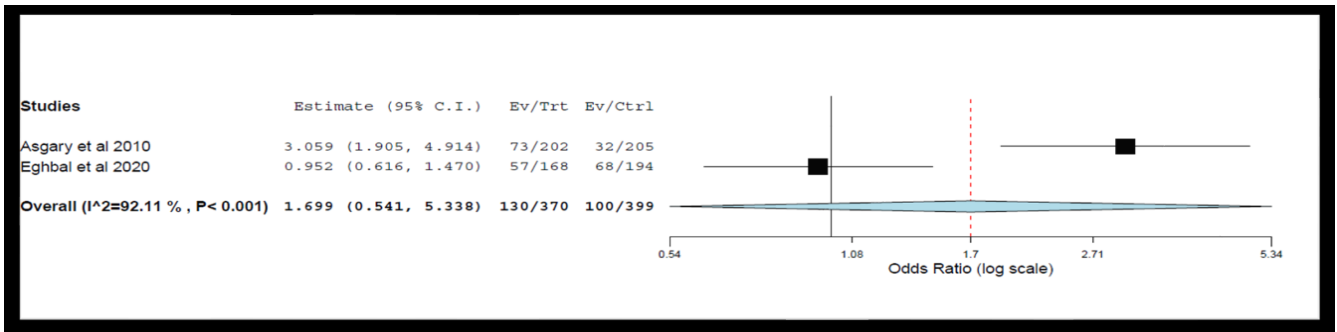


Figure 2: Forest plot of comparison: Time interval, outcome: 24 hrs

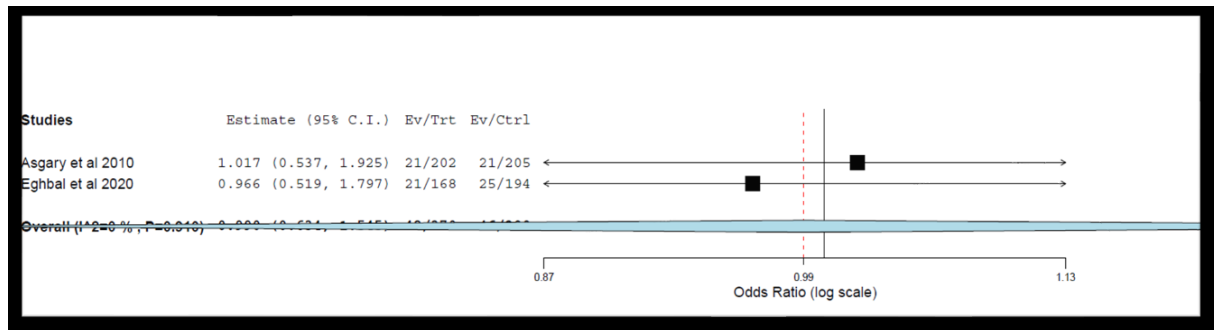


Figure 3: Forest plot of comparison: Time interval, outcome: 48hrs

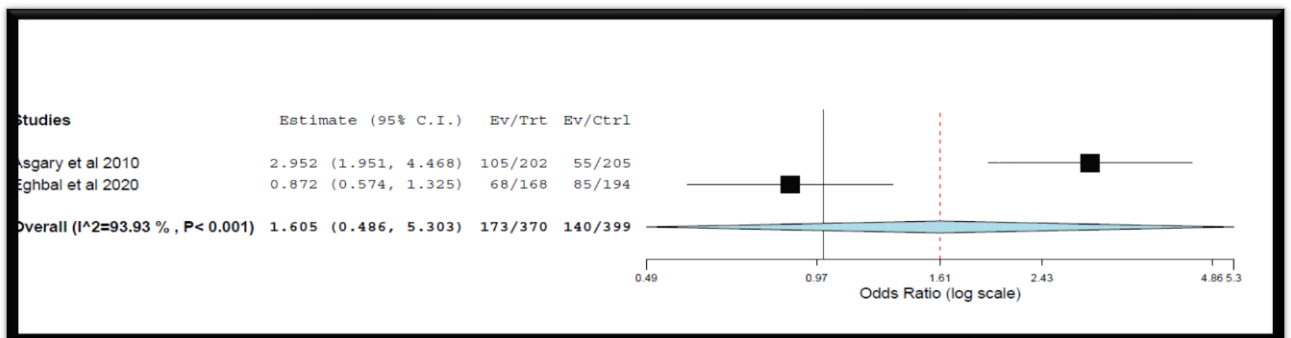


Figure 4: Forest plot of comparison: Time interval, outcome: 1 week

### Risk Of Bias In Individual Studies:

The Risk of bias was assessed by the two independent reviews for RCTs included in the review and discrepancies were resolved by discussion and appropriate consultation with a third reviewer. The domains for risk assessment were graded as high, uncertain, or low risk, based on selection bias (random sequence generation and allocation concealment), performance bias (blinding), detection bias (assessor blinding), attrition bias (incomplete outcome data), and reporting bias (selective reporting). Thus, the overall risk for individual studies was assessed as low, moderate, or high risk based on the domains and criteria. The study was assessed to have a low overall risk only if all domains were found to have low risk, and high overall risk if one or more of the six domains were found to be at high risk. A moderate risk assessment was provided to the studies when one or more domains were found to be uncertain, with none at high risk. (Figures 5&6)

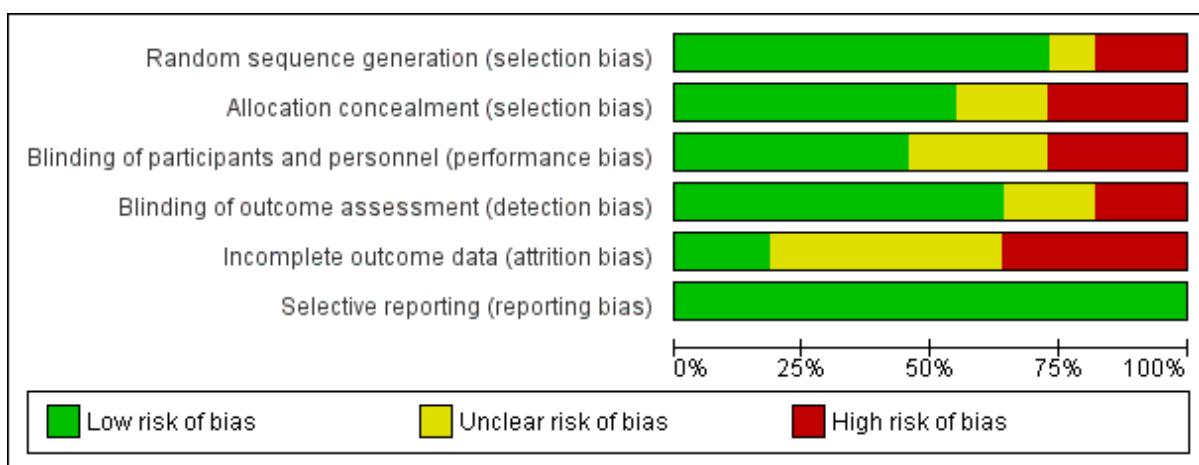


Figure 5: Risk of bias graph: review authors' judgements about each risk of bias item presented as percentages across all included studies.

	Random sequence generation (selection bias)	Allocation concealment (selection bias)	Blinding of participants and personnel (performance bias)	Blinding of outcome assessment (detection bias)	Incomplete outcome data (attrition bias)	Selective reporting (reporting bias)
Asgary et al 2010	+	+	+	+	-	+
B. Eren et al 2018	+	+	+	+	?	+
Bagheri et al 2019	?	?	?	?	-	+
Eghbal et al 2020	+	+	-	+	-	+
Galani et al 2017	+	+	?	+	-	+
Koli et al 2020	+	+	+	+	+	+
Kumar et al 2016	+	+	+	+	?	+
Queidemat et al 2015	-	-	-	-	?	+
Singh et al 2020	-	-	-	-	?	+
Taha et al 2017	+	?	?	?	+	+
Uesrichai et al 2019	+	-	+	+	?	+

Figure 6: Risk of bias summary: review authors' judgements about each risk of bias item for each included study.

## Discussion

Early studies on the effectiveness of vital pulp therapy for the management of

irreversible pulpitis in permanent teeth were limited and unfavourable with respect to many aspects of success. (1-2,11). However, many recent studies of vital pulp therapy of mature permanent teeth with irreversible pulpitis caused by carious pulp exposure have demonstrated a high success rate. The favourable treatment outcomes might be due to a better understanding of pulp biology and advances in material science and the introduction of bioactive material.

The American Association of Endodontists defines both asymptomatic and symptomatic irreversible pulpitis as “a clinical diagnosis based on subjective and objective findings indicating that the vital inflamed pulp is incapable of healing” (8). Clinically, the diagnosis of pulpal disease is based on the patient’s subjective symptoms, objective clinical examination, and radiographic findings and not histological findings. These clinical diagnostic procedures are not reliable. Clinical diagnosis of pulpal disease can only give a provisional diagnosis or educated judgment, which is subject to error because of the lack of correlation between clinical signs and actual histological findings of the pulps. This finding has been substantiated by many clinical studies (12–16). Clinically, a symptom of the pain of an endodontically involved tooth may indicate possible injury to the pulp but cannot be used to predict the extent and severity of the pulp injury, thus a diagnosis of reversible or irreversible pulpitis should be carefully evaluated before deciding on the treatment plan. All the studies included in this review included mature permanent teeth with only irreversible pulpitis, which are traditionally indicated for root canal treatment. Therefore, employing vital pulp therapy in such teeth proves their regenerative potential and agrees with the histological facts that have been established previously. (17)

A large non-inferiority randomized control trial was held by the ICER, comparing the effectiveness of vital pulp therapy against single-visit root canal treatment in relieving pain caused by irreversible pulpitis, and concluded that vital pulp therapy had no significant difference at the regular follow-up periods of post-operative pain evaluation, with the added benefit of preserving the vitality of the teeth. (18) Five of the studies included in this review compared these two treatment modalities and were randomized control trials. (18-22)

The patient demographics of the studies included in the present systematic review varied at large. Although all the studies were performed on mature permanent molars, the age of the patients treated was distributed over a large range. Traditionally, vital pulp therapy procedures have shown to have a successful outcome in immature permanent teeth or primary teeth owing to the presence of more collateral circulation, more repair potential, and a higher degree of reactivity to inflammation and injury. However, this systematic review aimed to establish that the same goals could be achieved in mature permanent teeth using the newer biomaterials. Hence all studies included performed vital pulp therapy on mature permanent molars on patients ages ranging right from 9yrs with an upper limit of up to 79yrs. The age of the patients did not affect the treatment outcome. Another factor determining the inclusion criteria was the method of post-operative pain measurement. The studies evaluated post-operative pain using either the Visual Analog Scale or the Numerical Rating Scale at regular intervals post-treatment. This helped in close monitoring of the patients and helped in determining the effectiveness of the treatment modalities. Long-term success evaluation was based

on specific radiographic criteria and the absence of symptoms. Studies failing to fulfill the above-mentioned standards were thus excluded.

The duration of achieving hemostasis has been suggested as a diagnostic indicator to assess the extent of the inflammation and healing capacity of the radicular pulp tissue (23). Hence it should be one of the most important factors to be considered in the present systematic review to assess the quality of the inclusion criteria of the randomized clinical trials. When bleeding can be controlled with a pressure pack and 2.5% NaOCl within 5-10 minutes, it suggests the presence of mild to moderately inflamed pulp which can heal in a conducive environment as mentioned in the standard protocol by AAPD (2014) and AAE (2018) (6,24).

All the reviewed studies used similar diagnostic criteria for irreversible pulpitis, including prolonged spontaneous or elicited pain. The studies reviewed were able to achieve hemostasis in a time period ranging from 2mins to 10 mins using either a cotton pellet soaked in NaOCl or CHX. Two studies used sterile saline solution and one used distilled water which could have had a derogatory effect on the outcome. However, all studies performed were able to achieve hemostasis in the time frame outlined in the literature, and thus could successfully be indicated for vital pulp therapy.

Three of the total articles selected achieved hemostasis using light pressure with a moist cotton pellet dipped in normal saline. (18,21,25) This is a traditional method that has been used to control bleeding in pulpotomy procedures. Six articles used Sodium hypochlorite as the hemostatic agent. (22,25-29) Five out of these used it at a concentration of 2.5% (22,25-28) while one study used a concentration of 5% NaOCl. (28)

After successfully achieving hemostasis, the next important step in vital pulp therapy is the selection and application of a pulpotomy agent. Materials used in preservative pulpotomy technique produce minimal insult to orifice tissue, thereby maintaining vitality and normal

histological appearance of radicular pulp. The studies included in this systematic review used a range of materials as pulpotomy agents.

All the studies included in this systematic review had a population comprising of vital permanent mature teeth with a pulpal diagnosis of symptomatic irreversible pulpitis. Ten studies used MTA as the pulpotomy agent of choice, either as a comparator to other agents or as a single group. (19,21-22,25-28,30-31) MTA has been suggested as a pulpotomy agent to achieve the desired treatment outcome. The literature indicates that MTA can induce growth factors released from the dentin matrix (32). Taha et al (8) compared MTA with Calcium hydroxide in a randomized control trial and found results favouring MTA in terms of short and long-term prognosis. MTA partial pulpotomy was successful in 85% of the cases, whereas Calcium hydroxide partial pulpotomy was successful in only 43%. These results could be attributed to the better sealing ability, lesser toxic response seen in MTA, and a higher potential for dentin bridge formation which is better in quality than that formed under Calcium hydroxide which has shown to have multiple tunnel defects and sometimes leads to internal resorption due to its high pH. (8)

Another study by Uesrichai et al (32) compared MTA with Biodentine, and found that both results were not statistically different as both the materials are bioactive hydraulic calcium silicate-based cements. Both bioactive cements have similar biological properties for vital pulp therapy, including high biocompatibility, odontogenic effect, low inflammatory response, angiogenesis (24), and antibacterial effects (33). Although both cements share similar biologic effects, they differ in terms of physical properties, such as handling and setting time. However, minor differences in characteristics of the setting, discoloration, and wash-out propensities have not shown to affect the results in this non-inferiority randomized control trial and proved that Biodentine can be successfully used as an alternative to MTA as a pulpotomy agent. (25)

Two other studies compared the routinely used Calcium hydroxide and MTA with PRF membrane as a pulpotomy material. (26,31) PRF was used considering the advantages of biocompatibility and bioactivity. Huang *et al.* reported that PRF exerted no cytotoxic effect on dental pulp stem cells and each cell maintained its original morphology (34,38). PRF also actively participates in pulpal healing by the release of growth factors such as PDGF and Transforming growth factor beta which plays an important role in the proliferation and differentiation of stem cells. (35) Both studies showed non-significant differences between the three materials when used as pulpotomy agents in terms of post-operative pain and long-term success. Previous studies have reported a superior dentin bridge quality and more predictable results with MTA than with Calcium hydroxide. (36-37) The explanation may be provided on the basis that the clinical and radiographic parameters may not provide information about the histological criteria. The quality of bridge formation may not have a direct correlation with clinical success. A histological study may better explain the influence of these three pulpotomy agents on pulpal healing.

Bagheri et al (39) in their randomized clinical trial used Dexamethasone as a pulpotomy agent primarily to relieve pain symptoms. Dexamethasone is a steroidal anti-inflammatory drug that inhibits phospholipase A2 and consequently reduces the amount of chemical mediators, decreasing the polymorphonuclear leukocyte chemotaxis (40). However, it has been shown that the administration of Dexamethasone leads to partial inhibition of the development of the inflammatory periapical lesion. The study population was followed up over one week to assess the post operative outcome. There were no significant differences found between the two, however, long-term follow-up is needed to validate dexamethasone as a pulpotomy agent. (40)

Asgary et al (28) in their large multi-centered randomized clinical trial, introduced Calcium enriched mixture (CEM) as a pulpotomy agent and found it to be non-inferior to MTA. Both CEM and MTA showed similar results in terms of dentin bridge formation and were superior to that of Calcium hydroxide. Moreover, CEM has similar biocompatibility as MTA and thus can be used as an alternative to the same. The post-operative pain using CEM was significantly lower when compared with single-visit root canal treatment in patients with symptomatic irreversible pulpitis which also authenticates the use of this procedure for the treatment of such cases. (28)

Post-operative pain was measured over for one week at regular intervals 6-8hrs and the results of all the thirteen studies showed that partial or full pulpotomy was able to achieve better pain relief as compared to routine non-surgical endodontic therapy. This can be attributed to the invasiveness of the root canal treatment which includes the use of rotary instruments leading to extrusion of apical debris, use of strong irrigants which can cause periapical irritation, insulting the periapical constriction leading to overpreparation and excessive loss of tooth material, etc. The long-term success rates were also in favour of vital pulp therapy, as periods of up to 10 years were followed-up. The vitality of the teeth was maintained, along with remission of pain, periapical pathology, and radiographic signs of inflammation, and showed overall improvement in the health of the teeth. Thus, both short and long-term assessments proved the success of vital pulp therapy as a less invasive and conservative treatment option.

We conducted a meta-analysis for the eligible studies which accounted for studies in which the data outcome was analyzed quantitatively. We extracted the outcome based on the VAS score as the pain parameter. The heterogeneity was higher hence we applied the random effect model

and the cumulative mean difference was derived. The mean difference showed that the VAS score was higher in the Root canal group than in the pulpotomy group after 24 and 48hrs. This showed that vital pulp therapy can effectively reduce post-operative pain in symptomatic irreversible pulpitis. Although all the studies included in this review are randomized controlled trials, clinical trials, or retrospective studies, differences in their study design, preoperative pulpal and periapical condition, treatment protocol followed and the duration after treatment episode when pain experience was recorded makes comparison between these studies complicated.

### **Limitations**

The variability among the studies concerning the method of achieving hemostasis, and the use of different pulpotomy agents. Another limitation is that pain is a subjective symptom and it is difficult to decide whether single or multiple factors cause this pain. The presence of several confounding factors in the studies makes it difficult to attribute pain to only one factor.

### **Future Studies**

Although vital pulp therapy has been found to be effective in relieving postoperative pain, its effect on the physiological healing process of the inflamed pulp and the duration required for complete healing to occur needs to be further evaluated. Postoperative pain is multifactorial and thus it is difficult to attribute pain to only one of the factors. Thus, the importance of standardizing variables is to be taken into consideration in future studies to eliminate potential confounding factors and allow the analysis of these factors individually in postoperative pain levels. Also, no standardization regarding the materials, duration of achieving hemostasis, and method of evaluating post-operative have been stated. Thus, further studies to identify an ideal protocol for performing vital pulp therapy in teeth with symptomatic irreversible pulpitis.

## Conclusion

At the end of this systematic review, we can conclude that, mature teeth with symptomatic irreversible pulpitis can be successfully treated with partial or complete pulpotomy. With the use of correct diagnostic methods, meticulously followed treatment protocol, and the application of newer biomaterials it is possible to preserve the vitality of the tooth and maintain its natural state with the additional benefit of reducing treatment time, post-operative pain, and overall armamentarium. Thus, a partial or complete pulpotomy is a highly effective alternative to routine non-surgical endodontics and can help bring about a paradigm shift in the specialty in the coming future.

## Acknowledgement:

Dr. Nikhil Bhanushali For Performing The Statistics Of The Study.

1. Competing interests None

2. Funding statement

No funding was received.

3. Author's contributions

All authors have contributed significantly, and all authors are in agreement with the manuscript.

Name	Concept and design	Acquisition of data or analysis	Interpretation of data	Drafting the article	Final approval
Dr Vibha Hegde	✓	✓			✓
Dr Mrunalini Vaidya	✓	✓		✓	✓
Dr Surelee Chavan	✓	✓	✓	✓	
Dr Simren Bhatia	✓	✓	✓	✓	

**Acknowledgements (if any):**

We would like to acknowledge Dr Nikhil Bhanushali for performing the statistical analysis and the formulation of the meta-analysis for this review.

4. ORCID link of the corresponding author:

Dr Surelee Chavan:

<https://orcid.org/0000-0002-2405-9926>

Dr. Simren Bhatia:

<https://orcid.org/0000-0002-4181-2115>

**References**

1. Huang GT. Pulp and dentin tissue engineering and regeneration: Current progress. *Regen Med* 2009;4:697-707.
2. Schwendicke F, Stolpe M. Direct pulp capping after a carious exposure versus root canal treatment: a cost-effectiveness analysis. *J Endod* 2014;40:1764-70.
3. Aguilar P, Linsuwanont P. Vital pulp therapy in vital permanent teeth with cariously exposed pulp: a systematic review. *J Endod* 2011;37:581-7.
4. Goodis, and Samuel Seltzer. *Seltzer and Bender's Dental Pulp*. Chicago: Quintessence Pub. Co, 2002.
5. WEINE, F. S. (2004). *Endodontic therapy*. St. Louis, Mo, Mosby.
6. Zanini M, Hennequin M, Cousson PY. A review of criteria for the evaluation of pulpotomy outcomes in mature permanent teeth. *J Endod* 2016;42:1167-74.
7. MARWAH, N. (2014). *Textbook of pediatric dentistry*.
8. Taha NA, Ahmad MB, Ghanim A. Assessment of mineral trioxide aggregate pulpotomy in mature permanent teeth with carious exposures. *Int Endod J* 2017;50: 117-25.
9. Seltzer S, Bender IB, Ziontz M. The dynamics of pulp inflammation: correlations between diagnostic data and actual histologic findings in the pulp. *Oral Surg Oral Med Oral Pathol* 1963;16:846-71.
10. American Academy of Pediatric Dentistry. Guidelines on pulp therapy for primary and immature permanent teeth.
11. H. F. Duncan, K. M. Galler, P. L. Tomson et al., "European Society of Endodontology position statement: management of deep caries and the exposed pulp," *International Endodontic Journal*, vol. 52, no. 7, pp. 923-934, 2019.
12. Huang FM, Yang SF, Zhao JH, Chang YC. Platelet-rich fibrin increases proliferation and differentiation of human dental pulp cells. *J Endod* 2010;36:1628-32.
13. Dohan DM, Choukroun J, Diss A, Dohan SL, Dohan AJ, Mouhyi J, et al. Platelet-rich fibrin (PRF): A second-generation platelet concentrate. Part II: Platelet-related biologic features. *Oral Surg Oral Med Oral Pathol Oral Radiol Endod* 2006;101:e45-50.
14. A comparative study of histologic response to different pulp capping materials and a novel endodontic cement. *Oral Surg Oral Med Oral Pathol Oral Radiol Endod* 2008; 106:609-14.

15. Nair PN, Duncan HF, Pitt Ford TR, Luder HU. Histological, ultrastructural and quantitative investigations on the response of healthy human pulps to experimental capping with mineral trioxide aggregate: A randomized controlled trial. *Int Endod J* 2008;41:128-50.
16. Czock D, Keller F, Rasche FM, et al. Pharmacokinetics and pharmacodynamics of systemically administered glucocorticoids. *Clin Pharmacokinet* 2005;44:61-98.
17. Barnkgkei IH, Halboub ES, Alboni RS. Pulpotomy of symptomatic permanent teeth with carious exposure using mineral trioxide aggregate. *Iran Endod J* 2013;8:65-8.
18. Simon S, Perard M, Zanini M, et al. Should pulp chamber pulpotomy be seen as a permanent treatment? Some preliminary thoughts. *Int Endod J* 2013;46:79-87.
19. Bjørndal L (2008) The caries process and its effect on the pulp: the science is changing and so is our understanding. *Pediatric Dentistry* 30, 192-6.
20. Ward J. Vital pulp therapy in cariously exposed permanent teeth and its limitations. *Aust Endod J* 2002; 28: 29-37.
21. Lin LM, Ricucci D, Saoud TM, Sigurdsson A, Kahler B. Vital pulp therapy of mature permanent teeth with irreversible pulpitis from the perspective of pulp biology. *Aust Endod J*. 2020 Apr;46(1):154-166.
22. Ricucci D, Loghin S, Siqueira JF Jr. Correlation between clinical and histologic pulp diagnoses. *J Endod* 2014;40:1932-9
23. Camp J. Pediatric endodontics: Endodontic treatment for the primary and young permanent dentition. In: Cohen S, Burns RC (Eds). *Pathways of the pulp*. 8th Edn. St Louis, Mo: Mosby Year Book, Inc; 2002.
24. Chueh LH, Chiang CP (2010) Histology of Irreversible pulpitis premolars treated with mineral trioxide aggregate pulpotomy. *Operative Dentistry* 35, 370-4.
25. Kumar V, Juneja R, Duhan J, Sangwan P, Tewari S. Comparative evaluation of platelet- rich fibrin, mineral trioxide aggregate, and calcium hydroxide as pulpotomy agents in permanent molars with irreversible pulpitis: A randomized controlled trial. *Contemp Clin Dent* 2016;7:512-8.
26. American Association of Endodontists, Glossary of Endodontic Terms, Tenth Ed., Chicago, IL. Available online: <https://www.aae.org/specialty/clinicalresources/glossary-endodontic-terms/> (accessed on 13 March 2020).
27. Elmsmari, F.; Ruiz, X.-F.; Miró, Q.; Feijoo-Pato, N.; Durán-Sindreu, F.; Olivieri, J.G. Outcome of Partial Pulpotomy in Cariously Exposed Posterior Permanent Teeth: A Systematic Review and Meta-analysis. *J. Endod.* 2019, 45, 1296-1306. [CrossRef]
28. Asgary S, Eghbal MJ. The effect of pulpotomy using a calcium-enriched mixture cement versus one-visit root canal therapy on postoperative pain relief in irreversible pulpitis: a randomized clinical trial. *Odontology*. 2010 Jul;98(2):126-33. doi: 10.1007/s10266-010- 0127-2. Epub 2010 Jul 23. PMID: 20652790.
29. Redig DF. A comparison and evaluation of two formocresol pulpotomy techniques utilizing "Buckley's" formocresol. *ASDC Journal of Dentistry for Children*. 1968; 35: 22-30.
30. Li, Y.; Sui, B.; Dahl, C.; Bergeron, B.; Shipman, P.; Niu, L.; Chen, J.; Tay, F.R. Pulpotomy for carious pulp exposures in permanent teeth: A systematic

- review and meta-analysis. *J. Dent.* 2019, 84, 1–8. [CrossRef]
31. Alqaderi, H.; Lee, C.-T.; Borzangy, S.; Pagonis, T.C. Coronal pulpotomy for cariously exposed permanent posterior teeth with closed apices: A systematic review and meta- analysis. *J. Dent.* 2016, 44, 1–7. [CrossRef]
  32. Uesrichai N, Nirunsittirat A, Chuveera P, Srisuwan T, Sastraruji T, Chompu-Inwai P. Partial pulpotomy with two bioactive cements in permanent teeth of 6- to 18-year-old patients with signs and symptoms indicative of irreversible pulpitis: a noninferiority randomized controlled trial. *Int Endod J.* 2019 Jun;52(6):749-759. doi: 10.1111/iej.13071. Epub 2019 Jan 30. PMID: 30638262
  33. Bortoluzzi EA, Broon NJ, Bramante CM, Consolaro A, Garcia RB de Moraes IG, *et al* Mineral trioxide aggregate with or without calcium chloride in pulpotomy. *J Endod* 2008;34:172-5.
  34. M. Galani, S. Tewari, P. Sangwan, S. Mittal, V. Kumar, and J. Duhan, “Comparative evaluation of postoperative pain and success rate after pulpotomy and root canal treatment in cariously exposed mature permanent molars: a randomized controlled trial,” *Journal of Endodontics*, vol. 43, no. 12, pp. 1953–1962, 2017.
  35. J. G. Pak and S. N. White, “Pain prevalence and severity before, during, and after root canal treatment: a systematic review,” *Journal of Endodontics*, vol. 37, no. 4, pp. 429–438, 2011.
  36. Grewal N, Salhan R, Kaur N, Patel HB. Comparative evaluation of calcium silicate-based dentin substitute (Biodentine<sup>®</sup>) and calcium hydroxide (pulpdent) in the formation of reactive dentin bridge in regenerative pulpotomy of vital primary teeth: Triple blind, randomized clinical trial. *Contemp Clin Dent.* 2016 Oct-Dec;7(4):457-463. doi: 10.4103/0976-237X.194116. PMID: 27994411; PMCID: PMC5141658.
  37. Camp J. Pediatric endodontics: Endodontic treatment for the primary and young permanent dentition. In: Cohen S, Burns RC (Eds). *Pathways of the pulp*. 8th Edn. St Louis, Mo: Mosby Year Book, Inc; 2002.
  38. Huang FM, Yang SF, Zhao JH, Chang YC. Platelet-rich fibrin increases proliferation and differentiation of human dental pulp cells. *J Endod* 2010;36:1628-32.
  39. Bagheri M, Khimani H, Pishbin L, Shahabinejad H. Effect of Pulpotomy Procedures With Mineral Trioxide Aggregate and Dexamethasone on Post-endodontic Pain in Patients with Irreversible Pulpitis: A Randomized Clinical Trial. *Eur Endod J.* 2019 Jun 20;4(2):69-74.
  40. Finn SB: *Biology of the dental pulp organ: a symposium*, University of Alabama, 1968, University of Alabama Press.
  41. Eren B, Onay EO, Ungor M. Assessment of alternative emergency treatments for symptomatic irreversible pulpitis: a randomized clinical trial. *Int Endod J.* 2018 Apr;51 Suppl 3:e227-e237.
  42. Eghbal MJ, Haeri A, Shahravan A, et al S. Postendodontic Pain after Pulpotomy or Root Canal Treatment in Mature Teeth with Carious Pulp Exposure: A Multicenter Randomized Controlled Trial. *Pain Res Manag.* 2020 Jun 30;2020:5853412.
  43. Kohli B, Chawla A, Logani A, Kumar V, Sharma S. Combination of Nonsurgical Endodontic and Vital Pulp Therapy for Management of Mature Permanent Mandibular Molar Teeth with Symptomatic Irreversible Pulpitis and Apical Periodontitis. *J*

- Endod. 2021 Mar;47(3):374-381.
44. Qudeimat MA, Alyahya A, Hasan AA. Mineral trioxide aggregate pulpotomy for permanent molars with clinical signs indicative of irreversible pulpitis: a preliminary study. *Int Endod J.* 2017 Feb;50(2):126-134.
  45. Singh R, Singh R, Kavita K, Kommula A, Kulkarni G, Jois HS. To Compare Mineral Trioxide Aggregate, Platelet-rich Fibrin, and Calcium Hydroxide in Teeth with Irreversible Pulpitis: A Clinical Study. *J Pharm Bioallied Sci.* 2020 Aug;12(Suppl 1):S436-S439.
  46. Kunert GG, Kunert IR, da Costa Filho LC, de Figueiredo JAP. Permanent teeth pulpotomy survival analysis: retrospective follow-up. *J Dent.* 2015 Sep;43(9):1125-1131.
  47. Linsuwanont P, Wimonsutthikul K, Pothimoke U, Santiwong B. Treatment Outcomes of Mineral Trioxide Aggregate Pulpotomy in Vital Permanent Teeth with Carious Pulp Exposure: The Retrospective Study. *J Endod.* 2017 Feb;43(2):225-230.
  48. Suryasa, I. W., Rodríguez-Gámez, M., & Koldoris, T. (2021). Get vaccinated when it is your turn and follow the local guidelines. *International Journal of Health Sciences*, 5(3), x-xv. <https://doi.org/10.53730/ijhs.v5n3.2938>