

How to Cite:

Margaret, A. P. ., Kumar S, R. E. ., & Ravanagomagan, R. (2022). Natal and neonatal teeth a case series - from south India. *International Journal of Health Sciences*, 6(S7), 2804–2810.
<https://doi.org/10.53730/ijhs.v6nS7.12126>

Natal and neonatal teeth a case series - from south India

Dr. A Priya Margaret

Assistant Professor, Department of Paediatrics, SreeBalaji Medical College and Hospital, Chrompet, Chennai-600044

Ramitha Enakshi Kumar S

Prefinal MBBS Government medical college Omandurar estate

Dr. Ravanagomagan*

Assistant Professor, Department of Paediatrics, SreeBalaji Medical College and Hospital, Chrompet, Chennai-600044

*Corresponding Author email: drmgr04@gmail.com

Abstract--Teeth eruption into the oral cavity follows a chronology. Small variations depending on endocrine, genetic and environmental factors can alter the chronology of teeth eruption. The occurrence of teeth at birth is called natal teeth and when teeth arise within 30 days of birth it is called neonatal teeth. The occurrence of natal and neonatal teeth is an uncommon anomaly. It is associated with a lot of superstition in various ethnic group. If the natal and neonatal teeth do not interfere with feeding nor are they causing any ulceration they can be left in place. Some natal and neonatal teeth cause injury to the mother on feeding and can cause tongue ulceration in the neonate. In such cases the teeth can be removed. If the natal and neonatal teeth are extremely mobile such that reattachment is unlikely and there is a danger of aspiration of the tooth, then they can be removed. We describe in this report 4 neonates with natal and neonatal teeth.

Keywords---Natal Teeth, Neonatal Teeth, Superstition, Feeding Difficulty.

Introduction

The first tooth, which erupts in an infant is usually the mandibular incisor . .The teeth which erupt prematurely are called as fetal teeth or congenital teeth or predeciduous teeth or dentitia praecox. natal and neonatal tooth termed by Massler and Savara. At the time of birth any teeth which are present they are called natal teeth. Any teeth which appear within 30 days of delivery called as

neonatal teeth. Compare to neonatal teeth, Natal teeth are 3 times common. The incidence of natal and neonatal teeth is 1:2000 to 1: 3500 and the prevalence is 1: 700 to 1:30000. Among different races there is a great variation of the incidence of natal and neonatal teeth. The female male preponderance varies with different studies but some studies reported Male preponderance, some told no difference and some with a female preponderance. The normal eruption of first teeth is viewed by parents with great excitement but the premature eruption of teeth is viewed with superstitions and misconceptions. The eruption of neonatal and natal teeth is uncommon. It is associated for ages with different superstitions among various ethnic groups. A large number of neonatal and natal teeth are normal primary teeth that erupted early. The remaining teeth are supernumerary about 10% of the total. The eruption of neonatal and natal teeth can be isolated or can be associated with a syndrome. Complications of neonatal and natal teeth include aspiration of tooth if mobile, ulceration of the feeding mother's breasts, sublingual aspiration, discomfort during suckling and trauma or irritation to the tongue. It is rare for premature babies to have natal and neonatal teeth. Cleft palate and cleft lip is associated with natal and neonatal teeth. 10% of bilateral cleft palate cases associated with Neonatal and natal teeth. Natal teeth are associated with 2% of unilateral cleft palate cases.

Cleft palate and lip are associated with a numerous syndromes like Beckel Gruber syndrome and Pierre Robin sequence in which natal teeth are reported.

The syndromes associated with natal teeth are the following: Ellis van crevald syndrome, HallermanStreiff syndrome.

Maternal factors which are associated with Neonatal and natal teeth are infections or trauma in the mother, febrile states, malnutrition especially hypovitaminosis and maternal exposure to polychlorinated biphenyls.

Cases:

Case 1: A term boy baby born by lower segment caesarean section out of non consanguineous marriage. Routine examination at the time of birth found that 2 natal teeth (figure 1) in the lower jaw (lower incisors), dental opinion obtained and confirmed that it was natal teeth. Antenatal history was insignificant. There was no problem while feeding. So we have sent the baby without intervention. On follow up baby was sucking and feeding well.

Case 2: A term girl baby born by normal vaginal delivery out of non consanguineous marriage. Routine examination after birth found that 2 natal teeth (figure 2) in the lower jaw (lower incisors), dental opinion obtained for natal teeth. No problem with feeding and attachment nil intervention done. Follow up visit showed good weight gain.

Case 3: A 40 weeks term boy baby delivered by normal vaginal delivery. Routine examination after birth revealed natal teeth (figure 3) in the lower jaw (lower incisors). In the post natal period the baby has difficulty in feeding and it was causing injury to the mother. We obtained dental opinion for teeth removal.

Teeth removal was planned. Inj vitamin k was given prior to the procedure. Under local anaesthesia teeth was extracted. Following tooth extraction baby was able to sucking and feeding well. Significant weight gain was noted on further follow up

Case 4: A 7 day old boy baby refereed with the history swelling in the lower jaw (figure 4) (Right lower incisors) noted 5 days after birth. Antenatal history was obtained uneventful. On examination and imaging revealed it's a tooth. Immediate dental opinion was obtained. It's not interfering with feeding no intervention has taken. On further follow up baby had good weight gain.

Discussion

There is a chronology for tooth eruption..(1) This chronology is well known and is there are small variations depending on hereditary, environmental and endocrine factors. Although permanent teeth eruption depends on genetics of the individual. Several general factors such as socio and economic status gender, body composition and craniofacial morphology can influence this process(2). At times this chronology may be altered and the 1st teeth may erupt at birth or within 30 days after birth.(3)

Congenital tooth, predecidual tooth, fetal tooth, and dentitia praecox is the name given to teeth that erupt ahead of time(4). According to Massler and Savara they are called as natal and neonatal teeth(5).Teeth which erupt or present at birth are called natal teeth and those that erupt within 30 days are called as neonatal teeth(6). Deciduous mandibular incisors represent 85% of the natal and neonatal teeth that erupt.. (7) . The rest are supernumerary. (8)

Systemic diseases and syndromes. Cause important disturbances in teeth eruption. (9) The syndromes that have been associated with natal teeth: (a) are Ellis-van Creveld syndrome or chondroectodermal dysplasia, (b) Hallermann-Streiff syndrome,oculo-mandibulo-dyscephaly with hypotrichosis or and ©Jadassohn-Lewandowski syndrome. Or pachyonychiacongenita .,rickets, and hypocalcemia with fracture of the ribs, and adrenogenital syndrome with 18-hydroxylase deficiency.(10)

There are certain maternal factors which are associated with an increased risk of natal teeth(11) When mothers were exposed to high levels of polychlorinated biphenyls and dibenzofurans their babies were found to have a 10% risk of natal teeth. Infection and febrile states in the mother are associated with natal and neonatal teeth.(10)

The neonatal and natal teeth cause a lot of difficulties to the mother and the neonate, such as pain on suckling and refusal to feed. The complications of neonatal or natal teeth are tooth aspiration if the tooth is mobile and loose, ulceration of the tongue of the neonate , and a difficulty with feeding. Ulceration to the mother's nipple can cause pain during breast feeding and premature cessation of lactation..

Neonatal and natal teeth are associated with superstitions for a long time.. Titus Livius, in 59 B.C., said that natal teeth were a prediction of disastrous events.

Caius Plinius Secundus (the Elder), in 23 B.C., believed male infants with natal teeth had a splendid future whereas he considered the presence of natal and neonatal teeth as bad omen in girls.. Superstition regarding natal and neonatal teeth existed in India, Poland and Africa. and in African folk such of those children born with natal and neonatal teeth were killed because they were supposed to bring misfortune.. In China, children with natal teeth consider as bad omen In England, it was considered that babies born with teeth would grow up to be come famous soldiers. France and Italy considered the children born with natal and neonatal teeth would in the future conquer the world. Deprivation of parental love to the child was seen in some superstitious families.. So many of the families want the natal and neonatal teeth to be removed as soon as possible

In 70% of the cases natal and/or neonatal teeth are firmly fixed . But in a small number of them they later become loose

Histological investigation has revealed a failure of root formation , a failure of cementum formation, irregular formation of dentin and a large vascular pulp despite eruption.

If the natal and neonatal teeth are mobile they cannot be maintained in the oral cavity. Also problems with suckling, traumatic injury to the mother or the tongue of the neonate necessitates the removal of the natal and neonatal teeth. . As natal or neonatal teeth can cause difficulties in feeding, ulceration of the nipple, ulceration of the tongue of the neonate and can become loose when they can be aspirated, extraction is the preferred treatment It is enough if a topical anaesthetic cream is applied before extraction of the natal and neonatal teeth as they have poor root development.. Vitamin K levels should be performed or prophylactic vitamin K injection should be given before the tooth is extracted in a neonate under the age of 10 days.

It is recommended that natal and neonatal teeth be left in place, if possible, and removed only if they cause difficulties in feeding, ulceration of the mother's nipple, ulceration of the neonate's tongue, become loose such that they can be aspirated or reattachment is not possible.

References To Be Filled

1. Cunha RF, Boer FA, Torriani DD, Frossard WT. Natal and neonatal teeth: review of the literature. *Pediatric dentistry*. 2001 Dec 1;23(2):158-62.
2. Almonaitiene R, Balciuniene I, Tutkuvienė J. Factors influencing permanent teeth eruption. Part one—general factors. *Stomatologija*. 2010 Sep;12(3):67-72.
3. Kamboj M, Chougule R. Neonatal Tooth—How Dangerous Can it Be?. *Journal of Clinical Pediatric Dentistry*. 2009 Sep 1;34(1):59-60.
4. Aboulouidad S, Aziz Z, El Bouihi M, Fawzi S, Abouchadi A, Hattab NM. Natal teeth: report of two cases. *Pan African Medical Journal*. 2020 Aug 20;36(1).
5. Massler M, Savara BS. Natal and neonatal teeth: a review of twenty-four cases reported in the literature. *The Journal of pediatrics*. 1950 Mar 1;36(3):349-59.

6. Khandelwal V, Nayak UA, Nayak PA, Bafna Y. Management of an infant having natal teeth. Case reports. 2013 Jun 1;2013:bcr2013010049.
7. Bodenhoff J, Gorlin RJ. Natal and neonatal teeth: folklore and fact. *Pediatrics*. 1963 Dec;32(6):1087-93.
8. Anthonappa RP, Omer RS, King NM. Characteristics of 283 supernumerary teeth in southern Chinese children. *Oral Surgery, Oral Medicine, Oral Pathology, Oral Radiology, and Endodontology*. 2008 Jun 1;105(6):e48-54.
9. Peedikayil FC. DELAYED TOOTH ERUPTION. *e-Journal of Dentistry*. 2011 Oct 1;1(4).
10. Leung AK. Natal teeth. *American Journal of Diseases of Children*. 1986 Mar 1;140(3):249-51.
11. Rao RS, Mathad SV. Natal teeth: Case report and review of literature. *Journal of oral and maxillofacial pathology: JOMFP*. 2009 Jan;13(1):41.
12. Suryasa, I. W., Rodríguez-Gámez, M., & Koldoris, T. (2022). Post-pandemic health and its sustainability: Educational situation. *International Journal of Health Sciences*, 6(1), i-v. <https://doi.org/10.53730/ijhs.v6n1.5949>

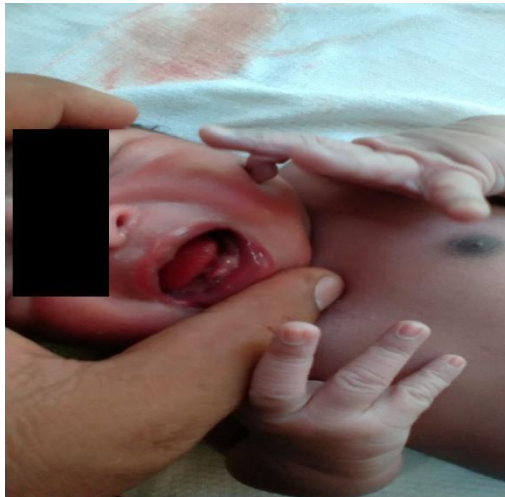

Figure: 1

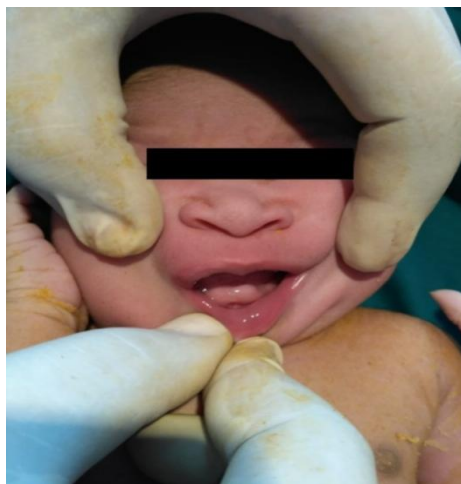

Figure: 2

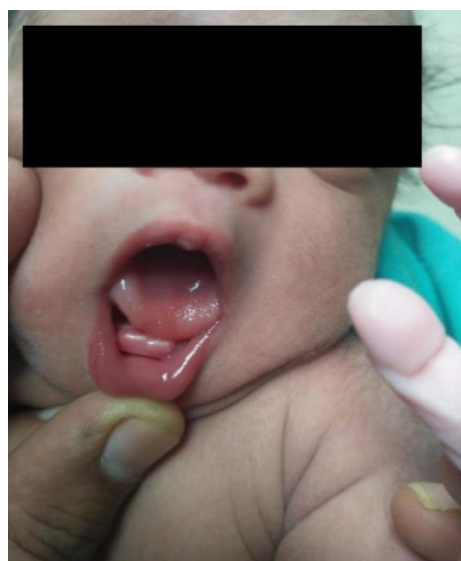

Figure :3

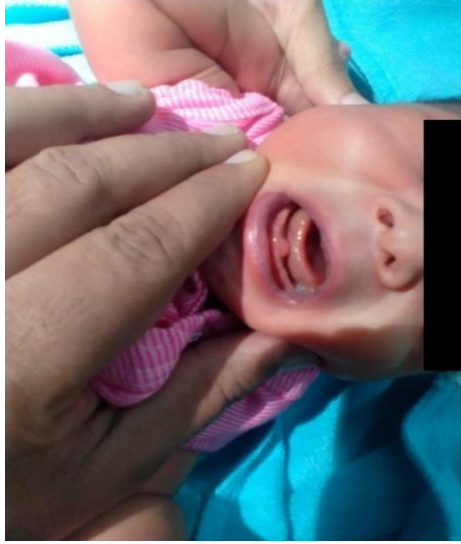


Figure: 4