

How to Cite:

Singh, R., Sawhny, A., Hora, B. S., Rashid, S., Ghosh, D., & Khanna, A. (2022). Impact of laser disinfection and passive ultrasonic irrigation on postoperative pain in single visit root canal therapy. *International Journal of Health Sciences*, 6(S6), 8445–8455.
<https://doi.org/10.53730/ijhs.v6nS6.12136>

Impact of laser disinfection and passive ultrasonic irrigation on postoperative pain in single visit root canal therapy

Richa Singh

Reader, Dept of Conservative Dentistry and Endodontics, Rama Dental College Hospital and Research Centre, Kanpur, India
Email: richasingh.2804@gmail.com

Asheesh Sawhny

Prof and HOD Dept of Conservative Dentistry and Endodontics, Rama Dental College Hospital and Research Centre, Kanpur, India
Email: drasheeshmydentist@gmail.com

Baljeet Singh Hora

Prof, Dept of Conservative Dentistry and Endodontics, Rama Dental College Hospital and Research Centre, Kanpur, India
Email: drbaljeet69@yahoo.com

Sheeban Rashid

Post Graduate Student, Dept of Conservative Dentistry and Endodontics, Rama Dental College Hospital and Research Centre, Kanpur, India
*Corresponding author email: sheebanrashid13@gmail.com

Debasmita Ghosh

Post Graduate Student, Dept of Conservative Dentistry and Endodontics, Rama Dental College Hospital and Research Centre, Kanpur, India
Email: debasmita2495ghosh@gmail.com

Ayushi Khanna

Post Graduate Student, Dept of Conservative Dentistry and Endodontics, Rama Dental College Hospital and Research Centre, Kanpur, India
Email: khannaayushi3981@gmail.com

Abstract--Introduction: Postoperative endodontic pain is common. 3 to 58% of patients had post-op pain. Canal microbes are tough to eliminate. No irrigant meets all the perfect irrigant characteristics. Methods: In Kanpur, India, 46 participants were enrolled in this randomised clinical trial from January to June 2022. Department of Conservative Dentistry and Endodontics conducted the study. Local

anaesthetic (1:2,000 lignocaine with adrenaline) was followed by rubber dam isolation and access cavity preparation. Teeth were cleaned and shaped. Patients were divided into two groups using a coin flip. Group A employed a 2 W 810 nm diode laser for laser disinfection. In Group B, sodium hypochlorite (NaOCl) was ultrasonically agitated. After a final treatment with saline, composite resin was used for obturation and post-endodontic restoration. A blinded assessor rated post-endodontic treatment after 6 hours, 24 hours, 48 hours, and 7 days. SPSS 20.0 was used to gather and analyse the data after utilising Pearson's Chi-square test with 5% significance. Results: 25 men and 19 women among 44 patients. 10 patients were 40-60, 28 were 30-40, and 12 were 18-29. No statistically significant difference was seen between PUI and laser disinfection in single visit root canal therapy ($p=0.086$). Conclusion: PUI and laser disinfection both reduce postoperative pain and suffering after a single root canal treatment. Early on, PUI is better than laser disinfection.

Keywords--PUI, disinfection, lasers, root canal therapy.

Introduction

Following endodontic treatment, postoperative discomfort is a frequent yet unwelcome symptom. Postoperative pain might occur anywhere from 3% to 58% of cases. Injury to the pulp or peri-radicular tissues caused by mechanical, chemical, or microbiological forces may contribute to discomfort after root canal therapy [1]. Because of various reasons, complete removal of the bacterial biofilm from the canals is particularly challenging [2]. The current available irrigants do not fulfill the criteria of an ideal irrigant [3]. In this instance, bacterial biofilm can be reduced or eliminated with the use of various disinfection devices. In 1980, Weller RN et al., gave the first description of passive ultrasonic irrigation (PUI). The ultrasonically actuated file's "non cutting" action was described as "passive." An oscillating file or smooth wire connected to an irrigant transmits acoustic energy right into the root canal to perform passive ultrasonic irrigation. The energy is carried by ultrasonic waves, which can lead to acoustic streaming and irrigant cavitation [4, 5].

To remove bacterial biofilms from accessible and inaccessible parts of canals and lateral canals, low intensity lasers are advised. This has been made possible by the development of a fibre delivery system [6]. In endodontics, the first deployment of laser was performed in 1971 by Weichman JA and Johnson FM [7]. A bactericidal impact of laser light directed into the root canal has been proven. The laser's ability to only shoot light in a straight path is its main drawback. The photo sensitizer is therefore being utilized in conjunction with the irrigant to the full extent of its effectiveness. Consequently, that light can likewise go through the lateral canals [8]. A laser's antibacterial action is based on thermal characteristics of laser tissue interaction [9]. A high power diode laser has been successfully used in dentinal disinfection. The diode laser has shown to be a useful tool [10, 11].

Debris removal and antibacterial efficiency has therefore been the subject of several in vitro and ex vivo research [12–18]. For evaluating PUI and laser disinfection during root canal irrigation, there is minimal known evidence for postoperative discomfort in a single visit endodontic therapy. Therefore, the null hypothesis used in the design of this study was that there was no difference between postoperative pain or discomfort or both during root canal treatment.

Materials and Methods

This randomized clinical research was performed for six months, from January 2022 to June 2022, in the Rama Dental College Hospital and Research Centre's Department of Conservative Dentistry and Endodontics in Kanpur, India. The Institutional Ethics Committee approved the study's protocol.

Sample size calculation

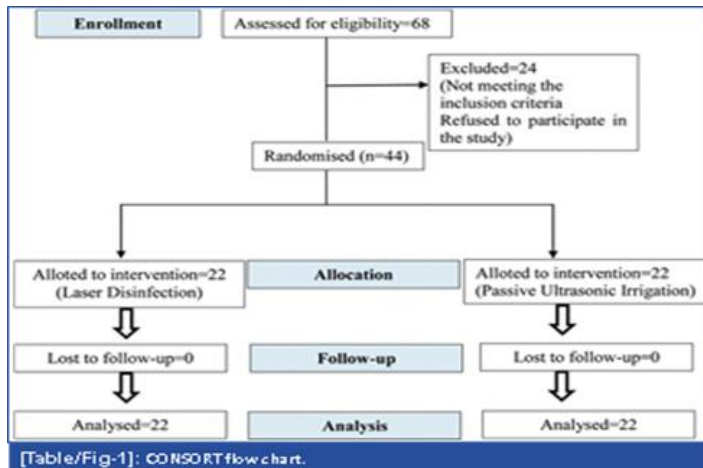
Using this formula, a minimum sample size of 34 (17 each group) with a 95% Confidence Interval (CI) and 80% power was needed.

$$n=2 \times (Z_{\alpha/2} + Z_{1-\beta})^2 / (M_1 - M_2 / \sigma)^2$$

The total sample size for each group was 22 patients since an additional five samples (20%) were added to make up for the dropout. For the study, a total of 44 individuals who needed at least one root canal treatment on single rooted non-vital teeth were taken into account.

Inclusion and Exclusion criteria

Patients between the ages of 18 and 60 who had single canals with completely developed apexes (Vertucci's type 1), non vital teeth that had undergone electric pulp testing or heat stimulation prior to anesthesia and were willing to sign the consent form were included in the study. Patients who could not have their teeth restored, had compromised periodontal health, acute apical abscesses, calcified canals, canals with resorption, pregnant or lactating women, had systemic conditions like hypertension or diabetes, were allergic to antibiotics, corticosteroids, or any inflammatory drugs, or had recently taken analgesics or anti-inflammatory medications were excluded from the study.



Study Procedure

Local infiltration anesthesia was administered to the maxillary teeth, and inferior alveolar nerve block anesthesia was administered to the mandibular teeth using a 1:200000 Lignocaine with adrenaline (nirlife). Endo access and Endo Z burs were used to design the access cavity after rubber dam isolation. In the event of deep proximal caries involvement, the caries excavation and access opening was done, and then the implicated proximal wall was built up using nanohybrid composite (GC Solare X). With the use of an apex finder (Root ZX mini, J. Morita), the working length was determined using a #10 K-file (Mani). Next, depending on the configuration of the canal, Chemo Mechanical Preparation (CMP) was performed using the step-back, crown-down, or hybrid methods. 5.25% sodium hypochlorite, 0.2% chlorhexidine gluconate, and 0.9% normal saline were utilized as irrigants throughout preparation. To prevent a reaction, sodium hypochlorite and chlorhexidine were not utilized in the conjugation [19]. Then, using the flip coin procedure, the patients were split into the two groups at random.

Group A (n=22)-Laser Disinfection (Photo activated Disinfection)

A methylene blue dye solution (50 g/mL) was prepared after CMP by combining the dye with 20 mL of saline. When dye is employed in photo activated disinfection, singlet oxygen is released, which damages bacterial membrane and DNA [20]. Therefore, the dye was injected into the coronal portion of the access cavity using a sterile disposable syringe. Following five seconds of dye immersion in the cavity, a 2W/810 nm diode laser (Picasso Lite) was employed in continuous mode with periodic application for an irradiation period of five to ten seconds, followed by a break of twenty seconds, moving the laser unit's tip from coronal to apical direction. This process was carried out 5 times. With sterile normal saline, the last irrigation was completed.

Group B (n=22)-Passive Ultrasonic Irrigation (PUI)

After CMP, sodium hypochlorite was irrigated and stirred using an ultrasonic tip (IrriSafe, SATELEC) connected to an ultrasonic unit (Suprasson P5 booster) with a power setting ranging from 4 to 8 for a period of 2-3 minutes. A continuous agitation was accomplished with the tip inserted 1 mm from the working length and remaining there until the agitation is completed. A final irrigation was carried out using sterile normal saline. The lateral compaction method was used to obturate. Composite resin was used to complete the post endodontic repair (GC Solare X). A modified verbal rating scale and a telephone discussion were used by the blinded assessor to complete the post endodontic evaluation. Modified verbal rating scale [21]

- 0 - No pain
- 1 - Slight pain/discomfort
- 2 - Moderate pain relieved by analgesics
- 3 - Moderate to severe pain not completely relieved by analgesics
- 4 - Severe pain/swelling not relieved by analgesics and required unscheduled visit.

The study considered follow-up for 6 hours, 24 hours, 48 hours, and 7 days. Patients were given a prescription for 200 mg of ibuprofen as an over-the-counter medication if they complained of pain.

Statistical analysis

The data was collected and statistically analysed using Pearson's chi-square test with 5% level of significance using statistical package for the social sciences (SPSS) software 20.0 (IBM SPSS Inc, Chicago, IL). Statistical analysis was analysed using Independent sample t-test. For all statistical analysis, probability levels of p-value <0.05 will be considered statistically significant

Results

Among the 44 patients who received treatment, 25 (56.81%) were men and 19 (43.18%) were women. Ten patients (22.72%) were between the ages of 41 and 60; 28 patients (63.63%) were between the ages of 30 and 40; and the remaining six patients (13.63%) were between the ages of 18 and 29. Out of 22 patients in Group A, 14 reported no pain, while eight reported minor discomfort at 6-hour intervals. Out of 22 patients in Group B, 19 reported no pain, while three reported mild discomfort at 6-hour intervals [Table/Fig-3]. In the early hours, there was no statistically significant difference between the two groups. 0.086 was the p-value ($p>0.05$). All of the patients experienced no discomfort at intervals of 24 hours, 48 hours, and 7 days.

Postoperative time	Laser disinfection		Passive ultrasonic irrigation	
	No pain	Slight pain	No Pain	Slight Pain
6hrs	14	8	19	3
24hrs	22	0	22	0
48hrs	22	0	22	0
1week	22	0	22	0

When the results of the present study were statistically analysed using a modified verbal rating scale to measure postoperative pain and discomfort for non-vital single-rooted teeth, the results revealed no significant difference between PUI and laser disinfection.[Table/Fig-4].

Post operative time	Group	N	Mean	Std. Deviation	Test of significance (p-value)
6hours	Group A	22	0.36	0.492	0.086
	Group B	22	0.14	0.351	
24hours	Group A	22	0	0	NA
	Group B	22	0	0	
48hours	Group A	22	0	0	NA
	Group B	22	0	0	
1 week	Group A	22	0	0	NA
	Group B	22	0	0	
Difference in pain in 1 week from 6 hours	Group A	22	0.36	0.492	0.086
	Group B	22	0.14	0.351	

Discussion

Successful eradication of debris and smear layers is obtained through alternating irrigation with sodium hypochlorite (NaOCl) and ethylene diamine tetra acetic acid (EDTA), in the coronal and intermediate levels but less successful in the apical third. This is because the root canals here are small and the irrigant fluids have a high surface tension, which prevents them from penetrating through the root canal walls [22].The most frequent issues encountered while trying to irrigate the root canal system are the formation of air bubbles and vapour locks, which prevent fluid from entering into the constrained spaces of fins, isthmuses, and lateral canals. To increase the degree of contact between irrigating fluids, physical agitation of the fluid using mechanical vibration, ultrasonic energy, or lasers has been employed [23].Therefore, the study's null hypothesis was not proven wrong. According to the study's findings, there was no statistically significant difference between PUI and laser disinfection in terms of postoperative pain and discomfort after single-visit root canal therapy for non-vital single-rooted teeth. The findings of this research are consistent with the following investigations.[Table/Fig-5] [12-18].

Author's name and year	Place of study	Number of subjects	Irrigation technique used	Parameters compared	Conclusion
Ahmetođlu F e tal. (2013)[12]	Turkey	51 Mandibular premolars	Self-Adjusting File (SAF) system, Passive Ultrasonic Irrigation(PUI) ,and Conventional Irrigation (CI)	Calcium hydroxide removal	In respect to SAF and CI, the ultrasonic irrigation approach was much more efficacious at removing CH dressing layers.
Lloyd A et al., (2014)[13]	Tennessee	14 Premolars	Standard Needle Irrigation(SNI) or Photon-Induced Photo-acoustic Streaming(PIPS)	Debris removal	When compared to SNI, laser-activated PIPS irrigation markedly enhanced the degree of debris removal from intricate canal spaces.
Mohan D et al., (2016)[14]	Kerala	53 Maxillary incisors	Conventional Endodontic Treatment (CET), Photo Activated Disinfection (PAD), and a combination of CET and PAD	Bacterial load of <i>E.faecalis</i>	PAD used along with CMP reduced the bacterial load of <i>E.faecalis</i>
De Meyer S et al.,(2017) [15]	Belgium	Resin root canal model	Syringe Irrigation (SI), Ultrasonically Activated Irrigation (UAI), and Laser Activated Irrigation (LAI)	Antimicrobial effect	Compared to ultrasonically stimulated irrigation, laser irrigation eradicated more biofilm.
Özkoçak I et al., (2018)[16]	Turkey	70 Incisors	Negative control, Positive control, 10mL2%chlorhexidine (CHX), 10mL5% NaOCl, diodelaser, Er:YAGlaser, and Indocyanin	Antibacterial efficiency	Promising results were obtained by using PDT with ICG.

			eGreen(ICG)-diodelaser(PDT).		
Plotino G et al., (2019)[17]	Italy	Transparent resin model radicular canal filled with dentin debris	ultrasonic insert 15.02; ultrasonic insert 25/25 IRRI K; ultrasonic insert 25/25 IRRI S; sonic insert 20/28 Eddy on a vibrating sonic air-scaler handpiece; 20.02K-file inserted on a Safety M4 handpiece	Elimination of debris from canal irregularities	Both sonic and ultrasonic activation demonstrate high capacity for dentin debris removal.
Mancini M et al., (2021)[18]	Italy	85 Premolars	Endoactivator, ultrasonic, laser	Smear layer removal	Laser showed best results.
Dedania MS et al., (2021, Present study)	India	44 Single root teeth	Photo Activated Disinfection (PAD) and Passive Ultrasonic Irrigation (PUI)	Post operative pain	In initial hours, the incidence of postoperative pain is slightly higher in Laser Disinfection as compared to Passive Ultrasonic Irrigation.

A comprehensive analysis by Susila A. and Minu J. in 2019 revealed equivalent findings, leading them to draw the conclusion that mechanical active irrigation devices assist reduction of postoperative discomfort and improve canal and isthmus cleanliness after endodontic treatment [24]. PUI enhances debris removal by creating a continuous movement of the irrigant through a process known as acoustic streaming [4]. By increasing the fluid's temperature by ultrasonic activation of NaOCl, substances in the fluid can have a greater impact, operate more quickly on both hard and soft tissues, and remove smear layers more effectively. Along with acoustic streaming, ultrasonic energy also generates cavitation at the instrument's tip. Explosions and implosions produce shear stress, which can physically destroy biofilms and harm microorganisms [25,26].

In instances of infection, low intensity laser irradiation has been recommended as an adjunct to chemo-mechanical root canal preparation. Many scientists have investigated how low-level laser irradiation, often known as photodynamic therapy (PDT), inhibits bacterial growth. When exposed to a material that is light sensitive, microorganisms develop a susceptibility to light irradiation, which results in a photochemical reaction that generates free radicals and singlet oxygen. Bacterial cell walls burst as a result, and the germs perish. [20]. Low-intensity lasers have an antibacterial impact by damaging their cell wall. There are several vesicle types on the bacteria's surface (membrane blebbing). When the

two outer membrane layers split, the inner membrane layer dissociates from them. The cell metabolism may also be significantly affected by a little change in the cell membrane's shape. [7]

The flexible and thin fibre of diode lasers makes it simple to enter small canals and increases the effectiveness of disinfection in the radicular dentinal tubules to a depth of 500µm. Its bactericidal effects are undeniable, comparable to those of the Nd: YAG laser. The diode laser's sterilizing effect is comparable to that of the Nd: YAG laser. The risk of an unfavorable temperature rise is decreased by the diode laser's lower penetration depth when compared to the Nd: YAG laser. However, when 20-second rest breaks were allowed following each cycle of laser treatment, the temperature increase in the periodontal ligament did not go over the acceptable level (10 C)[10]. The diode laser inhibits the enzymes that cause inflammation while stimulating cell growth. Furthermore, there are several uses for diode lasers. Diode lasers also have these qualities, and their affordability is expanding their usage in general practice. [11]

Limitations

Single-rooted teeth, a brief recall time, a small sample size, confounding factors such as a person's reaction to pain, the structure of the anterior and premolar teeth, which might influence the results, and the subjectivity of the verbal rating scale are all limitations of the study. Future studies using multiple-rooted teeth, different mechanical agitators, and a bigger sample size are still necessary.

Conclusion

It is possible to claim that PUI and laser disinfection are additive to conventional needle irrigation systems within the constraints of the analysis. However, compared to PUI, laser disinfection has a slightly greater incidence of postoperative discomfort in the early hours.

References

1. Ahmad M, Ford TP, Crum LA, Walton AJ. Ultrasonic debridement of root canals: Acoustic streaming and its possible role. *J Endod.* 1987;13(10):490-99.
2. Ahmetog̃lu F, S̃ims̃, ek N, Keles̃, A, Ocak MS, Er K. Efficacy of self-adjusting file and passive ultrasonic irrigation on removing calcium hydroxide from root canals. *Dent Mater J.* 2013;32(6):1005-10.
3. Cameron JA. The Use of Ultrasound for the Removal of the Smear Layer. The Effect of Sodium Hypochlorite Concentration; SEM study. *Aust Dent J.* 1988;33(3):193-200.
4. Darmadi, N. M., Edi, D. G. S., Kawan, I. M., Semariyani, A. A. M., & Sudiarta, I. W. (2018). The changes in protein content, moisture content, and organoleptic pindang of auxis thazard due to re-boiling stored in cold temperatures. *International Journal of Life Sciences*, 2(3), 75-85. <https://doi.org/10.29332/ijls.v2n3.210>
5. De Meyer S, Meire MA, Coenye T, De Moor RJ. Effect of laser-activated irrigation on biofilms in artificial root canals. *Int Endod J.* 2017;50(5):472-79.

6. Giri, M. K. W. (2019). Immunological side in overtraining exercise. *International Journal of Health & Medical Sciences*, 2(1), 1-6. <https://doi.org/10.31295/ijhms.v2n1.52>
7. Gondim E Jr, Setzer FC, dos Carmo CB, Kim S. Postoperative pain after the application of two different irrigation devices in a prospective randomised clinical trial. *J Endod*. 2010;36(8):1295-301.
8. Gutknecht N, Van Gogswaardt D, Conrads G, Apel C, Schubert C, Lampert F. Diode laser irradiation and its bactericidal effect in root canal wall dentin. *J Clin Laser Med Surg*. 2000;18(2):57-60.
9. Haapasalo M, Shen Y, Qian W, Gao Y. Irrigation in endodontics. *Dent Clin N Am*. 2010;54(2):291-312.
10. Kiran S, Prakash S, Siddharth PR, Saha S, Geojan NE, Ramachandran M. Comparative evaluation of smear layer and debris on the canal walls prepared with a combination of hand and rotary protaper technique using scanning electron microscope. *J Contemp Dent Pract*. 2016;17:574-81.
11. Klim JD, Fox DB, Coluzzi DJ, Neekel CP, Swick MD. The diode laser in dentistry. *Rev Wavelengths*. 2000;8(4):13-16.
12. Lacerda MF, Lacerda GP, Campos CN. Evaluation of the dentin changes in teeth subjected to endodontic treatment and photodynamic therapy. *Revista de Odontologia da UNESP*. 2016;45(6):339-43.
13. Lloyd A, Uhles JP, Clement DJ, Garcia-Godoy F. Elimination of intracanal tissue and debris through a novel laser-activated system assessed using high-resolution micro-computed tomography: A pilot study. *J. Endod*. 2014;40(4):584-87.
14. Mancini M, Cerroni L, Palopoli P, Olivi G, Olivi M, Buoni C, et al. FESEM evaluation of smear layer removal from conservatively shaped canals: Laser activated irrigation (PIPS and SWEEPS) compared to sonic and passive ultrasonic activation-An ex vivo study. *BMC Oral Health*. 2021;21(1):81.
15. Mohan D, Maruthingal S, Indira R, Divakar DD, Al Kheraif AA, Ramakrishnaiah R, et al. Photoactivated disinfection (PAD) of dental root canal system-An ex-vivo study. *Saudi J Biol Sci*. 2016;23(1):122-27.
16. Özkoçak I, Göktürk H, Coskun US, Aytac F. Antibacterial efficiency of different irrigation solutions, lasers and photodynamic therapy with indocyanine green in root canals infected by enterococcus faecalis. *Meandros Med Dent J*. 2018;19(4):289-95.
17. Parakh P, Bhondwe S, Mahajan V, Dhoot R, Muthiyan S. Sequence of Irrigation in Endodontics. *IOSR-JDMS*. 2019;18(6):41-43.
18. Pearson GJ, Schuckert KH. The role of lasers in dentistry: Present and future. *Dent Update*. 2003;30(2):70-76.
19. Plotino G, Grande NM, Mercade M, Cortese T, Staffoli S, Gambarini G, et al. Efficacy of sonic and ultrasonic irrigation devices in the removal of debris from canal irregularities in artificial root canals. *J Appl Oral Sci*. 2019;27:e20180045.
20. Rao KN, Kandaswamy R, Umashetty G, Rathore VP, Hotkar C, Patil BS. Post-Obturation pain following one-visit and two-visit root canal treatment in necrotic anterior teeth. *J Int Oral Health*. 2014;6(2):28-32.
21. Rooney J, Midda M, Leeming J. A laboratory investigation of the bacteriocidal effect of a Nd: YAG laser. *Br Dent J*. 1994;176(2):61-64.

22. Siqueira JF, Jr Rôças IN. Optimising single-visit disinfection with supplementary approaches: a quest for predictability. *Aust Endod J.* 2011;37(3):92-98.
23. Souza EB, Amorim CV, Marques JL. Effect of diode laser irradiation on the apical sealing of MTA. *Braz Oral Res.* 2006;20:231-34.
24. Suryasa, I. W., Rodríguez-Gámez, M., & Koldoris, T. (2021). The COVID-19 pandemic. *International Journal of Health Sciences*, 5(2), vi-ix. <https://doi.org/10.53730/ijhs.v5n2.2937>
25. Susila A, Minu J. Activated irrigation vs. conventional non activated Irrigation in endodontics-a systematic review. *EurEndod J.* 2019;4(3):96.
26. Tinaz AC, Alacam T, Uzun O, Maden M, Kayaoglu G. The effect of disruption of apical constriction on periapical extrusion. *J Endod.* 2005;31(7):533-35.
27. Weichman JA, Johnson FM. Laser use in endodontic: A preliminary investigation. *Oral Surgery.* 1971;31(3):828-30.
28. Weller RN, Brady JM, Bernier WE. Efficacy of ultrasonic cleaning. *J Endod.* 1980;6(9):740-43.
29. Wu MK, Wesselink PR. A primary observation on the preparation and obturation of oval canals. *Int Endod J.* 2001;34(2):137-41.