

**How to Cite:**

Khudhur, H. J., & Mussa, Q. H. (2022). Comparative study between modified blair incision and modified facelift incision for benign parotid tumor. *International Journal of Health Sciences*, 6(S6), 8072–8082. <https://doi.org/10.53730/ijhs.v6nS6.12203>

## **Comparative study between modified blair incision and modified facelift incision for benign parotid tumor**

**Haider Jihad Khudhur**

B. D. S., Senior Resident Maxillofacial Surgery, Iraqi Board for Medical Specialization, Iraq

\*Corresponding author email: [Ali.mario28@yahoo.com](mailto:Ali.mario28@yahoo.com)

**Qais Habeeb Mussa**

Prof. Dr. Maxillofacial Surgery, Iraqi Board for Medical Specialization, Iraq

**Abstract**--Background: Modified Blair incision is the classical incision for benign parotid lesions, it provides good surgical exposure, but it leaves a visible scar in the neck which bothers a wide range of patients, especially female and young patients. modified facelift incision is the new alternative approach for benign parotid lesions, it cosmetically better than the modified Blair incision because this incision is hidden behind the ear and in the hairline. Materials and Methods: This prospective clinical research comprised 16 individuals who had superficial parotidectomy for benign lesions. Group 1 = 8 patients had a modified facelift incision and Group 2 = 8 had a modified Blair incision. Variables included age, gender, histological diagnosis, operating time, and surgical exposure. The major outcomes were surgical complications and patient satisfaction. Descriptive statistics include mean, median, SD, ranges, frequencies, and proportions. Fisher's exact test compared frequencies, and student's t-test (independent two groups model) compared means  $P < 0.05$  is significant. Results: There were no statistically significant differences in postoperative complications rates between the groups. Of modified blair incisions, 25.0% suffered seroma postoperatively versus 12.5 % of modified facelift incisions. Of modified blair incisions, 12.5 % suffered gustatory sweating versus none following modified facelift incisions. The cosmetic satisfaction scores based on visual analog scale (VAS) scores with a modified facelift incisions was 9.6 compared to modified blair incisions with 6.4 (P. value  $< 0.001$  highly significant difference). the mean Deep hollow satisfaction score was 9.4 for modified facelift incisions, and for modified blair incisions was 5.4 (P. value  $< 0.001$ ). Conclusions: The reduced facelift incision leaves no visible scar in the neck, which improves aesthetics. The modified facelift incision allows

good access to all parotid gland locations. The modified facelift incision and SMAS flap can be employed to restore the depression defect immediately. Postoperative complications are comparable for modified facelift and Blair incisions. Small and medium-sized lesions can be treated with modified facelift incision, while big tumors require modified Blair incision.

**Keywords**--modified blair, modified facelift, benign parotid tumor, skin flap, SMAS flap.

## Introduction

Salivary gland neoplasms are 5–7% of head and neck malignancies. 80% of parotid gland neoplasms are benign. Pleomorphic adenoma is the most frequent parotid tumor (60%) [1]. Incisions In the head and neck, lesions should be adequately exposed and a cosmetic result achieved. In addition to oncologic considerations in the treatment of parotid lesions, cosmesis is significant to a wide variety of patients, notably female and young patients, and influences their choice to have surgery. Parotid gland lesions are excised via a modified Blair incision (also called bayonet-shaped or cervicomastoidfacial incision). Modified Blair incision gives a good exposure and is straightforward to execute. Despite careful closure, it leaves a noticeable scar on the neck. Blair's incision does not readily allow for restoration of the parotid bed, which can lead to a depression deformity and facial asymmetry. Therefore, head and neck surgeons aim to create other ways for parotid surgery, therefore the incision used in parotidectomy has changed.

In 1967, Appiani used a facelift incision for parotid tumor removal to prevent a noticeable scar [2]. Then, comparable methods to parotid masses were documented [3],[4]. Introduced a modified facelift incision to access the parotid gland in 1994. Since then, it's gained popularity for its aesthetic benefits. The cervical section of the initial blair incision is moved into the hairline to eliminate a noticeable scar [5],[6]. However, many heads and neck surgeons are worried about the appropriateness of surgical exposure and its repercussions. A few publications showed that the modified facelift incision provides the same exposure as the regular Blair's incision, independent of tumor size [7],[8] Others say a modified facelift incision can be utilized for parotid lesions that move [9]. These anxieties and suspicions make this technique uncommon. Various approaches have been described for reconstructing the depression defect after parotidectomy. It includes the sternocleidomastoid flap, SMAS advancement flap, temporalis muscle flap, temporoparietal fascia flap, and free abdominal fat grafting. Many writers mention using a SMAS advancement flap in parotid surgery to minimize postoperative depression deformity. The SMAS flap reduces Frey's syndrome, too [10].

## Materials and Methods

This study comprised 16 patients with benign parotid lesions who underwent parotidectomy at Al-hussainy teaching hospital from March 2019 to September

2020. Group 1 = 8 patients had a modified facelift incision, and Group 2 = 8 patients had a modified Blair incision. Preoperatively the patients were assessed using a complete medical history, physical exam, ultrasonography, FNA cytology, and parotid CT. Pathology verified the diagnosis. Most patients were followed for 6 months postoperatively. Age, gender, histological diagnosis, operation time, postoperative problems, and patient satisfaction were evaluated.

### **Inclusion criteria**

- Any patient with confirmed benign parotid gland tumor.
- tumors less than 4 cm in size.
- Patients general condition allowing performing excision of the tumor.

### **Exclusion criteria**

- Patient who are medically compromised.
- Patients with malignant parotid tumor.
- large tumors (greater than 4cm in diameter).

### **Clinical examination**

All patients with parotid tumors had clinical examinations to determine tumor size, location, consistency (hard, rubbery, and anchored to underlying tissues), skin ulceration or tethering, and facial nerve function. This research categorized tumors as small (less than 2 cm), medium (2-4cm), and big (greater than 4 cm). This research examined tumors less than 4 cm. Preoperative imaging was taken for all patients in order to aid in diagnose and assess the site and extent of tumors these include: ultrasound and CTscan(axial and coronal sections). (Figure 1)

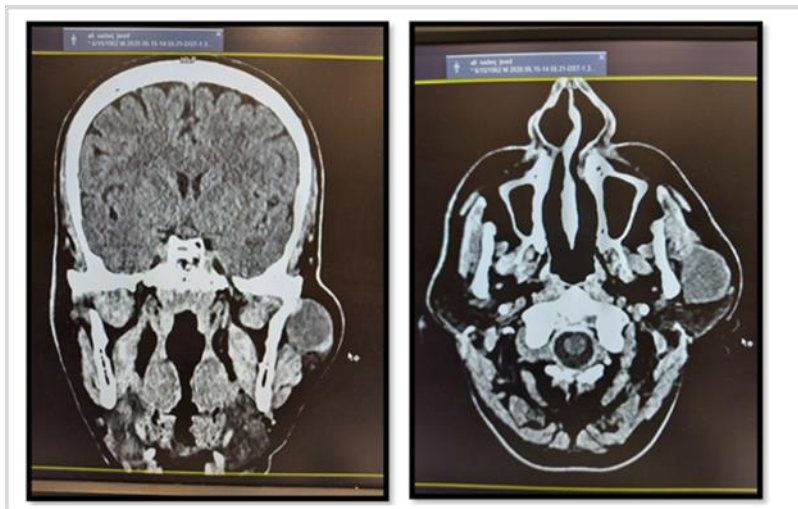


Figure 1. CT scan of patient with left parotid tumor, coronal. Axial section

## Surgical procedure

The patient lies supine with a cotton bag under his shoulder and his head twisted. Povidone-iodine-treated skin is covered with towels, leaving the ear, eye, mouth, and neck exposed. Eight patients in Group 1 received a modified facelift incision, and eight in Group 2 got a modified Blair incision. Group 1 used a number 21 blade and methyl violet to mark the incision site. It started at the temporal scalp and followed a pre-auricular crease. The incision runs along the earlobe's retro-auricular sulcus. The retro-auricular incision continues beyond the hairline to avoid a sharp tragus angle. Incision continues along hairline inferiorly. We raise the mastoid skin flap from the sternocleidomastoid to the parotid fascia. An helper retracts or staystitches the flap. After lifting the skin flap, the vast auricular nerve branches are visible in the ear lobe. We cut the nerve to preserve earlobe sensation. In the preauricular region, skin and SMAS were raised to the parotid gland. (figure 2)

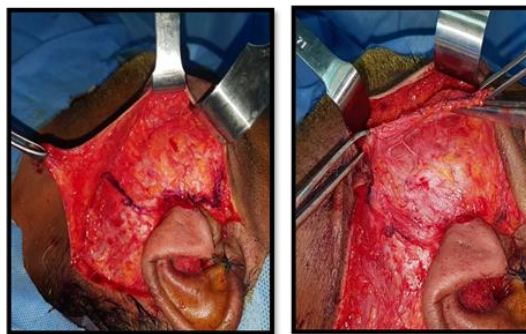


Figure 2. Skin flap elevation and SMAS flap elevation

## Statistical analysis

SPSS 26 was used to enter and manage data. Mean, median, SD, ranges, frequencies, and proportions are descriptive statistics. Fisher's exact test compares frequencies, and the student's t-test compares means.  $P < 0.05$  is deemed significant. Finally, outcomes are in tables and figures with explanations.

## Results

16 patients receiving parotidectomy at AL-Hussainey Teaching Hospital in Karbala were recruited in this clinical experiment and divided into two groups: group I used modified facelift incision and group II utilized modified blair incision.

### Socio-demographic characteristics (Age & Gender)

The distribution of the study patients by age is shown in table (1). Study patient's age was ranging from 13 to 60 years with a mean of  $36.4 \pm 16.6$  years in group I, and the patient's age in group II was ranging from 20 to 65 years with a mean of  $42.9 \pm 18.9$  years. The distribution of the study patients by gender is shown in

table( 2). In group I, the proportion of female was 75.0% and male was 25.0% (Female to male ratio = 3:1 in group I), and group II, the proportion of female was 62.5 % and male was 37.5% (Female to male ratio = 1.7:1.0 in group II)

Table 1  
Distribution of the study patients by demographic characteristics (Age)

	No.	%	No.	%	
13 - 20	1	12.5	1	12.5	1.00 ns
21 - 30	2	25.0	1	12.5	
31 - 40	2	25.0	2	25.0	
41 - 50	2	25.0	1	12.5	
51-60	1	12.5	2	25.0	
> 60	0	0.0	1	12.5	
Mean $\pm$ SD*	36.4 $\pm$ 16.6		42.9 $\pm$ 18.9		0.438 ns
Range	13 - 60		20 - 65		

SD: standard deviation, ns: not significant

Table 2  
Distribution of the study patients by demographic characteristics (Gender)

	Group I		Group II	
	No.	%	No.	%
Male	2	25.0	3	37.5
Female	6	75.0	5	62.5
Total	8	100.0	8	100.0

Fisher's Exact Test used to compare genders = 1.00,  
P. value = 0.896 not significant

### Size of the tumors

The distribution of patients according to the tumor size is shown in table (3).The mean tumor size was 2.77cm in group I, and in group II the mean tumor size was 2.80 cm.

Table 3  
Distribution of study patients according to the tumor size

Statistics for Size of tumor (cm)	Group I	Group II
Mean	2.77	2.80
Range	2 - 3.5	1.5 - 3.5

Student's t test used to compare means, t = 0.091  
P. value = 0.929 not significant

### Histological type of tumors

The distribution of patients according to the histological type of tumors is shown in (table (4) , figure (1). The more frequent histopathological type of tumor in both

groups was pleomorphic adenoma which reported in 5 patients (62.5%) of group I and 6 patients (75%) in group II giving a total of 11/16 patients. Cyst was reported in three patients, two of them in group II, while monomorphic adenoma and lipoma were found only in group I.

Table 4  
Distribution of study patients according to the histological type of tumors

Histopathology	Group I		Group II		Fisher's exact test	P. value
	No.	%	No.	%		
Pleomorphic adenoma	5	62.5	6	75.0	1.00	0.589 ns
Cyst	1	12.5	2	25.0	1.03	0.522 ns
Monomorphic adenoma	1	12.5	0	0.0	1.07	1.00 ns
Lipoma	1	12.5	0	0.0	1.07	1.00 ns
Total	8	100.0	8	100.0	-	-

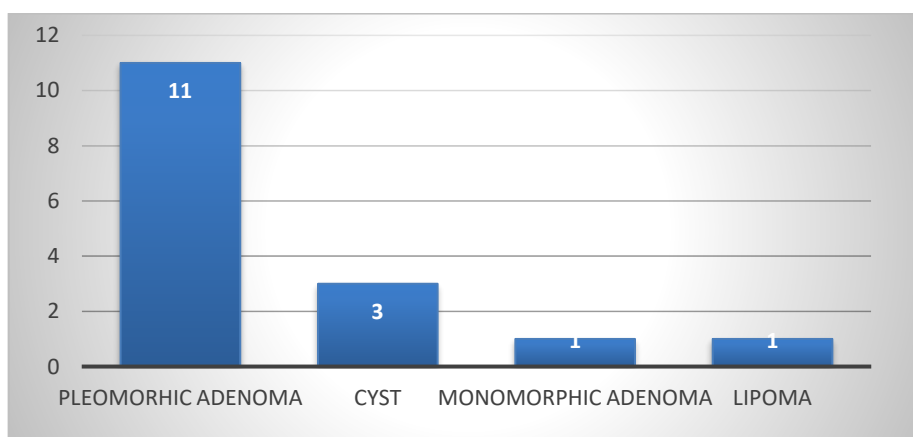


Figure 1. Distribution of study patients according to the histological type of tumors

### Surgical interventions

The distribution of study patients according to the type of surgical intervention is shown in table (5) and figure (2). It was obvious that the most common type of surgical intervention used was superficial parotidectomy with preservation of facial nerve (75.0 %) in both groups.

Table 5  
The distribution of study patients according to the type of surgical interventions

Treatment plan	Group I		Group II	
	No.	%	No.	%
Extracapsular dissection	2	25.0	2	25.0
Superficial Parotidectomy with preservation of facial nerve	6	75.0	6	75.0
Total	8	100.0	8	100.0

Fisher's Exact Test used to compare plans = 0, P. value = 1.0 not significant
---

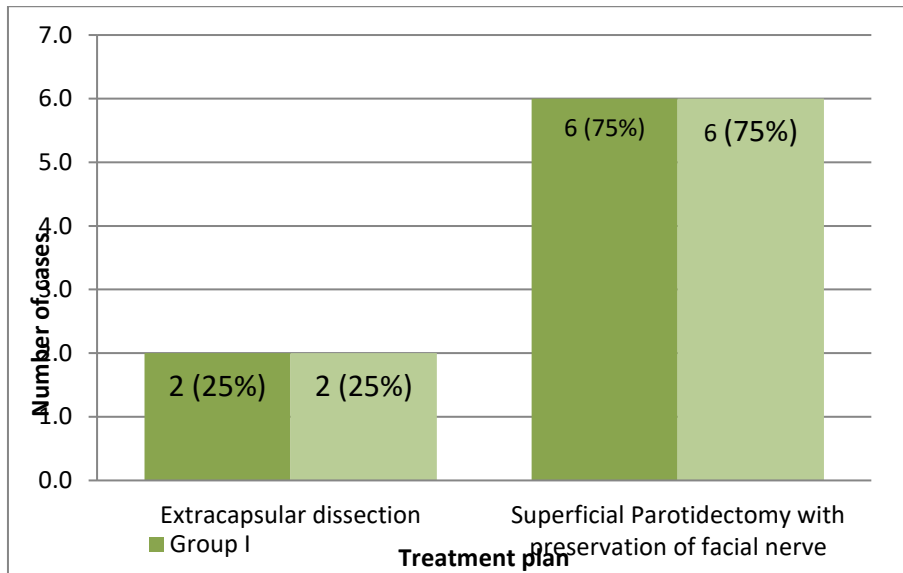


Figure 2. The distribution of study patients according to the type of surgical interventions

### Operative time and Postoperative Complications

The distribution of study patients according to operative time is shown in table (6). On comparison of operative time between the studied groups, the mean operative time was relatively longer in group I than group II, the mean time was 128.3 (range: 120-145) minutes vs. 122.5 (range: 115-140) minutes, respectively. The distribution of study patients according to postoperative complication is shown in table (7). Regarding the postoperative complications, four complications incident among the total patients 25%, but the highest proportion of the study patients had no postoperative complications 75%. The reported complications was seroma in one patient from group I and two patients from group II, and Frey syndrome in only one patient from group II.

Table 6  
The distribution of study patients according to operative time

Statistics for Operative time (minutes)	Group I	Group II
Mean	128.3	122.5
Range	120 – 145	115 – 140
Student's t test used to compare means, t = 0.74 P. value = 0.314 no significant difference		

Table 7  
The distribution of study patients according to postoperative complications

Complication*	Group I		Group II		P. value
	No.	%	No.	%	
No complication	7	87.5	5	62.5	0.601 ns
Seroma	1	12.5	2	25.0	0.984 ns
Frey syndrome	0	0.0%	1	12.5	1.00 ns
Total	8	100.0	8	100.0	-

ns: not significant

## Discussion

Modified Blair incision is the conventional parotidectomy method; it's straightforward and affords adequate parotid gland exposure, but it leaves a conspicuous scar in the neck. Besides oncologic considerations in the treatment of parotid lesions, cosmesis is of utmost relevance for a wide variety of patients, notably female and young patients. Appiani was the first to recommend facelift incision for parotid surgery to avoid a conspicuous neck scar. Since since, this incision has been famous for its cosmetic effects. This study compared the modified blair incision and modified facelift incision in patients receiving parotidectomy in terms of demographic features, therapy and surgical technique, operating time, tumor size, postoperative problems, and patient satisfaction level in karbala.

## Demographic characteristics

Many studies advise a modified facelift incision for parotidectomy due to its high aesthetic effect because the scar is buried behind the ear and in the hairline. Lohuis et al. [10], show that the number of patients with benign parotid lesions is significant, and the cosmetic effects of the incision utilized play a major influence in their choice to have surgery. Garciano et al.[11], observed that females (67.9%) and young individuals typically employ the modified facelift incision. In this study, group I had a mean age of 36.4, while group II had a mean age of 42.9. There was no statistically significant difference in age between the two groups, as earlier studies have shown [12],[13],[14]. There was no statistically significant difference between male and female, however females outnumbered men, notably in group I (female to male ratio = 3:1 in group I and 1.7:1.0 in group II). According to other research, the modified facelift incision can be utilized more often on women [11].

## Size of the tumors

Regarding the tumor size and exposure of parotid lesion, anatomical studies have demonstrated that the exposure obtained by the modified facelift incision is equal to that obtained by the standard Blair's incision regardless of tumor size [6, 13,15]. Other authors showed that the modified facelift incision allows exposure of small(tumor 2 cm or less) and medium sized(2-4 cm) lesions of the parotid gland [10], [16],[17]. In our study the mean size of the parotid lesion in the MFI group was 2.77cm —versus 2.80 cm in the BI group, and there was no statistical

significant differences between the studied groups regarding the tumor size (P. value = 0.929), and this is in consistent with the study of Graciano et al. [11] and Bulut et al. [18].

### **Treatment and Surgical procedure**

Superficial parotidectomy with preservation of the facial nerve was the most common type of intervention (75.0 %) in both groups probably due to high involvement of these groups of salivary glands with the most common type of salivary gland tumor pleomorphic adenoma.

### **Operative time and Postoperative Complications**

Operative time has been officially analyzed in multiple studies [5],[7],[10],[19], which demonstrated that the operative time for super facialparotidectomy via modified facelift was slightly longer and there was no statistically significant difference between the two incisions, except one study by Terris et al in 1994 which show a slightly shorter operative time with the modified facelift incision in comparison with Blair's incision. Bulut et al. [18], reported an increased operative time via modified facelift incision by 19 min. In our study, On comparison of operative time between the studied groups, the mean operative time was relatively longer in group I than group II, the mean time was 128.3 (range: 120-145) minutes vs. 122.5 (range: 115-140) minutes, respectively. and there was no statistically significant difference between two incisions (P. value = 0.314), this is in keeping with other studies [7],[18].

The operative time using a modified facelift incision can be slightly longer, because of the modified facelift incision is a more challenging technique and require more retraction. Regarding the postoperative complications in general, several authors showed that there were no significant differences between the two incisions [5], [11], [13], [18], [19]. Wasson et al. [16], found that the facial nerve dysfunction in patients operated via the modified facelift incision lower than Blair incision, because there was a large difference in numbers between the two groups in Wasson study. Other studies De Vicente et al., [13], Lee et al. [15], Bulut et al. [18], did not observe any significant difference in facial nerve dysfunction between the two incisions. Fortunately, facial nerve dysfunction was not reported in the present study may be due to limited number of patients.

### **Conclusion**

The modified facelift incision covers neck scars better than the modified Blair incision after benign parotidectomy. Blair's incision and the modified facelift incision both give excellent parotid gland access. Rapid repair of the depression defect with a modified facelift incision and SMAS flap improves patient satisfaction. Postoperative problems after a modified facelift incision are prevalent. Small and medium-sized tumors can be treated using the modified facelift incision. Large, deep tumors require the modified Blair incision.

## References

1. Amin, A., Mostafa, A., Rifaat, M., Nabawi, A., Shallan, M., Rabie, A., & Elzohairy, M. (2011). Parotidectomy for benign parotid tumors: An aesthetic approach. *Journal of the Egyptian National Cancer Institute*, 23(2), 67–72.
2. Appiani E. (1967). Handling of a parotidectomy and muscular graft. *Prensa Med Argent*, (54), 1242–1243.
3. Brennan, P. A., VishyMahadevan, & Evans, B. T. (2016). *Clinical head and neck anatomy for surgeons*. Boca Raton: Crc Press, Taylor & Francis Group. (pp. 59–68).
4. Bulut, O. C., Plinkert, P., & Federspil, P. A. (2016). Modified facelift incision for partial parotidectomy versus bayonet-shaped incision: a comparison using visual analog scale. *European Archives of Oto-Rhino-Laryngology*, 273(10), 3269–3275.
5. de Vicente, J. C., González-García, M., de Villalain, L., & Fernández-Valle, Á. (2015). Modified facelift approach combined with a superficial musculoaponeurotic system flap in the treatment of benign parotid tumors. *Journal of Cranio-Maxillofacial Surgery*, 43(8), 1655–1661.
6. Graciano, A. J., Chone, C. T., & Fischer, C. A. (2013). Cervicomastoidfacial versus modified rhytidectomy incision for benign parotid tumors. *Brazilian Journal of Otorhinolaryngology*, 79(2), 168–172.
7. Grover, N., & D'Souza, A. (2013). Facelift Approach for Parotidectomy. *Otolaryngology–Head and Neck Surgery*, 148(4), 548–556.
8. Guerrerosantos, J., Dicksheet, S., Guillen, C., & Andino, N. (1982). Hidden Incision in Surgery of Parotid, Submandibular, Cervical, and Cheek Benign Tumors. *Annals of Plastic Surgery*, 9(5), 402–408.
9. Hinderer, U. T. (1977). Prevention of Unsatisfactory Scarring. *Clinics in Plastic Surgery*, 4(2), 199–205.
10. Kim, D. Y., Park, G. C., Cho, Y. W., & Choi, S. H. (2014). Partial superficial parotidectomy via retroauricular hairline incision. *Clinical and Experimental Otorhinolaryngology*, 7(2), 119–122.
11. Lee, S.-Y., Koh, Y. W., Kim, B. G., Hong, H. J., Jeong, J. H., & Choi, E. C. (2011). The Extended Indication of Parotidectomy Using the Modified Facelift Incision in Benign Lesions: Retrospective Analysis of a Single Institution. *World Journal of Surgery*, 35(10), 2228–2237.
12. Lin, T. C., Chen, P. R., Wen, Y. H., & Chou, Y. F. (2011). Intra-auricular modification of facelift incision with sternocleidomastoid flap - a cosmetic approach for parotidectomy: How we do it. *Clinical Otolaryngology*, 36(4), 375–379.
13. Lohuis, P. J. F. M., Tan, M. L., Bonte, K., van den Brekel, M. W. M., Balm, A. J. M., & Vermeersch, H. B. (2009). Superficial Parotidectomy via Facelift Incision. *Annals of Otology, Rhinology & Laryngology*, 118(4), 276–280.
14. Meningaud JP, Bertolus C, Bertrand JC. Parotidectomy: assessment of a surgical technique including facelift incision and SMAS advancement. *J Craniomaxillofac Surg*. 2006; 34:34-37.
15. Nouraei, S. A. R., Al-Yaghchi, C., Ahmed, J., Kirkpatrick, N., Mansuri, S., Singh, A., & Grant, W. E. (2006). An anatomical comparison of Blair and facelift incisions for parotid surgery. *Clinical Otolaryngology*, 31(6), 531–534.

16. Suryasa, I. W., Rodríguez-Gámez, M., & Koldoris, T. (2021). Get vaccinated when it is your turn and follow the local guidelines. *International Journal of Health Sciences*, 5(3), x-xv. <https://doi.org/10.53730/ijhs.v5n3.2938>
17. Terris, D. J., Tuff, K. M., & Fee, W. E. (1994). Modified facelift incision for parotidectomy. *The Journal of Laryngology & Otology*, 108(7), 574–578.
18. Upile, T., Jerjes, W. K., Nouraei, S. A. R., Grant, W., Singh, S., Sudhoff, H., & Hopper, C. (2009). Further anatomical approaches to parotid surgery. *European Archives of Oto-Rhino-Laryngology*, 267(5), 793–800.
19. Wasson, J., Karim, H., Yeo, J., & Panesar, J. (2010). Cervicomastoidfacial versus modified facelift incision for parotid surgery: A patient feedback comparison. *Annals of the Royal College of Surgeons of England*, 92(1), 40–43.
20. Widjaja, G. (2021). Impact of human resource management on health workers during pandemics COVID-19: systematic review. *International Journal of Health & Medical Sciences*, 4(1), 61-68. <https://doi.org/10.31295/ijhms.v4n1.850>
21. Zheng, Z., Li, J., Wang, J., & Sun, J. (2018). Hidden scar dissection of benign parotid gland tumors via a V-shaped minimal facelift incision. *Journal of Craniofacial Surgery*, 29(8), 2299–2303.