

How to Cite:

Sukmawati, S. Y., Rahman, M. A., Utamayasa, A., & Hidayat, T. (2022). Possibility of rheumatic fever in patient with chorea: A case report. *International Journal of Health Sciences*, 6(S9), 354–360. <https://doi.org/10.53730/ijhs.v6nS9.12264>

Possibility of rheumatic fever in patient with chorea: A case report

Sari Yunita Sukmawati

Universitas Airlangga, Surabaya, Indonesia

Mahrus. A. Rahman

Universitas Airlangga, Surabaya, Indonesia

Corresponding authors email: mahrus_rahman@yahoo.com

Alit Utamayasa

Universitas Airlangga, Surabaya, Indonesia

Taufiq Hidayat

Universitas Airlangga, Surabaya, Indonesia

Abstract---Most authorities suggest Sydenham chorea (SC) to be an autoimmune disease that is triggered by a streptococcus infection, subsequently resulting in a hypersensitivity humoral reaction to the infection and cross-reactivity streptococci antigens and human tissue antigens through antigen mimicry. Typically, the first episode occurs 6 to 8 weeks after an episode of GABHS pharyngitis. Diagnostic evaluation of Sydenham chorea should include a careful history and neurologic examination. This case presents an 11-year old girl with a primary complain of involuntary movements, slurred speech and an unstable gait since 1.5 month. Chorea is a clinical diagnosis, made after a careful assessment to exclude other causes. It is important to consider whether a child presenting with chorea could have an autoimmune disorder. Laboratory investigations and echocardiography may be indicated, particularly if there are no other features to support a diagnosis of rheumatic fever.

Keywords---Sydenham Chorea, Streptococcus Infection, Clinical Diagnosis, Laboratory Investigation.

Introduction

Sydenham chorea (SC) is a neurological disorder of childhood resulting from infection via Group A beta-hemolytic streptococcus (GABHS), the bacterium that causes rheumatic fever. The random, writhing movements of chorea are caused

by an autoimmune reaction to the bacterium that interferes with the normal function of a part of the brain (the basal ganglia) that controls motor movements. Sydenham's chorea is characterized by the abrupt onset (sometimes within a few hours) of neurologic symptoms, classically chorea, usually affecting all four limbs. (Rwebembera et al., 2022)

In developing areas of the world, prevalence ARF is estimated to affect over 33 million people and is the leading cause of cardiovascular death during the first five decades of life. ARF can occur at any age, although most cases occur in children 5 to 15 years of age (Zühlke et al., 2017). The mean incidence of ARF is 19 per 100,000 school-aged children worldwide but it is lower (≤ 2 cases per 100,000 school-aged children) in the United States and other developed countries. Most cases occur in low and middle income countries and among Indigenous groups such as those in Australia and New Zealand. (Carapetis et al., 2016) SC is one of the major manifestations of ARF described in Jones criteria for diagnosis of ARF. Sydenham's chorea affects almost 30% - 46 % of patients with acute rheumatic fever (ARF). It is more frequent in females and is rare in the first decade of life, and genetic vulnerability underlies. (Dean & Singer, 2017)

Proposed treatments of SC in ARF currently include acute and prophylactic penicillin therapy, anti inflammatory, symptomatic medications (neuroleptics drug). Prevention of the SC by aggressively treating Group A B-hemolytic streptococcal pharyngeal infection and reducing the likelihood of rheumatic heart disease is needed. Once SC is diagnosed, secondary antibiotic prophylaxis is indicated to decrease the risk of neurologic and cardiac problems with future streptococcal infections. (Feinstein & Walker, 2018; Gerber et al., 2009) The purpose of this case report is to determine the possibility of rheumatic fever in patient with chorea and treatment of ARF.

Case Report

Mrs. P, 11 years old girl from Kediri, was admitted February 2020 due to involuntary movement. Patient was referred from public hospital in Kediri with chief complain of involuntary movements since 1.5-month prior admission. In the first week, the patient had upper and lower extremities involuntary movement. The involuntary movements are rapid, repetitive, aimless, swinging, similar to the movement of a dancer, which occur unnoticed and cannot be controlled. The duration of movement happening from 5-10 minutes to each attack and reappears several times. There is a break between several attacks when no involuntary movement is happening. In the beginning, these movements only appear a few minutes every few hours. As time goes, the duration is getting longer, and the frequency increases more often. The neurological features of SC are involuntary movements, which are exacerbated by stress and disappear during sleep.

Two days prior admission, those symptoms were causing discomfort and disrupting the patient's activity. At the same time, she went through gait disturbance such as halting gait, stumbling and falling that are frequent and severe enough to be incapacitating. She had been having difficulties with speaking and daily activities such as eating and drinking from a glass. Patient

even couldn't eat and drink without assistant. Symptoms can appear gradually or all at once and also may include facial grimacing, hypotonia, muscle weakness, emotional instability.

From the physical examination upon admission (20th February 2020), we found involuntary movements all over the body, include head and neck, trunk, and both upper and lower extremities. No other remarkable finding in this patient. Head CT scan result showed sinusitis sphenoidalis dextra without any other abnormalities. The antistreptolysin O (ASO) titer was 505,91 IU/ ml . Patient was consulted to pediatric cardiology division. Plan for ECG and echocardiography.

Echocardiography had also performed on 21th February 2020 at hospital resulting severe MR, moderate AR, dilatation RA, dilatation RV with ejection fraction 69.30%. Patient was diagnosed rheumatic fever, with active carditis with Severe MR, moderate AR, dilatation LA, dilatation LV.

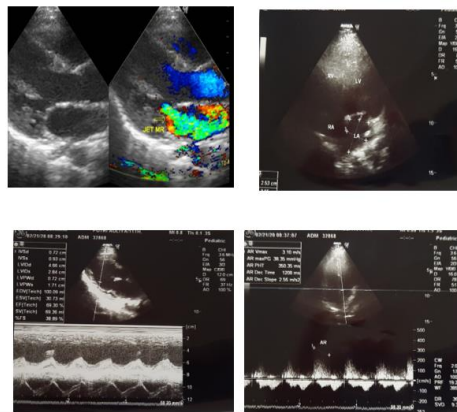


Figure 1. Echocardiography at hospital on 21th February 2020

Patient was transferred to pediatric cardiology ward, patient was treated with erythromycin 250 mg four times a day for 10 days, lisinopril 1x 5 mg per oral, and spironolactone 1x 22 mg per oral. To reduce chorea symptoms, patient was consulted to neuropediatric division and got haloperidol 0.8 mg two a day (0.015 mg/bw/day). She also got prednisone 2 mg/ kgbw/ day for two weeks and tapering off. Steroids were given in this case during the acute inflammatory period of rheumatic fever. Four days later after she got therapy, the symptoms gradually decreases, patient still must have totally bed rest. Three days later, she was discharged and still continuing therapy.

One month after discharged, patient came for followed up. She has returned to school and still continues her prophylactic erythromycin therapy. Her murmur still persist, and she has monthly follow-up visits. She is not having any behavior problems and is performing well in school.

Discussion

Chorea is a movement disorder that occurs in many different diseases and conditions. Chorea is a movement disorder that causes involuntary, irregular, unpredictable muscle movements. The word chorea comes from the Greek word for “dance”, as the quick movements of the feet or hands are comparable to dancing. (Wild & Tabrizi, 2007) Chorea itself isn't life-threatening, but it could be a sign of a neurological disorder. By convention, movement disorders are divided into two major categories, hyperkinetic movement disorders and hypokinetic movement disorders. (Wilson & Keener, 2018) Abnormalities of movement that are presumed to be due to central nervous system divided into pyramidal and extrapyramidal. The components of the central nervous system typically implicated in disorders of movement are the basal ganglia and frontal cortex. (Bhidayasiri & Truong, 2004)

In this case, patient had been no history of seizures in either the patient or family. Patient was not currently on medications and had no known medication allergies. Patient also denied unusual ingestions. Once a diagnosis of sydenham chorea is made, associated medication and toxin should be excluded. In this case, patient came with chief complain of involuntary movements. Involuntary movements is characterized by rapid, irregular, and aimless involuntary movements of the arms and legs. The movements are repetitive, swinging, similar to the movement of a dancer, which occur unnoticed and cannot be controlled. In the beginning, these movements only appear a few minutes every few hours. As time goes, the duration is getting longer, and the frequency increases more often but not progressive. Patients claimed there had been no previous history of a similar disease from her family. Head CT scan showed no neurodegenerative process (normal). So it can be concluded that chorea caused by Huntington's disease should be excluded.

In Sydenham's chorea, neurons in the basal ganglia are attacked by antibodies against the group A carbohydrate of *Streptococcus* spp that react with the surface of the neuron. (Dale, 2003) This reaction activates signalling through calcium/calmodulin-dependent protein kinase type II (CAMK2), which involves an increase in tyrosine hydroxylase in dopaminergic neurons. Receptors, such as the D1 and D2 dopamine receptors, and lysoganglioside might be autoantibody targets on the neuronal cell. This targeting could lead to altered cell signalling and increased levels of dopamine, in turn leading to abnormal movements and behaviours. (Carapetis et al., 2016)

The therapeutic management of rheumatic fever has four main goals: first, eradication of group A streptococcus beta haemolyticus, second, an anti-inflammatory treatment of the symptoms of rheumatic fever, third supportive management and management of complications and fourth long term prophylaxis of recurrent infection. (Feinstein & Walker, 2018)

In this case, patient have penicillin allergy history so after she was diagnosed with SC, our patient was treated with erythromycin 250 mg fourth daily for 10 days and continued treated with orals erythromycin 250 mg twice daily for secondary prophylaxis.

Carditis is the most serious major manifestation of rheumatic fever. It may culminate in chronic valvular disease and can lead to heart failure and, ultimately, death. The carditis usually has no associated symptoms and is often only identified during clinical examination of a patient who presents with a fever, arthritis or chorea (involuntary, jerky movements of the limbs). The clinical features reflect the involvement of the various layers of the heart viz. endocardium including the valves, the myocardium, or the pericardium, and frequently all three layers of the heart. The heart valves are the most commonly affected structure. Recommended therapies for acute rheumatic fever includes anti-inflammatory agents.(Walker & Wilmshurst, 2010)

In this case, the patient received oral prednisone, full dose (2 mg/kg/day) for the first 2 weeks, gradually tapering off. Weight, blood pressure, serum glucose and electrolytes were monitored, and none of the patients developed any adverse effects except slight, transient weight gain.

Because Sydenham's chorea is usually self limited, bed rest and stress avoidance may suffice for the treatment. If the choreic movements are prolonged or severe, drug treatment become necessary. Several dopamine antagonists have been utilized in worldwide studies to treat chorea, the most common being the neuroleptics haloperidol and pimozide. Those agents which affect the neurotransmitters dopamine and GABA which is suitable with pathophysiology of SC.(Işıkay & Yılmaz, 2021)

In this case, patient experiencing involuntary movements. In the beginning, these movements only appear a few minutes every few hours. As time goes, the duration is getting longer, and the frequency increases more often. Those symptoms were causing discomfort and disrupting the patient's activity. At the same time, she go through gait disturbance such as halting gait, stumbling and falling that are frequent and severe enough to be incapacitating. So patient got haloperidol, which is this drugs in use to reduce chorea symptoms. Based on literature symptomatic treatment decision of chorea should be based on the functional impact on the child caused by chorea itself.

Conclusion

SC is one of the major clinical manifestations of acute rheumatic fever (ARF). The diagnosis of syndeham chorea was made by Jones criteria. The diagnosis of ARF is made when the patient presents with two major manifestations or one major manifestation and at least two minor manifestations. The exceptions to these criteria are patients who present with chorea or indolent carditis because these manifestations might only become apparent months after the causative streptococcal infection.

Chorea is a clinical diagnosis, made after a careful assessment to exclude other causes. It is important to consider whether a child presenting with chorea could have an autoimmune disorder,etc. Laboratory investigations and echocardiography may be indicated, particularly if there are no other features to support a diagnosis of rheumatic fever.

Therapeutic interventions for patients with acute rheumatic fever has four main tenets: eradication of group A streptococcus beta haemolyticus, second, an anti-inflammatory treatment of the symptoms of rheumatic fever, third supportive management and management of complications and fourth long term prophylaxis of recurrent infection. We hope that the present case report, will focus attention, emphasizes the importance and awareness, in any child with chorea, therefore it is clinically important to screen patients sydenham chorea for earlier diagnosis, treatment, prevent complication of ARF and improvement of the quality of life.

Acknowledgments

We would like to thank Mahrus A Rahman, Alit Utamayasa, and Taufiq Hidayat for providing language help, writing assistance and supervising this case report. Funding: No external funding granted

References

- Bhidayasiri, R., & Truong, D. D. (2004). Chorea and related disorders. *Postgraduate Medical Journal*, 80(947), 527–534.
- Carapetis, J. R., Beaton, A., Cunningham, M. W., Guilherme, L., Karthikeyan, G., Mayosi, B. M., Sable, C., Steer, A., Wilson, N., & Wyber, R. (2016). Acute rheumatic fever and rheumatic heart disease. *Nature Reviews Disease Primers*, 2(1), 1–24.
- Dale, R. C. (2003). Autoimmunity and the basal ganglia: new insights into old diseases. *Qjm*, 96(3), 183–191.
- Dean, S. L., & Singer, H. S. (2017). Treatment of Sydenham's chorea: a review of the current evidence. *Tremor and Other Hyperkinetic Movements*, 7.
- Feinstein, E., & Walker, R. (2018). An update on the treatment of chorea. *Current Treatment Options in Neurology*, 20(10), 1–15.
- Gaibullaeva, N. N. (2021). The role of clinical examination early diagnosis of glaucoma. *International Journal of Health & Medical Sciences*, 4(3), 333–337. <https://doi.org/10.31295/ijhms.v4n3.1745>
- Gerber, M. A., Baltimore, R. S., Eaton, C. B., Gewitz, M., Rowley, A. H., Shulman, S. T., & Taubert, K. A. (2009). Prevention of rheumatic fever and diagnosis and treatment of acute Streptococcal pharyngitis: a scientific statement from the American Heart Association Rheumatic Fever, Endocarditis, and Kawasaki Disease Committee of the Council on Cardiovascular Disease in the Young, the Interdisciplinary Council on Functional Genomics and Translational Biology, and the Interdisciplinary Council on Quality of Care and Outcomes Research: endorsed by the American Academy of Pediatrics. *Circulation*, 119(11), 1541–1551.
- İşikay, S., & Yılmaz, K. (2021). Oxcarbazepine May Be Useful in Sydenham Chorea. *Turkish Archives of Pediatrics*, 56(6), 648.
- Rwebembera, J., Nascimento, B. R., Minja, N. W., de Loizaga, S., Aliku, T., Dos Santos, L. P. A., Galdino, B. F., Corte, L. S., Silva, V. R., & Chang, A. Y. (2022). Recent Advances in the Rheumatic Fever and Rheumatic Heart Disease Continuum. *Pathogens*, 11(2), 179.
- Suryasa, I. W., Rodriguez-Gámez, M., & Koldoris, T. (2022). Post-pandemic health and its sustainability: Educational situation. *International Journal of Health*

- Sciences, 6(1), i-v. <https://doi.org/10.53730/ijhs.v6n1.5949>
- Walker, K. G., & Wilmshurst, J. M. (2010). An update on the treatment of Sydenham's chorea: the evidence for established and evolving interventions. *Therapeutic Advances in Neurological Disorders*, 3(5), 301–309.
- Wild, E. J., & Tabrizi, S. J. (2007). The differential diagnosis of chorea. *Practical Neurology*, 7(6), 360–373.
- Wilson, R. B., & Keener, A. M. (2018). Movement disorders in children. *Advances in Pediatrics*, 65(1), 229–240.
- Zühlke, L. J., Beaton, A., Engel, M. E., Hugo-Hamman, C. T., Karthikeyan, G., Katzenellenbogen, J. M., Ntusi, N., Ralph, A. P., Saxena, A., & Smeesters, P. R. (2017). Group A streptococcus, acute rheumatic fever and rheumatic heart disease: epidemiology and clinical considerations. *Current Treatment Options in Cardiovascular Medicine*, 19(2), 1–23.