

**How to Cite:**

Ahmed, O. E. F. M. S., Mahmoud, A. A. F., Ali, H. E. M., AlAshmawy, M. M., Abdullah, A. B., Fattah, M. A. A., & Abdo, A. A. T. (2022). Assessment of narrow alveolar ridge expansion by ossiodensification vs. ridge splitting technique for dental implant placement: Clinical and radiographic study. *International Journal of Health Sciences*, 6(S9), 392–403.  
<https://doi.org/10.53730/ijhs.v6nS9.12291>

## **Assessment of narrow alveolar ridge expansion by ossiodensification vs. ridge splitting technique for dental implant placement: Clinical and radiographic study**

**Omar El Farouk Mossad Sadek Ahmed**

BDS (2009) G. Faculty of Dental medicine, Al-Azhar University, Dentist, Ministry of health.

Email: [dromarelfarouk@gmail.com](mailto:dromarelfarouk@gmail.com)

**Ashraf Abdel Fattah Mahmoud**

Professor of Oral and Maxillofacial Surgery Faculty of Dental Medicine, Boys, Assiut, Al-Azhar University.

Email: [Ashraf10102002@yahoo.com](mailto:Ashraf10102002@yahoo.com)

**Hossam Eldin Mohammed Ali**

Assistant Professor of Oral and Maxillofacial Surgery Faculty of Dental Medicine, Boys, Assiut, Al-Azhar University.

Email: [Dr.nourhossam@gmail.com](mailto:Dr.nourhossam@gmail.com)

**Mohamed Mahgob AlAshmawy**

Assistant Professor of Oral and Maxillofacial Surgery Faculty of Dental Medicine, Boys, Assiut, Al-Azhar University.

Email: [Mohamedalashmawy.46@azhar.edu.egy](mailto:Mohamedalashmawy.46@azhar.edu.egy)

**Abdelaziz Baiomy Abdullah**

Faculty of Dental Medicine, Boys, Assiut, Al-Azhar University

Email: [Abdelazizbaiomy@azhar.edu.eg](mailto:Abdelazizbaiomy@azhar.edu.eg)

**Mohamed Ashraf Abdel Fattah**

Faculty of Dental Medicine, Boys, Assiut, Al-Azhar University

Email: [dr\\_m\\_ashraf87@yahoo.com](mailto:dr_m_ashraf87@yahoo.com)

**Ali Ali Tawfik Abdo**

Faculty of Dental Medicine, Boys, Assiut, Al-Azhar University

Email: [alystar2005@yahoo.com](mailto:alystar2005@yahoo.com)

**Abstract**--Objectives: Comparing osseodensification vs. ridge splitting techniques in dental implant placement regarding implant stability, insertion torque, bone width and density. Patients and Method: Twenty individuals with a narrow ridge width of 3-6 mm at crestal bone level were included in this study. They were divided into two groups: Group I Osseodensification technique, Group II Ridge splitting technique with bone expanders and sticky bone augmentation. Implant stability, insertion torque, surgical procedure duration, bone width, and density were all evaluated by CBCT. Results: Group (I) had showed higher statistically significant Insertion torque than group (II). While group (II) had showed statistically significant increase in mean ISQ reading after 6 months ( $p < 0.001$ ). Group (II) showed statistically significant higher surgical time than group (I). Group (II) showed a higher increase in bone gain than group (I). Group (I) had showed statistically significant increase in mean bone density postoperatively, after 3 and 6 months ( $p < 0.001^*$ ). While group (II) had showed statistically significant increase in mean bone density postoperatively, after 3 and 6 months ( $p < 0.001$ ). Conclusion: Osseodensification technique had been shown to increase ridge width while maintaining primary implant stability and bone density around dental implants without sacrificing bone.

**Keywords**--Narrow Alveolar, Ossiodensification Ridge Splitting, bone expanders, Dental Implant.

## Introduction

Following tooth loss, bone resorption occurred four times more frequently in mandible than in maxilla.<sup>(1)</sup> Throughout course of 4 to 12 months after tooth extraction. Buccolingual crestal bone breadth decreased from 3.1 to 5.9 mm (about 50% of its previous width). The alterations in dimension were more noticeable in molar than premolar areas, and they were even more noticeable in mandible than maxilla. <sup>(2)</sup> Using a typical surgical technique, a minimum of 6 to 7 mm of bone width was required for implant with a diameter of 3.5 to 4 mm. For a predictable result, a minimum bone width of 1 to 1.5 mm was necessary on both buccal and lingual sides. <sup>(3)</sup> Alveolar ridge augmentation had been done using a variety of techniques, including guided bone regeneration, distraction osteogenesis, onlay block grafting, and ridge splitting. <sup>(4)</sup>

GBR was a well-documented treatment for atrophic alveolar ridge augmentations. Significant disadvantages of this procedure were relatively long healing period and potential of membrane exposure, which might result in bone loss or implant failure. <sup>(5)</sup> Predictable autogenous bone transplants can be collected from intraoral or extraoral locations.<sup>(6)</sup> However, bone grafting techniques were linked to complications such as donor site morbidity, a protracted period of healing before implant implantation, and graft resorption. <sup>(7)</sup>

Ridge splitting procedure, as opposed to guided bone regeneration or bone grafting, allowed for simultaneous implant insertion, removed the need for bone harvesting,

and decrease danger of graft or membrane exposure. As a result, treatment time was shortened in half and morbidity was lowered. <sup>(8, 9)</sup>

Osseodensification technique was a revolutionary non-subtractive drilling method in which specially constructed drills moved in a counterclockwise manner compacting bone at osteotomy walls, allowing more intimate contact of the implant with osteotomy site, and boosting primary stability.<sup>(10)</sup> Because bone matrix cells and biochemicals were kept in place and autografted along surface of the osteotomy site, maintaining and preserving bone during osteotomy preparation increased primary stability, which led to increased bone to implant contact, implant secondary stability and improve healing process. <sup>(11)</sup> The aim of this study was to evaluate and compare between mandibular alveolar ridge expansion with osseodensification versus ridge splitting techniques with bone expanders and sticky bone augmentation supplemented by immediate implant placement at both groups.

### **Patients and method**

This study was designed as a randomized clinical trial of 30 implants over 20 patients with missing mandibular posterior teeth seeking for receiving dental implants. They were selected from Outpatient clinic of Oral and Maxillofacial Surgery Department, Faculty of Dental Medicine, Al-Azhar University, Assiut Branch.

#### **Inclusion criteria**

1. Patient's age was  $\geq$  18 years old including both genders.
2. Healed long span edentulous area was selected in mandible for at least 6 months after extraction.
3. Patients who had an alveolar ridge with sufficient horizontal dimensions 3-6 mm width bucco-lingually and vertical dimensions were minimum of 10 mm height.
4. Mandibular posterior regions with low bone density (D3-D4 bone density according to Misch's <sup>(12)</sup> bone classification) based on CBCT findings.

#### **Exclusion criteria**

1. Presence of acute or chronic infection or local pathological condition at proposed implant zone.
2. Mandibular posterior regions with high bone density (D1 and D2 bone density according to Misch's <sup>(12)</sup> bone classification) depending on CBCT findings.
3. Patients with parafunctional habits such as severe bruxism and clenching.
4. Any local or systemic limitation that interfere with implant placement.

### **Grouping**

**Group (I)**, 10 patients with partial edentulous narrow mandibular ridges were treated by piezosurgery horizontal crestal cut with no vertical cuts, supplemented by osseodensification technique with simultaneous implant placement into their ridges.

**Group (II)**, 10 patients with partial edentulous narrow mandibular ridges were treated by piezosurgery ridge splitting technique as horizontal crestal cut with two

vertical cuts and serial hand bone expanders then implant placement into their ridges supplemented by sticky bone and membrane coverage.

#### Assessment:

- **Clinical parameters**
  - ISQ reading.
  - Insertion torque (N/cm).
  - Duration (min).
- **Radiographic parameters**
  - Horizontal bone gain in CBCT (mm).
  - Bone density (HU).

#### Group I: Osseodensification group:

After exposing alveolar crest, an osteotomy was prepared at desired implant placement area, a pilot drill (1.8 mm) was rotated at 800 RPM in a clockwise rotation (CW) to desired depth utilizing a high-speed surgical handpiece and a surgical motor to depth determined within approximately 2 mm from mandibular canal. A horizontal crestal ridge cut was done using Piezosurgery. US1 0.5-0.6 mm thickness tip to allow further buccal plate flexibility with no vertical cuts.

Osseodensification technique was utilized using Densah® Bur VT1525 2.0-mm running in a non-cutting counterclockwise (CCW) direction at 1200 RPM (Densifying Mode) with a bouncing motion to expand osteotomy then increase bur size by manufacturer's protocols until desired implant diameter to be equal or slightly wider (up to 0.7 mm wider) than initial ridge width without any bone dehiscence.

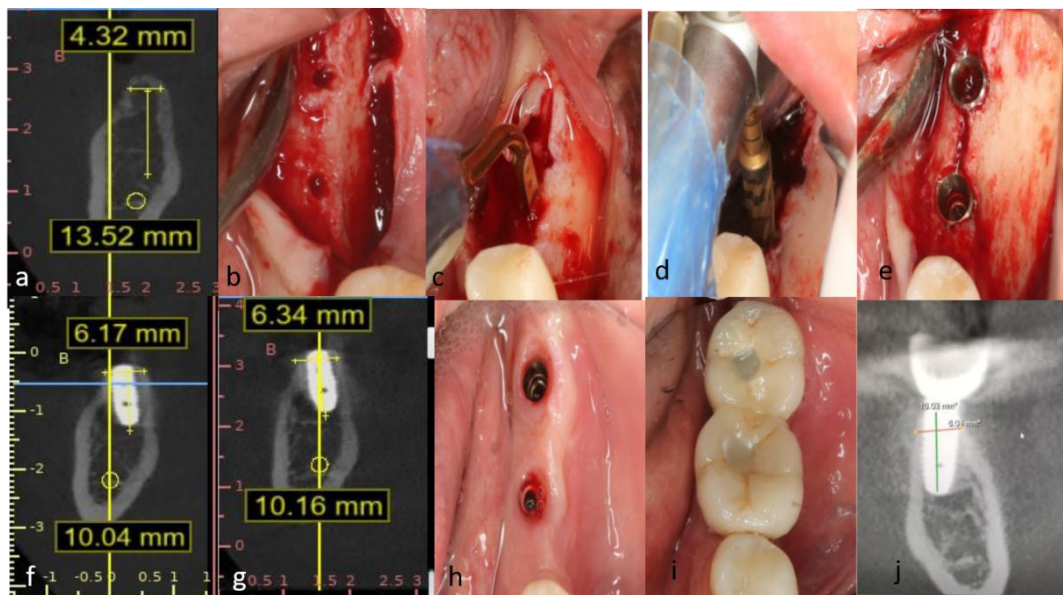


Figure (1): a, initial widths and lengths of alveolar ridge, b, pilot drill osteotomy, c, horizontal crestal ridge cutting with Piezosurgery, d, osseodensification drill at implant site., e, implant in desired site, f, bone widths and lengths of alveolar

bone 3 months postoperatively, g, bone widths and lengths of alveolar 6 months postoperatively, h, healing abutment removal, I, porcelain fused to metal bridge delivery, j, bone widths and lengths of alveolar bone after delivery.

### **Group II: Ridge Splitting group:**

Osteotomies were done using piezoelectric device which consisted of one horizontal crestal cut, mesial and distal vertical cuts under copious sterile saline irrigation; horizontal crestal cut was made in alveolar ridge by US 1 tip while mesial vertical cut was made by US1 (Left or Right) and at least two millimeters from tooth mesial to site of surgery, and posterior cut was made by US1 (Left or Right) and should be located few millimeters distal to future position of last implant.

Two vertical cuts at periphery of crestal cut were made to reach cancellous bone; drilling at target site of implant placement with pilot drill (1.8 mm) rotated at 800 RPM in a clockwise rotation to desired depth utilizing a high-speed surgical handpiece and a surgical motor to determined depth. Then Bone Expander screws were inserted serially to reach desired measured diameter to allow prober implant placement that was at least 2mm from inferior alveolar nerve bundle. Implant was inserted according to manufacture company then hard tissue grafting in form of sticky bone and collagenous membrane were utilized to augment bone around implant and filling gap created between buccal and lingual plates.

### **Sticky bone preparation**

Before surgery, 10 mL of peripheral venous blood was drawn. Blood was deposited in 15 mL laboratory plain plastic tube that was pretreated with 2ml, 3.8% tri-sodium citrate. Tube was centrifuged at 3500 rpm at room temperature for 8 minutes in centrifuge device. After centrifugation, blood was separated into two layers with cellular components remaining at bottom of tube and plasmatic component above. The inferior half which was darker in color of the latter was collected and stored in a sterile metal container. Plasma Rich in Growth Factors was mixed with xenografts powder and calcium chloride which left for 5-10 minutes for polymerization to produce sticky bone graft.

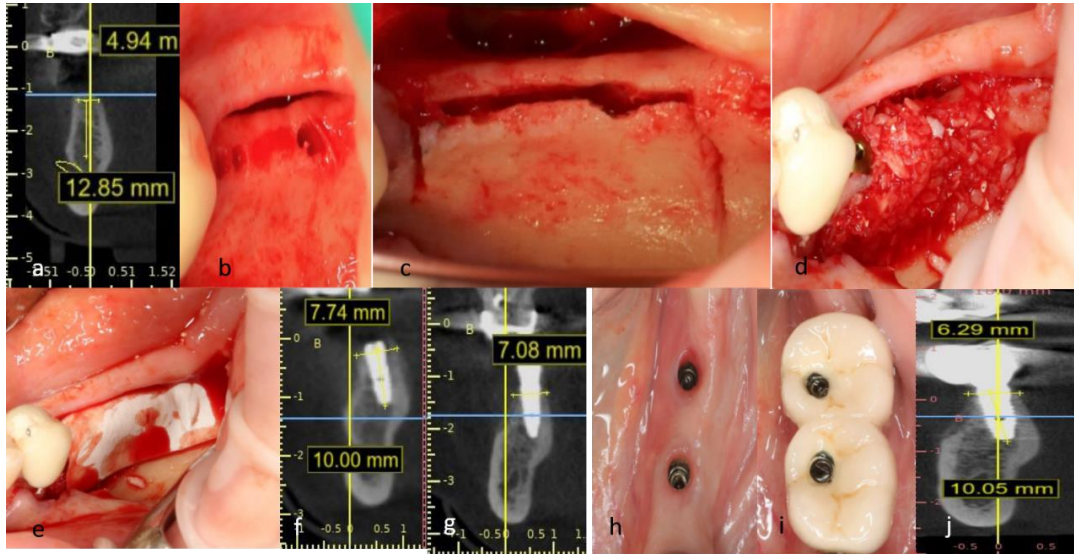


Figure (2): a, initial widths and lengths of alveolar ridge, b, pilot drill osteotomy, c, horizontal crestal ridge cutting with Piezosurgery, d, sticky bone in place, e, collagen membrane over sticky bone, f, bone widths and lengths of alveolar bone 3 months postoperatively, g, bone widths and lengths of alveolar 6 months postoperatively, h, healing abutment removal, I, porcelain fused to metal bridge delivery, g, bone widths and lengths of alveolar bone after delivery.

## Follow up and data collection

### I. Clinical parameters:

#### 1. Implant stability quotient (ISQ):

All implants were evaluated for primary stability once after implant insertion with an Osstell®

a magnetic resonance device, which uses resonance frequency analysis for determining implant stability and another measurement after six months at second surgical phase.

#### 2. Insertion Torque:

Insertion torque in Newton/Centimeter (N/cm) for each Implant was recorded using a manual calibrated torque gauge ratchet to place implant in its final position and at that instance, maximum final torque applied was noted on torque gauge scale and recorded to make database.

#### 3. Duration of surgical procedure:

Duration of surgical procedure was documented and recorded for each surgical procedure in minutes (min) from incision to suturing.

### II. Radiographic parameters:

CBCT radiographic examinations were performed immediately after surgery, 3, 6 months postoperatively. This had included measurements of alveolar ridge width, recording bone density value around implants, crestal bone loss as well as detection of possible injury to inferior alveolar nerve and/or peri-implantitis.

#### **4. Measuring of horizontal bone gain & loss:**

The reference-plane for horizontal bone gain measurement was determined by bone-level crestal plane of inserted implants in cross sectional view of CBCT. From this reference-plane both buccal and lingual bone level of each implant was measured in millimeters on day of implant placement (immediate) and on follow-up visits at 3 and 6 months.

#### **5. Measuring of bone density:**

Change in bone density around implant was measured in Hounsfield units using BlueSky Bio®. (software) (HU). On buccal, lingual, mesial, and distal sides of implant, measurement sites were positioned at top, middle, and apical parts. Average density was calculated using mean values of bone density along each side of the implant. This procedure was carried out at each postoperative follow-up interval (immediate, 3 and 6 months).

#### **Prosthetic phase:**

Following a second surgical exposure six months after implant placement, gingival formers were placed for 1-2 weeks to establish proper gingival shape at implants' collar region. Impression was taken using open tray impression technique with implant impression coupling and implant analogues. Porcelain fused to metal screw retained crowns were delivered to all patients for both groups and abutments were screwed to implants with a torque of 35 N/cm, and implants were functionally loaded. Patients were instructed about maintenance of oral hygiene by means of dental floss, interdental brush, and mouth wash.

#### **Statistical analysis of data:**

Shapiro-Wilk test was used to verify normality of distribution. Quantitative data were described in mean, standard deviation was judged at the 5% level. Student t-test for normally distributed quantitative variables, to compare between two studied groups.

#### **Results**

Regarding Initial, there was a statistically a significant difference between two groups ( $p < 0.001^*$ ). Group (I) Ossiodensification had showed a statistically a significant higher ISQ reading than Group (II) Ridge splitting. After 6 months, there was a statistically a significant difference between groups ( $p < 0.015^*$ ). Table (1).

There was a statistically a significant difference between two groups ( $p < 0.001^*$ ). Group (I) Ossiodensification had showed a statistically a significant higher Insertion torque than Group (II) Ridge splitting Table (1). There was a statistically a significant difference between groups ( $p < 0.001^*$ ). Ossiodensification had showed a statistically a significant lower Duration than Ridge splitting Table (1).

Regarding Initial horizontal bone gain, Postoperatively, after 3 months and 6 months, there was a statistically non- significant difference between two groups ( $p = 0.217, 0.201, 0.288$  respectively). Regarding Increase from Initial, there was a statistically a significant difference. Ridge splitting Group (II) showed a higher Increase from Initial than Ossiodensification Group (I) Postoperatively and after 3 months ( $p = 0.023^*, 0.041$ ) Table (1).

Regarding Initial bone density, Postoperative, after 3 months and 6 months there was a statistically non-significant difference between groups ( $p=0.176$ ,  $0.792$ ,  $0.824$  respectively). Regarding Increase from Initial, there was a statistically significant difference. Ossi densification Group (I) had showed a higher Increase from Initial than Ridge splitting Postoperatively and after 3-months ( $p=0.023^*$ ,  $0.041$ ) Table (1).

Table (1): Comparison between the two studied groups according to ISQ reading

	Ossi densification (n = 10)	Ridge splitting (n = 10)	t	p
Age (years)	34.80 ± 3.36	35.0 ± 4.35	t= 0.115	0.910
Sex				
Male	2 (20.0)	0 (0.0%)	x <sup>2</sup> = 2.222	FEp= 0.474
Female	8 (80.0)	10 (100.0)		
ISQ reading				
Initial	73.70 ± 5.79	39.0 ± 6.15	12.991*	<0.001*
After 6 months	77.0 ± 6.06	70.90 ± 3.78	2.701*	0.015*
Increase from Initial				
After 6 months	3.30 ± 9.72	31.90 ± 7.08	7.505*	<0.001*
Insertion torque	43.50 ± 4.12	24.50 ± 8.96	6.094*	<0.001*
Duration (min)	24.20 ± 1.75	62.50 ± 7.17	16.413*	<0.001*
Horizontal bone gain in CBCT				
Initial	4.61 ± 0.40	4.32 ± 0.60	1.279	0.217
Postoperative	6.77 ± 0.95	7.24 ± 0.58	1.337	0.201
After 3 months	6.71 ± 0.91	7.09 ± 0.60	1.100	0.288
After 6 months	6.60 ± 0.95	6.95 ± 0.61	0.975	0.345
Increase from Initial				
Postoperative	2.16 ± 0.67	2.92 ± 0.69	2.488*	0.023*
After 3 months	2.10 ± 0.65	2.77 ± 0.71	2.203*	0.041*
After 6 months	1.99 ± 0.68	2.63 ± 0.74	2.010	0.060
Density				
Initial	408.8 ± 116.3	487.0 ± 131.2	1.410	0.176
Postoperative	682.0 ± 66.93	668.6 ± 142.1	0.270	0.792
After 3 months	766.2 ± 94.70	775.4 ± 87.26	0.226	0.824
After 6 months	853.5 ± 68.22	865.8 ± 82.90	0.362	0.721
Increase from Initial				
Postoperative	273.2 ± 69.0	181.6 ± 113.7	2.179*	0.043*
After 3 months	357.4 ± 58.50	288.4 ± 85.21	2.111*	0.049*
After 6 months	444.7 ± 66.57	378.8 ± 99.39	1.742	0.099

Data was expressed using Mean ± SD.

t: Student t-test

p: p value for comparing between two studied groups

\*: Statistically significant at  $p \leq 0.05$

## Discussion

In this study, we had compared osseodensification with ridge splitting procedures using bone expanders, sticky bone, platelet-rich growth factors, and collagen membrane covering on mandibular alveolar ridge. The risk of bone resorption of laterally out displaced buccal bone wall was a major disadvantage of alveolar bone splitting.<sup>(13)</sup> In our current study, we had used xenograft mixed with plasma rich in growth factor to make a sticky bone graft with a barrier membrane to achieve greater bone width. There was a statistically significant difference in ridge splitting after 3 and 6 months ( $p < 0.001^*$ ). Platelets had long been recognized to produce large amounts of growth factors, which had promoted cell proliferation, matrix remodeling, and angiogenesis.<sup>(14)</sup> Sticky bone was a physiologically cemented bone transplant encased in a fibrin web. Growth factors were to assist body in repairing itself by stimulating stem cells to regenerate new tissues.<sup>(15)</sup>

The key benefits of piezoelectric tool were its ability to cut mineralized tissues precisely, as well as its ability to inflict less tissue damage, resulting in better recovery.<sup>(16)</sup> We had obtained a favorable outcome with piezosurgery in crestal ridge splitting that was supplemented by rapid implant placement in our study, which was consistent with Blus et al.<sup>(17)</sup> who had a successful result with ridge splitting and fast implant insertion in mandible without problems. Huwais's<sup>(10)</sup> osseodensification drills had a particularly constructed form that compacted bone along osteotomy walls in a counterclockwise orientation, allowing more intimate interaction of implant with osteotomy site and boosting primary stability. This was matched with our findings, which revealed that group (I) better in primary stability than group (II).

In current investigation, intraoperatively, osseodensification group (I) had revealed a significant difference at ISQ reading than ridge splitting group II. After 6 months, there was a statistically significant difference ( $p < 0.015^*$ ) across two groups, with osseodensification group (I) having a statistically significant higher ISQ reading than ridge splitting group (II). This was explained due to compaction auto-grafting and related spring-back effect, osseodensification group (I) was demonstrated to improve implant primary stability by increasing bone-to-implant contact following implant insertion. This autografted bone particles had worked as a core for quicker bone development surrounding implant, potentially reducing healing time.<sup>(18)</sup>

Insertion torque had showed a statistically significant difference between two groups ( $p < 0.001^*$ ). at group I (osseodensification) was statistically significantly greater than group II (ridge splitting). This agreed with Inchingolo et al.<sup>(19)</sup> who had compared osseodensification to conventional drilling and had found that osseodensification had higher insertion and removal torque, increased primary and secondary stability, higher bone-to-implant contact, and higher bone volume around implants. This positive outcome was made possible by drills designed to have many lands with large negative rake angles that had worked as noncutting edges to expand the bone.<sup>(20)</sup>

In this study, osseodensification group I had demonstrated a statistically significant increase in average bone density at 3, 6 months postoperatively

( $p < 0.001$ ). In their animal investigation, Huwais and Meyer<sup>(10)</sup> had founded that osseodensification enhanced bone density along osteotomy and generated a compaction autografted bone over whole depth of osteotomy bed, specially at apical region. In a 5-year retrospective clinical study, Huwais et al.<sup>(21)</sup> had founded that osseodensification technique increased bone density through compaction autografting and thus helped facilitate crestal sinus augmentation; however, ridge splitting group II showed a statistically significant increase in mean bone density after 3 and 6 months ( $p < 0.001$ ).

At first glance, we had founded no statistically significant difference between two investigated groups in terms of bone density ( $p = 0.369$ ). After 3 months, osseodensification group (I) exhibited a statistically significant difference ( $p = 0.001$ ) from ridge splitting group (II), indicating a greater bone density. After 6 months, osseodensification group I had higher density than ridge splitting group II ( $p = 0.002$ ).

This result could be explained by high bone-to-implant contact in osseodensification group I and the elasticity of cancellous bone, whereas in ridge splitting group II, implant gained primary stability from apical 2mm and remaining part was surrounded by grafted bone mixed with growth factors and a dynamic process that involved bone tissue modelling and remodeling. This was in consensus with Berglundh et al.<sup>(22)</sup> who reported that physiologic loss of implant stability during early osseous healing was linked to bone resorption, which was visible during the first weeks of healing, and that the resorbed bone was replaced with newly formed viable bone, indicating a transition of implant stability from mechanical anchorage to biological attachment, which was responsible for secondary stability.

In comparison between two studied groups according to horizontal bone width at CBCT there was a higher increase in ridge splitting group II than osseodensification group I regarding initial at postoperative and three months reading ( $p = 0.023$ ,  $0.041$ ). While at 6 months post operatively there was no significant difference between two groups regarding bone gain at CBCT ( $p = 0.345$ ). This result matched that of Bassetti M. et al.<sup>(23)</sup> who found a 2.5 mm increase in bone width using a ridge splitting approach with rapid implant implantation and particulate bone graft.

Osseodensification group (I) had a statistically significant shorter duration time than ridge splitting group II in this investigation. This agreed with Fugazzotto PA.<sup>(24)</sup> who noted various advantages over the traditional delayed technique, including a single surgical operation, a shorter total treatment period, and greater patient satisfaction.

## **Conclusion**

The fact that both groups' implants survived had demonstrated that osseodensification and ridge splitting with bone expanders were effective methods for narrow alveolar bone expansion. Osseodensification had been shown to enhance ridge width while maintaining primary implant stability and bone density around dental implants without sacrificing bone. Piezo-surgery was a successful

procedure with little bone loss. Sticky bone with platelets rich in growth factors had improved bone integration around dental implant significantly.

## References

1. Akbarov, A. N., & Xabilov, D. N. U. (2021). The condition of the oral cavity in patients who have had a viral infection COVID-19. *International Journal of Health & Medical Sciences*, 4(4), 381-383. <https://doi.org/10.21744/ijhms.v4n4.1796>
2. Al-Johany SS, Al Amri MD, Alsaeed S, Alalola B. Dental Implant Length and Diameter: A Proposed Classification Scheme. *Journal of Prosthodontics*. 2017;26(3):252-60.
3. Araújo MG, Lindhe J. Ridge alterations following tooth extraction with and without flap elevation: an experimental study in the dog. *Clin Oral Implants Res*. 2009;20(6):545-9.
4. Bassetti MA, Bassetti RG, Bosshardt DD. The alveolar ridge splitting/expansion technique: a systematic review. *Clin Oral Implants Res*. 2016;27(3):310-24.
5. Bassetti R, Bassetti M, Mericske-Stern R, Enkling N. Piezoelectric alveolar ridge-splitting technique with simultaneous implant placement: a cohort study with 2-year radiographic results. *Int J Oral Maxillofac Implants*. 2013;28(6):1570-80.
6. Berglundh T, Abrahamsson I, Lang NP, Lindhe J. De novo alveolar bone formation adjacent to endosseous implants. *Clin Oral Implants Res*. 2003;14(3):251-62.
7. Blus C, Szmukler-Moncler S, Vozza I, Rispoli L, Polastri C. Split-crest and immediate implant placement with ultrasonic bone surgery (piezosurgery): 3-year follow-up of 180 treated implant sites. *Quintessence Int*. 2010;41(6):463-9.
8. Chiapasco M, Abati S, Romeo E, Vogel G. Clinical outcome of autogenous bone blocks or guided bone regeneration with e-PTFE membranes for the reconstruction of narrow edentulous ridges. *Clin Oral Implants Res*. 1999;10(4):278-88.
9. Emami E, de Souza RF, Kabawat M, Feine JS. The Impact of Edentulism on Oral and General Health. *Int J Dent*. 2013;2013:498305.
10. Fugazzotto PA. Implant placement at the time of mandibular molar extraction: description of technique and preliminary results of 341 cases. *J Periodontol*. 2008;79(4):737-47.
11. Han JY, Shin SI, Herr Y, Kwon YH, Chung JH. The effects of bone grafting material and a collagen membrane in the ridge splitting technique: an experimental study in dogs. *Clin Oral Implants Res*. 2011;22(12):1391-8.
12. Huwais S, Mazor Z, Ioannou AL, Gluckman H, Neiva R. A Multicenter Retrospective Clinical Study with Up-to-5-Year Follow-up Utilizing a Method that Enhances Bone Density and Allows for Transcrestal Sinus Augmentation Through Compaction Grafting. *Int J Oral Maxillofac Implants*. 2018;33(6):1305-11.

13. Huwais S, Meyer EG. A Novel Osseous Densification Approach in Implant Osteotomy Preparation to Increase Biomechanical Primary Stability, Bone Mineral Density, and Bone-to-Implant Contact. *Int J Oral Maxillofac Implants*. 2017;32(1):27-36.
14. Inchingolo AD, Inchingolo AM, Bordea IR, Xhajanka E, Romeo DM, Romeo M, et al. The Effectiveness of Osseodensification Drilling Protocol for Implant Site Osteotomy: A Systematic Review of the Literature and Meta-Analysis. *Materials (Basel)*. 2021;14(5).
15. Koo S, Dibart S, Weber HP. Ridge-splitting technique with simultaneous implant placement. *Compend Contin Educ Dent*. 2008;29(2):106-10.
16. Machtei EE. The effect of membrane exposure on the outcome of regenerative procedures in humans: a meta-analysis. *J Periodontol*. 2001;72(4):512-6.
17. Misch CE, Perel ML, Wang HL, Sammartino G, Galindo-Moreno P, Trisi P, et al. Implant success, survival, and failure: the International Congress of Oral Implantologists (ICOI) Pisa Consensus Conference. *Implant Dent*. 2008;17(1):5-15.
18. Pai UY, Rodrigues SJ, Talreja KS, Mundathaje M. Osseodensification - A novel approach in implant dentistry. *J Indian Prosthodont Soc*. 2018;18(3):196-200.
19. Pavlíková G, Foltán R, Horká M, Hanzelka T, Borunská H, Sedý J. Piezosurgery in oral and maxillofacial surgery. *Int J Oral Maxillofac Surg*. 2011;40(5):451-7.
20. Piccinini M. Mandibular bone expansion technique in conjunction with root form implants: a case report. *J Oral Maxillofac Surg*. 2009;67(9):1931-6.
21. Podaropoulos L. Increasing the Stability of Dental Implants: the Concept of Osseodensification. *Balkan Journal of Dental Medicine*. 2017;21.
22. Schwartz-Arad D, Levin L, Sigal L. Surgical success of intraoral autogenous block onlay bone grafting for alveolar ridge augmentation. *Implant Dent*. 2005;14(2):131-8.
23. Solakoglu Ö, Heydecke G, Amiri N, Anitua E. The use of plasma rich in growth factors (PRGF) in guided tissue regeneration and guided bone regeneration. A review of histological, immunohistochemical, histomorphometrical, radiological and clinical results in humans. *Ann Anat*. 2020;231:151528.
24. Suryasa, I. W., Rodríguez-Gámez, M., & Koldoris, T. (2022). Post-pandemic health and its sustainability: Educational situation. *International Journal of Health Sciences*, 6(1), i-v. <https://doi.org/10.53730/ijhs.v6n1.5949>
25. Taschieri S, Corbella S, Del Fabbro M. Use of plasma rich in growth factor for schneiderian membrane management during maxillary sinus augmentation procedure. *J Oral Implantol*. 2012;38(5):621-7.
26. Trisi P, Berardini M, Falco A, Podaliri Vulpiani M. New Osseodensification Implant Site Preparation Method to Increase Bone Density in Low-Density Bone: In Vivo Evaluation in Sheep. *Implant Dent*. 2016;25(1):24-31.