

**How to Cite:**

Abdo, A. A. T., Mahmoud, A. A. F., Abdullah, A. A. B., AlAshmawy, M. M., Ali, H. E. M., Ahmed, O. E. F. M. S., & Fattah, M. A. A. (2022). Yang's keyhole plate versus conventional plate for treatment of mandibular sub-condylar fractures: Clinical and radiographic evaluation. *International Journal of Health Sciences*, 6(S9), 404–411. <https://doi.org/10.53730/ijhs.v6nS9.12292>

# Yang's keyhole plate versus conventional plate for treatment of mandibular sub-condylar fractures: Clinical and radiographic evaluation

**Ali Ali Tawfik Abdo**

BDS (2009) G. MSc 2016 G, Dentist, Ministry of health.

Email: [alystar2005@yahoo.com](mailto:alystar2005@yahoo.com)

**Ashraf Abdel Fattah Mahmoud**

Professor of Oral and Maxillofacial Surgery Faculty of Dental Medicine, Boys, Assiut, Al-Azhar University.

Email: [Ashraf10102002@yahoo.com](mailto:Ashraf10102002@yahoo.com)

**Abdel Aziz Baiomy Abdullah**

Assistant Professor of Oral and Maxillofacial Surgery Faculty of Dental Medicine, Boys, Assiut, Al-Azhar University.

Email: [Abdelazizbaiomy@azhar.edu.eg](mailto:Abdelazizbaiomy@azhar.edu.eg)

**Mohamed Mahgob AlAshmawy**

Assistant Professor of Oral and Maxillofacial Surgery Faculty of Dental Medicine, Boys, Assiut, Al-Azhar University.

Email: [Mohamedalashmawy.46@azhar.edu.egy](mailto:Mohamedalashmawy.46@azhar.edu.egy)

**Hossam Eldin Mohammed Ali**

Faculty of Dental Medicine, Boys, Assiut, Al-Azhar University

Email: [Dr.nourhossam@gmail.com](mailto:Dr.nourhossam@gmail.com)

**Omar El Farouk Mossad Sadek Ahmed**

Faculty of Dental Medicine, Boys, Assiut, Al-Azhar University

Email: [dromarelfarouk@gmail.com](mailto:dromarelfarouk@gmail.com)

**Mohamed Ashraf Abdel Fattah**

Faculty of Dental Medicine, Boys, Assiut, Al-Azhar University

Email: [dr\\_m\\_ashraf87@yahoo.com](mailto:dr_m_ashraf87@yahoo.com)

**Abstract**--Objectives: The use of a keyhole plate vs two miniplates in the treatment of mandibular subcondylar fractures. Materials and methods: Twenty patients were randomized into two equal groups. Ten patients with subcondylar fractures were treated with two Yang's keyhole plates in Group I. Ten patients with subcondylar fractures

were treated with two conventional miniplates in Group II. Maximum mouth opening (MMO), Protrusive excursive movement, Lateral excursive movement, and Time for reduction and fixation were all used to evaluate patients clinically vertical height of ramus, and antero-posterior condylar angulation are all measured radiographically. Results: There was a statistically non-significant difference between the study and control groups at all intervals regarding MMO, Protrusive excursive movement, Lateral excursive movement, vertical height of the ramus, antero-posterior condylar angulation, but was significant at time for reduction and fixation. Conclusion: reducing a mandibular condylar fracture using a YK-plate, the results were similar and the operating time was quicker than when utilizing a traditional mini plate fixation.

**Keywords**---sub-condylar fractures, Yang's Keyhole Plate, miniplates.

## **Introduction**

Subcondylar fractures account for up to 45 percent of all mandibular fractures. The treatment of mandibular condylar fractures, on the other hand, is still a point of contention in maxillofacial surgery. (1) Closed reduction, which may entail up to 6 weeks of intermaxillary fixation (IMF) and intense physiotherapy. In patients with condylar injuries treated in a closed manner, long-term consequences include discomfort, arthritis, malocclusion, mandibular deviation during opening and closing motions, temporomandibular joint (TMJ) dysfunction, facial asymmetry, and decreased posterior facial height (2,3), as well as ankylosis. (4-6) There has been an increasing interest in using direct fixation with an open approach that allows for anatomical fragment reduction to achieve a speedier return to normal function. (7, 8)

When a bone segment is precisely physically reduced, most plates now on the market are known to be associated with little difference in prognosis. (9,10) However, in certain people, these miniplates are difficult to accurately fit to the bone segment, and bone fragment reduction and fixation at subcondylar fracture locations requires an extra-oral incision and an endoscope. Miniplates are difficult to utilise in the subcondylar area, therefore surgical outcomes are sensitive and highly dependant on the surgeon. (11, 12). The YK plate, unlike other plates, includes a range of hole sizes, allowing for a simple attaching mechanism. As a consequence, patients with subcondylar and angle fractures of the mandible can be treated with a smaller incision than with other plate systems when using the YK plate. Furthermore, the initial screw introduced can be utilised as an anchor screw, making surgery more convenient (13). A keyhole plate was compared to two miniplates in the treatment of extracapsular mandibular subcondylar fractures.

## **Subjects and Methods**

Twenty patients (16 males and 4 females) with extracapsular subcondylar fracture were recruited from the outpatient clinic of the Faculty of Dental

Medicine Al-Azhar University's Oral and Maxillofacial Surgery department (Assiut Branch). All patients signed an informed consent form before surgery, and the Al-Azhar ethics committee authorised the study (number/year).

***Inclusion criteria:***

- Patients free from conditions contraindicating surgery.
- Patients from 18-40 years.
- Patients sub-condylar fracture indicated for open reduction.

***Exclusion Criteria***

- Infected fracture site.
- Patients with systemic bone diseases.

***Study sample:***

Patients were be divided randomly into 2 groups using online software (<https://www.randomizer.org>). Group I: consisted of ten patients with sub condylar fracture treated with 2 yang's keyhole plates. Group II: consisted of ten patients with subcondylar fracture were treated with two standard miniplates.

***Operative Procedure***

Following anaesthetic induction, the fracture was exposed, the IMF was secured to ensure appropriate occlusion. The retromandibular method was a viable option. A 1 cm posterior and parallel to the posterior edge of the mandible's ramus incision was created. The parotid gland retreated superiorly and anteriorly after skin incision. The masseter muscle was being stripped from the ramus to disclose the fracture site during subcutaneous dissection. Fractured segments were reduced into normal position by inserting stainless steel wire (0.5) in Basel region of angle to function as a distraction of ramus exposing area of condyle, then adapting plate and drilling screw holes with surgical drill (1.8 mm diameter) under continual saline irrigation.

Two Yang's key hole plates were used to fix the broken condyle in Group I.

Group II: The broken condyle was fixed with two miniplates, one on the ramus's posterior border and the other parallel to the mandibular notch.

The occlusion was checked before IMF was removed.

The extraoral wound was closed using polyglycolic polylactic 3-0 suture material\* for deep layers and 4-0 polypropylene suture material\*\* for skin layer.

***Postoperative care***

Each patient received intravenous \*\*\*unasyn 1.5 gm/12 hours for one day postoperatively followed by Amoxicillin/Clavulanate potassium \*\*\* \* 1 gm twice daily for the next 5 days.

***Assessment:***

- Clinical
  - MMO
  - Protrusive and Lateral excursive movement
  - Time for reduction and fixation
- Radiographic
  - Vertical height of ramus

- Antero-posterior condylar angulation

### Statistical analysis of the data

Quantitative data were described using mean, standard deviation. Significance of obtained results was judged at 5% level. Student t-test for normally distributed quantitative variables, to compare between two studied groups was used.

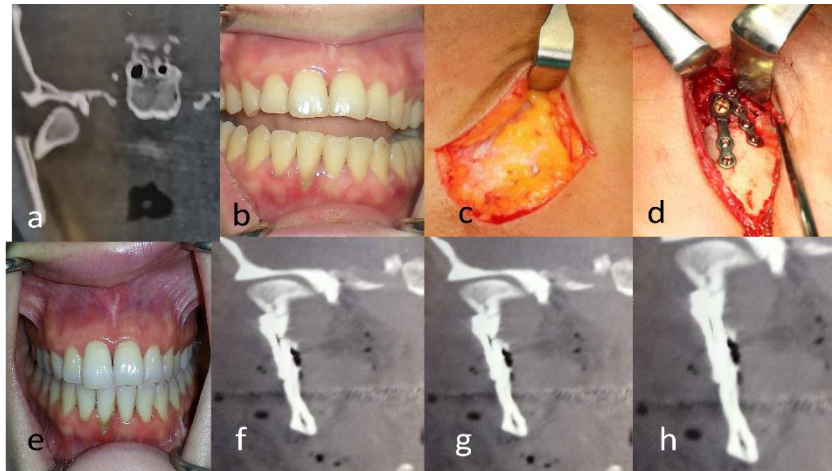


Figure (1): a, Preoperative 3D C.T showing right medially displaced of subcondylar fracture, b, preoperative occlusion, c, Retromandibular incision, d, Reduction and Fixation by yang key hole plate with fixation by two yang key hole plat, e, Postoperative occlusion after 3 months, f, C.T postoperatively coronal cut, g, after 3 months, and h, after 6 months.

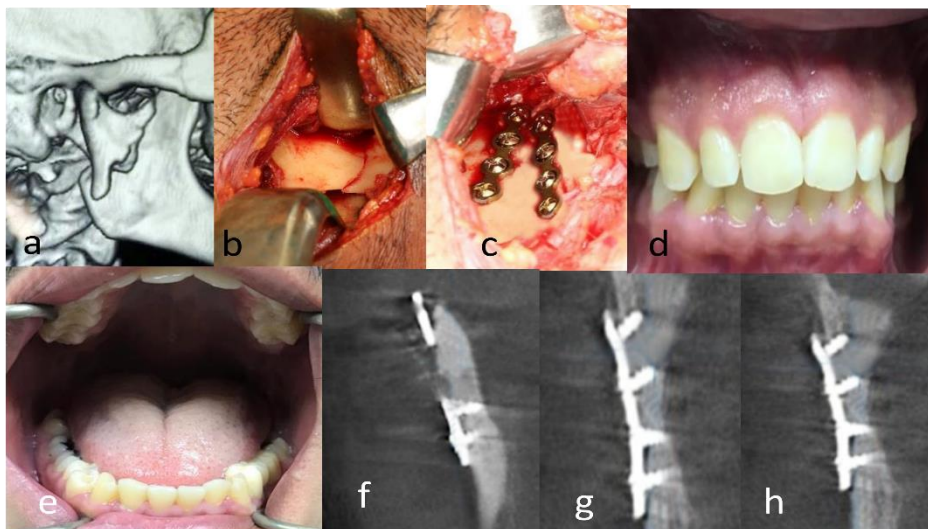


Figure (2): a, Preoperative 3D C.T showing lateral displacement of subcondylar fracture, b, Reduction of fracture segments after surgical exposure c, fixation by two conventional plate, d, Postoperative occlusion after 3 months, e, MMO after 6 months, f, C.T postoperatively coronal cut, g, after 3 months, and h, after 6 months.

## Results

At 1<sup>st</sup> week, 3<sup>rd</sup> week, 3<sup>rd</sup> month, and 6<sup>th</sup> month, there was a statistically non-significant difference between study and control groups regarding MMO (p=0.431, 0.380, 0.182, 0.526 respectively). At 1<sup>st</sup> week, 3<sup>rd</sup> week, 3<sup>rd</sup> month, and 6<sup>th</sup> month, there was a statistically non-significant difference between study and control groups regarding protrusive excursive movement (p=0.241, 0.199, 1.000, and 0.525 respectively) At 1<sup>st</sup> week, 3<sup>rd</sup> week, 3<sup>rd</sup> month, and 6<sup>th</sup> month, there was a statistically non-significant difference between study and control groups regarding lateral excursive movement (p=0.809, 0.291, 0.848, and 1.000 respectively).

At Immediate, 1<sup>st</sup> month, 3<sup>rd</sup> month, and 6<sup>th</sup> month, there was a statistically non-significant difference between study and control groups regarding vertical height of ramus (p=0.360, 0.379, 0.379, and 0.379 respectively). At Immediate, 1<sup>st</sup> month, 3<sup>rd</sup> month, and 6<sup>th</sup> month, there was a statistically non-significant difference between study and control groups regarding antero-posterior condylar angulation (p=0.604, 0.593, 0.593, and 0.593 respectively). There was statistically a significant difference between study and control groups (p<0.001\*). Study group showed a lower Time for reduction and fixation than control group.

Table (1) Comparison between two studied groups according to MMO, Protrusive excursive movement, Lateral excursive movement, vertical height of the ramus, antero-posterior condylar angulation, and time for reduction and fixation

	Study	Control	p
MMO			
1 <sup>st</sup> week	22.20 ± 2.82	21.0 ± 3.77	0.431
3 <sup>rd</sup> week	30.40 ± 2.01	29.70 ± 1.42	0.380
3 <sup>rd</sup> month	35.60 ± 3.20	33.70 ± 2.91	0.182
6 <sup>th</sup> month	39.10 ± 1.66	38.50 ± 2.42	0.526
Protrusive excursive movement			
1 <sup>st</sup> week	3.40 ± 0.84	3.90 ± 0.99	0.241
3 <sup>rd</sup> week	5.70 ± 1.16	6.30 ± 0.82	0.199
3 <sup>rd</sup> month	8.20 ± 1.23	8.20 ± 0.92	1.000
6 <sup>th</sup> month	8.60 ± 1.26	8.90 ± 0.74	0.525
Lateral excursive movement			
1 <sup>st</sup> week	4.40 ± 0.84	4.50 ± 0.97	0.809
3 <sup>rd</sup> week	7.10 ± 1.20	6.50 ± 1.27	0.291
3 <sup>rd</sup> month	9.20 ± 1.32	9.30 ± 0.95	0.848
6 <sup>th</sup> month	9.60 ± 0.84	9.60 ± 0.52	1.000
vertical height of the ramus			
Immediate	71.0 ± 7.06	67.30 ± 10.27	0.360
1 <sup>st</sup> month	70.59 ± 7.11	66.99 ± 10.37	0.379
3 <sup>rd</sup> month	70.59 ± 7.11	66.99 ± 10.37	0.379
6 <sup>th</sup> month	70.59 ± 7.11	66.99 ± 10.37	0.379
antero-posterior condylar angulation			

Immediate	29.90 ± 3.98	28.90 ± 4.48	0.604
1 <sup>st</sup> month	29.56 ± 4.04	28.52 ± 4.49	0.593
3 <sup>rd</sup> month	29.56 ± 4.04	28.52 ± 4.49	0.593
6 <sup>th</sup> month	29.56 ± 4.04	28.52 ± 4.49	0.593
Time for reduction and fixation	23.50 ± 2.46	31.10 ± 3.35	<0.001*

t: Student t-test

p: p value for comparing between two studied groups

\*: Statistically significant at  $p \leq 0.05$

## Discussion

In the present study, there was no statistically significant difference in MMO, protrusive excursive movement, lateral excursive movement, vertical height of the ramus, or antero-posterior condylar angulation. However, group (I) recovered faster and better than group (II), which was consistent with the findings of Woo et al (13). The newly created YK plate system may be used to treat subcondylar and angle fractures in the mandible, and it is easy to apply and utilize.

Cheon et al (14) looked at individuals who had been treated with a YK plate for mandibular fracture reduction. The YK plate technique had proven to be a reliable approach for obtaining stable occlusion, with no patient complaining of joint sickness or discomfort. This was consistent with our findings, which revealed that both groups had satisfactory occlusion at the end of the preliminary experiment with no statistically significant differences.

In the current study, patients in group (I) had an average MMO of  $22.20 \pm 2.82$  at the end of three weeks, which jumped to  $30.40 \pm 2.01$  at the end of three weeks, and reached a maximum level of  $35.60 \pm 3.20$  at three months, which was more evident in the findings compared to the control group. This was in line with Woo et al (13), who found similar results following a four-month follow-up in their trial. This was demonstrated in our study, where we found a greater improvement in MMO range after following patients for 6 months, with a reading of  $39.10 \pm 1.66$  mm in the study group.

Sufficient stability could be achieved by using a YK plate in a mandibular fracture, which could swiftly decrease the fracture bone segment and secure it to the correct position by inserting an anchor screw into a broad hole in the anterior section (11, 12). With a slight modification of the anterior hole, such as a sliding-plate, a YK-plate could be utilized to maintain condylar position, and fixation according to the positioning of an enlarged head screw.

The study group spent less time than the control group to decrease and mend. This was supported by the findings of woo et al (13), who looked at the clinical outcomes and surgical convenience of a newly developed Yang's Keyhole plate (YK plate) system for the treatment of mandibular subcondylar and angle fractures. The findings suggested that using the YK plate approach was more convenient and time-saving than using the 4-hole miniplate.

Kim et al (16) achieved a similar outcome, which was confirmed in our investigation, where we achieved appropriate stability and bone healing using the YK plate. Group (I) had a more accurate anatomical reduction of fractured bone than group (II), which was compared to the findings of Cheon et al (14), which found that Yang's key hole plate provided superior results to two plate fixations with easier application, lower cost, and shorter fixation time. In summary, while taking advantage of sliding-plate, the YK-plate was deemed to be easier to apply in clinical practise.

## References

1. Abdel-Galil K, Loukota R. Fractures of the mandibular condyle: evidence base and current concepts of management. *Br J Oral Maxillofac Surg* 2010;48:520–526.
2. Boyd N, John D, Lovald S. Clinical and FEA of low profile 3 D and parallel miniplates in fixation of mandibular symphysis and parasymphysis fracture. *J Maxillofacial Oral Surg* 2008;7:431-7.
3. Cheon KJ, Cho SW, Jang WS, Kim JW, Yang BE. Long-term Stability after Reduction of Mandible Fracture by Keyhole Plate: Evaluation at the Time of Plate Removal. *Maxillofac Plast Reconstr Surg*. 2020 Mar 16;42:6.
4. Danda AK, Muthusekhar MR, Narayanan V, Baig MF, Siddareddi A. Open versus closed treatment of unilateral subcondylar and condylar neck fractures: a prospective, randomized clinical study. *J Oral Maxillofac Surg* 2010; 68: 1238-1241.
5. Gassner R., Tuli T., Hachl O., Rudisch, A., Ulmer H .Cranio-maxillofacial trauma: a 10 year review of 9543 cases with 21067 injuries. *J Craniomaxillofac Surg* 2003; 31: 5-61.
6. Hakim SG, Wolf M, Wendlandt R, Kimmerle H, Sieg P, Jacobsen HC. Comparative biomechanical study on three miniplatesosteosynthesis systems for stabilisation of low condylar fractures of the mandible.*Br J Oral Maxillofac Surg*. 2014;52:317-22.
7. Kalfarentzos E, Desponia D, Georgios M, TyllianakisM. Biomechanical evaluation of plating technique for fixing mandibular angle fracture: The introduction of a new 3- D plate approach. *Oral Maxillofac Surg* 2009;13:139-44.
8. Khidoyatova, M. R., Kayumov, U. K., Inoyatova, F. K., Fozilov, K. G., Khamidullaeva, G. A., & Eshpulatov, A. S. (2022). Clinical status of patients with coronary artery disease post COVID-19. *International Journal of Health & Medical Sciences*, 5(1), 137-144. <https://doi.org/10.21744/ijhms.v5n1.1858>
9. Kim JW, Park KN, Lee CH, Kim YS, Kim YH, Yang BE. Finite Element Stress Analysis of Keyhole Plate System in Sagittal Split Ramus Osteotomy. *Sci Rep*. 2018;12;8:8971.
10. Kommers SC, van den Bergh B, Forouzanfar T: Quality of life after open versus closed treatment for mandibular condyle fractures: a review of literature. *J Craniomaxillofac Surg* 2013; 41: 221-225.
11. Loukota R. Endoscopically assisted reduction and fixation of condylar neck/base fractures—the learning curve. *Br J Oral Maxillofac Surg* 2006;44:480–481.
12. Perren Evolution of the internal fixation of long bone fractures. The scientific

- basis of biological internal fixation: choosing a new balance between stability and biology *J Bone Joint Surg Br.*, 84 (2002), 1093-1110.
13. Schmelzeisen R, Cienfuegos-Monroy. Patient benefit from endoscopically assisted fixation of condylar neck fractures--a randomized controlled trial. *J Oral Maxillofac Surg.* 2009;67:147-58.
  14. Schneider M1, Erasmus F, Gerlach KL, Kuhlisch E, Loukota RA, Rasse M, et al. Open reduction and internal fixation versus closed treatment and mandibulomaxillary fixation of fractures of the mandibular condylar process: a randomized, prospective, multicenter study with special evaluation of fracture level. *Br J Oral Maxillofac Surg* 2008;66:2537-44.
  15. Seemann R, Frerich B, Müller S, et al. Comparison of locking and nonlocking plates in the treatment of mandibular condyle fractures. *Oral Surg Oral Med Oral Pathol Oral Radiol* 2009;108:328-334.
  16. Shiju M, Rastogi S, Gupta P, Kukreja S, Thomas R, Bhugra AK, Parvatha Reddy M, Choudhury R. Fractures of the mandibular condyle--Open versus closed--A treatment dilemma. *J Craniomaxillofac Surg.* 2015;43:448-51.
  17. Suryasa, I. W., Rodríguez-Gómez, M., & Koldoris, T. (2021). Get vaccinated when it is your turn and follow the local guidelines. *International Journal of Health Sciences*, 5(3), x-xv. <https://doi.org/10.53730/ijhs.v5n3.2938>
  18. Woo IH, Kim JW, Kim JY, Yang BE. A New Method of Fixation With the Yang's Keyhole Plate System for the Treatment of Mandible Fractures. *J Craniofac Surg.* 2017;28:508-512.