

How to Cite:

Kalyankar, S., Sharma, A., Jadhav, A., Patil, R., Gujarathi, N., & Shelke, A. (2022). Comparative evaluation of efficacy of different endodontic file systems for removal of gutta percha from root canals using CBCT: An in-vitro study. *International Journal of Health Sciences*, 6(S8), 2724–2732. <https://doi.org/10.53730/ijhs.v6nS8.12334>

Comparative evaluation of efficacy of different endodontic file systems for removal of gutta percha from root canals using CBCT: An in-vitro study

Dr. Sailee Kalyankar

Post Graduate student, Department of Conservative Dentistry and Endodontics, Bharati Vidyapeeth (Deemed to be University) Dental college and hospital, Pune

Dr. Anupam Sharma

Professor and Head of the Department, Department of Conservative Dentistry and Endodontics, Bharati Vidyapeeth (Deemed to be University) Dental college and hospital, Pune

Dr. Aniket Jadhav

Associate Professor, Department of Conservative Dentistry and Endodontics, Bharati Vidyapeeth (Deemed to be University) Dental college and hospital, Pune

Dr. Rajlaxmi Patil

Assistant Professor, Department of Conservative Dentistry and Endodontics, Bharati Vidyapeeth (Deemed to be University) Dental college and hospital, Pune

Dr. Nirmitee Gujarathi

Assistant Professor, Department of Conservative Dentistry and Endodontics, Bharati Vidyapeeth (Deemed to be University) Dental college and hospital, Pune

Dr. Abhishek Shelke

Post Graduate student, Department of Conservative Dentistry and Endodontics, Bharati Vidyapeeth (Deemed to be University) Dental college and hospital, Pune

Abstract---Aim- To evaluate the removal of gutta percha by hand file system, rotary file system and reciprocating file system from root canals by using CBCT. Materials and Method: Root canals of 42 extracted human mandibular premolars were prepared using the ProTaper Universal rotary system and then obturated. Root filling quality was confirmed on CBCT images. Specimens were divided into 3 groups (n = 14) according to the system used for filling removal, group 1: H File, group 2: MTwo rotary retreatment file, and group 3: Wave One file. Each specimen was sent for CBCT Analysis.

Statistical Analysis Used: Evaluation of data was done statistically using One-way Analysis of Variance and Tukey's post hoc test. Results: There was statistical difference in all the groups ($P > 0.05$). All systems demonstrated presence of remnants of filling material. Mean reduction in the volume of GP after retreatment of Group I was 0.006mm^3 , Group II was 0.002mm^3 Group III was 0.003mm^3 . Conclusion: The system responsible for a better removal of root canal filling material was the MTwo Retreatment file system, followed by the WaveOne system and H File.

Keywords--endodontic retreatment, gutta percha, rotary instrumentation, reciprocating files, cone-beam computed tomography.

Introduction

The main goal of root canal treatment is to clean, shape and create a fluid tight seal between the endodontic sealer and gutta percha in the system. With an ever increasing number of endodontic treatments done each day, it has become imperative to minimize mistakes leading to endodontic failure. The common causes for failed root canal treatment are persistent intraradicular infection, unfilled or overfilled canals, incomplete cleaning and disinfection and untimely coronal restoration^[1]. There has been an increased emphasis on preservation of teeth, including those with failed root canal treatments. Nonsurgical RCT is usually preferred for such cases.^[2] So, the objective of retreatment should be to substantially reduce the microbial load from the root canal. Removing all the root filling material allows subsequent cleaning, shaping and filling of the root canal system.

The aim of this study was to compare hand, rotary and reciprocating instrument systems – H file, MTwo Retreatment rotary file, WaveOne Reciprocating file on the basis of efficacy in removing gutta-percha from the root canal during endodontic retreatment. Traditionally, hand files were used for retreatment. The use of rotary instruments reduces the fatigue and duration of endodontic retreatments^[3]. A rotary system named MTwo retreatment file system had been introduced into the market by VDW (Munich). It comprises R1 and R2 files that have cutting tips and constant helical angles. The WaveOne NiTi file system from Dentsply Maillefer is a single-use, single-file system to shape the root canal completely from start to finish. Reciprocating motion is similar to the balanced forces because their counter clockwise angle is greater than the clockwise movement and leads the file to continuously move towards the apex.^[4] This same technique is used to remove filling material from the root canals in a brushing motion.^[5] Radiographic and destructive methods are used for the evaluation of residual filling materials. For eliminating errors in measurement, Cone beam computed tomography was used in this study.

Materials and Methods

Specimen Preparation

All the specimens used in this study were obtained from Department of Oral and Maxillofacial Surgery, Bharati Vidyapeeth Dental College and Hospital, Pune. The study protocol was reviewed and approved by the Research Ethics Committee of the same institution. Forty-two extracted, intact single rooted permanent mandibular premolars were collected. Samples with completely formed apex having relatively straight roots were included in this study. Teeth with caries, cracks, previous restoration, curved roots, external resorption, internal resorption, open apex and calcified canals were excluded from this study. After extraction, the teeth were cleaned with an ultrasonic scaler. To standardize the working length of 15mm, all selected teeth were decoronated 2mm coronal to the cemento-enamel junction using a low speed diamond disk under copious water cooling. Access opening was done by using endoaccess bur. Patency of canals was confirmed by inserting size 10 K file (Mani, Japan) until the apical foramen was reached and the tip of the file was visible from apex. Both the working length and the reference point of each individual canal was recorded.

All the root canals were instrumented using the NiTi ProTaper Rotary system (Dentsply Maillefer). Initial preparation of each selected canal was done using hand K files. Files were inserted passively into the canal with a light watch-winding action and any force during filing was avoided. Each canal was enlarged upto 20 K file before insertion of Protaper Universal rotary system. The method of preparation was crown down technique. Coronal two-thirds of the canal were first pre-enlarged followed by preparing its apical one-third. According to manufacturer's instruction, all files were used at constant speed of 300 rpm and torque of 2N. S1 and S2 files were used to instrument the middle and apical thirds, and the canals were then finished using instruments F1, F2 until the working length was reached. At each instrument change, canals were irrigated with a 5.25% sodium hypochlorite (NaOCl) (Prime Dental products, India) solution using a total of 20 ml per specimen. After completion of root canal instrumentation, 17% EDTA (Prime Dental products, India) was applied for 3 minutes to remove the smear layer, and canals were irrigated again with 5 mL 5.25% NaOCl solution.

The root canals were obturated with gutta-percha (Dentsply) and AH plus (Dentsply) sealer. The selected master cone was coated with sealer and introduced into the root canal up to the working length. Lateral compaction was done by using spreader and accessory gutta-percha cones.^[16] The coronal part of root canal was sealed with temporary filling material. Teeth were embedded in modelling wax simulating shape of jaw and then root filling quality was confirmed on CBCT images. After obturation, the specimens were stored at 37°C and 100% humidity for 1 month to ensure the sealer was fully set^[14,15]

Root canal retreatment

The filled canals were randomly divided into three experimental groups (n = 14). The groups represented the 3 different filling material removal systems to be

applied - H File(Mani, Japan), MTwo retreatment rotary system(VDW) and WaveOne system (Dentsply Maillefer). Gates Glidden drills 1, 2, and 3 were used to remove 2mm of filling material from cervical part of all the specimens. After which retreatment was performed using three different systems with gutta-percha solvent RC Solve (Prime Dental Products, India).

Group 1 : Hand File system : Headstrom File

Insertion is easy due to no cutting edges and backward inclination of the edges. When the instrument was withdrawn, cutting took place and debris were carried away from the apex. They can only be used in traction motion because of their profile. File sequence used was ISO 10,15, 20, 25 with 25mm length and 2% taper. Root canals were irrigated.

Group 2: Rotary Retreatment System : MTwo Retreatment system

MTwo retreatment file R1 (15/.05 taper) and Mtwo R2 (size 25/.05 taper) instrument were used, using light apical pressure at a constant speed 350 rpm and torque 1.5 N as per manufacturer's recommendation. Root canals were irrigated after the use of each instrument with 5.25% NaOCl and saline (Otsuka Pharmaceutical India Pvt. Ltd., India).

Group 3 : Reciprocating System: WaveOne Reciprocating system

The retreatment procedure was performed with the WaveOne Primary file (tip size 25; variable taper) using the endomotor set at reciprocation mode. (170° counterclockwise and 50° clockwise). The instrument was advanced apically using an in-and-out pecking motion; gentle apical pressure was applied with a brushing action against the lateral walls. Following the retreatment procedures of all groups, the final irrigation protocol was: 2 mL of 17% EDTA, which was left in canal for 2 min for removal of intracanal smear layer, followed by 3 mL of 5.25% NaOCl and 1 mL of saline solution for 30 s. Then each specimen was dried with sterile absorbent points and sent for CBCT Analysis.

Filling removal evaluation

The roots were positioned in a custom made template of modelling wax in which they were aligned perpendicularly to the beam and were scanned before and after instrumentation using Planmeca CBCT scanner (Helsinki, Finland). Exposure parameters were, exposure time 3.0s, operating at 75kV and 2.0mA. The scan was done with a field of view of 8cm diameter and was 8cm high. The volumes of interest were then reconstructed with 0.260 mm isometric voxel size. Volumetric analysis was done using ITK-SNAP (Latest version 3.6) software. The CBCT images were obtained and converted into DICOM (Digital Imaging and Communications in Medicines) image format. These files were transferred into software, after which, a region of interest was selected by outlining the external margins of the filling at 3 to 5 zones along the entire length of the canal and volumes were measured in mm³ by semi-automatic segmentation procedure. In this manner volumetric analysis was done before and after removal of guttapercha.

Statistical analysis

Data obtained was entered and sorted in Microsoft Excel (v.2013). Statistical analysis was performed using Statistical package for social sciences (SPSS) software (v.21.0). Descriptive statistics was performed for post obturation and post retreatment assessment in different groups used in the study. Intragroup comparison between Post obturation and post retreatment was done for all the three groups using Paired t-test. Intergroup comparison of Post obturation and post retreatment was done between different groups using One-way Analysis of Variance (ANOVA) followed by Tukey's post hoc test to assess significant differences. All statistical tests were performed at 95% confidence intervals; keeping p value of less than 0.05 as statistically significant.

Results

All teeth examined exhibited some residual filling material within the canals. Mean reduction in the volume of GP after retreatment of Group I (H File) was 0.006mm^3 and for Group II (M Two) was 0.002mm^3 and for Group III (Wave One) was 0.003mm^3 (Table 1). Statistically significant difference ($P>.05$) was observed among the groups. MTwo showed the best results followed by WaveOne and Hfile.(Graph 1)

Discussion

Maximum removal of filling material directly hinges the success of endodontic retreatment. Retreatment is considered as a valid alternative for extraction in case of failure in endodontic treatment. The complete removal of root filling material is difficult, it is one of the main goals of nonsurgical endodontic retreatment procedure^[6]. Achievement of this goal can be measured by assessing the apical foramen, the action of endodontic instruments and irrigating solutions used during instrumentation. This procedure effectively eliminates the necrotic tissue and microorganisms from the remaining of canal^[7].

Although root canal anatomy varies widely, human single-rooted teeth were used in this study because of their ease of handling and simulation of treatment to reflect real endodontic practice as closely as possible. Working length standardization was done by removal of tooth crowns. Different methodologies have been reported to evaluate the amount of filling material remaining in the root canal after the retreatment procedure. It can be assessed by radiography,^[8] or by using a scoring system,^[9] longitudinal root splitting and linear measurement of the remaining gutta-percha and sealer. Three-dimensional visualization of the root canal system would provide a better understanding of the distribution of debris after retreatment. This technique gives detailed information about the morphological features without damaging the teeth or their surrounding tissue^[10] and hence CBCT evaluation was used in our study. Chemical solvents have been used to dissolve gutta-percha. Traditionally, chloroform was used as a popular solvent for gutta-percha removal owing to its ability to rapidly dissolve gutta-percha. However, due to its carcinogenic nature, use of chloroform has been discontinued. Hence, commercially available solvent, RC Solve (Prime Dental,

Mumbai), an orange oil derivative with the basic ingredient D-Limonene has been used in this study.

In the present study, all teeth showed residual filling materials, and none of the file systems could completely remove the filling material. Among the tested file systems, Mtwo retreatment files had maximum efficacy for removal of the filling material followed by WaveOne and H file. The maximum amount of residual filling material was recorded in Hedstrom file group. Mtwo Retreatment files had maximum efficacy for removal of filling material, because of the design and characteristic features of these files. They have cutting tip and a constant helical angle, which ensures the instrument's easy progression into the gutta-percha filling, without any need to exert pressure. The cutting blades form a vertical spiral, which provides better control and precise cutting through the canal^[10]. In the Mtwo file, the distance between cutting edges is increased from the tip of the instrument to the handle. The depth of the space designed for dentin removal is increased behind the blades, which provides the largest space for dentin removal and leads to more efficient gutta-percha and sealer removal.

Reciprocating systems produce a broader motion in the counterclockwise direction yet shorter in the clockwise direction, keeping the file more centered in the canal^[11]. This factor, together with the marked taper of these files, creates a greater contact area between the instrument and gutta-percha. Reciprocating systems were not originally designed for use in retreatment procedures; nevertheless, they have been found to be efficacious in the removal of filling material from the root canals, owing to its brushing motion against the lateral walls of the canal. The results of the present study revealed that none of the canals submitted to filling removal were completely devoid of residual guttapercha and sealer. This finding is consistent with previous studies ^{[12][13][17]}, which reported the virtual impossibility of removing 100% of the residual gutta-percha and sealer from root canal walls, irrespective of the technique used for filling material removal.

Conclusion

Within the limitations of this in vitro study following conclusions are drawn. There was no total removal of the root canal filling material regardless of the system used. Rotary and Reciprocating file system is more efficient than hand file system; The system responsible for a better removal of root canal filling material was the MTwo Retreatment file system, followed by the WaveOne system and H File.

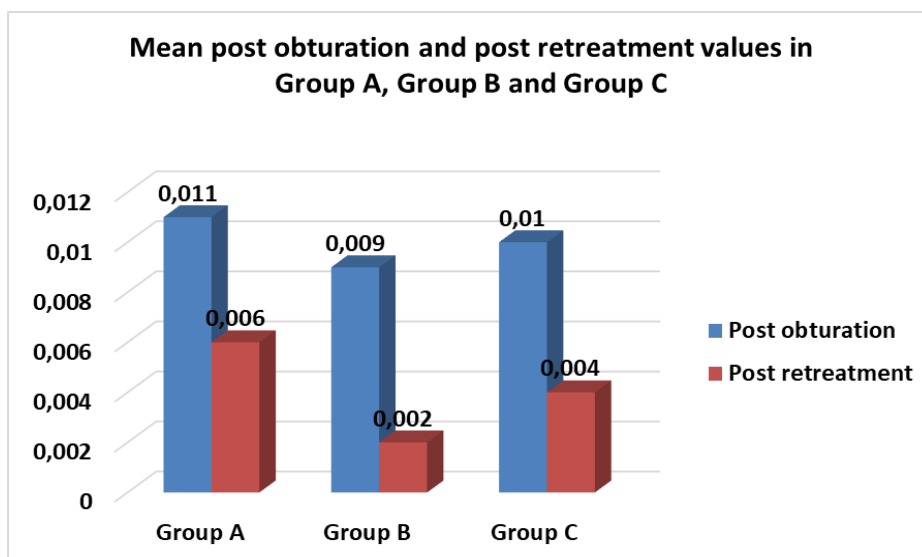
References

1. Akansha Garg¹ , Ajay Nagpal² , Shashit Shetty³ , Sunil Kumar⁴ , Kamal Krishan Singh⁵ , Amit garg. Comparison of Time Required by D-RaCe, R-Endo and Mtwo Instruments for Retreatment: An in vitro Study. Journal of Clinical and Diagnostic Research. 2015 Feb, Vol-9(2): ZC47-ZC49
2. B€urklein S, Hinschitzka K, Dammaschke T, et al. Shaping ability and cleaning effectiveness of two single-file systems in severely curved root canals

- of extracted teeth: Reciproc and WaveOne versus Mtwo and ProTaper. *Int Endod J* 2012;45:449–61.
3. Berutti E, Chiandussi G, Paolino DS, et al. Effect of canal length and curvature on working length alteration with WaveOne reciprocating files. *J Endod* 2011;37: 1687–90.
 4. Bramante CM, Fidelis NS, Assumpcao TS, et al. Heat release, time required, and cleaning ability of MTwo R and ProTaper universal retreatment systems in the removal of filling material. *J Endod* 2010;36:1870–3.
 5. Bueno CES, Delboni MG, Araujo RA, et al. Effectiveness of rotary and hand files in gutta-percha and sealer removal using chloroform or clorexidine gel. *Braz Dent J* 2006;17:139–43.
 6. Colombo AP, Fontana CE, Godoy A, De Martin AS, Kato AS, Rocha DG, Pelegrine RA, Bueno CE. Effectiveness of the waveone and ProTaper D systems for removing gutta-percha with or without a solvent. *Acta Odontológica Latinoamericana*. 2016 Dec;29(3):262-7.
 7. de Campos Fruchi L, Ordinola-Zapata R, Cavenago BC, Duarte MA, da Silveira Bueno CE, De Martin AS. Efficacy of reciprocating instruments for removing filling material in curved canals obturated with a single-cone technique: a micro-computed tomographic analysis. *Journal of endodontics*. 2014 Jul 1;40(7):1000-4. doi: 10.1016/j.jend.2014.05.029
 8. De Carvalho Maciel AC, Zaccaro Scelza MF. Efficacy of automated versus hand instrumentation during root canal retreatment: an ex vivo study. *Int Endod J* 2006 Oct;39(10):779-84.
 9. Glickman GN, Vogt MV: preparation for treatment. In: Cohen S, Hargraves KM. *Pathways of the pulp*, 10th Edition. Mosby, 2011: p.91. [5] Paik S, Sechrist C, Torabinejad M. Levels of evidence for the outcome of endodontic retreatment. *J Endod*. 2004;30(11):745-50.
 10. Hülsmann M, Stotz S. Efficacy, cleaning ability and safety of different devices for guttapercha removal in root canal retreatment. *Int Endod J* 1997 Jul;30(4):227-33.
 11. Kfir A, Tsesis I, Yakirevich E, Matalon S, Abramovitz I. The efficacy of five techniques for removing root filling material: microscopic versus radiographic evaluation. *Int Endod J*. 2012;45:35–41.
 12. Marfisi K, Mercade M, Plotino G, Duran- Sindreu F, Bueno R, Roig M. Efficacy of three different rotary files to remove gutta-percha and Resilon from root canals. *Int Endod J*. 2010 Nov;43(11):1022-8
 13. Pawar AM, Thakur B, Metzger Z, Kfir A, Pawar M. The efficacy of the Self-Adjusting File versus WaveOne in removal of root filling residue that remains in oval canals after the use of ProTaper retreatment files: A cone-beam computed tomography study. *Journal of conservative dentistry: JCD*. 2016 Jan;19(1):72.
 14. Pinto de Oliveira D, Vicente Baroni Barbizam J, Trope M, Teixeira FB. Comparison between gutta-percha and Resilon removal using two different techniques in endodontic retreatment. *J Endod*. 2006 Apr;32(4):362-4.
 15. Sjahrudin, H., Nugroho, B. S., Sembiring, T. B., Bangkara, B. A., & Fatmawati, E. (2022). The relevance of public knowledge and the degree of health: Public health literacy study. *International Journal of Health Sciences*, 6(1), 469–480. <https://doi.org/10.53730/ijhs.v6n1.4978>

16. Somma F, Cammarota G, Plotino G. Effectiveness of manual and mechanical instrumentation for the retreatment of three different root canal filling materials. *J Endod* 2008;34:466–9
17. Suandayani, N. K. T. ., Sutapa, G. N. ., & Kasmawan, I. G. A. . (2020). Quality control of X-rays with collimator and the beam alignment test tool. *International Journal of Physical Sciences and Engineering*, 4(3), 7–15. <https://doi.org/10.29332/ijpse.v4n3.468>
18. Suk M, Bago I, Katić M, Šnjarić D, Munitić MŠ, Anić I. The efficacy of photoninitiated photoacoustic streaming in the removal of calcium silicate-based filling remnants from the root canal after rotary retreatment. *Lasers in medical science*. 2017 Dec 1;32(9):2055-62.-rol 42
19. Widana, I.K., Sumetri, N.W., Sutapa, I.K., Suryasa, W. (2021). Anthropometric measures for better cardiovascular and musculoskeletal health. *Computer Applications in Engineering Education*, 29(3), 550–561. <https://doi.org/10.1002/cae.22202>
20. Wilcox LR, Krell KV, Madison S, Rittman B. Endodontic retreatment: evaluation of gutta-percha and sealer removal and canal instrumentation. *J Endod*. 1987;13:453-57
21. Xu LL, Zhang L, Zhou XD, et al. Residual filling material in dentinal tubules after gutta-percha removal observed with scanning electron microscopy. *J Endod* 2012;38:293–6.

Tables and graphs



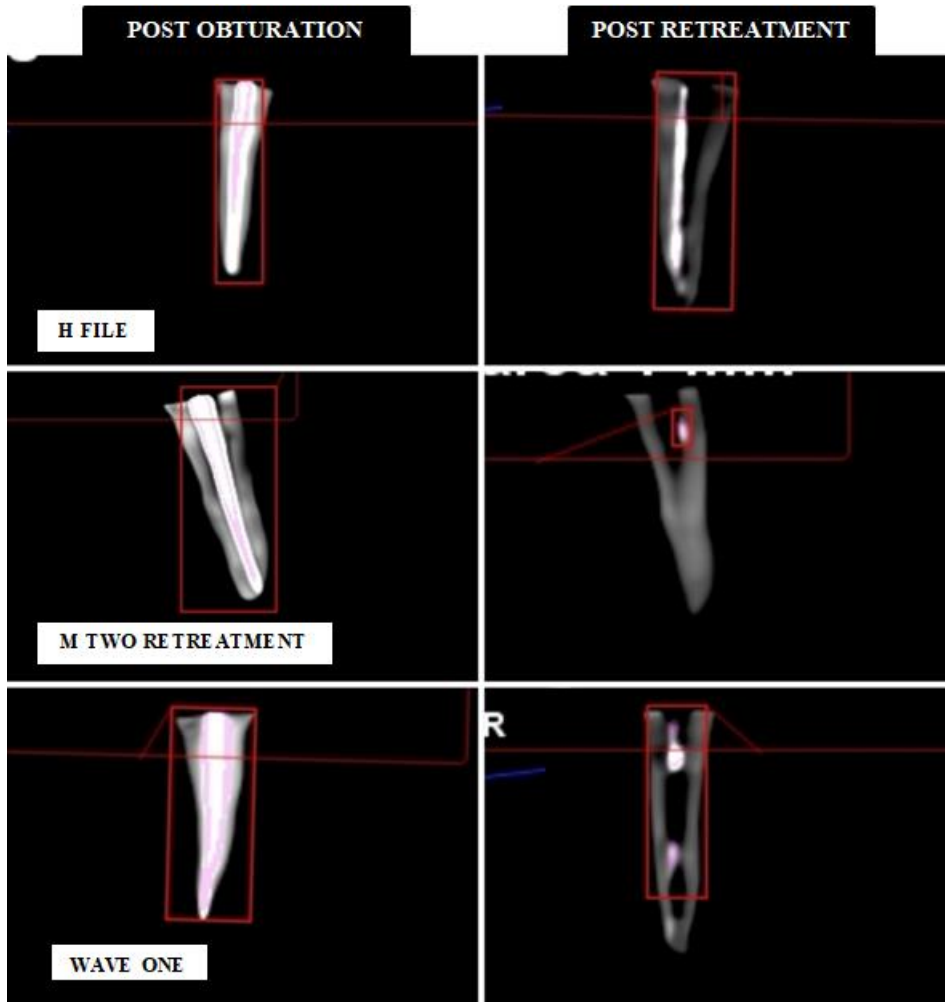
Graph 1 : Mean post obturation and post retreatment values in Group A, Group B, Group C

Table 1 :Descriptive statistics: Mean (SD) of Group A Group B, Group C at post obturation and post retreatment

Groups		N	Minimum	Maximum	Mean	Std. Deviation
Group A	Post obturation	14	.006	.022	.011	.005

	Post retreatment	14	.002	.018	.006	.004
Group B	Post obturation	14	0.005	0.013	0.009	0.002
	Post Retreatment	14	0.001	0.004	0.002	0.001
Group C	Post obturation	14	0.006	0.019	0.010	0.003
	Post retreatment	14	0.001	0.10	0.004	0.003

Image



H File, M Two, WaveOne file : Post obturation and post retreatment.