

How to Cite:

Kalyani, T., Yadav, Y., Rai, A. L., Shetty, D., & Kaul, N. (2022). Immunohistochemical evaluation of tumor angiogenesis and architectural changes in regional lymph nodes of oral squamous cell carcinoma (OSCC). *International Journal of Health Sciences*, 6(S9), 1621–1632.
<https://doi.org/10.53730/ijhs.v6nS9.12695>

Immunohistochemical evaluation of tumor angiogenesis and architectural changes in regional lymph nodes of oral squamous cell carcinoma (OSCC)

Thirumalaraju Kalyani

PhD Scholar, Department of Anatomy, Santosh Medical College Deemed to be University, Ghaziabad, UP.

Email: tkalyani1412@gmail.com

Yogesh Yadav

HOD & Professor, Department of Anatomy, Noida International Institute of Medical Sciences, Greater Noida, UP.

Email: yogeshyadav@msn.com

Anju Lata Rai

Professor, Department of Anatomy, ABVIMS, RML Hospital, New Delhi.

Corresponding author email: anjulata72@gmail.com

Devicharan Shetty

Dean, HOD & Professor, Department of Oral Pathology, ITS CDSR, Muradnagar, Delhi Meerut Road, Ghaziabad, UP.

Email: devicharanshetty@its.edu.in

Nisha Kaul

HOD & Professor, Department of Anatomy, Santosh Medical College, Deemed to be University, Ghaziabad.

Abstract---Aim: To evaluate the mean vascular area (MVA) and to correlate it with immunomorphological pattern of lymph nodes. Materials and Methods: A total of 50 positive OSCC cases (clinically and histopathologically diagnosed) from Santosh Medical College and I.T.S Dental college, ghaziabad were taken for the study. The lymph nodes collected were stained with routine hematoxylin & eosin and accessed for immunomorphological pattern. The sections were evaluated immunohistochemically by anti-von Willebrand factor (vWF) VIII to analyze the micro vessels in OSCC. Results: Three hundred and forty two lymph nodes were evaluated and the most predominant lymph node patterns were found to be Germinal Center Predominance

(37.43%). Our results showed a significant association between tumor node metastasis (TNM) staging, histopathological grading, and mean vascular area with lymph node reactivity pattern. Conclusion: There was an increase in angiogenesis with in different grades of OSCC and mean vascular area with morphological pattern of lymph nodes can be used as an additional parameter which would help in assessing prognosis and survival of the patient.

Keywords---Oral Squamous Cell Carcinoma, Germinal center Predominance, Lymphocyte predominance, Mean vascular area, Tumor node metastasis

Introduction

Oral squamous cell carcinoma (OSCC) is major public health problem in the Indian subcontinent, accounts for more than 90% of oral malignancies (Chandavarkar et al., 2014) There are many experimental and clinical data demonstrating that growth of this tumor is angiogenesis dependent (Folkman, 1990; Weidner, 1993)

Angiogenesis is mediated by angiogenic stimulating factors like vascular endothelial growth factor (VEGF), fibroblast growth factor-2 (FGF-2), transforming growth factor beta (TGF- β), hepatocyte growth factor, angiogenin, and anti-von willibrand factor (vWF) (Ribatti et al., 2001). The von Willebrand factor is synthesized by vascular endothelial cells and immunohistochemical detection of anti-vWF VIII has been used extensively to measure Mean vascular area/Mean vascular Density (MVA/MVD) to quantify angiogenesis in tumors (Mannucci, 1998).

With tumor progression, the cancer cells penetrate through lymphatic endothelial cell barrier and finally drain into regional lymph nodes (LN) leading to lymphadenopathy. Enlargement of LNs may be caused either by metastasis or immunological reactivity of LN in response to tumor-associated antigens (Ioachim and Mediros, 2009). The LN reactivity often leads to multitude of architectural changes in them. Assessment of the patterns of reactivity of the LN is thus, a reliable method to evaluate the host immune status and has been associated with the prognosis of the patient (Suchitra et al., 2015)

The LN reactivity patterns in relation to immunological function are sub-categorized by WHO (Cottier et al., 1972; Berlinger et al., 1976; Tsakraklides et al., 1973) as Lymph node Predominance (LP), Germinal Center Predominance (GCP), Sinus histocytosis (SH), Lymphocyte depletion (LD) and Unstimulated pattern (UP). There are many studies on OSCC induced lymph node reactivity pattern, but there is dearth of literature on correlation of immunomorphological changes in lymph node with vascularity of tumor. Hence, the aim of the present study was to evaluate angiogenetic activity in OSCC, by assessing MVA using vWF VIII as marker and to demonstrate its possible correlations with the lymph node reactivity pattern.

Materials and Methods

The present retrospective study includes 50 formalin-fixed and paraffin embedded tissue blocks of histologically proven different grades of OSCC and of all levels of related lymph nodes (n=342) ,5 normal palatine tonsil tissue was taken as control group. The samples were archived from November 2020 to December 2021. Ethical clearance was obtained from the Faculty Research and Ethical review committee.

- 1) Demographic data for age and sex as obtained from departmental case records were tabulated
- 2) Immunohistochemistry- A tissue section of 3 micron thickness were taken on poly-L-lysine coated glass slide for immunohistochemical staining with anti-factor VIII related antigen.

The sections were deparaffinized were then hydrated through descending grades of alcohol and antigen retrieval was done by using Proteolytic enzyme pepsin (BioGenex) for 40mins The sections were incubated with peroxidase blocking reagent for 10 minutes, followed by incubation with ready to use Factor VIII-Related antigen (Mouse monoclonal Antibody (Biogenex Pvt.Ltd) for 1 hour at room temperature. The slides were rinsed in PBS and super enhancer was applied for 20 mins. After that the slides were incubated in poly-HRP (anti-mouse and anti-rabbit secondary antibody) for 30mins.

Visualization of sections were performed using freshly prepared substrate DAB (3,3-diaminobenzidine) chromogen solution for 10 minutes. The presence of brown colour end product at the site of target antigen was indicative of immunoreactivity. The slides were rinsed with PBS, dipped in hematoxylin and washed in distilled water. Through ascending grades of alcohol the slides were passed, cleared in xylene and mounted with DPX.

- 3) Lymph node evaluation-3 micron thickness of representative tissue of lymph node block was obtained and stained with hematoxylin and eosin. A minimum of three sections were taken from LNs at different levels (Levels I-V) and were evaluated to confirm the predominant morphological Pattern.

Microvessel counting and morphometric assesment

The number of blood vessels were counted and assessed for morphometric parameter (area) using Magnus pro image analysis software in four different fields at 40x. Individual microvessels were marked along the outer border of endothelial cells of each blood vessel as “free hand area” and software generated results for each image were noted in millimeters.

Statistical analysis

The association of the variables which were qualitative in nature were analyzed using Chi-Square test. If any cell had an expected value of less than 5 then Fisher’s exact test was used. Spearman rank correlation coefficient and Anova test has been used for MVA. The data entry was done in the Microsoft EXCEL spreadsheet and the final analysis was done with the use of Statistical Package

for Social Sciences (SPSS) software, IBM manufacturer, Chicago, USA, version 21.0.

Results

Overall 342 lymph nodes were collected from 50 cases OSCCs and examined. Out of 50 cases 38 (76%) were male and 12 (24%) were female with age range from 30-80 years. The most common site in the present study was found to be highest in buccal mucosa (n=43 cases) followed by alveolar 4 and tongue 3. Based on clinical staging of OSCC Tumor Node Metastasis (TNM) the highest number of cases were observed in stage 4 (67.84%) followed by stage 3 (17.84%) and stage 2 (16%) (Table 1).

In the present study, well-differentiated OSCC, moderately differentiated OSCC and poorly differentiated OSCC accounted for 74.56%, 16.08% and 9.36% respectively (Table 2). All cases were divided into five groups according to the lymph node immunomorphological pattern out of which 84(24.56%) were lymphocyte predominance (Fig 1), 128(37.43%) lymph nodes showed germinal center predominance (Fig 2), 34(9.94%) showed sinus histiocytosis, 78 (22.81%) were lymphocyte depletion (Fig 3), and 18(5.26%) were unstimulated pattern. One way ANOVA test was applied on the results to compare the MVA in different grades of OSCC and p-value was found to be significant with LP, GCP and SH (p-value was < 0.05).in PDSCC cases (Table 3)

TNM staging and immunomorphological pattern

Sinus histiocytosis was significantly higher in stage IV and (p= 0.014). However Germinal center predominance which was highest in the cases of TNM stage III and IV of OSCC was statistically non-significant and (p value= 0.306). Overall association between TNM stage of primary tumor and the immunomorphological patterns was statistically significant p<0.001.(Table 1)

Table 1:-Statistical association between TNM staging and immunomorphological pattern

Reactivity pattern	Stage II (n=49)	Stage III (n=61)	Stage IV (n=232)	Total	P value
Lymphocyte predominance	14 (16.67%)	13 (15.48%)	57 (67.86%)	84 (100%)	0.679
Germinal center predominance	14 (10.94%)	26 (20.31%)	88 (68.75%)	128 (100%)	0.306
Sinus histiocytosis	0 (0%)	8 (23.53%)	26 (76.47%)	34 (100%)	0.014
Lymphocyte	17	14	47	78	0.091

depletion	(21.79%)	(17.95%)	(60.26%)	(100%)	
Unstimulated	4	0	14	18	
pattern	(22.22%)	(0%)	(77.78%)	(100%)	0.06

Histopathological grade of primary tumor and immunomorphological pattern:

Germinal center pattern was significantly higher in both WDSCC and MDSCC (p value = 0.005). However lymphocyte depletion pattern which was highest in WDSCC was statistically non-significant (p value= 0.772). Overall association between histopathological grade of primary tumor and immunomorphological pattern was statistically significant $p < 0.0001$. (Table 2)

Table 2:- Statistical association between histopathological grade of primary tumor and immunomorphological pattern

Reactivity pattern	WDSCC (n=255)	MDSCC (n=55)	PDSCC (n=32)	Total	P value
Lymphocyte predominance	58 (69.05%)	9 (10.71%)	17 (20.24%)	84 (100%)	0.0003
Germinal center predominance	95 (74.22%)	28 (21.88%)	5 (3.91%)	128 (100%)	0.005
Sinus histocytosis	30 (88.24%)	0 (0%)	4 (11.76%)	34 (100%)	0.006
Lymphocyte depletion	58 (74.36%)	14 (17.95%)	6 (7.69%)	78 (100%)	0.772
Unstimulated pattern	14 (77.78%)	4 (22.22%)	0 (0%)	18 (100%)	0.318

(WDSCC: well differentiated squamous cell carcinoma, MDSCC: moderately differentiated squamous cell carcinoma, PDSCC: poorly differentiated squamous cell carcinoma)

Mean vascular area with histopathological grade

A significant correlation was found between mean vascular area and grading (p value < 0.0001). The number of blood vessels was found to be increased from well-differentiated OSCC to poorly differentiated OSCC (Fig 4 and 5).

Mean vascular area and immunomorphological pattern:

The mean MVA was found to be highest in PDSCC in which most predominant pattern was found to be LP (3 cases, p-value=0.000), followed by GCP (1 case, p-value= 0.000), and SH (1 case, p-value=0.005) whereas mean MVA of LD (2 cases, p-value=0.133) and UP (1 case, p-value=0.626) was found to be highest in MDSCC. (Table 3)

Table 3: Statistical association between mean vascular area and immunomorphological pattern

Reactivity Pattern	No of OSCC Cases	Mean MVA WDOSCC	Mean MVA MDOSCC	Mean MVA PDOSCC	p-value
LP	13	560.39	55079.52	574518.22	0.000
GCP	16	516.93	1192.35	242927.05	0.000
SH	7	1455.47	0	10924.29	0.005
LD	10	581.77	567806.16	132597.43	0.133
UP	4	54139.53	115406.2	0	0.626

LP: Lymphocyte predominance, GCP: Germinal center predominance, SH: Sinus histiocytosis, LD: Lymphocyte depletion, UP: Unstimulated pattern

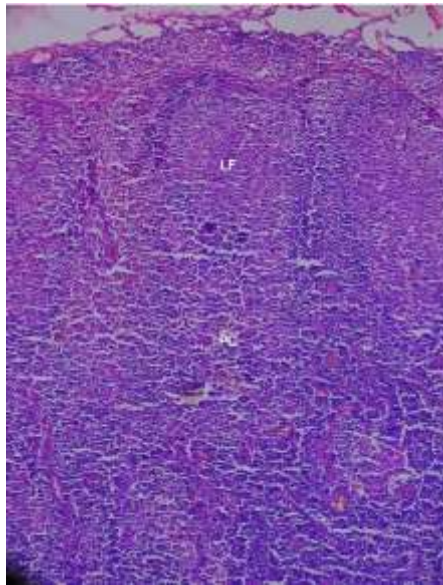


Figure1: Photomicrograph showing Lymphocyte predominant (H&E stain, x10)

Note: 1. Cortex shows lymphoid follicles (LF) without germinal centers and thin mantle layer

2. Increase number of small lymphocytes throughout Cortex, Para-cortical (PC) and Medullary regions

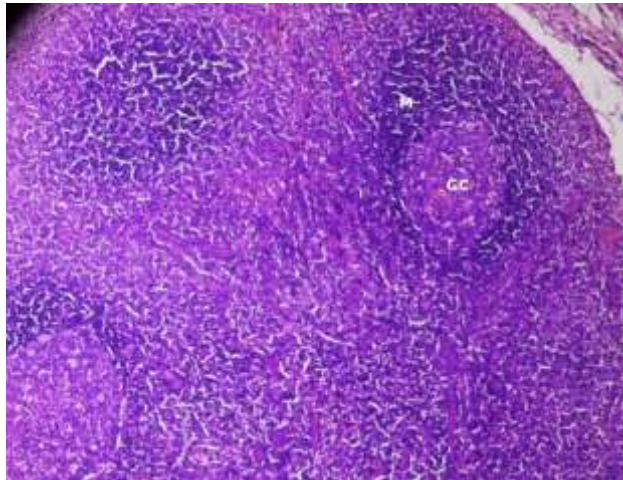


Figure 2: Photomicrograph showing Germinal Centre predominant (H&E stain, x10)

Note: 1. Germinal center (GC) contain large lymphoid cells and mitotic figures
2. Prominent mantle layer (M) and para-cortical area unremarkable

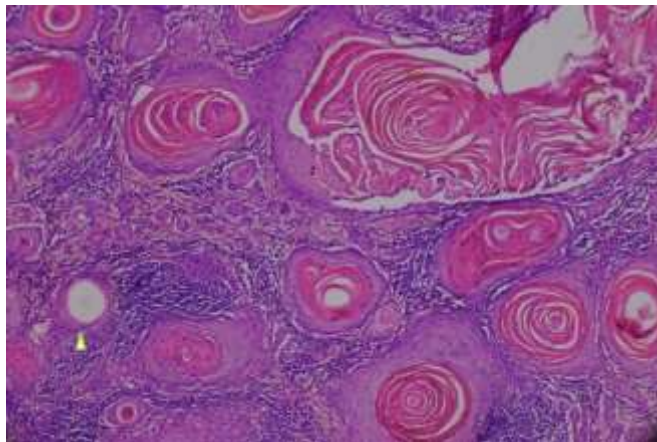


Figure 3: Photomicrograph showing lymphocyte depleted pattern (H&E stain, x10)

Note: 1. Small hyaline deposits on the wall of blood vessels of para-cortical area
2. Normal architecture of lymph node has been replaced by whorls of hyaline deposits

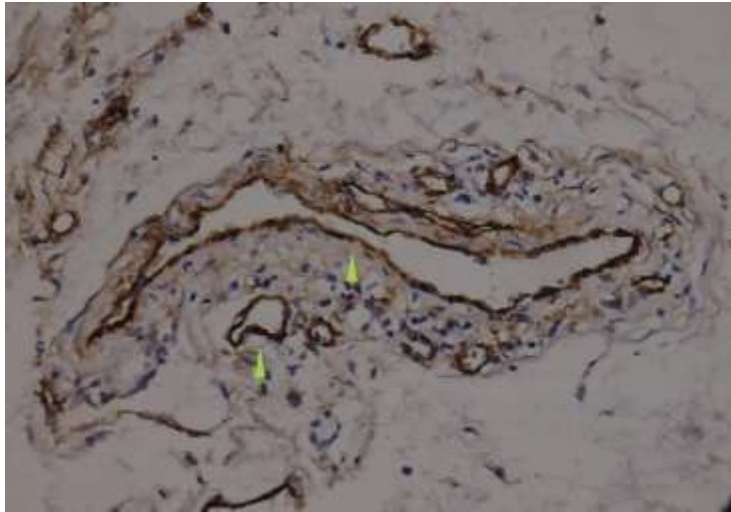


Figure 4:
Note: Light microscope view with yellow arrow mark showing number of vWF positive blood vessels in well differentiated squamous cell carcinoma (10x).

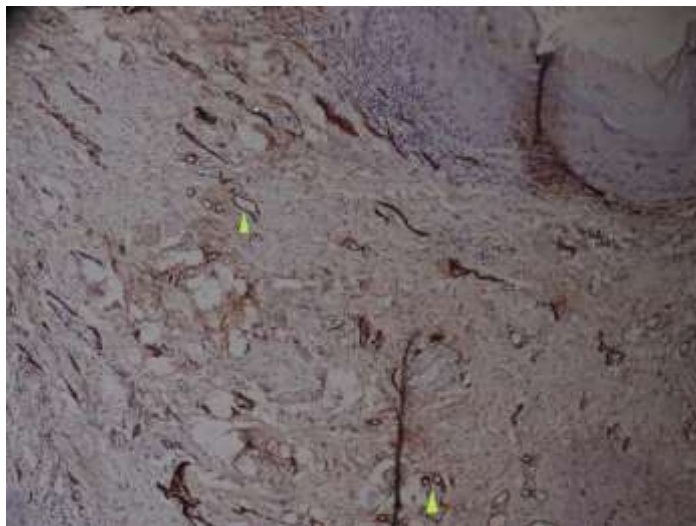


Figure 5
Note: Light microscope view with yellow arrow mark showing number of vWF positive blood vessels in poorly differentiated squamous cell carcinoma (10x)

Discussion

OSCC is usually associated with regional lymph node (LN) metastasis and tumor cells brings about certain morphological changes in the LN (Ioachim and Meiros, 2009). Earlier studies have shown angiogenesis aids in progression and metastasis of malignant tumors (Sharma et al., 2010; Iamaroon et al., 2003).The present study was taken up to observe the morphological changes occurring within the lymph node and to correlate them with TNM staging, histopathological grading and mean vascular area.

In the present study, 76% of OSCC cases were in male patients. This is in accordance with studies showing that tobacco intake which is a key causative agent, is higher among males (Chandavarkar et al., 2014). It is well believed that new blood vessels are recruited by secreting growth factors from tumor cells (Shieh et al., 2004) and micro vessel density has been extensively used to quantify angiogenesis (Weidner et al., 1991) observed a significant correlation between micro vasculature density and Ca Breast metastasis.

The most commonly utilized markers for evaluating micro vessel are VEGF, CD105, CD31, CD34, and vWF (Jahanshahi and Sabaghian, 2012; Kabiraj et al., 2018). MVA in the current study was evaluated immunohistochemically by using anti-factor VIII related antigen (vWF) as it has less nonspecific staining and better highlighting of vessels. and has the tendency to stain small, large and newly formed blood vessels (Kabiraj et al., 2018; Rubio et al., 2000).

In the present study MVA was found to be significantly higher in poorly differentiated squamous cell carcinoma (PDSCC) as compared to WDSCC and MDSCC indicating that vascularity increases with tumor progression. Several authors have reported the usefulness of angiogenesis evaluation as prognostic tool for assessment of patients and they have correlated it with histopathological grades of oral squamous cell carcinoma and have found significant results (Jaafari et al., 2010; Pujari et al., 2013; Kalra et al., 2012; Boas et al., 2013; Wadhwan et al., 2015).

Regional lymph nodes in OSCC not only act as anatomic barriers to the systemic dissemination of tumor but also participate in the primary immunological defense mechanism against tumors. This can be seen as change in cellular organization occurring within the node (Lores et al., 1998). OSCC is known to be associated with early deficiencies of cell-mediated immunity as well humoral immunity and evaluation of morphological patterns is not only a reliable method to assess the host immune status but is an useful indicator of the potential of the cancer cells to invade (Yadav et al., 2012; Raj et al., 2014). It is a well-known fact that patients exhibiting varied morphological patterns of lymph nodes have differing reactive response towards the tumour.

In the present study the most predominant reactivity pattern was found to be germinal center predominance (37.43%) followed by lymphocyte predominance (24.56%), lymphocyte depletion (22.81%), sinus histocytosis (9.94%) and unstimulated pattern (5.26%). The following patterns were also seen by previous authors. However some authors (Balla et al., 2020; Suchitra et al., 2015) observed LP as most predominant pattern followed by GCP, SH and LD. They have suggested LP pattern may be actively engaged in a cell-mediated immune response and with Germinal Center Predominance indicate a humoral response to antigenic stimuli. These mechanisms may prevent tumor metastasis to the regional lymph nodes (Raj et al., 2014)

Acharya et al., 2019 however apart from aforementioned patterns have also assessed vascular transformation of sinuses (VTS) and granulomatous reaction (GR). The most predominant pattern in her study was VTS followed by GCP, LP, LD, SH and GR. Similar to our study Vidyadevi et al., 2014 in her study observed GCP (79.27%) as predominant pattern.

Absence of stage I cases in this study might be due to delayed reporting of patients to hospitals and late presentation of symptoms. While correlating individual immunomorphological pattern with TNM staging, a significant association was seen only with sinus histiocytosis ($p < 0.014$) but not with other patterns (Table 1). Hence our findings supports the fact that the presence of SH indicates more advanced stage of carcinoma (Ioachim and Medeiros, 2009). It is also being associated with the poorer patient prognosis and Tumour invasion (Bhatlawande et al., 2019) Of the 255 nodes harvested from WDSCC cases in the present study (Table 2), 74.22% ($p < 0.005$) LNs showed GCP pattern, 69% lymphocyte predominance ($p < 0.0003$). Suchitra et al., 2015 in their study on OSCC correlated LP with survival rate and found to have a significant association with mortality and improved 5 year survival rate. Both GCP and LP lymph node reactivity showed to be a better prognostic factor Some investigators found GCP to be more common in metastatic cases and overall 5 year survival rate with this pattern is somewhat less when compared to LP (Berlinger et al., 1976).

In an attempt to derive corerelation between the pattern of lymph node reactivity and MVA the mean MVA was found to be highest in PDSCC in which most predominant pattern was found to be LP followed by GCP, SH ($p < 0.05$) (Table 3). Of all the cases of oscc 13 cases showed LP pattern irrespective of metastatic status indicating increase in vascularity of OSCCs do not predict the regional LN metastasis, thereby confirming OSCC spread through lymphatic vessels (Shieh et al., 2004; Weidner et al., 1991). Previous studies have observed tumor progression may aid in release of antigens which can bring a typical immune response in the LN and LP and GCP are early immunological response to antigenic insult. With metastasis LP is replaced by SH and LD pattern and these changes may help to determine disease prognosis (Bhatlawande et al., 2019)

There is insufficient literature on individual morphological pattern of lymph node associating with TNM staging, Grading and MVA. Assessment of these parameters can be utilized in classifying the OSCC as high-risk and low-risk cases and planning various therapeutic strategies.

Conclusion

The evaluation of Lymph node reactivity intends to ultimately determine the host immune response facing a malignancy. More extensive studies on morphological patterns and their correlation with angiogenesis are required to elucidate their role in patient prognosis and survival.

Acknowledgement

I am very grateful to Dr. Nikita Gulati, Reader, who helped in standardizing the immunohistochemistry protocol and Mr Rajkumar technician in the department of oral pathology I.T.S Center for Dental Studies and Research, Muradnagar, Ghaziabad and Ms Bhawna Garg, statistician for statistical analysis.

References

1. Acharya, S., Kumari, N., Srivastava, P., Arnold, D., and Nikhil, K.(2019). Architectural changes in regional lymph nodes of oral squamous cell

- carcinoma. *J Oral Maxillofac Pathol*, 23(2), 305.
2. Balla, H., Uppala, D., Majumdar, S., Kotina, S., Kodati, S., and Namana, M. (2020). Evaluation of immunomorphological patterns of cervical lymph nodes in oral squamous cell carcinoma. *J Oral Maxillofac Pathol*, 24(2), 285-292.
 3. Berlinger, N.T., Tsakraklides, V., Pollak, K., Adams, G.L., Yang, M., and Good, R.A. (1976). Immunologic assessment of regional lymph node histology in relation to survival in head and neck carcinoma. *Cancer*, 37, 697-705.
 4. Bhatlawande, H.C., Kale, A.D., Desai, K.M., Hallikerimath, S., Belaldavar, C., and Mane, D et al. (2019). Role of immuno-reactive patterns of lymph nodes in neck dissection cases of oral squamous cell carcinoma: a clinical and histopathological study. *J Korean Assoc Oral Maxillofac Surg*, 45, 267-275.
 5. Boas, D.S., Takiya, C.M., Gurgel, C.A., Cabral, M.G., and Santos, J.N. (2013). Tumor-infiltrating macrophage and microvessel density in oral squamous cell carcinoma. *Braz Dent J*, 24, 194-9.
 6. Chandavarkar, V., Uma, K., Sangeetha, R., and Mishra, M. (2014). Immunomorphological patterns of cervical lymph nodes in oral squamous cell carcinoma. *J Oral Maxillofac pathol*, 18, 349-55.
 7. Cottier, H., Turk, J., and Sobin, L. (1972). A proposal for a standardized system of reporting human lymph node morphology in relation to immunological function. *Bull WHO*, 47, 375-417.
 8. Folkman, J. (1990). What is the evidence that tumors are angiogenesis dependent? *J Nat Cancer Inst*, 82, 4-6.
 9. Iamaroon, A., Pongsiriwet, S., Jittidecharaks, S., Pattanaporn, K., Prapayasatok, S., and Wanachantararak, S. (2003). Increase of mast cells and tumor angiogenesis in oral squamous cell carcinoma. *J Oral Pathol Med*, 32, 195-9.
 10. Ioachim, H.L., and Mediros L.J.(2009 a). Ioachim's Lymph Node Pathology. 4th ed. Philadelphia (PA):Wolters Kluwer/Lippincott Williams & Wilkins; Tumor- reactive lymphadenopathy, 243-7
 11. Ioachim, H.L., and Medeiros LJ.(2009b). Ioachim's Lymph Node Pathology. 4th ed. Philadelphia (PA):Wolters Kluwer/Lippincott Williams & Wilkins; Tumor metastasis in lymph nodes,590-8.
 12. Jaafari Ashkavandi, Z., Moshref, M., Mashhadi-Abbas, F., Sargolzaie, S., and Taghavi, N. (2010). Evaluation of CD31 expression and mast cell count in dysplastic lesions and squamous cell carcinoma of the oral cavity. *J Iran Red Crescent Med*, 12, 272-76.
 13. Jahanshahi, G., and Sabaghian, M. (2012). Comparative immunohistochemical analysis of angiogenesis and mast cell density in oral normal mucosa and squamous cell carcinoma. *Dent Res J (Isfahan)*, 9, 8-12.
 14. Kabiraj, A., Jaiswal, R., Singh A., Gupta, J., Singh, A., and Samadi, F.M. (2018). Immunohistochemical evaluation of tumor angiogenesis and the role of mast cells in oral squamous cell carcinoma. *J Can Res Ther*, 14, 495-502.
 15. Kalra, M., Rao, N., Nanda, K., Rehman, F., Girish, K.L, Tippu, S et al. (2012). The role of mast cells on angiogenesis in oral squamous cell carcinoma. *Med Oral Patol Oral Cir Bucal*, 17, e190-196.
 16. Lores, B., García-Estevez, J.M., and Arias, C. (1998). Lymph nodes and human tumors (review). *Int J Mol Med*, 1, 729-33.
 17. Mannucci, P.M. (1998). von Willebrand factor: A marker of endothelial damage? *Arterioscler Thromb Vasc Biol*, 18, 1359-62.
 18. Pujari, R.K., Vanaki, S.S., Puranik, R.S., Desai, R.S., Motupalli, N., and Halawar, S. (2013). Histomorphometric analysis of vascularity in normal buccal mucosa, leukoplakia, and squamous cell carcinoma of buccal mucosa.

- J Oral Maxillofac Pathol, 17, 334-9.
19. Raj, L.S.M., Boaz, K., and Natarajan, S. (2014). Prognostic significance of lymph node pattern in oral squamous cell carcinoma (OSCC). *J Clin Diagn Res*, 8, 232-5.
 20. Ribatti, D., Vacca, A., Nico, B., Crivellato, E., Roncali, L., and Dammacco, F. (2001). The role of mast cells in tumour angiogenesis. *Br J Haematol*, 115, 514-21.
 21. Rubio, L., Burgos, J.S., Morera, C., and Vera-Sempere, F.J. (2000). Morphometric study of tumor angiogenesis as a new prognostic factor in nasopharyngeal carcinoma patients. *Pathol Oncol Res*, 6, 210-6.
 22. Sharma, B., Sriram, G., Saraswathi, T.R., Sivapathasundharam, B. (2010). Immunohistochemical evaluation of mast cells and angiogenesis in oral squamous cell carcinoma. *Indian J Dent Res*, 21, 260-5.
 23. Shieh, Y.S., Lee, H.S., Shiah, S.G., Chu, Y.W., Wu, C.W., and Chang, L.C. (2004). Role of angiogenic and non-angiogenic mechanisms in oral squamous cell carcinoma: Correlation with histologic differentiation and tumor progression. *J Oral Pathol Med*, 33, 601-6.
 24. Suchitra, G., Puranik, R.S., Vanaki, S.S., Prasad, B.G., and Malgaonkar, N.I. (2015). Immunoreactivity of excised lymph nodes in neck dissections of squamous cell carcinoma of oral cavity. *J Oral Maxillofac Pathol*, 19(2), 128-133.
 25. Tsakraklides, V., Anastassiades, T., and Kersey, J.H. (1973). Prognostic significance of regional lymph node histology in Uterine cervical cancer. *Cancer*, 31, 860-8.
 26. Wadhwan, V., Sharma, P., Saxena, C., and Venkatesh, A. (2015). Grading angiogenesis in oral squamous cell carcinoma: A histomorphometric study. *Indian J Dent Res*, 26, 26-30.
 27. Weidner, N., Semple, J.P., Welch, W.R., and Folkman, J. (1991). Tumor angiogenesis and metastasis - Correlation in invasive breast carcinoma. *N Engl J Med*, 324, 1-8.
 28. Weidner, N. (1993). Tumor angiogenesis: review of current applications in tumor prognostication. *Semin Diag Pathol*, 10, 302-313.
 29. Yadav, S.T., Madhu Shankari, G.S., Chatura, K., Dhanuja, R.J., and Rashmi, M. (2012). Immunomorphological assessment of regional lymph nodes for predicting metastases in oral squamous cell carcinoma. *Indian J Dent Res*, 23,1.