

How to Cite:

Shukur, D. M., & Ali, Q. T. (2022). Chemical castration with silver nitrate and potassium permanganate of local male bucks. *International Journal of Health Sciences*, 6(S9), 1937–1955. <https://doi.org/10.53730/ijhs.v6nS9.12836>

Chemical castration with silver nitrate and potassium permanganate of local male bucks

Dler Muwafaq Shukur

College of Veterinary Medicine, University of Al-Qadisiyah, Al-Dewaniyah, Iraq
Email: Delermofaq@gmail.com

Qayes Taref Ali

College of Veterinary Medicine, University of Al-Qadisiyah, Al-Dewaniyah, Iraq.
Email: qayes.ali@qu.edu.iq

Abstract---The purpose of the study is to compare the effectiveness of castration using two different drugs. The study was carried out on 12 local Iraqi male goats adult of 13-15 months. Intratesticular injection of chemical was done for inducing castration in the male goat. The animals were divided into three groups consisting of 4 animals in each group, in which in Treatment G1 the goats were castrated chemically using 1% AgNO₃ and for the other group Treatment G2 were castrated using 0.25 g KMnO₄ dissolving in 50 ml. Statistical analysis revealed that there was significant difference ($P > 0.01$) difference between the two groups G1 and G2 respectively in testicular measurement, the testosterone concentration and histopathologically revealed severe depletion of germ cells in seminiferous tubules and empty from any sperm. Numerical observation for both of the findings reveals that there was a difference between the two treatment groups. From the present finding it may be concluded that castration using KMnO₄ may be the best option for castration of the goat. The present study achieved in the farm beside vet hospital in Aldewaneya city during the period extended from November 2021 to January 2022.

Keywords---chemical, castration, silver, nitrate, potassium, permanganate, local, male, bucks.

Introduction

Despite being a cost-effective procedure, open castration of domestic male animals may require post-operative care to reduce the risk of bleeding and infection. Chemical agents such as cadmium chloride, ferric chloride, and ferrous sulphate have been injected as alternatives to non-surgical chemical sterilizing. Following intratesticular injection, these substances can result in mild

discomfort, pyrexia, or possibly severe inflammation (orchitis). Some substances, such as cadmium chloride, glycerol, and lactic acid (Immegart and Threlfall, 2000), selectively destroyed the testicular parenchyma while causing irreversible damage to the testicular tissue. In some instances, the interstitial component grew back after a period of early testicular atrophy that resulted in secondary male behavior and management issues. There isn't a chemosterilizing agent that is 100 percent effective. using an intra-testicular injection of to cause sterilization

Materials and Methods

The study was conducted on 12 local Iraqi male goats adult of 13-15 month with initial body weight (29.92 ± 0.54) kg. All animals were healthy and free of apparent physical and clinical abnormalities conditions. Clinical examination was done to assure that the animal is free from any obvious abnormalities of palpable reproductive system. Bucks were kept in controlled environments throughout the experiment and observation and they were numbered from (1-20) by inserted ears tags. Bucks dewormed with ivermectin in a dose of 0.2 mg/kg B.W. and vaccinated with Enterotoxemia (1 ml) each drugs injected subcutaneously at least 15 days before injection of chemical agent.

Experimental Design:

Bucks were randomly allotted to three groups (four goat/group) as follows:

- 1- Control group (G1): left without treatment which after one month and removed right testes to comparative histopathologic with other groups.
- 2- Silver Nitrate group (G2): received bilateral intratesticular injection 4 ml each testes with of 1.0% concentration AgNO-3 solution in 100 ml distilled water injection.
- 3- Potassium Permanganate group (G3): received in their testicles bilateral intratesticular injection of 4 ml each testes .Dissolving 0.25 g potassium permanganate in 50 ml distilled water.

Width, length and weight of testes measurement:

Before and after start this study measurements width, length and testes weighing were taken and recorded for first month to observation inflammation, swelling, odema ,sloughing, and any change like temperature after injection. Additionally, observation sexual behavior for all experimental groups after treatment.

Pre-injection Management:

Goats are considered to be more sensitive to the effects of xylazine than are other ruminants. The low-concentration (20 mg/ml) small-animal formulation should be used (Michael, 2002).

Small ruminants are generally not fasted longer than 24 hours, and water is not withheld for more than 12 hours. (Seddighi, *et al.* 2016) .

Goats were draped with sterile surgical drapes to results an aseptic injection field. Intra-testicular Injection Technique:

Sedation occurs before treatment and before surgical removed of the testes.

Intratesticular injection using a sterile 21 gauge needle directed injected deeply in the center of the testicle (Fig.1) and then distributed into cranial pole and redirected toward caudal pole without withdrawal from the skin testes for spread solution in most parts of testes ,(Driancourt, 2018) Who used sterile needle

gauge 21 was inserted from the caudo-ventral aspect of the testis then pushed in the center of the testis toward the cranio-dorsal pole of the testis. Record any adverse effect which happened, as result of injection and observation of vital signs included capillary refill time, cardiac and respiratory signs from constant observation of mucous membrane, used stethoscope, additionally temperature measurement which checked for two weeks followed injection.

Serum of testosterone concentration:

Before experimental was started, blood samples was collected from jugular vein of all experimental groups and after two month from experimental begin(post injected) also blood collected and measure level of testosterone. Serum samples 2 mL blood samples were collected from jugular vein following aseptic measures, before orchietomy (chemical castration) using blood collection Gel tube. Blood samples were centrifuged 3000 rpm for 20 minutes. Afterwards, serum were collected in Eppendorf tubes and kept at -20°C . testosterone measurement using ELISA technique. (Hasan, *et al*, 2018).

Histopathological Evaluation:

proximal (basal)scrotum, middle scrotum and distal (apical)scrotum sections from castrated bucks were collected and put into neutral buffer formalin(10%)for at least 24hr. most of the water in a specimen removed before it can be infiltrated with wax. This process is usually executed by immersing specimens in a series of ethanol (alcohol) solutions. Currently, fixation for diagnostic pathology which proceed to 4–5 μm paraffin sections, typically is less than 24h, and less is known. The slides were stained with Hematoxylin –Eosin stain to examined the structure of the interstitial structures in the testes under a light microscopic (Grizzle, 2009).

Statistical Analysis:

Means and standard error were studied for control and treatment group. Analysis of variance also was used to indicate the effect of chemical agent on testes of treatment groups on weight, width and its length additionally serum testosterone concentration. Statistical analysis the experimental data were analyzed for statistical significance by two-way analysis of variance and followed by post hoc LSD comparison using the SPSS version 27, (Inc., Chicago, IL, USA) computer software. All data were reported as mean + SE and statistical significance was accepted at $P < 0.05$ (Garth and Hallam, 2008).

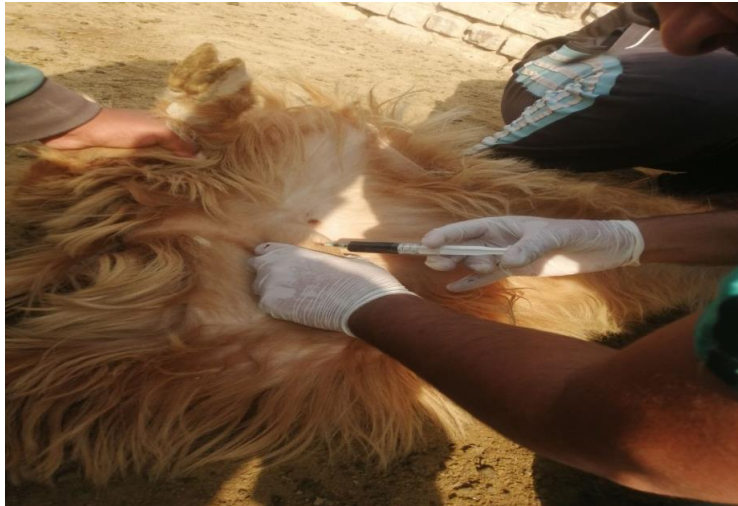

Fig.-1: intratesticular injection at the cranial pole without withdrawal

Results

Clinical monitoring:

Mounting Behavior

There was significant change in the behavior of any of the 12 bucks which used in the experiment.

(G1) there was no change in sexual behavior until end experimental. Also (G2) animal mounting behavior was absence after three days.

In (G3) after three days was observed sexual behavior was absence after four days...

Temperature, Appetite and Capillary refill time(CRT):

These clinical signs were monitored for the first three days post-injection.

Body temperature for all Experimental animals suffered from increase temperature after one day post-injection which reach to $(39.5 \pm 0.3^\circ\text{C})$ then after three days the temperature beginning decrease to the normal range $(39-38.5^\circ\text{C})$ no significant effect at the moment of evaluation $(P < 0.05)$. Rectal temperature was not affected by different treatments $(P < 0.05)$, with means between $38.5 \pm 0.3^\circ\text{C}$ and $39.3 \pm 0.2^\circ\text{C}$.

Another vital signs appetite of animal post-injection where the animal reduced appetite for three days.

Second parameters for the first week post-injection was Capillary refill time was assessed on duration required for the oral mucosa of the upper lip to return to its original color after blanching for 4 seconds.

The CRT was significantly associated with rectal temperature and normal value in goats congruent was $(1.9 \pm 0.1 \text{ sec})$ and this parameter reflected (table 1).

Table-1. Mean values of clinical signs first week after treatment in 20 mature male goats.

Groups	Rectal temperature	Capillary refill time
G1	38.5±0.3	20±0.5
G2	39±0.2	3.5±0.1
G3	39.2±0.3	3 ±0.24

Depending on these parameters, there was no significant change in animal condition which ascribed to the action of the chemical agents used, where their effects were on the testis only and not reached and spread by blood stream .

Discomfort:

There was no adverse reaction reported in the control group which not received any chemical agent. While mild degree of discomfort represented by restlessness, shifting from one hip to the other and difficult walking. This discomfort was ephemeral in nature and caused by pain occur from deposit of chemical agent through the testis and caused testicular swelling.

Testicular Swelling:

Immediately following the intra-testicular injection of animals with chemical agent, the testicle became swollen and measured with caliper used (Lofty; et al, 2020) . While G1 not effected . G2, and G3 the size of each testicle was the largest on three days after injection, then gradually decrease in size with in (15-20) days . At beginning (post injection), the swelling were expected reaction to insertion of the needle and caused traumatic injury for three days. This might have been a result of edema or cellular infiltrates.

Body weight:

The body weight of animals were increased significantly ($p < 0.01$) in all castrated groups and G1 . The mean of body weight gained G3, more than G2 were get the higher body weight gained Table- 2, While the least were G1.

Table -2 : Body weight of bucks before treatment and at the end of experiment before castration after two month and weight gain (mean ± SE). (n=4)

Groups	Body weight(Kg)	
	Before treatment	After treatment
G1	31.87±1.007	36±1.008
G2	30±0.93	36.25±1.88
G3	29.25±0.87	37.5±0.95

Treatment groups denote to significance difference ($P < 0.01$) in column.

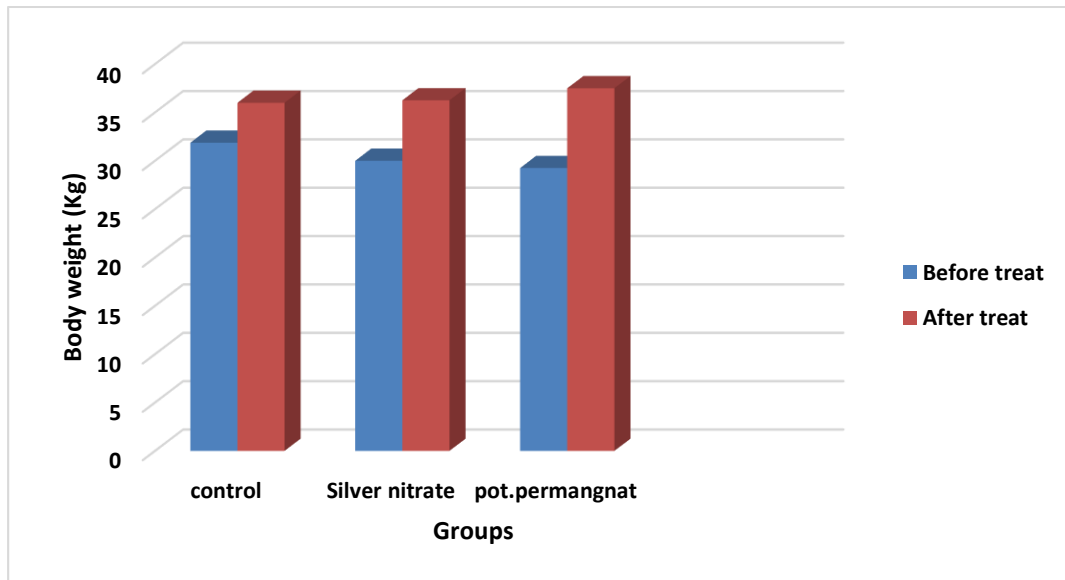


Fig.-2: Body weight gained of adult bucks after treatment demonstrate significant increase ($P < 0.01$) in body weight gained in all treatment groups compared with control where no significant difference ($P < 0.05$) at the end of experimental.

Testicular Weight:

There was no a significant decrease ($P < 0.05$) in the weight of right and left testes (right and left) in G1, G2, and G3 after one month as showed in Table 3.

Table-3: Mean \pm SE of testicular weight (gm) of all bucks after one month post-injection

Goups	Testicular weight(gm) both testes				
	1	7	14	21	28
G1	410.14 \pm 1.26	453.62 \pm 1.27	408.75 \pm 0.50	425.27 \pm 0.55	457.19 \pm 0.63
G2	248.51 \pm 3.03	279.13 \pm 1.82	303.69 \pm 1.74	321.04 \pm 3.27	285.61 \pm 2.82
G3	193.95 \pm 0.62	242.32 \pm 0.32	265.78 \pm 0.23	254.52 \pm 1.16	229.65 \pm 0.36

There is no significant variances at $p < 0.05$ in G2, and G3.

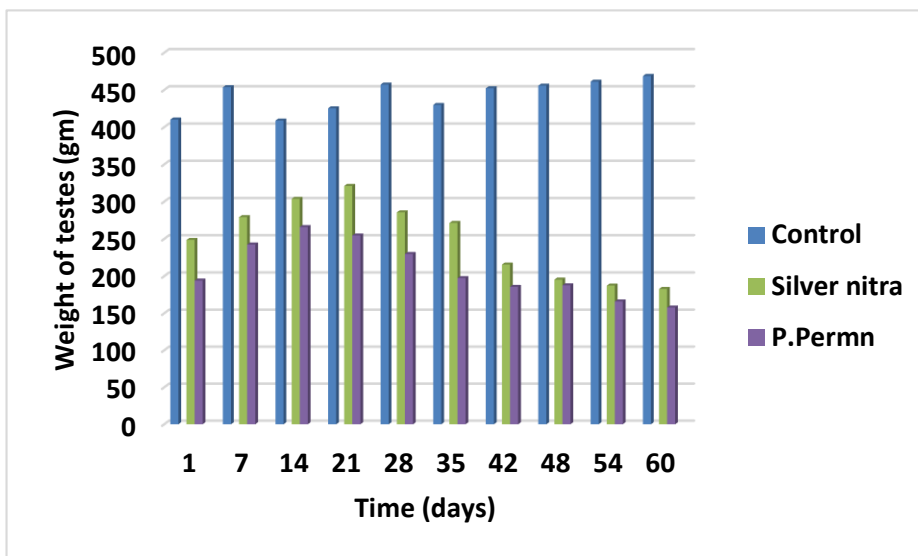


Fig.-3: Testicular weight (gm) of adult bucks through two month from treatment demonstrate significant decrease in weight of testes of G2 and G3

Testicular length (left testes):

There was a significant decrease ($P < 0.01$) in the length of left testes of G2, and G3 respectively then G1.

In G3 there were obvious changes in the left testicular length (decrease in size and length making able to determine the treated testicles) as showed in Fig.-4.

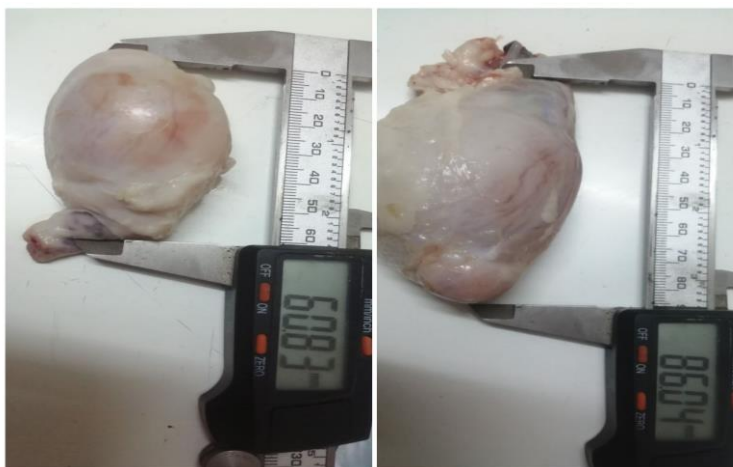

Fig.-4: The picture on the left side of treated testes, While on the right side of G1.

Table-4: Mean±SE of testicular length (Left testes) (mm) of mature bucks after two months post-injection

Groups	Length of the left testes Period(day)									
	1	7	14	21	28	35	42	48	54	60
G1	113	116.66	107	101.66	99	105.66	106	109.33	105.33	110.66
G2	103	111.66	112	103.33	110.33	100	88.66	86.66	92	89.66
G3	102.66	115.33	113	98.33	106.33	108	91.33	87.66	83.33	82

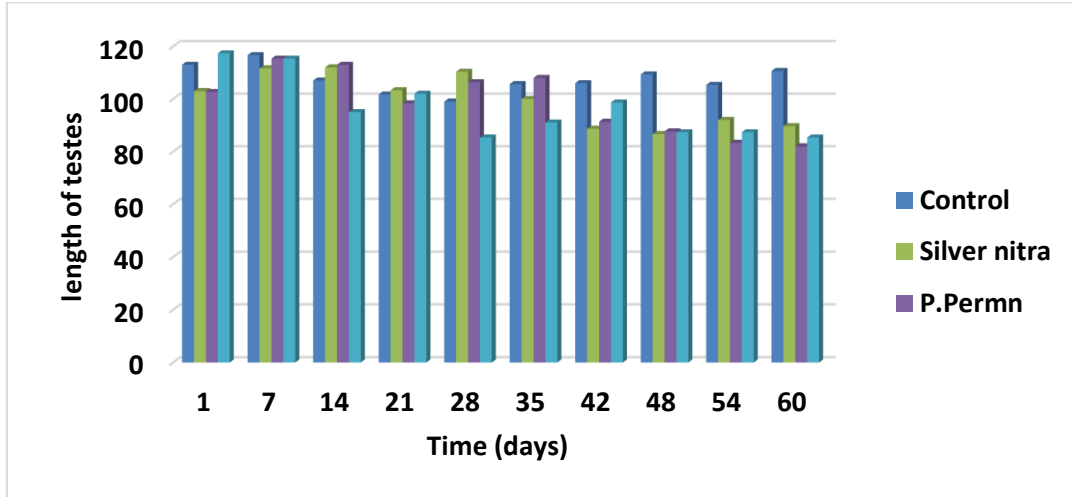


Fig-5: Testicular length (mm) of adult animals through two months and measured each week after treatment demonstrate no significant decrease in length of treated animals.

Testicular circumference:

Testicular circumference (Right testes)

The testicular circumference of the right testes in G2, and G3 respectively were significantly decreased ($P < 0.01$) compared with G1 were no significant difference ($p < 0.05$) between the circumference of the testes.

Goups	Testicular Circumference(mm) right testes				
	1	7	14	21	28
G1	48.25+1.6	47.75+0.25	49+0.40	50.25+0.47	51.25+0.47
G2	44.75+0.75	42.75+0.94	40.25+1.43	40.5+1.19	36.75+1.10
G3	44.75+0.62	39.75+0.62	39.25+1.10	34.25+0.94	36.25+1.10

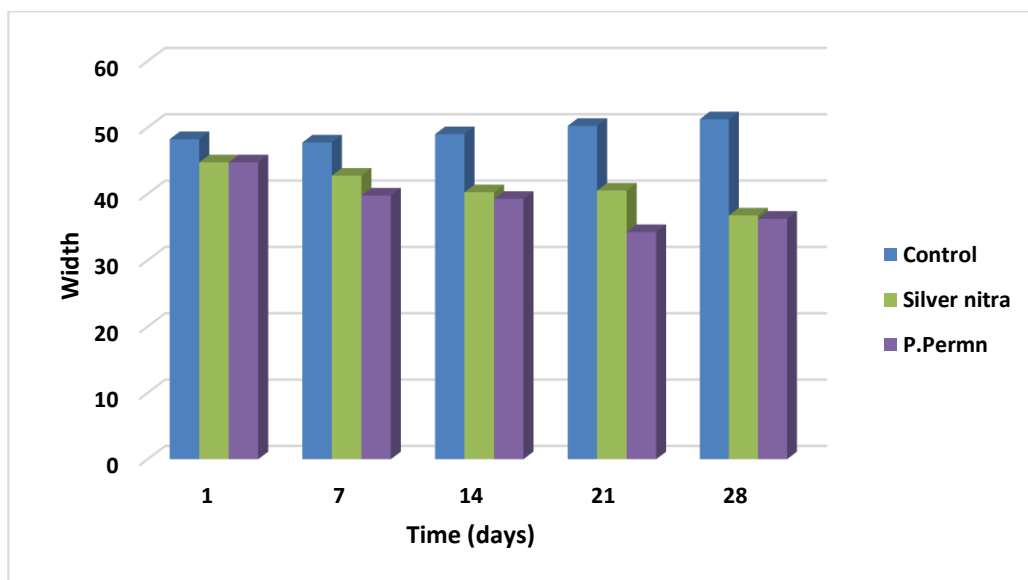


Fig.-6: Testicular circumference (mm) of right testes in adult bucks through one month. There was significant decrease $P<0.01$ in treated animals compared with G1

Testicular circumference (Left testes)

The testicular circumference of the left testes after two month from treatment of G2, and G3 respectively were significantly decreased at $P<0.01$, Whereas no significant difference in G1 as showed in Table- 7.

Table-6: Mean \pm SE of left testicular circumference (mm) of the bucks after two month from treatment compared with G1 there was no significant difference ($P<0.05$) through two months

Groups	Testicular Circumference(mm) of the left testes									
	1	7	14	21	28	35	42	48	54	60
G1	48.25 \pm 1.43	49.25 \pm 1.25	46 \pm 0.40	45 \pm 0.70	53.75 \pm 0.62	50.75 \pm 0.47	50.5 \pm 0.86	48.75 \pm 0.62	49.75 \pm 0.62	51.75 \pm 0.62
G2	40.25 \pm 0.25	43 \pm 0.40	46 \pm 1.35	40.75 \pm 1.6	41.25 \pm 3.09	37.25 \pm 4.09	33.25 \pm 0.25	31.25 \pm 1.10	27.25 \pm 0.25	22.75 \pm 0.47
G3	39.75 \pm 0.47	40 \pm 1.35	39.25 \pm 2.09	35.75 \pm 0.25	30.75 \pm 0.62	26 \pm 1.68	32 \pm 1.35	27.75 \pm 0.62	25.5 \pm 0.86	22.75 \pm 0.62

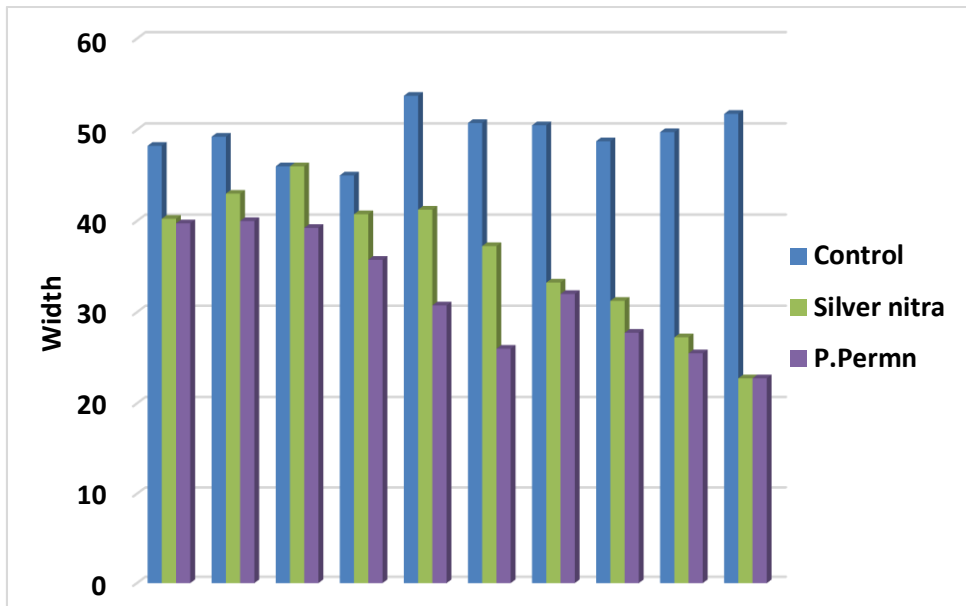


Fig.-7: Testicular circumference (mm)of left testes in adult bucks through two month post treatment in treated groups compared with G1 were no significant difference (P<0.05).

Testosterone hormone:

The serum testosterone hormone level in all groups before treatment ranged between (40.12±5.97 to 52.08 ± 4.55 pg/ml). as showed in table- 8 , and fig.-8. Post two months of intratesticular injection the level of hormone shows significant difference (P<0.01) in G1 at the end of experiment. Whereas there is significant decrease (P<0.01) in treated groups compared with G1 showed decrease hormone level inG2, and G3.

Table-8: Mean ±SE of testosterone hormone of adult bucks before and after treatment after two months

Groups	Testosterone Hormone (pg/ml)	
	Before treatment	After treatment
G1	40.12± 5.97	85.38 ± 28.2
G2	42.24 ± 6.20	35.73± 3.09
G3	44.20 ± 7.24	35.73 ± 4.6

There is significant increase (P<0.01) in G1.

There is decrease level in the hormone at all treated groups.

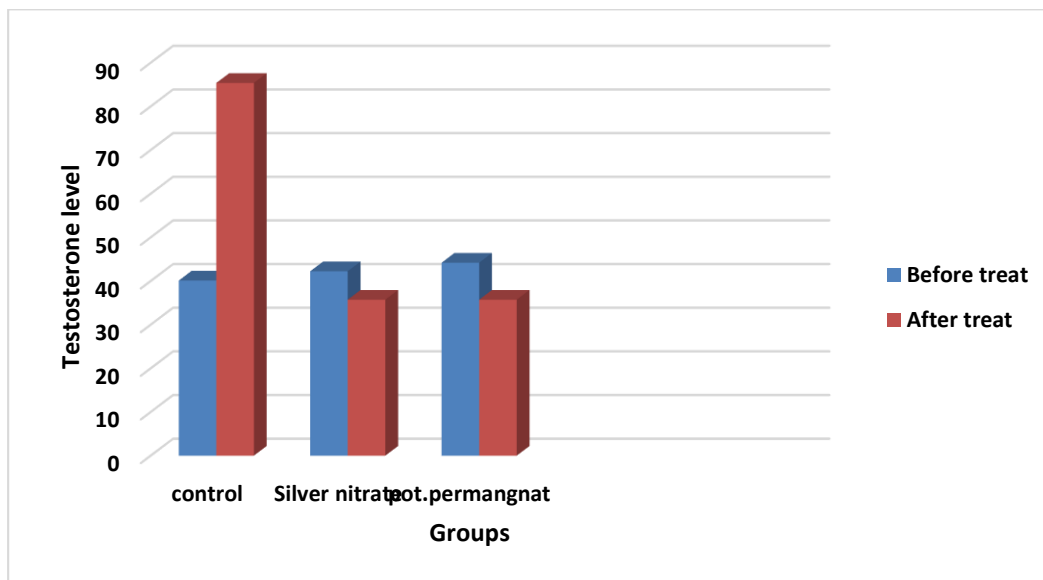


Fig.-8: Testosterone hormone of adult bucks before and after treatment in two months there was significant increase ($P < 0.01$) compared with treated groups.

Gross lesions

There was obvious lesion in the testes after two months of experiment time in G2, and G3. Whereas no obvious lesion was detected in testes of G1.

G2 after two months was reveal little amount of silver nitrate at the proximal part of testes and some coagulated as showed in fig.-9. G3 was demonstrate some of chemical agent at the distal part of body testes and some coagulative necrosis in the edge as showed in fig.10.

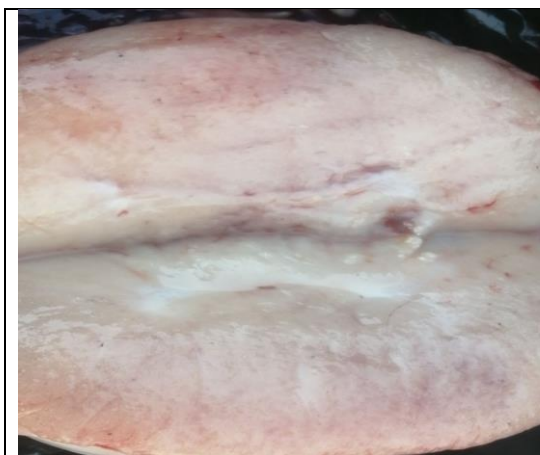

Fig.-9: Gross lesions of G2 after two months.



Fig.-10: Gross lesions of G3 after two months.

4-6. Histopathological findings

Comparable pathological changes represented with sever damages of testicular tissue were seen in all treated groups. While G1 showed no changes. The histopathological changes were more obvious in the seminiferous tubules. Where the seminiferous tubules lined by basement membrane containing spermatogonia, sertoli cells, different stage of spermatozoa in the lumen interstitial cells (leydig cell) and germinal cells(Fig.11)(Fig.12). These changes in the bucks have (treated groups): coagulative necrosis, fibrosis in seminiferous tubules, atrophy in germinal layer of seminiferous tubules, calcification of seminiferous tubules ,vacuolar degeneration of spermatogonia and degenerative changes of spermatogenesis.. After one month post injection, The changes of G2 which included sever depletion of germ cell in seminiferous tubules to only single layer and empty from any sperm (fig.13). diffuse coagulative necrosis of seminiferous tubules(Fig.14), fibrosis in interstitial tissue(leydig cells) degenerated of seminiferous tubules and absence of sperm (15) (Fig16), the seminiferous tubules surrounding by inflammatory cells in tubules(17).Post- injection of G2 showed (Fig. 18) also coagulative necrosis in seminiferous tubules.

In G3 were showed absence germ cells and sperm in seminiferous tubules (Fig.19), sever depletion of germ cells, fibrosis in seminiferous tubules and absent germ cells (Fig.20) .

G1 after two months shows normal architecture in seminiferous tubules and interstitial tissue(fig.21).

At two month post- injection of G2 showed congested blood vessels and fibrosis in stroma(fig.22) granulomatous inflammation in seminiferous tubules and fibrosis(fig.23), hyalinized seminiferous tubule and vacuolar degeneration of spermatogonia(fig.24).

(G3) at two month post- injection , histopathological section of the testes showed irregular seminiferous tubules and sever atrophy of germ cells(fig.25), sever depletion of germ cells in seminiferous tubules with many focal granulomatous inflammation(fig.26) granulomatous inflammation with infiltration inflammatory cells mainly lymphocyte and macrophages(fig.27).

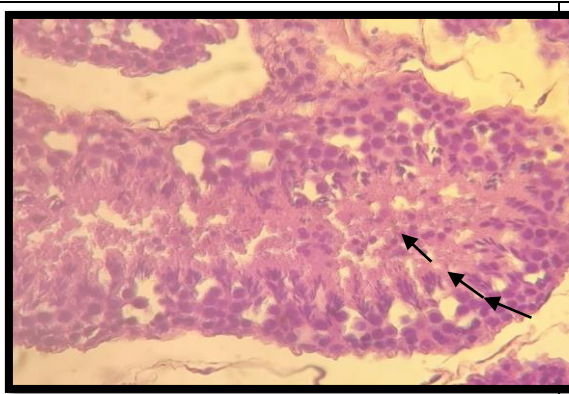


Fig.-11: Testes related of G1 showed seminiferous tubules lined by basement membrane containing spermatogonia , below it the sertoli cells, different stage of spermatozoa in the lumen (LC)(H&E X 40).

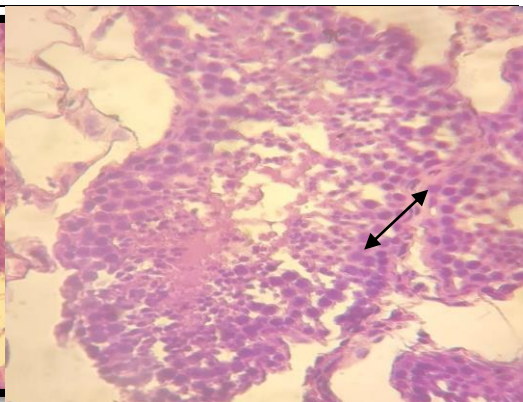


Fig. (12). Histology of testis related to control group shows seminiferous tubules containing sertoli cells and interstitial tissue between the tubules containing leydig cells (LC) (H&E X40)

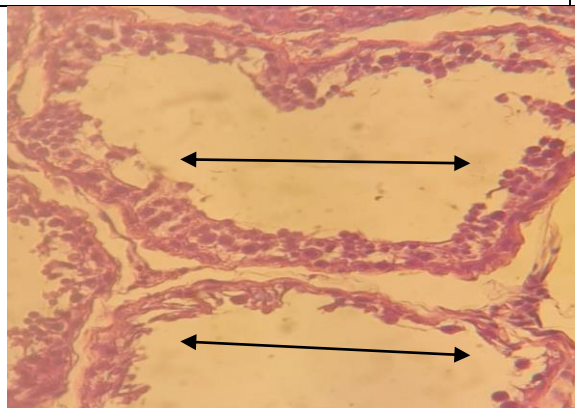


Fig. (13). Histopathological section of the testis at one month post- injection of G2 showed sever depletion of germ cell in seminiferous tubules to only single layer and empty from any sperm(H&E X40)

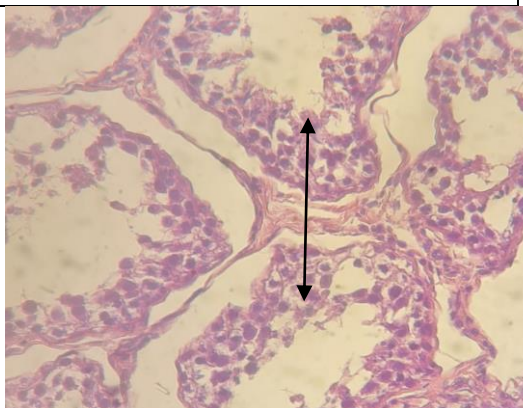


Fig. (15). Histopathological section of the testis at one month post-injection of G2 showed degenerated of seminiferous tubules and absence of sperm (H&E X40).

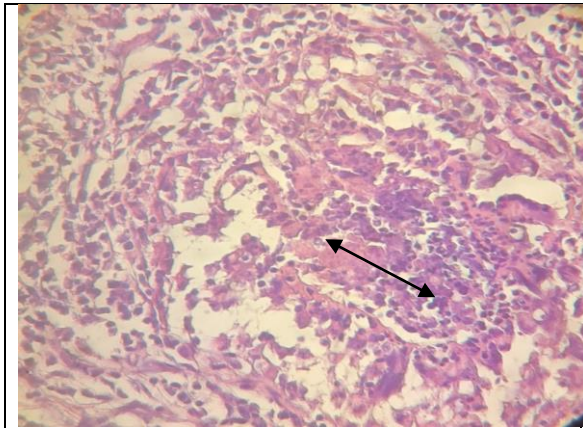


Fig. (14). Histopathological section of the testis at one month post- injection of G2 showed , coagulative necrosis in seminiferous tubules surround by inflammatory cells (H&E X40)

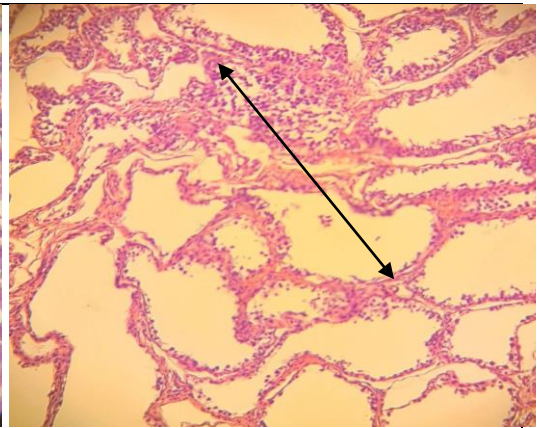


Fig. (16). Histopathological section of the testis at one month post-injection of G2 showed infiltration of inflammatory cells and fibrosis in interstitial tissue of seminiferous tubules (H&E X10) ◀

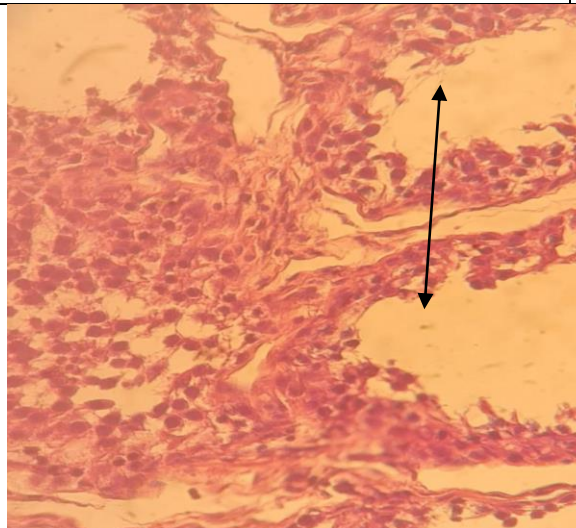


Fig. (19). Histopathological section of the testis at one month post- injection of G3 showed absence germ cells and sperm in seminiferous tubules (H&E X40) .

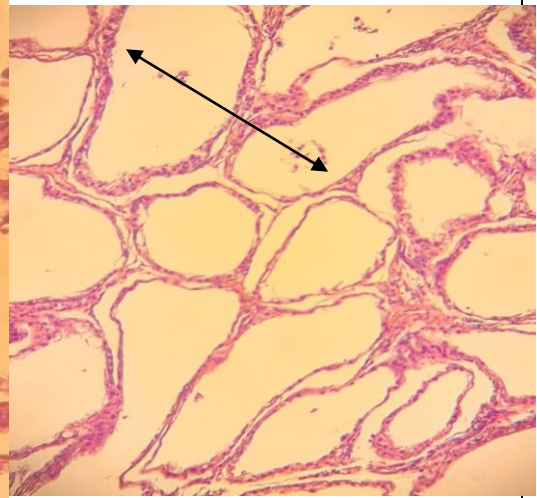


Fig. (20). Histopathological section of the testis at one month post-injection of G3 showed sever depletion of germ cells and fibrosis in seminiferous tubules (H&E X40)

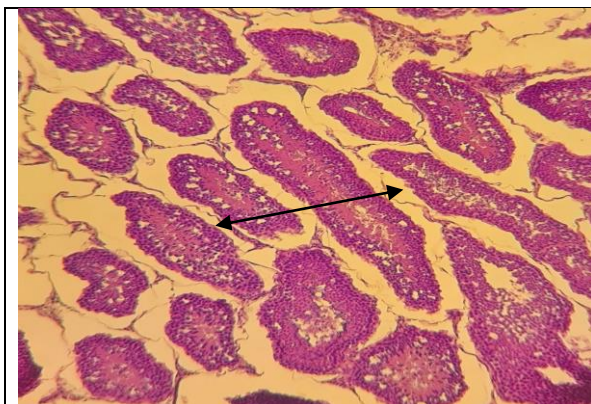


Fig. (21). Histology of testis related to G1 after two months shows normal architecture in seminiferous tubules and interstitial tissue (H&E X10).

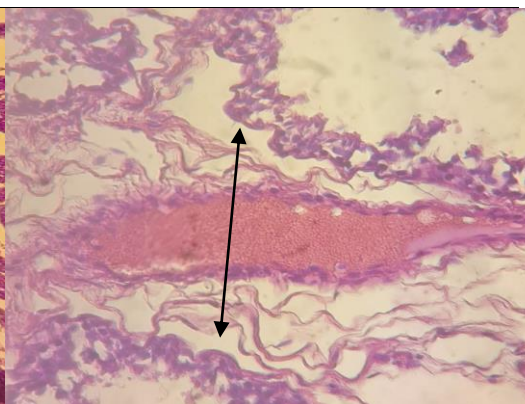


Fig. (22). Histopathological section of the testis at two month post-injection of G2 showed congested blood vessels and fibrosis in stroma (H&E X40) .

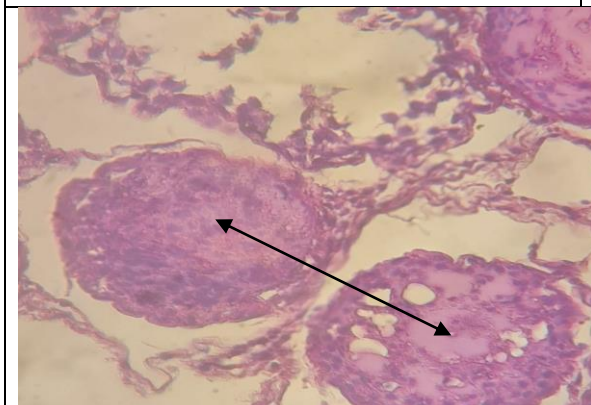


Fig. (23). Histopathological section of the testis at two month post-injection of G2 showed granulomatous inflammation in seminiferous tubules and fibrosis (H&E X40).

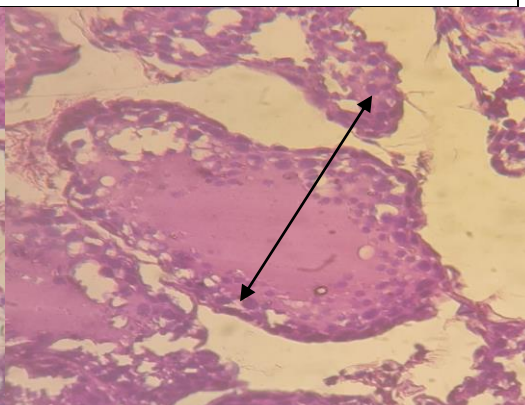
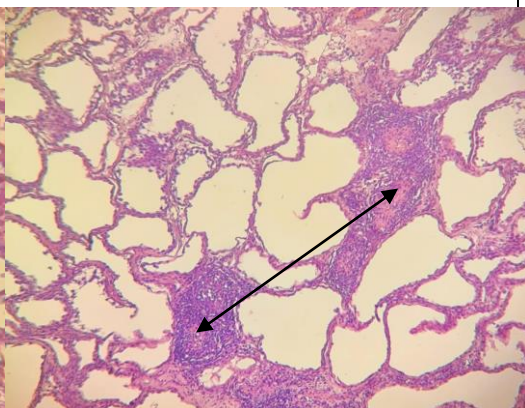
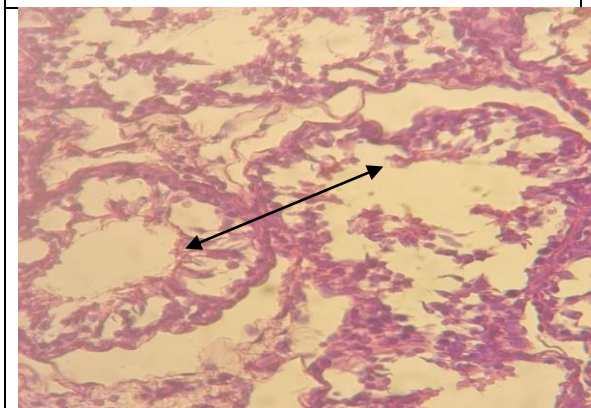
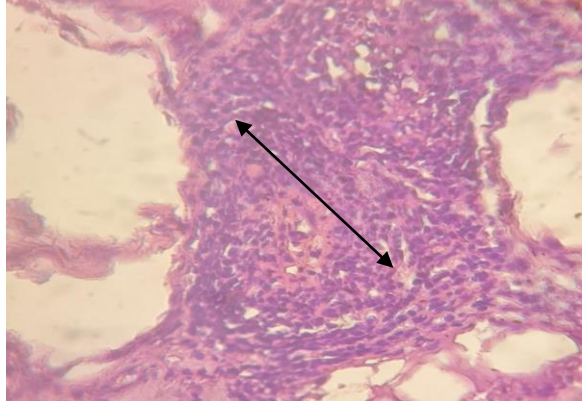


Fig. (24). Histopathological section of the testis at two month post-injection of G2 showed hyalinized seminiferous tubule and vacuolar degeneration of spermatogonia (H&E X40).



<p>Fig. (25). Histopathological section of the testis at two month post- injection of G3 showed irregular seminiferous tubules and sever atrophy of germ cells (H&E X40)</p>	<p>Fig. (26). Histopathological section of the testis at two month post- injection of G3 showed sever depletion of germ cells in seminiferous tubules with many focal granulomatous inflammation (H&E X10).</p>
	
<p>Fig. (27). Histopathological section of the testis, two month post- injection of G3 showed granulomatous inflammation with infiltration inflammatory cells mainly lymphocyte and macrophages (H&E X40)</p>	

Discussion

The sterilization of adult male goats and castration by chemical agent with silver nitrate, potassium permanganate in the present study achieved a significant raise in weight gain than the G1. This may have come from the chemical sterilization which is substantial for better external fat score, mohair production is higher in castrated goats than intact ones and carcass weight improvement. These compacts with (Edmondson and Misty, 2021) who is found castration in goat can cause scored in body weight gain.

Testicular measurement revealed that the length, weight, and circumference of the testes subjected to the chemical agent injection registered a significant decrease at $P < 0.01$ than G1 and effect appear in, G2 and G3 respectively. These changes in measurement resulted from atrophy and decrease size of testes due to the height of the seminiferous epithelium was significantly reduced in the testes compared with G1. This appropriate with (Fagundes et al., 2014) found significant atrophied changes in the testes after injection zinc gluconate into the testes.

The changes in the value of testosterone hormone in the serum of adult bucks before and after treatment ranged from (85.38 to 34.75 pg/ml) in all animals of the study and there was significant variances at $P < 0.01$ in G2, and G3 compared with G1. The results is compatible with (Vanderstichel, 2015) who found no significant difference of testosterone hormone in chemically sterilized dogs.

The result revealed that the value of testosterone hormone in the G2, and G3(injection with chemical agent) recorded low level testosterone hormone compared with G1 where noticeable with,G3 and finally G2 and G1 . These results can be demonstrate by necrosis of convoluted seminiferous tubules with loss of their distinct borders and Damaged seminiferous tubules caused by chemical agent injection and that was including the leydig cells which are responsible for the testosterone hormone production(Vasta ;*et al.*,2006)(Michele and Carlo .2012) which considered interstitial cells there for significant effect in testosterone levels and this observed with(Pereira,*et al.*,2018)who found serum testosterone concentrations from bulls subjected to chemical castration with calcium chloride indicate statistically significant differences testosterone hormone levels in treatment groups.

In case of G2, and G3,there were relatively low level testosterone hormone compamred with G1, where reached in all animal before treatment (11.96pg/ml).In this study appeared there was degeneration and irreversible necrosis occurring in the testes and no compensatory mechanism to replace the damage which making testosterone level low. These results correspond with (Fagundes, et al., 2014)(Mohammed and James, 2013).Also low level of testosterone hormone and its present in serum of blood although chemical castration and damage was occurred due to produce by the adrenal cortex .this was concurs with (Lara , 2017) who found that the hormone The primary androgen produced by the adrenal cortex is dehydroepiandrosterone (DHEA) Adrenal Glands 5 (and the sulfate metabolite, DHEA-S that considered a precursor to sex hormones such as testosterone and estradiol.

In G2 testosterone ranged from (42.24 to 35.73 pg/ml), G3 from (44.20 to 35.73 pg/ml) While G1 from (40.12 to 85.38 pg/ml) reveled significant increase after two months post the experiment. Although hemicastration to right testis after one month, hypertrophy not occurrence in left testis in castrated animal treated with chemical agents in all group that injected where testis measurement persistant reduced in weight , length and circumference according to tables and charts mentioned in this study. Whereas compared with G1 significant increase in measurement (weight, length and circumference). All treated testis were noticed grossly decreased in all parameters (weight, length and circumference of testis)more than G1 and this was due to capillaries that carried blood was collapsed due to the decreased blood flow and capillary hydrostatic pressure, causing tissue anoxia and this consistent with (Sella;et al., 2017) who found that response to tissue injury ..Also chemical castration caused degeneration imbalance between free oxygen/nitrogen species and free radical scavenging molecules, oxidative stress and this noticeable by (Nasser; et al.,2020).

The main histological finding indicative no sperm in the seminiferous tubules and no spermatids, sever depletion of the germ cells and degeneration of leydig and sertoli cells, coagulative necrosis and fibrosis occur in seminiferous tubules and interstitial cells. Also there was congestion blood vessels in seminiferous tubules and granulomatous inflammation with infiltrations, inflammatory cells mainly lymphocyte, macrophages and neutrophils and fibrosis in interstitial tissue. These pathological changes was happened after one and two month from chemical castration and these results concurs with (Jana and Samanta,2005)

who found calcium chloride produced disintegration of the germ cell assembly in seminiferous tubules, washing out of the germ cells from the tubules and some of the tubules showed the elimination of all germ cells and also explained by (Andrade; *et al.*, 2014) who noticed extensive testicular fibrosis when used intratesticular hypertonic saline in cattle. Testis of G2 and G3 were observed grossly as smaller in measurements (width, length, weight of testes) than G1 and this occurred due to degeneration and severe depletion of germ cells in seminiferous tubules and necrosis and led to observed atrophy of testes and this is consistent with (Hasan; *et al.*, 2020) who noticed that indicating severe degeneration of testicular tissue.

Change in the behavior of G2, and G3 represented by reduced appetite, increased restlessness, shifting from one hip to the other and difficult walking for at least 3 days, scrotal swelling. These signs concurrent with (Pereira, *et al.*, 2018) who noticed scrotal swelling and over the following two days, calves continued to show signs of pain and discomfort, whereas complication for most surgical operation represented by wound infection with bacteria, Myiasis and prolonged period for recovery compared with chemical castration. This study accorded with (Mintline, *et al.*, 2014) who stated that the dramatic changes in healing score occur between 21 days and 35 days after surgical procedure in calves. Chemical castration of animals showed signs of restlessness for a long period when compared with surgical and burdizzo instrument castration and this was referred to (Nasser *et al.*, 2020), resulted from higher plasma cortisol in chemical castration than burdizzo and surgical castration in donkeys. From the results of this experiment, the chemical castration caused testicular damage and irreversible change in adult bucks, and less inflammatory reaction. It takes a little time to do it and lowest costs than other castration methods.

References

- Swindle, M. Michael (2002). *Laboratory Animal Medicine || Preanesthesia, Anesthesia, Analgesia, and Euthanasia.* , (), 955–1003.
- Seddighi, Reza; Doherty, Thomas J. (2016). *Field Sedation and Anesthesia of Ruminants.* *Veterinary Clinics of North America: Food Animal Practice*, (), S0749072016300251.2
- Driancourt, Marc A. (2018). *Encyclopedia of Reproduction || Male Contraception in Animal Species.* , (), 553–558.
- Kuladip Jana; P.K. Samanta; D. Ghosh (2005). Evaluation of single intratesticular injection of calcium chloride for nonsurgical sterilization of male Black Bengal goats (*Capra hircus*): a dose-dependent study. , 86(1-2), 0–108.
- Immegart, H.M., Threlfall, W.R., 2000. Evaluation of intratesticular injection of glycerol for non-surgical sterilization of dogs. *Am. J. Vet. Res.* 61, 544–549.
- Grizzle, WE (2009). Special symposium: fixation and tissue processing models. *Biotechnic & Histochemistry*, 84(5), 185–193.
- Hasan, M; Miah, MAH; Rosy, TA; Jha, PK; Juyena, NS (2018). Serum testosterone concentration in surgically castrated Black Bengal goats. *Bangladesh Veterinarian*, 33(2), 71–77.
- Andrew Garth, Sheffield Hallam University, 2008, *Analysing data using SPSS.*
- Fagundes, Ana Katharyne F.; Oliveira, Erika C.S.; Tenorio, Bruno M.; Melo, Cibele C.S.; Nery, Lorena T.B.; Santos, Fábio André B.; Alves, Luiz Carlos; Douglas,

- Robert H.; Silva, Valdemiro A. (2014). Injection of a chemical castration agent, zinc gluconate, into the testes of cats results in the impairment of spermatogenesis: A potentially irreversible contraceptive approach for this species?. *Theriogenology*, 81(2), 230–236.
- Edmondson, Misty A. (2021). *Sheep, Goat, and Cervid Medicine || Theriogenology of sheep, goats, and cervids.* , (), 141–208.
- Vanderstichel, R.; Forzán, M.J.; Pérez, G.E.; Serpell, J.A.; Garde, E. (2015). Changes in blood testosterone concentrations after surgical and chemical sterilization of male free-roaming dogs in southern Chile. *Theriogenology*, 83(6), 1021–1027.
- Bertolotto, Michele; Trombetta, Carlo (2012). [Medical Radiology] *Scrotal Pathology || Anatomy of the Scrotum.* , 10.1007/978-3-642-12456-3(Chapter 170), 27–34.
- Vasta, V.; Shimizu-Albergine, M.; Beavo, J. A. (2006). Modulation of Leydig cell function by cyclic nucleotide phosphodiesterase 8A. *Proceedings of the National Academy of Sciences*, 103(52), 19925–19930.
- Pereira, Lucas F.; Dias, Fernanda G.G.; Miguel, Marina P.; Honsho, Cristiane S.; Tavares, Denise C.; Hellú, José A.A.; Souza, Fabiana F; (2018), *Testicular histological evaluation and serum testosterone.*
- Mohammed, A; James, FO (2013). Chemical castration by a single bilateral intratesticular injection of chlorhexidine gluconate and cetrimide in bucks. *Sokoto Journal of Veterinary Sciences*, 11(1), –.
- Trevino, Lara A. (2017). *Reference Module in Neuroscience and Biobehavioral Psychology || Adrenal Glands.* , (), –.
- Abou-Khalil, Nasser S.; Ali, Marwa F.; Ali, Magda M.; Ibrahim, Ahmed (2020). Surgical castration versus chemical castration in donkeys: response of stress, lipid profile and redox potential biomarkers. *BMC Veterinary Research*, 16(1), 310–.
- Kuladip Jana; P.K. Samanta; D. Ghosh (2005). Evaluation of single intratesticular injection of calcium chloride for nonsurgical sterilization of male Black Bengal goats (*Capra hircus*): a dose-dependent study. , 86(1-2), 0–108.
- Neto, Olmiro Andrade; Gasperin, Bernardo G.; Rovani, Monique T.; Ilha, Gustavo F.; Nóbrega, Janduí E.; Mondadori, Rafael G.; Gonçalves, Paulo B.D.; Antoniazzi, Alfredo Q. (2014). Intratesticular hypertonic sodium chloride solution treatment as a method of chemical castration in cattle. *Theriogenology*, 82(7), 1007–1011.e.
- Hasan, M; Miah, MAH; Rosy, TA; Jha, PK; Juyena, NS (2018). Serum testosterone concentration in surgically castrated Black Bengal goats. *Bangladesh Veterinarian*, 33(2), 71–77
- Paranzini, Cristiane Sella; Sousa, Anne Kemmer; Cardoso, Guilherme Schiess; Perencin, Felipe Montanheiro; Trautwein, Luiz Guilherme Corsi; Bracarense, Ana Paula Frederico Rodrigues Loureiro; Martins, Maria Isabel Mello (2017). Effects of chemical castration using 20% CaCl₂ with 0.5% DMSO in tomcats: Evaluation of inflammatory reaction by infrared thermography and effectiveness of treatment. *Theriogenology*, (), S0093691X17304879–.
- Mintline, E. M.; Varga, A.; Banuelos, J.; Walker, K. A.; Hoar, B.; Drake, Daniel; Weary, D.M.; Coetzee, J. F.; Stock, M. L.; Tucker, C. B. (2014). Healing of surgical castration wounds: a description and an evaluation of flunixin. *Journal of Animal Science*, 92(12), 5659–5665.