

How to Cite:

Rumbiak, A. L. E., Sugianto, P., & Setyowatie, S. (2022). Multiple cerebral abscess caused by *Klebsiella pneumoniae* on post tumor excision procedure: A case study. *International Journal of Health Sciences*, 6(S8), 3591–3596.
<https://doi.org/10.53730/ijhs.v6nS8.12900>

Multiple cerebral abscess caused by *Klebsiella pneumoniae* on post tumor excision procedure: A case study

Adelheid Loraine Erensina Rumbiak

Resident, Department of Neurology, Faculty of Medicine, Airlangga University - Dr. Soetomo Regional Public Hospital, Surabaya, Indonesia

Paulus Sugianto

Department of Neurology Teaching Staff, Faculty of Medicine, Airlangga University - Dr. Soetomo Regional Public Hospital, Surabaya, Indonesia
Corresponding authors email: paulus.sugianto@gmail.com

Sita Setyowatie

Department of Neurology Teaching Staff, Faculty of Medicine, Airlangga University - Dr. Soetomo Regional Public Hospital, Surabaya, Indonesia

Abstract---A cerebral abscess can happen due to a nearby brain infection, other rare body parts spread, head injury and surgery procedures. Intracranial *Klebsiella pneumoniae* infection rarely happens and usually occurs in immunocompromised patients. We reported a case of a 50 years old immunocompetent woman with prior tumor excision that progressed to a cerebral abscess. The patient came to the ER unconscious with progressive right-side weakness, pus from previous operation scar, fever and headache since few days' pre-admission. Laboratory findings were leukocyte 13.710, neutrophil 9%, CRP 7.6, and negative HIV test. The contrast CT scan resulted in a multiloculated ring enhancement left frontal lobe lesion sized 5.8x6.9x5.0 cm and perifocal oedema. Open craniotomy managed to evacuate ±40cc. The microbiology culture tested positive for *Klebsiella pneumoniae*. Despite proper technique and administration of prophylaxis antibiotics, severe infection that requires immediate intervention still develops in a small group of patients. *Klebsiella pneumoniae* is a common pathogen causing cerebral abscess in both immunocompromised and healthy patients. Pus drainage and immediate antibiotics administration improved all symptoms, including hemiparesis. This case highlights the importance of quick and right therapy.

Keywords---cerebral abscess, post-operation cranial infection, *Klebsiella pneumoniae*.

Introduction

A cerebral abscess is a focal intracerebral infection originating from a localized cerebritis area that evolves into an encapsulated pus accumulation with good vascularization. (Kolegium Neurologi Indonesia, 2019) The incidence of this disease ranges from 0.4 – 0.9 cases per 100.000 people and is more commonly found in immunocompromised patients. Most cases (80%) were located at the left lobe, cerebellum, and brain stem and are seen more in men than women aged 30-40, with a 2:1 to 3:1 ratio. A cerebral abscess can happen due to nearby and distant infections spreading hematogenous. (Winn, 2017) Other than that, the infection can also happen because of sharp head trauma or brain surgery. Trauma can lead to cerebral abscess from an open cranial fracture with dura damage by foreign things or procedural-related. The incidence of abscesses associated with trauma reaches 2.5 – 10.9%. (Valentino A & Angraini GP, 2019) Around 0.8-7% of post-operative infection is reported in a series of patients undergoing neurosurgical procedures receiving pre-operative prophylaxis antibiotics. Few retrospective studies showed a higher infection rate without prophylaxis antibiotics (10%). (Dashti et al., 2008) The clinical manifestation of this disease is not specific, depending on the size, location of brain lesion, and virulence of the infectious organism. Some early symptoms include headache (49-97%), fever (32-72%), neurologic deficits (20-60%), loss of consciousness (28-91%), seizures (13-35%), nausea and vomiting (27-95%), nuchal rigidity (5-52%) and papilledema (9-51%). (Winn, 2017). (Valentino A & Angraini GP, 2019) Specific neurologic deficits observed varies based on abscess location in the central nervous system. Major pathogens are bacteria encompassing *Streptococcus* and *Staphylococcus spp.* *Klebsiella pneumoniae* (*K. pneumoniae*) is involved in less than 1% of cases. *Klebsiella* is a rod-shaped Gram-negative bacterium that causes opportunistic infection in high-risk groups like Diabetes Mellitus, history of alcohol consumption, cirrhosis, and head trauma treated with craniotomy. (Wu et al., 2021) This case report discussed a rare occurrence of post-surgical infection on patient receiving pre-operative prophylaxis antibiotics, highlighting the importance of a quick life-saving intervention.

Case Report

A 50-year-old woman came to the emergency room unconscious two days ago. The patient also felt fever and progressive weakness on half of her right side of the body since a week ago, productive pus in a previous operation scar one month ago, and occasional headaches. She had a history of brain tumor excision surgery in 2016. The histopathology examination resulted in microcystic meningioma WHO grade I. Comorbidities such as diabetes Mellitus, hypertension, stroke, other tumors, lung tuberculosis, ear discharge, or teeth problems were denied. From the physical examination, the patient looked severely ill with altered consciousness of GCS 215, heart rate of 85 bpm, respiratory rate of 20 times per minute, body temperature of 37,3°C, saturation of 98% with 3 LPM oxygen support using nasal cannula. The overall head-to-toe examination was within

normal range. Neurologic examination findings showed meningeal signs with no nuchal rigidity, isochoric round pupils, 3mm/3mm, positive light and corneal reflexes, the right main type of facial palsy, and hard-to-evaluate lingual palsy. In physiologic reflex evaluation, BPR, TPR, KPR, and APR were all +2/+2. In pathologic reflex evaluation, only Babinsky sign was positive; +/- . Both Chaddock and Hoffman-Tromner were negative. The motoric examination resulted in right lateralization, while sensory and cerebellum function could hardly be evaluated. No abnormalities were found regarding the autonomous system.

Laboratory findings showed leukocytes of 13.710 and neutrophils of 79.9% with a CRP value of 7,6. The patient tested negative for Rapid HIV and three ways serology HIV tests. Thorax imaging showed no anomalies. However, a head CT scan using contrast showed a multiloculated ring enhancement lesion sized 5,8 x 6,9 x 5 in the left frontal lobe, perifocal edema that led to a 1.7 cm midline shift towards the right, and general brain edema (Figure 1.) After being informed of therapy options, surgery intervention was chosen to eliminate the abscess. Therefore, the patient underwent an open craniotomy to evacuate abscess. The patient was consulted with ENT and an oral surgeon to explore other possible infection sources. However, none was found.

Approximately 40 ccs of thick greenish pus outside the dura defect was detected intraoperatively. Microbiology culture showed positive *Klebsiella pneumoniae* sensitive to antibiotics such as amycasine, chloramphenicol, imipenem, and meropenem with resistance towards gentamycin, aztreonam, ampicillin, ampicillin-sulbactam, cephazolin, ceftazidime, cefotaxime, ceftriaxone, cefepime, tigecycline, ciprofloxacin, and levofloxacin. The patient was treated with the recommended antibiotics using 3x 2 grams of meropenem and 3 x 500 mg of metronidazole.

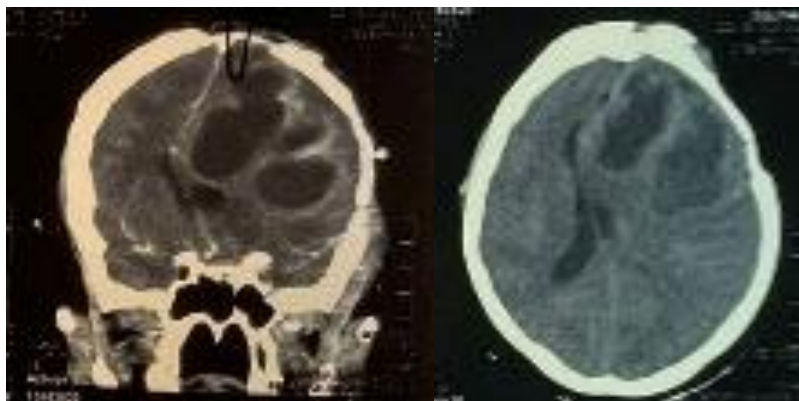


Figure 1. Head CT Scan with Contrast (a)coronal and (b) axial view

Discussion

The pathogen causing cerebral bacterial abscess varies according to geographic location, age, medical condition, surgical indications, and infection methods.(Muzumdar et al., 2011) For the last 10-15 years, otogenic abscess incidence has decreased while post-traumatic or post-surgical cerebral abscess

has risen.(Carpenter et al., 2007) In immunocompetent patients, almost all cases are caused by bacteria.(Sonnevile et al., 2017) In this case report, we elaborated on a cerebral abscess case in an immunocompetent woman with a history of tumor excision caused by *Klebsiella pneumoniae*. *K. pneumoniae* is a Gram-negative bacteria found especially in hospitals that tend to cause multiple abscesses in low immune system patients.(Wang et al., 2019) This bacteria is involved in less than 1% of cases. The risk factors of *K.pneumoniae* related abscess include diabetes mellitus, alcoholism, cirrhosis, and head trauma treated by craniotomy.(Wu et al., 2021)

A cerebral abscess is diagnosed using thorough anamnesis, physical examination, and adequate neuroimaging and laboratory evaluation. Sometimes, a diagnosis is made based on CT-Scan, MRI, and blood work findings due to various symptoms. Previous systematic review and meta-analysis reported elevated erythrocyte sedimentation rate, leukocytosis, elevated C-reactive protein (CRP), and positive blood culture. Further imaging examination will help further determine the localization, extension, and lesion characteristics. Contrast CT-Scan commonly found a hypodense nucleus surrounded by a thin contrast-enhancing ring mimicking capsule and perilesional edema of various degrees. Some features, such as leukocytosis, elevated CRP level, and similar CT-Scan findings, were observed in our patients. Hence supporting the diagnosis. (Brouwer et al., 2014)(Ruiz-Barrera et al., 2022)

The abscess size is the most crucial aspect of treating this infection. Abscesses bigger than 2.5 cm are managed by combining medications and a surgical approach. The recommended surgical procedure is craniotomy with abscess excision or stereotactic aspiration. Several factors, including location and abscess characteristics, should also be accounted for in deciding the correct surgical approach. However, open craniotomy is often preferred because of its low recurrence rate.(Cavuşoğlu et al., 2008) Therefore, this patient received intensive antibiotics and underwent a craniotomy.

Regardless of the patient's immune system condition, risk factors and presence of comorbidities like as chronic otitis media, mastoiditis, immunocompetent patients are still at risk of experiencing post-operative infection due to *Staphylococcus aureus*, *Streptococcus spp.* *Enterobacteriaceae* or *Clostridium spp.* Therefore, the administration of third-generation cephalosporin and metronidazole is justified.(Zhao et al., 2022) It has also been statistically proven to benefit patients with predisposition conditions.(Brouwer et al., 2014) Once the organism is identified, the antimicrobial therapy should be modified. We applied the concept to our patients. At first, she received 2 grams of ceftriaxone twice and 500 milligrams of metronidazole thrice a day. After the culture results, we changed the antibiotics regimen to 2 grams of meropenem twice and 500 milligrams of metronidazole thrice a day.

A combination of abscess removal with a size bigger than 2.5 cm and antibiotics administration for a minimum of 6 weeks was recorded as a practical therapy approach, reaching 90%.(Brouwer et al., 2014) This patient had undergone surgery and received empiric antibiotics for a week prior to receiving the first-line

antibiotic for two weeks. This treatment plan showed massive clinical improvement, specifically in consciousness level and motoric weakness.

Conclusion

Post-craniotomy infection is a complication that requires quick evaluation. Although the procedure was performed with the right technique, sterile method, and adequate prophylaxis antibiotics, a small portion of patients can still experience a severe infection. This case study proves that a common pathogen causing cerebral abscess, such as *Klebsiella pneumoniae* in immunocompromised patients, can also be found in immunocompetent patients. A better outcome is seen with quick intervention and the right therapy.

Acknowledgements

This work was supported by all the staffs of Department of Neurology Faculty of Medicine, Airlangga University - Dr. Soetomo Regional Public Hospital.

References

- Brouwer, M. C., Tunkel, A. R., McKhann, G. M., & van de Beek, D. (2014). Brain abscess. *The New England Journal of Medicine*, 371(5), 447–456. <https://doi.org/10.1056/NEJMra1301635>
- Carpenter, J., Stapleton, S., & Holliman, R. (2007). Retrospective analysis of 49 cases of brain abscess and review of the literature. *European Journal of Clinical Microbiology & Infectious Diseases: Official Publication of the European Society of Clinical Microbiology*, 26(1), 1–11. <https://doi.org/10.1007/s10096-006-0236-6>
- Cavuşoglu, H., Kaya, R. A., Türkmenoglu, O. N., Colak, I., & Aydin, Y. (2008). Brain abscess: Analysis of results in a series of 51 patients with a combined surgical and medical approach during an 11-year period. *Neurosurgical Focus*, 24(6), E9. <https://doi.org/10.3171/FOC/2008/24/6/E9>
- Dashti, S. R., Baharvahdat, H., Spetzler, R. F., Sauvageau, E., Chang, S. W., Stiefel, M. F., Park, M. S., & Bambakidis, N. C. (2008). Operative intracranial infection following craniotomy. *Neurosurgical Focus*, 24(6), E10. <https://doi.org/10.3171/FOC/2008/24/6/E10>
- Kolegium Neurologi Indonesia. (2019). *Modul Neuroinfeksi Program Pendidikan Dokter Spesialis Saraf*.
- Muzumdar, D., Jhawar, S., & Goel, A. (2011). Brain abscess: An overview. *International Journal of Surgery (London, England)*, 9(2), 136–144. <https://doi.org/10.1016/j.ijssu.2010.11.005>
- Ruiz-Barrera, M. A., Santamaría-Rodríguez, A. F., & Zorro, O. F. (2022). Brain abscess: A narrative review. *Neurology Perspectives*, 2(3), 160–167. <https://doi.org/10.1016/j.neurop.2022.01.010>
- Sonneville, R., Ruimy, R., Benzonana, N., Riffaud, L., Carsin, A., Tadié, J.-M., Piau, C., Revest, M., Tattevin, P., & ESCMID Study Group for Infectious Diseases of the Brain (ESGIB). (2017). An update on bacterial brain abscess in immunocompetent patients. *Clinical Microbiology and Infection: The Official Publication of the European Society of Clinical Microbiology and Infectious Diseases*, 23(9), 614–620. <https://doi.org/10.1016/j.cmi.2017.05.004>

- Valentino A & Angraini GP. (2019). Abses Otak. *Jurnal Ilmu Kedokteran*, 13, 75–86.
- Wang, B., Zhang, P., Li, Y., & Wang, Y. (2019). Klebsiella pneumoniae-induced multiple invasive abscesses: A case report and literature review. *Medicine*, 98(39), e17362. <https://doi.org/10.1097/MD.00000000000017362>
- Winn, H. R. (Ed.). (2017). *Neurological Surgery* (Seventh edition). Elsevier.
- Wu, C., Han, S., Baydur, A., & Lindgren, B. (2021). Klebsiella brain abscess in an immunocompetent patient: A case report. *Journal of Medical Case Reports*, 15(1), 44. <https://doi.org/10.1186/s13256-020-02633-0>
- Zhao, J., Huo, T., Luo, X., Lu, F., Hui, S., & Yang, B. (2022). Klebsiella pneumoniae-related brain abscess and meningitis in adults: Case report. *Medicine*, 101(2), e28415. <https://doi.org/10.1097/MD.00000000000028415>