

How to Cite:

Sonis, A. G., Stolyarov, E. A., Geringer, J., Alekseev, D. G., Ladonin, S. V., Sefedinova, M. Y., & Bezrukova, M. A. (2022). Postoperative bone defects' reconstruction in patients with focal form of chronic post-traumatic osteomyelitis. *International Journal of Health Sciences*, 6(S9), 2193–2202. <https://doi.org/10.53730/ijhs.v6nS9.12901>

Postoperative bone defects' reconstruction in patients with focal form of chronic post-traumatic osteomyelitis

Aleksandr G. Sonis

Dr. Habil., Prof., Head of Department of General Surgery of Samara State Medical University, Samara, Russian Federation

Email: a.g.sonis@samsmu.ru

Evgeniy A. Stolyarov

Dr. Habil., Prof., Head of Department of General Surgery of Samara State Medical University, Samara, Russian Federation

Email: e.a.stolyarov@samsmu.ru

Jean Geringer

Ph.D., Assoc. Prof., École nationale supérieure des mines de Saint-Étienne, Saint-Etienne cedex 2, France

Email: jalgeringer@hotmail.com

Denis G. Alekseev, Ph.D., Assoc. Prof., Department of General Surgery of Samara State Medical University, Samara, Russian Federation.

Corresponding author email: d.g.alekseev@samsmu.ru

Sergey V. Ladonin, Ph.D., Assoc. Prof., Department of General Surgery of Samara State Medical University, Samara, Russian Federation

Email: s.v.ladonin@samsmu.ru

Maria Yu. Sefedinova, Asst., Department of General Surgery of Samara State Medical University, Samara, 443099, Russian Federation

Email: m.yu.sefedinova@samsmu.ru

Maria A. Bezrukova, Ph.D., Assoc. Prof., Department of General Surgery of Samara State Medical University, Samara, Russian Federation

Email: m.a.bezrukova@samsmu.ru

Abstract--A prospective comparative analysis, i.e. the results of treatment of 68 patients, was carried out. The focal form of chronic post-traumatic osteomyelitis of the distal third of the tibia was focused. All patients were subjected to surgical debridement of the osteomyelitic focus on the variant of osteonecrectomy, followed by

myoplastic reconstruction of the formed bone defect with chopped autologous muscle. In 30 patients, the traditional method of myoplastic reconstruction was used, and in 38 patients, the improved one. We added autologous Platelet-Rich Plasma (hereinafter - PRP) to the muscle graft before placing it into the bone defect. After filling in the defect, we sutured a Resorbable Collagen Membrane (hereinafter - RCM) to its edges in order to seal the defect and additionally fix the muscle graft. The dynamics of changes in the structure and the rate of fixation of the muscle graft to the walls of the bone cavity, the duration of the local inflammatory response, the duration of hospitalization, short-term outcomes, and long-term results of treatment in the comparison groups were evaluated. When using the improved method of myoplastic reconstruction, a significant reduction in the time of homogenization of the muscle graft was noticed by 34.5% and its fixation to the walls of the bone defect by 43.1%, as well as a decrease in the duration of the local inflammatory reaction by 34.2%. The average duration of inpatient treatment was reduced by 24.7%. When assessing the immediate outcomes of treatment, the relative risk reduction was 23.6%, and when evaluating long-term results - 35.8%, respectively. The use of PRP and RCM in the complex of treatment measures in patients with chronic osteomyelitis is safe and effective. When the osteomyelitic process is localized in the areas of the limbs with a small volume of soft tissues, the reconstruction of the postoperative bone defects by using chopped autologous muscle, coupled with PRP and RCM, is the method of choice.

Keywords---Osteomyelitis, Osteonecrectomy, Bone Defects' Reconstruction, Platelet-Rich Plasma, Resorbable Collagen Membrane

1. Introduction

In the structure of general surgical pathology, a purulent-inflammatory natured diseases account for about 30%, of which up to 44% fall on such nosology as osteomyelitis. This disease, at the same time, is one of the most common and severe types of disorder of the musculoskeletal system (Wu et al., 2019; Maffulli et al., 2016; Felice et al., 2016).

Treatment of osteomyelitis includes the impact on all components related to the pathogenesis of the disease. The basis of the complex treatment measures is surgical intervention, which consists of sanify and, following it, reconstructive stages (Wu et al., 2019). At the first stage, sequesters and necrotic elements in the bone and surrounding soft tissues are removed, at the second stage, the formed bone cavity are reconstructed (Maffulli et al., 2016; Santosh & Ogle, 2017). In the case of process' localization in areas with a small volume of soft tissues (distal third of the tibia), free myoplasty becomes an option of choice. This method involves filling the bone cavity with patient's own minced muscle tissue (Mandell et al., 2018; Hung et al., 2017). Such a graft is plastic, easily takes the form of a bone's defect and fills it. On the other hand, the minced muscle is difficult to fix to the walls of the bone's defect. Also, bleeding from the surrounding tissues or an

inflammatory reaction can reject the graft (Bensman et al., 2021; Kovar et al., 2020). It is possible to prevent graft's rejection by using modern cellular and tissue technologies at the reconstructive stage of surgical intervention (Hofstee et al., 2020). An example of cellular technology is platelet-rich autologous plasma (hereinafter - PRP), and of a tissue technology - a resorbable collagen membrane (hereinafter - RCM) (Le et al., 2019; Foster et al., 2020; Egawa et al., 2019).

PRP is an autologous blood plasma with the platelet's concentration exceeds the baseline level and, due to this, has a local stimulating effect on regenerative and reparative processes. The role of platelets in tissue regeneration is due to the presence of growth factors and other active molecules (chemokines, arachidonic acid, fibrinogen, fibrin, etc.) deposited in α -granules, electron dense bodies, lysosomes and released locally at the site of injury. The stimulating effect of PRP is manifested if the concentration of platelets in it is more than 750,000 per μ l. (Everts et al., 2020; Lang et al., 2018).

The RCM is represented by heterogeneous type I collagen, devoid of antigenic load. On the one hand, the membrane, being a dense connective tissue structure, serves as a compact substance, preventing the muscle graft from leaving the bone defect during its transformation inside it. In addition, the RCM promotes the activation of the migration of osteoblasts along the collagen matrix, which leads to the restoration of the osteoid layer (Wessing et al., 2017; Sbricoli et al., 2020). This study aims at evaluating the effectiveness of the author's method of free myoplasty of the postoperative bone defects in patients with focal chronic osteomyelitis of the distal third of the tibia compared to the usual method.

2. Materials and methods

2.1. Patients' selection

The study is a prospective analysis of the results of treatment of 68 patients with focal form of chronic post-traumatic osteomyelitis of the distal third of the tibia. At the prehospital stage, all patients were subjected to the standard procedure of mandatory examinations required for surgical treatment - general clinical blood tests, computed tomography (hereinafter - CT) of the affected limb segment, fistulography.

All 68 study participants were randomly divided into two comparable groups. The observation group consisted of 38 people, the comparison group - of 30 people. The patients were treated in the surgical department of the chair and clinic of propaedeutic surgery of Samara State Medical University in the period from January 2018 to December 2019.

The comparison groups were comparable in age ($p \geq 0.05$): 52.29 ± 2.11 years in the comparison group and 53.06 ± 2.16 years in the observation group, as well as in gender ($p \geq 0.05$): the comparison group consisted of 7 (23.3%) women and 23 (76.7%) men; the observation group of 9 (23.7%) and 29 (76.3%) women and men respectively. The osteomyelitis focuses in 100% of episodes was localized in the distal third of the tibial diaphysis, while the average volume of the affected bone tissue, according to the data of CT studies, was comparable in both groups -

19.38±1.98 cm³ in the comparison group and 20.96±2.02 cm³ in the observation group. All study participants noted the presence of a functioning external fistulous tract. The etiological basis of the disease in both groups was a previous trauma (shattered fracture because of pedestrian accident), while the duration of persistence of the osteomyelitis process in all patients exceeded 6 months and was, in the comparison group, 1.23±0.16 years, and in the observation group - 1.56±0,22 years. The difference is statistically insignificant ($p \geq 0.05$). Before being included in the study, no surgical interventions in the focus of osteomyelitis were performed in the study participants. Also, the groups were completely comparable in any other parameters that could affect the study result.

2.2. Treatment options

The treatment options for osteomyelitis in both groups corresponded to generally accepted principles and consisted of surgical intervention and anti-infectious chemotherapy. The surgical method of treatment was the main one in both groups. The first stage of surgical intervention was carried out radical sanitation of the osteomyelitis focus with osteonecrectomy (figure 1). The fistula tract was excised after it was stained, sequestered bone, pathological granulations were removed, and the bone marrow canals were opened. The viability of bone tissue was determined by the appearance of capillary bleeding ("blood dew") from the walls of the formed bone defect. Additionally, the surgical wound was treated with solutions of antiseptics.

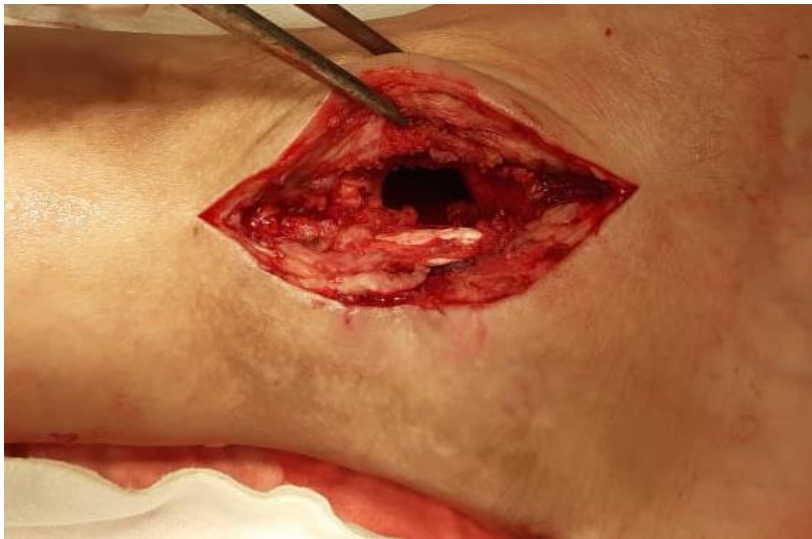

Figure 1: *Bone defect after osteonecrectomy*

This was followed by the second or the so-called reconstructive stage of the operation, when we sealed the bone defect formed after osteonecrectomy. In patients of the comparison group ($n = 30$ people), this stage was carried out according to the standard method. A portion of the vastus lateralis muscle was taken from the thigh (considering the cicatricial dystrophic changes in the operation area) on the healthy lower limb using a separate access. Perimysium, fascia, soft tissues and skin at the sampling site were sutured in layers. Further,

the mechanical grinding of muscle tissue was carried out. The minced autologous muscle was tightly filled in the postoperative bone defect.

In the patients of the observation group (n = 38 people), the following manipulations were performed during the reconstructive stage of surgery. The collection of muscle from the donor site and its grinding was carried out similarly to those in the comparison group. Before the operation, the patients were taken venous blood, and by the time of the bone defect sealing, PRP was prepared with a platelet concentration of ~1 407 640 per μl (with a standard deviation of 320 100 cells). PRP was mixed with minced autologous muscle, which, in turn, was placed into the bone defect. The compact bone substance along the perimeter of the postoperative defect was perforated with a thin bur, leaving 0.3-0.7 cm from the edge and with a step of 0.8-1.0 cm. The RCM was cut in accordance with the dimensions of the "window" in the bone's compact substance and fixed with ligatures of absorbable suture material through burr-formed holes. The ligatures were tied in such a way that the RCM had the form of a "flap" or "sail" (fig.2-4). This method of myoplastic reconstruction of postoperative bone defect was patented by authors (No. RU2627815C1 from 11.08.2017).

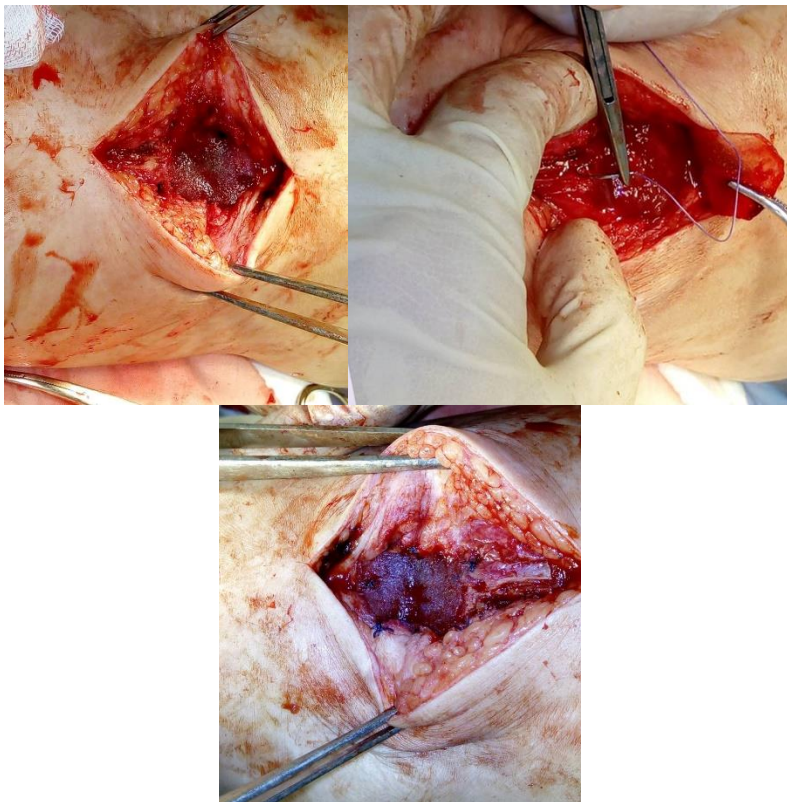


Figure 2-4: *Bone defect sealed by minced autologous muscle combined with PRP and covered by sewn RCM.*

The intervention in both groups was completed with layer-by-layer wound closure (fascia, skin). If necessary, local skin grafting was performed to close the

operation wound. In the postoperative period, all patients subjected immobilization of the operated limb from the tips of the toes to the popliteal fossa. To influence the causative agent of the disease, all patients were prescribed anti-infectious chemotherapy drugs, considering the recommendations of the current treatment procedures and medical reference literature (drug formulary).

2.3. Analysis stage

The study by design was a prospective observational study with an assessment and analysis of the local patterns, short-term treatment outcomes and its long-term results. To assess the effectiveness of the suggested method of reconstruction in a complex measure of treatment, we investigated the dynamics of two parameters in comparison by groups (Table 1).

Table 1
Local criteria of effectiveness

Object	Parameter	Assessment method
Muscle graft	Dynamics of structural changes and fixation to the walls of the bone defect	Echography
Surrounding soft tissue	Duration of local inflammatory response	Thermography

The assessment of the short-term outcomes of the complex treatment was carried out considering the nature of the postoperative wound healing. The result was considered favorable when the wound healed by primary or secondary intention; unfavorable - if suppuration developed in the postoperative bone cavity with rejection of the muscle graft.

Patients with favorable short-term treatment outcomes were re-examined at least 1 year after surgery, evaluating long-term results. If the patient had no clinical signs of the disease relapse within the established follow-up period, and the X-ray or CT examination did not reveal signs of recurrence of the osteomyelitis process around the intervention area, the result was considered satisfactory. If, during the indicated period, the patient had exacerbations of chronic osteomyelitis, and X-ray or CT examination revealed focuses of necrosis and sequestration around the intervention area, the result was considered unsatisfactory.

The next step was to compare the data obtained between the groups using descriptive statistics methods. Calculated relative values, average values and standard errors. To determine the statistical significance of differences in mean values when comparing samples, the Student's test was used; to compare two relative indicators - Fisher's exact test. Differences between values were considered statistically significant at $p \leq 0.05$. We also calculated such indicators as odds ratio (hereinafter - OR), relative risk (hereinafter - RR), with the calculation of the boundaries of the 95% confidence interval (hereinafter - CI) and relative risk reduction (hereinafter - RRR) and number needed to treat (hereinafter - NNT).

3. Results and Discussions

Based on the outcomes of the study, the following results were obtained. Echography data showed that the muscle transplant becomes homogeneous in the comparison group at 10.12 ± 1.06 days, in the observation group - at 7.64 ± 1.16 days after surgery (reduction of graft's homogenization time was 24.5%), which was manifested by the absence of anechoic fluid layers (blood, exudate) between echo-positive fragments of muscle tissue. The muscle transplant was fixed to the walls of the bone defect at 14.02 ± 1.89 days in the comparison group and at 7.98 ± 1.64 days in the observation group (reduction of graft's fixing time was 43.1%), as evidenced by the disappearance of the anechoic layer of fluid between the transplant and the walls of the bone defect. The difference in both cases is statistically significant ($p \leq 0.05$).

The results of thermography in the groups indicated that the local temperature in the distal third of the operated limb in patients in the groups returned to the initial (preoperative) values for different periods of time. So, in patients of the comparison group, this occurred, on average, by 7.54 ± 1.08 days, and in patients of the observation group - by 4.96 ± 1.16 days (reduction of local temperature normalization period was 43.2%). The difference, inpatient vs. observation groups, is statistically significant ($p \leq 0.05$).

When analyzing the effectiveness of complex treatment schemes in patients with chronic focal post-traumatic osteomyelitis, the following results were obtained. Favorable short-term outcomes of complex treatment in the comparison group were observed in 23 patients (76.7%), in the observation group - in 36 patients (94.7%), unfavorable - in 7 (23.3%) and 2 (5.3%) patients of patients, respectively. The difference is statistically significant ($p \leq 0.05$) in both cases.

Considering the treatment outcomes, the RRR was 23.6%, the NNT indicator was found to be equal to 6 patients. The OR parameter was 5.48 (>1). Patients in the observation group were more likely to develop a favorable short-term treatment outcome. The revealed dependence was statistically significant ($p \leq 0.05$), since the 95% CI did not include 1 (the value of its lower limit was 1.09, the upper one was 28.76). The RR, Relative Risk, was 1.23, that indicates a higher likelihood of developing favorable short-term treatment outcomes in patients of the observation group. This relationship, however, was not statistically significant ($p \geq 0.05$), since the 95% CI included 1 (the value of its lower limit was 1.00, the upper one was 1.53).

The average duration of inpatient treatment of chronic osteomyelitis in the comparison group was 21.56 ± 1.86 days, in the observation group - 16.24 ± 1.38 days (reduction of treatment duration was 24.7%). The difference between the groups for this indicator is statistically significant ($p \leq 0.05$).

Long-term results of complex treatment were studied in patients with favorable short-term treatment outcomes, that is in 59 people: 23 from the comparison group and 36 from the observation group. Satisfactory long-term results of treatment (remission) were obtained in 16 (69.6%) of 23 patients in the comparison group and in 34 (92.8%) of 36 patients in the observation group.

Unsatisfactory long-term results (relapses) were observed in 7 (30.4%) of 23 patients in the comparison group and in 2 (7.2%) of 36 patients in the observation group with satisfactory short-term treatment outcomes. The difference is statistically significant in both cases ($p \leq 0.05$).

Evaluation of long-term results of treatment showed RRR in 35.8%. The NNT indicator was equal to 4 patients. The OR parameter was 7.43 (>1). The chance of developing a satisfactory long-term result was higher in the patients of the observation group. The observed dependence was statistically significant ($p \leq 0.05$), since the 95% CI did not include 1 (the value of its lower limit was 1.39, the upper one was 39.91). The RR was 1.36, which indicates a higher probability of developing satisfactory long-term results in patients of the observation group. This relationship was also statistically significant ($p \leq 0.05$), since the 95% CI did not include 1 (the value of its lower limit was 1.02, the upper one was 1.80).

4. Conclusion

Thus, the use of the author's method of free myoplasty in a complex of treatment measures in patients with chronic post-traumatic osteomyelitis of the distal third of the tibia significantly accelerates the processes of homogenization of the muscle transplant and its fixation to the walls of the bone cavity and reduces the duration of the local inflammatory reaction and the length of hospital stay. The results of complex treatment of chronic osteomyelitis in general, both in the case of short-term outcomes and long-term results, also turned out to be significantly better in the observation group. The results of the study allow us to recommend the inclusion of the author's method of free muscle plastics in the complex of treatment measures in patients with chronic post-traumatic osteomyelitis of the distal third of the tibia.

The use of PRP and RCM in the complex of treatment measures in patients with chronic osteomyelitis is safe and effective. When the osteomyelitic process is localized in the areas of the limbs with a small volume of soft tissues, the reconstruction of the postoperative bone defects by using chopped autologous muscle, coupled with PRP and RCM, is the method of choice.

Funding

Nil

Conflict of interest

The authors declare they have no conflict of interests

Acknowledgements

The authors wish to appreciate the Clinics of Samara state medical university for creating the most favorable and constructive conditions for conducting the study

References

Wu, Z. Q., Zeng, D. L., Yao, J. L., Bian, Y. Y., Gu, Y. T., Meng, Z. L., Fu, J., & Peng, L. (2019). Research Progress on Diagnosis and Treatment of Chronic

- Osteomyelitis. *Chinese medical sciences journal = Chung-kuo i hsueh k'o hsueh tsa chih*, 34(3), 211–220. <https://doi.org/10.24920/003493>.
- Maffulli, N., Papalia, R., Zampogna, B., Torre, G., Albo, E., & Denaro, V. (2016). The management of osteomyelitis in the adult. *The surgeon : journal of the Royal Colleges of Surgeons of Edinburgh and Ireland*, 14(6), 345–360. <https://doi.org/10.1016/j.surge.2015.12.005>.
- Rivas Felice, J., González Herranz, P., Mejía Casado, A., Pérez Navarro, R., & Hernández Díaz, R. (2017). Chronic recurrent osteomyelitis: A diagnostic and therapeutic challenge. *Osteomielitis crónica recurrente: un reto diagnóstico y terapéutico. Revista española de cirugía ortopédica y traumatología*, 61(1), 35–42. <https://doi.org/10.1016/j.recot.2016.07.004>.
- Santosh, A. B., & Ogle, O. E. (2017). *Clinical Microbiology for the General Dentist. Dental clinics of North America*, 61(2), xv–xvii. <https://doi.org/10.1016/j.cden.2017.01.001>.
- Mandell, J. C., Khurana, B., Smith, J. T., Czuczman, G. J., Ghazikhanian, V., & Smith, S. E. (2018). Osteomyelitis of the lower extremity: pathophysiology, imaging, and classification, with an emphasis on diabetic foot infection. *Emergency radiology*, 25(2), 175–188. <https://doi.org/10.1007/s10140-017-1564-9>.
- Hung, D. Z., Tien, N., Lin, C. L., Lee, Y. R., Wang, C. C., Chen, J. J., & Lim, Y. P. (2017). Increased risk of chronic osteomyelitis after hip replacement: a retrospective population-based cohort study in an Asian population. *European journal of clinical microbiology & infectious diseases : official publication of the European Society of Clinical Microbiology*, 36(4), 611–617. <https://doi.org/10.1007/s10096-016-2836-0>.
- Bensman, V. M., Savchenko, Y. P., & Malyshko, V. V. (2021). Anterior prompt for debridement and myoplasty femoral neck and head osteomyelitis. *Wounds and Wound Infections. The Prof. B.M. Kostyuchenok Journal*, 8(2), 34–40. <https://doi.org/10.25199/2408-9613-2021-8-2-34-40>.
- Kovar, A., Colakoglu, S., & Iorio, M. L. (2020). Choosing between Muscle and Fasciocutaneous Free Flap Reconstruction in the Treatment of Lower Extremity Osteomyelitis: Available Evidence for a Function-Specific Approach. *Journal of reconstructive microsurgery*, 36(3), 197–203. <https://doi.org/10.1055/s-0039-1698469>.
- Hofstee, M. I., Muthukrishnan, G., Atkins, G. J., Riool, M., Thompson, K., Morgenstern, M., Stoddart, M. J., Richards, R. G., Zaat, S., & Moriarty, T. F. (2020). Current Concepts of Osteomyelitis: From Pathologic Mechanisms to Advanced Research Methods. *The American journal of pathology*, 190(6), 1151–1163. <https://doi.org/10.1016/j.ajpath.2020.02.007>.
- Le, A., Enweze, L., DeBaun, M. R., & Dragoo, J. L. (2019). Platelet-Rich Plasma. *Clinics in sports medicine*, 38(1), 17–44. <https://doi.org/10.1016/j.csm.2018.08.001>.
- Foster, A. L., Moriarty, T. F., Trampuz, A., Jaiprakash, A., Burch, M. A., Crawford, R., Paterson, D. L., Metsemakers, W. J., Schuetz, M., & Richards, R. G. (2020). Fracture-related infection: current methods for prevention and treatment. *Expert review of anti-infective therapy*, 18(4), 307–321. <https://doi.org/10.1080/14787210.2020.1729740>.
- Egawa, S., Hirai, K., Matsumoto, R., Yoshii, T., Yuasa, M., Okawa, A., Sugo, K., & Sotome, S. (2020). Efficacy of Antibiotic-Loaded Hydroxyapatite/Collagen Composites Is Dependent on Adsorbability for Treating Staphylococcus aureus

- Osteomyelitis in Rats. *Journal of orthopaedic research : official publication of the Orthopaedic Research Society*, 38(4), 843–851. <https://doi.org/10.1002/jor.24507>.
- Everts, P., Onishi, K., Jayaram, P., Lana, J. F., & Mautner, K. (2020). Platelet-Rich Plasma: New Performance Understandings and Therapeutic Considerations in 2020. *International journal of molecular sciences*, 21(20), 7794. <https://doi.org/10.3390/ijms21207794>.
- Lang, S., Loibl, M., & Herrmann, M. (2018). Platelet-Rich Plasma in Tissue Engineering: Hype and Hope. *European surgical research. Europäische chirurgische Forschung. Recherches chirurgicales europeennes*, 59(3-4), 265–275. <https://doi.org/10.1159/000492415>.
- Wessing, B., Lettner, S., & Zechner, W. (2018). Guided Bone Regeneration with Collagen Membranes and Particulate Graft Materials: A Systematic Review and Meta-Analysis. *The International journal of oral & maxillofacial implants*, 33(1), 87–100. <https://doi.org/10.11607/jomi.5461>.
- Sbricoli, L., Guazzo, R., Annunziata, M., Gobbato, L., Bressan, E., & Nastri, L. (2020). Selection of Collagen Membranes for Bone Regeneration: A Literature Review. *Materials (Basel, Switzerland)*, 13(3), 786. <https://doi.org/10.3390/ma13030786>.