

How to Cite:

Damayanti, D., Prakoeswa, C. R. S., Anggraeni, S., Umborowati, M. A., & Rahmi, A. M. (2022). Successful treatment of secukinumab in severe plaque psoriasis: A case report. *International Journal of Health Sciences*, 6(S6), 10754–10762.
<https://doi.org/10.53730/ijhs.v6nS6.12902>

Successful treatment of secukinumab in severe plaque psoriasis: A case report

Damayanti

Department of Dermatology and Venereology, Faculty of Medicine Airlangga University/ Dr. Soetomo General Academic Hospital, Surabaya, Indonesia
*Corresponding author email: damayanti@fk.unair.ac.id

Cita Rosita Sigit Prakoeswa

Department of Dermatology and Venereology, Faculty of Medicine Airlangga University/ Dr. Soetomo General Academic Hospital, Surabaya, Indonesia

Sylvia Anggraeni

Department of Dermatology and Venereology, Faculty of Medicine Airlangga University/ Dr. Soetomo General Academic Hospital, Surabaya, Indonesia

Menul Ayu Umborowati

Department of Dermatology and Venereology, Faculty of Medicine Airlangga University/ Dr. Soetomo General Academic Hospital, Surabaya, Indonesia

Alfina Multaza Rahmi

Department of Dermatology and Venereology, Faculty of Medicine Airlangga University/ Dr. Soetomo General Academic Hospital, Surabaya, Indonesia

Abstract--Psoriasis is a persistent, chronic condition that manifests on the skin, joints, and other visible places that compromises the quality of life. The vast understanding of the pathophysiology of psoriasis has led to a rise in the use of biological therapy in treating psoriasis in recent years. A 48-year-old woman with severe plaque psoriasis was previously treated with methotrexate and phototherapy for 3 months, however, the treatment showed no significant improvement. The patient was then treated with a biological agent, namely secukinumab, with a dose of 150 mg weekly for 5 weeks followed by one dose a month later. The symptoms were improved considerably after 10 weeks of observation, which indicated by the decrease in Psoriasis Area Severity Index (PASI) score and the Dermatology Life Quality Index (DLQI) score. There was no significant side effect during the observation. This case showed that secukinumab therapy at a dose of 150 mg can successfully treat severe plaque psoriasis patient.

Keywords---biologic agents, human, disease, psoriasis, secukinumab.

Introduction

Psoriasis is a common inflammatory disease that is immunologically mediated (Gudjonsson & Elder, 2019). It is characterized by erythematous plaques covered in white, thick squamous layers, which develop as a result of epidermal proliferation and differentiation problems (Prakoeswa et al., 2021). Psoriasis is a persistent, chronic condition that manifests on the skin, joints, and other visible places that compromises the quality of life (QoL). The presently available psoriasis treatment reduces disease activity and lessens symptoms, like other immune-mediated complex diseases, and there is no definitive cure (Meneguín et al., 2020).

Around 125 million individuals worldwide are affected by psoriasis, a prevalent chronic inflammatory disease with incidence rates of 0.3% to 0.6% in various racial groups (Prakoeswa et al., 2021). A study in Indonesia reported that psoriasis is more common in women than men. The illness might occur at any stage of life, but it most frequently affected people between the ages of 26 and 35. Psoriasis vulgaris is the most prevalent of the several kinds of psoriasis (Rizqia et al., 2020). There are several medications that can be used for psoriasis, most often topical corticosteroids (Weigle & McBane, 2013). Methotrexate and cyclosporin A are recommended as the first line of systemic medication, while sulfasalazine, mycophenolate mofetil, and acitretin are the second line. Phototherapy can be performed as a combination treatment with systemic medication, while biological agents can be used if there is no significant response from these combinations. Currently, there are six types of biologic agents available in Indonesia, namely adalimumab, etanercept, infliximab, secukinumab, ustekinumab, and guselkumab (Siswati et al., 2021). Secukinumab has proven to be safe and effective in treating psoriasis symptoms over the long term (Thaci et al., 2019). Here, we present a case report of a 48-year-old woman with severe plaque psoriasis who was successfully treated with secukinumab.

Case Report

A 48-year-old woman came to the Dermatology and Venereology Outpatient Clinic at Dr. Soetomo General Academic Hospital Surabaya, Indonesia, with a chief complaint of erythematous plaque with white and silvery scales on her scalp, face, neck, trunk, upper and lower extremities for the last 1 month. The complaint started from small erythematous plaques on her trunk that multiplied, became wider, thicker, and spread throughout her body and head. Thick white scales formed on top of the erythematous plaques. The patient was previously treated by a dermatologist with folic acid, methisoprinol, urea cream 10%, and oral antihistamine for 2 weeks, but there was no significant improvement. The patient was then referred to Dr. Soetomo General Academic Hospital Surabaya, Indonesia, and was diagnosed with severe plaque psoriasis.

On the patient's first visit, the Psoriasis Area Severity Index (PASI) score was 39.9 and the Dermatology Life Quality Index (DLQI) score was 28. The patient also

suffered from diabetes mellitus type 2 for two years and regularly received insulin injections. The blood examination showed no abnormalities and the histopathology examination of the skin tissue revealed hyperkeratosis, acanthosis, spongiosis, and psoriasiform hyperplasia on the epidermal layer. In the dermal layer, the blood vessels were dilated with perivascular lymphocyte infiltration. These findings support the diagnosis of psoriasis vulgaris (Fig 1). The patient was treated with a combination of oral methotrexate at a dose of 15 mg per week and phototherapy two times per week. A favorable result was observed after 4 months of methotrexate administration and phototherapy, with no abnormalities in the liver function being found. The patient almost reached PASI 90 (PASI score decreased to 5) and the DLQI score decreased to 5.

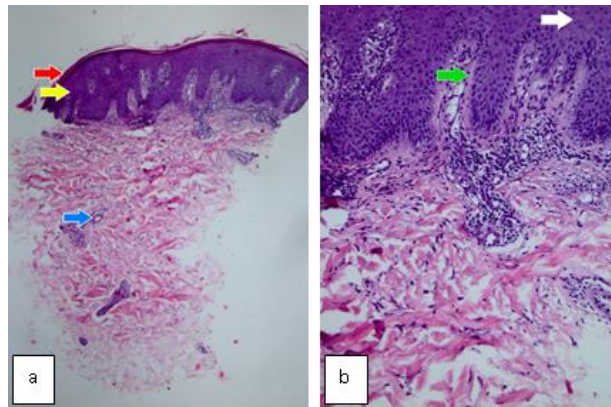


Figure 1. The histopathological examination showed parakeratosis (red arrow), acanthosis (yellow arrow), dilated capillary vessel (blue arrow), elongated rete ridge in psoriasiform hyperplasia (green arrow), and spongiosis (white arrow). The skin tissue was examined with 40x magnification (a) and 200x magnification (b)

Consequently, the patient complained of toothache, and the erythematous plaque with silvery scales reappeared. The PASI and DLQI scores were elevated once again (PASI score 20.3 and DLQI score 15) and there was no significant improvement in the symptoms after methotrexate administration and phototherapy for three months. Therefore, a decision to treat the patient with a biological agent, namely secukinumab, was made. At the time of starting the secukinumab treatment, the physical examination revealed multiple erythematous plaques with silvery scales with a PASI score of 14.7 and a DLQI score of 16 (Fig 2a). Before starting the treatment with secukinumab, the patient underwent a screening. From the peripheral blood smear examination, there was no suspicion of malignancy. The chest X-ray showed no tuberculosis (TB) infection. The blood examination was within normal limits, specifically, hemoglobin (Hb) 11.6 g/dL, white blood cell (WBC) 4,450/ μ L, and platelet 350,000/ μ L. The liver function test showed aspartate aminotransferase (AST) 26 U/L and alanine aminotransferase (ALT) 29 U/L. The kidney function test was blood urea nitrogen (BUN) 6 mg/dL and serum creatinine (SC) 0.8 mg/dL. The patient had gone through menopause 5 years ago. The results for Hepatitis B virus, Hepatitis C virus, and HIV tests were non-reactive. The random blood glucose was 278 mg/dL. The C-reactive protein (CRP) was 0.3, and the

electrolytes for sodium, potassium, and chloride were 139 mmol/L, 4.1 mmol/L, and 103 mmol/L, respectively.

The patient received five subcutaneous injections of secukinumab at a dose of 150 mg weekly, followed by one subcutaneous injection at a dose of 150 mg a month later. Improvements on the patient's skin lesion can be seen in week three (Fig 2b). Two weeks after the last injection, the patient showed improvement with PASI 60 (PASI score decreased to 6) and the DLQI score decreased to 0 (Table 1, Fig 2c). The blood examination after secukinumab therapy was within normal limit (Hb 12.4, WBC 5,620/ μ L, platelet 381,000/ μ L, BUN 9 mg/dL, SC 0.85 mg/dL, sodium 141 mmol/l, potassium 4.3 mmol/l, chloride 100 mmol/l, AST 16 U/L, ALT 20 U/L). However, there was an increase in blood glucose tests, specifically the fasting blood glucose of 339 mg/dL and HbA1c of 12.6%.

Table 1
The patient's PASI and DLQI score progression

Week	PASI	DLQI	Secukinumab Injection 150mg
0	14.7	16	I
1	14.1	14	II
2	12.9	8	III
3	11.5	5	IV
4	10.3	3	V
8	8.4	1	VI
10	6	0	two weeks after the last injection

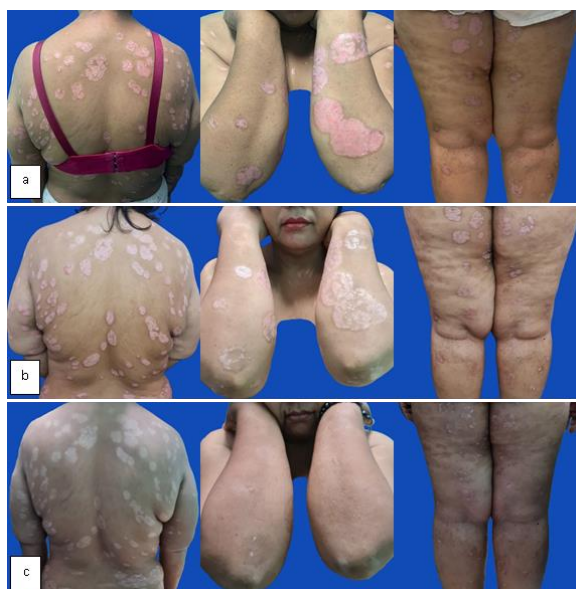

Figure 2. The physical examination of the patient (a) before the secukinumab treatment, (b) after the 4th injection, and (c) two weeks after the last injection of secukinumab

Discussion

The quality of life (QoL) can be negatively impacted by psoriasis, a chronic and recurrent condition that affects the skin, joints, and other visible regions of the body. Dermatoses may contribute to negative feelings like anxiety, melancholy, or even depressive symptoms and it is assumed that they can affect one's self-image and self-esteem. Consequently, the perception of QoL is seen to be a crucial factor in dermatology (Meneguín et al., 2020). A study in China reported on QoL in patients with moderate-to-severe psoriasis. The study examined many aspects of patients' lives that psoriasis affected including the symptoms, management of the symptoms, functioning, activities of daily living, psychological and social impact, as well as finances and employment. The findings of the study demonstrated that psoriasis had a negative impact on patients' lives and lowered the QoL (Zhong et al., 2021).

Psoriasis can be treated topically, systemically, or with phototherapy. Treatment is given based on the area of the body, especially psoriasis vulgaris. Biologic agents are protein products derived from living things, namely humans, plants, animals, or microorganisms. Biological systemic therapy has several advantages such as excellent therapeutic response (reaching PASI 90 or even 100), relatively safer, and minimal side effects compared to non-biological systemic therapy. In Indonesia, biologic agents are indicated for moderate to severe psoriasis cases with at least one of the following criteria: (1) adult patients who do not respond well to at least two standard systemic therapies such as cyclosporin A, methotrexate, or phototherapy, (2) intolerant or contraindicated to conventional systemic treatment (Novianto et al., 2021).

Secukinumab is developed from human antibodies anti-IL-17A IgG1 monoclonal antibodies (antibodies produced by identical immune cells that are all clones of individual stem cells) that particularly bind and neutralize IL-17A. Interleukin-17A plays an important role in the proinflammatory cytokine in the pathogenesis of psoriasis. Keratinocytes activated by Interleukin-17A, causing hyperproliferation and excess production of antimicrobial peptides, cytokines, and chemokines, which activates other immune cells, resulting in the inflammation of psoriasis. Interleukin-17 is a proinflammatory cytokine secreted by T-helper-17 (Th17) cells. Under the effects of IL-6 and transforming growth factor- β , CD4 T cells turned into Th17 cells and stimulate the expression of interleukin-23 receptors (IL-23R) and IL-17. Apart from T-cells, IL-17 is also released by mast cells and neutrophils. Interleukin-17 and its receptors are also presented in the synovial tissue, and the IL-17 pathway is suggested to be involved in the pathogenesis of psoriatic arthritis. Interleukin-17 may release various effectors that can generate inflammation of joints, impair, and change the structure of tissues. The binding of IL-17A by secukinumab prevents interactions with IL-17 receptor, which will prevent the release of other proinflammatory cytokines, chemokines, and mediators of tissue damage and lowers IL-17A's role in the development of this inflammatory disease (Kofoed et al., 2015; McInnes et al., 2015; Rønholt & Iversen, 2017; Shirley & Scott, 2016; Yunita & Anggraeni, 2022).

Biologic agents are strictly contraindicated for pregnant or nursing women, children under the age of 18, and individuals with systemic diseases, particularly

TB, hepatitis, HIV, cancer, or neurological disease (Novianto et al., 2021). Supporting tests, such as histology, anti-streptolysin O (ASTO) titers, albumin, fat profiles, uric acid, full blood counts, total urine, liver function tests (AST/ALT), renal function tests (BUN/SC ratio), and serum electrolytes, should be performed before treatment. Additionally, patients are recommended to perform laboratory controls, such as pregnancy tests, hypersensitivity screening, skin cancer, active and chronic infections, contraception, lactation, as well as immunization requirements. A comprehensive blood screening (Hb, hematocrit, leukocytes, platelets), CRP, liver enzymes, creatinine serum, pregnancy test, complete urine, Hepatitis B and C, HIV, and TB test are all required during the therapy. The use of contraception is advised for twenty weeks after the secukinumab therapy has finished (Nast et al., 2017; Yunita & Anggraeni, 2022).

Secukinumab has successfully treated moderate-to-severe plaque psoriasis, as seen by the improvement of PASI scores, and has shown immediate and effective clinical improvement as well as long-term maintenance (Augustin et al., 2020). In this case, secukinumab with a dose of 150 mg per injection for five consecutive weeks and one injection one month later was given to the patient. The symptoms improved considerably after 10 weeks of observation, which was indicated by the decrease in the PASI score (14.7 to 6) and DLQI score (16 to 0). A randomized controlled trial reported significant improvement in plaque psoriasis patients with secukinumab 300 mg and 150 mg compared to placebo at week 12 (efficacy endpoint PASI 75). According to the study, the percentage of patients who reached PASI 75 at week 12 was 81.6% with secukinumab 300 mg and 71.6% with secukinumab 150 mg. Furthermore, each secukinumab-dose group had a significantly higher percentage of patients with a DLQI score of 0 or 1 compared to the placebo group, suggesting no worsening of health-related QoL (Langley et al., 2014). These findings showed that secukinumab at a dose of 150 mg can provide equally good efficacy similar to the higher dose.

It is important to note that metabolic patient features like obesity, metabolic syndrome, diabetes, or hyperuricemia can all contribute to the worsening of systemic inflammation in psoriasis patients (Gerdes et al., 2019). The patient in this case had type 2 diabetes and had been receiving insulin injections for two years before the treatment. According to a study, secukinumab therapy demonstrated a shift towards reducing fasting plasma glucose levels compared to placebo treatment over the first 12 weeks in people with diabetes. In the general population, secukinumab therapy showed no effect on fasting plasma glucose, with constant levels seen throughout 52 weeks of observation (Gerdes et al., 2019). However, an increase in blood glucose was observed in this patient, which might be affected by factors other than secukinumab therapy.

When administering secukinumab, it is necessary to evaluate the side effects that may occur. Post-administration of secukinumab should be monitored for immediate and long-term side effects on a regular basis, both clinically and laboratory tests (Siswati et al., 2021). Upper respiratory infections including nasopharyngitis and rhinitis are the most frequent side effects of secukinumab, followed by oral herpes, rhinorrhea, diarrhea, and urticaria. The less common side effects are conjunctivitis, otitis externa, tinea pedis, neutropenia, and oral

candidiasis (Nast et al., 2017; Yunita & Anggraeni, 2022). In this patient, there were no significant side effects during the 10 weeks of observation.

Conclusion

This case demonstrated a successful secukinumab therapy at a dose of 150 mg as a treatment for severe plaque psoriasis.

Acknowledgments

The authors would like to express our gratitude to Dr. Soetomo General Academic Hospital and Faculty of Medicine Universitas Airlangga, Surabaya, Indonesia.

Consent

Written informed consent has been obtained for the patient's information and photographs to be published.

References

- Augustin, M., Jullien, D., Martin, A., Peralta, C. (2020). Real-world evidence of secukinumab in psoriasis treatment – a meta-analysis of 43 studies. *Journal of the European Academy of Dermatology and Venereology*, 34(6), 1174–1185. <https://doi.org/10.1111/jdv.16180>
- Gerdes, S., Pinter, A., Papavassilis, C., & Reinhardt, M. (2020). Effects of secukinumab on metabolic and liver parameters in plaque psoriasis patients. *Journal of the European Academy of Dermatology and Venereology*, 34(3), 533–541. <https://doi.org/10.1111/jdv.16004>
- Gudjonsson, J. E., & Elder, J. T. (2019). Psoriasis. In Kang, S., Amagai, M., D, Bruckner, A. L., MD, Enk, A. H., Margolis, D. J., McMichael, A. J., Orringer, J. S (Eds.). *Fitzpatrick Dermatology*. (9th ed., Vol. 1, pp. 457–497). McGraw-Hill Education.
- Kofoed, K., Skov, L., & Zachariae, C. (2015). New drugs and treatment targets in psoriasis. *Acta dermato-venereologica*, 95(2), 133–139. <https://doi.org/10.2340/00015555-1931>
- Langley, R. G., Elewski, B. E., Lebwohl, M., Reich, K., Griffiths, C. E., Papp, K., Puig, L., Nakagawa, H., Spelman, L., Sigurgeirsson, B., Rivas, E., Tsai, T. F., Wasel, N., Tyring, S., Salko, T., Hampele, I., Notter, M., Karpov, A., Helou, S., Papavassilis, C., FIXTURE Study Group. (2014). Secukinumab in plaque psoriasis--results of two phase 3 trials. *The New England journal of medicine*, 371(4), 326–338. <https://doi.org/10.1056/NEJMoa1314258>
- McInnes, I. B., Mease, P. J., Kirkham, B., Kavanaugh, A., Ritchlin, C. T., Rahman, P., van der Heijde, D., Landewé, R., Conaghan, P. G., Gottlieb, A. B., Richards, H., Pricop, L., Ligozio, G., Patekar, M., Mpfu, S., & FUTURE 2 Study Group. (2015). Secukinumab, a human anti-interleukin-17A monoclonal antibody, in patients with psoriatic arthritis (FUTURE 2): a randomised, double-blind, placebo-controlled, phase 3 trial. *Lancet (London, England)*, 386(9999), 1137–1146. [https://doi.org/10.1016/S0140-6736\(15\)61134-5](https://doi.org/10.1016/S0140-6736(15)61134-5)
- Meneguín, S., de Godoy, N.A., Pollo, C. F., Miot, H. A., de Oliveira, C. (2020). Quality of life of patients living with psoriasis: a qualitative

- study. *BMC Dermatology*, 20(22). <https://doi.org/10.1186/s12895-020-00116-9>
- Nast, A., Spuls, P. I., van der Kraaij, G., Gisondi, P., Paul, C., Ormerod, A. D., Saiag, P., Smith, C. H., Dauden, E., de Jong, E. M., Feist, E., Jobling, R., Maccarone, M., Mrowietz, U., Papp, K. A., Reich, K., Rosumeck, S., Talme, T., Thio, H. B., van de Kerkhof, P., Werner, R. N., Dressler, C. (2017). European S3-Guideline on the systemic treatment of psoriasis vulgaris - Update Apremilast and Secukinumab - EDF in cooperation with EADV and IPC. *Journal of the European Academy of Dermatology and Venereology: JEADV*, 31(12), 1951–1963. <https://doi.org/10.1111/jdv.14454>
- Novianto, E., Budianti, W. K., Fitri, E. M., Wiryadi, B. E., Soebaryo, R. W., Puspongoro, E. H. D., Effendi, E. H., Rahmayunita, G., Irawan, A., Prakoeswa, C. R. S., Kariosentono, H., Roesyanto, I. D., Adiguna, M. S., Adji, A., Rofiq, A., Nopriyati, Anum, Q., Sugianto, Y. F. R., Djohan, Radiono, S., Triwahyudi, D., Anindya, S., Debinta, A. A., Effendy, I. (2021). Indonesian clinical practice guidelines for systemic and biologic agents for adults with plaque psoriasis. *Journal of General Procedural Dermatology Venereology Indonesia*, 5(3);152–170. <http://dx.doi.org/10.19100/jdvi.v5i3.244>
- Prakoeswa, C. R. S., Hidayati, A. N., Hendaria, M. P., Listiawan, M. Y., Utomo, B., Damayanti, Citrashanty, I., Anggraeni, S., Umborowati, M. A., & Ervianti, E. (2021). The Profile of Psoriasis Vulgaris Patients: A Descriptive Study. *Berkala Ilmu Kesehatan Kulit Dan Kelamin*, 33(3), 173–181. <https://doi.org/10.20473/bikk.V33.3.2021.173-181>
- Rizqia, U., Kurniawan, R., Fitri., E. W. (2020). Profil Penderita Psoriasis di Poli Kulit dan Kelamin RSUD Meuraxa kota Banda Aceh periode tahun 2016-2019. *Jurnal Medika Malahayati*, 4(4), 268–273. <https://doi.org/10.33024/jmm.v4i4.3396>
- Rønholt, K., & Iversen, L. (2017). Old and New Biological Therapies for Psoriasis. *International journal of molecular sciences*, 18(11), 2297. <https://doi.org/10.3390/ijms18112297>
- Shirley, M., & Scott, L. J. (2016). Secukinumab: A Review in Psoriatic Arthritis. *Drugs*, 76(11), 1135–1145. <https://doi.org/10.1007/s40265-016-0602-3>
- Siswati, A. S., Prakoeswa, C. R. S., Triwahyudi, D., Budianti, W. K., Mawardi, P., Dwiyanana, R. V., Widaty, S., Hindritiani, R., Diba, S., Yogiarti, F., Pangastuti, M. (2021). Panduan Praktis Klinis Bagi Dokter Spesialis Dermatologi dan Venereologi Indonesia. Perhimpunan Dokter Spesialis Kulit dan Kelamin Indonesia.
- Thaçi, D., Körber, A., von Kiedrowski, R., Bachhuber, T., Melzer, N., Kasperek, T., Duetting, E., Kraehn-Senftleben, G., Amon, U. and Augustin, M. (2020). Secukinumab is effective in treatment of moderate-to-severe plaque psoriasis: real-life effectiveness and safety from the PROSPECT study. *Journal of the European Academy of Dermatology and Venereology*, 34, 310–318. <https://doi.org/10.1111/jdv.15962>
- Weige, N., & McBane, S. (2013). Psoriasis. *Am Fam Physician*, 87(9):626–633.
- Yunita, I., & Anggraeni, S. (2022). Secukinumab Therapy in Psoriasis Management. *Berkala Ilmu Kesehatan Kulit Dan Kelamin*, 34(1), 59–65. <https://doi.org/10.20473/bikk.V34.1.2022.59-65>

Zhong, H., Yang, H., Mao, Z., Chai, X., Li, S. (2021). Impact of moderate-to-severe psoriasis on quality of life in China: a qualitative study. *Health Qual Life Outcomes*, 19(271). <https://doi.org/10.1186/s12955-021-01902-w>