

**How to Cite:**

Gidwani, A., Tanwani, T., Tripathi, G., Soni, S., Srivastava, A. ., & Thadlani, J. (2022). Customised abutment for achieving the predictable emergence profile for immediate implant in molar site: A case report. *International Journal of Health Sciences*, 6(S9), 2496–2506.  
<https://doi.org/10.53730/ijhs.v6nS9.12963>

## **Customised abutment for achieving the predictable emergence profile for immediate implant in molar site: A case report**

**Dr. Ankita Gidwani**

Post Graduate, Department of Prosthodontics and Crown & Bridge in New Horizon Dental College and Research Institute, Sakri, Bilaspur, Chhattisgarh  
Email: [ankita.gidwani.29@gmail.com](mailto:ankita.gidwani.29@gmail.com)

**Dr. Tushar Tanwani**

Professor and HOD, Department of Prosthodontics and Crown & Bridge in New Horizon Dental College and Research Institute, Sakri, Bilaspur, Chhattisgarh  
Email: [tushar\\_tanwani@yahoo.co.in](mailto:tushar_tanwani@yahoo.co.in)

**Dr. Gaurav Tripathi**

Professor, Department of Prosthodontics and Crown & Bridge, New Horizon Dental College and Research Institute, Sakri, Bilaspur, Chhattisgarh  
Email: [dr.gaurav.tripathi23@gmail.com](mailto:dr.gaurav.tripathi23@gmail.com)

**Dr. Sudeepti Soni**

Reader, Department of Prosthodontics and Crown & Bridge, New Horizon Dental College and Research Institute, Sakri, Bilaspur, Chhattisgarh  
Email: [dr.sudeepti.soni@gmail.com](mailto:dr.sudeepti.soni@gmail.com)

**Dr. Ankita Srivastava**

Post Graduate, Department of Prosthodontics and Crown & Bridge, New Horizon Dental College and Research Institute, Sakri, Bilaspur, Chhattisgarh  
Email: [Ankbebz\\_13@yahoo.in](mailto:Ankbebz_13@yahoo.in)

**Dr. Juhi Thadlani**

Post Graduate, Department of Prosthodontics and Crown & Bridge, New Horizon Dental College and Research Institute, Sakri, Bilaspur, Chhattisgarh  
Email: [Drjuhi1320s@gmail.com](mailto:Drjuhi1320s@gmail.com)

**Abstract**--The alveolar bone undergoes a remodelling process after tooth extraction, which leads to horizontal and vertical bone loss. These resorption processes complicate dental rehabilitation, particularly in connection with implants. Clinical studies have suggested that retaining roots of hopeless teeth may avoid tissue alterations after tooth extraction. The aim is to seal the surgical site

following the outline of extraction socket and to develop an ideal prosthetic emergence profile, modelled on the anatomy of the existing tooth. In present case report a non restorable mandibular molar was treated with socket sealing protocol followed by immediate implant placement. Using sequential osteotomy drills implant site was prepared and roots were dissected in buccolingual direction along the long axis. Roots were extracted using elevators and implant of desired size was placed. A Customized sealing socket abutment (SSA) was prepared to support the coronal emergence profile of the tooth. This technique is a minimally invasive that can preserve the hard and the soft tissue contour of the ridge.

**Keywords**---Sealing Socket Abutment (SSA), Customised abutment, Immediate Implant, Digital Impressions,

## Introduction

Immediate implant placement after extraction of a molar is an attractive treatment alternative for the significant clinical benefits it provides to the patient, as well as for the dentist:

- Reduction of number of surgeries
- Reduction of overall length
- Reduction of morbidity.

To reduce invasiveness as well as technique sensitivity of the procedure the protocol illustrated in this article discusses the use of an anatomical Sealing Socket Abutment (SSA) (Finelle 2017, Finelle 2019) designed and manufactured using CAD-CAM technology to preserve peri-implant hard and soft tissue structure. The aims of the SSA are:

- To mechanically seal the surgical site following the outline of the extraction socket with its anatomical design
- To stabilize the blood clot and to favour bone regeneration space for the substitute material (Retzepi 2010)
- To support soft tissues to prevent them from collapsing during healing time.
- To develop an ideal prosthetic emergence profile, modelled on the anatomy of the existing tooth (Chu 2012).

### Case Report:

A 27-year old man presented to our department with grossly decayed RC treated lower molar (#36) (Fig.1). The patient's medical history revealed no contraindications to dental implant therapy and restorative treatment. The soft tissue position was intact.

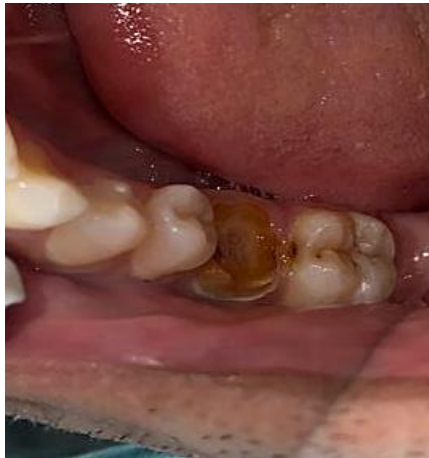

Figure 1 Intra Oral Photograph

### Treatment Planning

Tooth #36 was diagnosed as non-conservable as it was grossly decayed. Radiographs and clinical examination showed no signs of acute infection (fig 2, fig 3). Immediate implant placement after atraumatic extraction was planned.

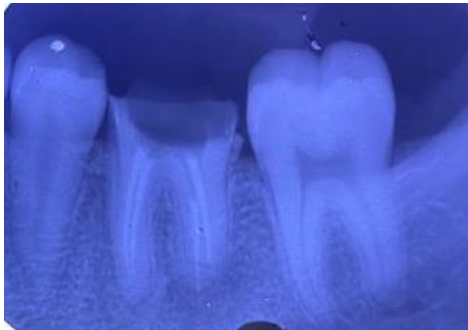

Figure 2 IOPA

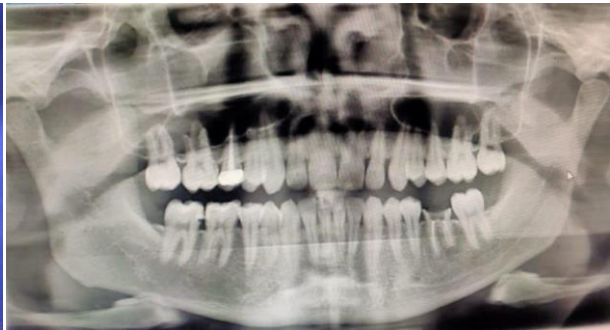

Figure 3 OPG

### Surgical Procedure

Minimally invasive extraction presents major clinical advantages in the final outcome of prosthetic rehabilitation, it provides greater tissue preservation alveolar bone and adjacent soft tissue. To achieve that, a small ditch is made at the centre of the furcation area using straight fissure bur to a full depth. A pilot drill (2.0) was used to a full depth. Following drilling sequence till 3.2. Furthermore the tooth was sectioned buccolingually using SF bur (fig 4).

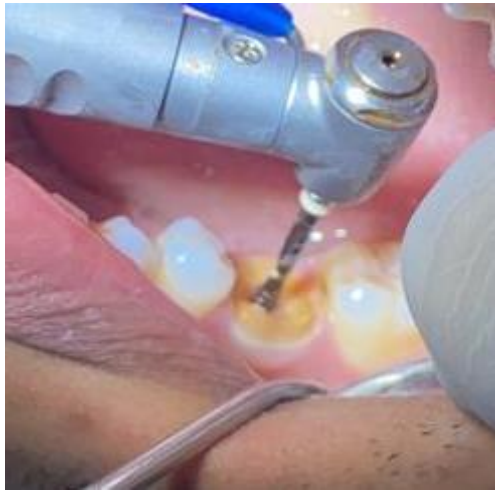

Figure 4 Pilot Drill

An atraumatic flapless tooth extraction was performed by odontosection and separation of the supracrestal gingival fibers with periostomes. Additionally the alveolar socket was liberally irrigated with sterile saline solution and cleaned with curettes to remove granulation tissue (fig 5).

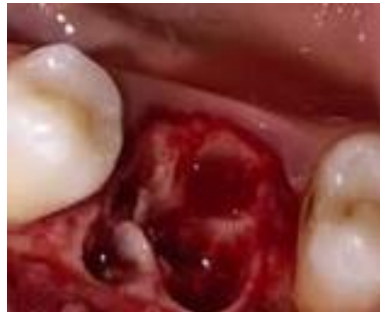

Figure 5 Extraction socket and pilot drill marking

A prosthetically-driven intraseptal drilling was executed to obtain an implant anchorage as close to ideal as possible. Subsequently, an implant (Bioline5 x 13 mm) was inserted with a satisfying insertion torque (40 N/cm). Accordingly, this proposed protocol of the chairside fabrication of a CAD/CAM abutment to seal the alveolar socket (SSA: Sealing Socket Abutment) immediately at the time of extraction-implantation was established.

An innovative protocol has been established at the time of extraction, to close the socket that is an immediate abutment customised digitally by CAD-CAM. A scan body (fig 6,7) was connected onto the platform of implant with flat aspect of scan head facing buccally, which would capture the 3D position of implant via Intraoral Scanner.

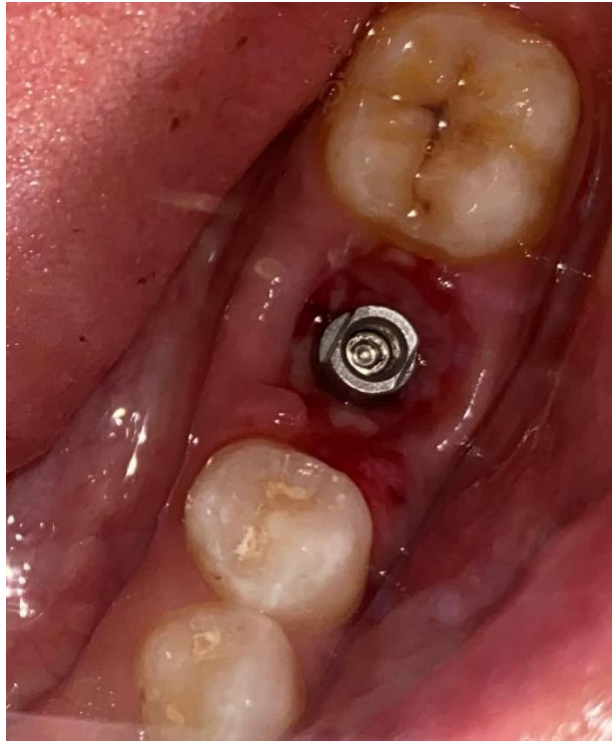

Figure 6 implant placement and scan body in place

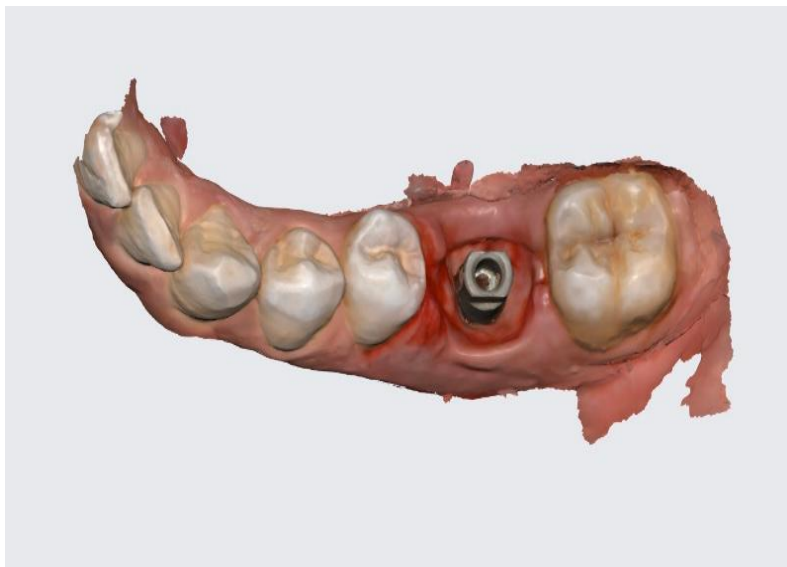


Figure 7 Intra oral scan with scan body

Immediately this impression was exported for the designing to the lab containing designed prosthetic software. Meanwhile a sterile gauze was placed at surgical site for 15 minutes and post operative instructions were given to the patient.

The designed process mimics the outline of the previous freshly extracted molar in order to create a mechanical seal between the oral cavity and surgical site. This ideal emergence profile is created to guide soft healing and positioning during the maturation process. Fabrication of SSA was outsourced from in-office milling system (fig 8).



Figure 8 Socket sealing abutment in-office milling

After milling, adhesive cement (Multilink N, Ivoclar) was used to assemble SSA onto Ti base. Finally SSA was screwed on the implant with a manual insertion torque of 10-15N/cm (fig 9)

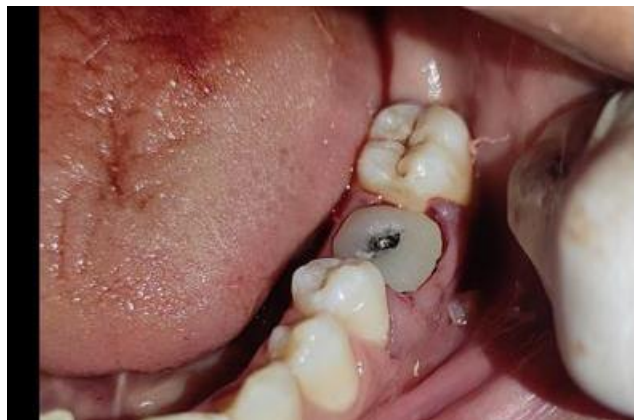

Figure 9 Socket sealing abutment in place to maintain the emergence profile

Proper seal and fit was evaluated after the placement. The screw access was then later isolated by Teflon tape and sealed with light curing resin. An OPG was taken to verify the proper position of implant (fig 10)

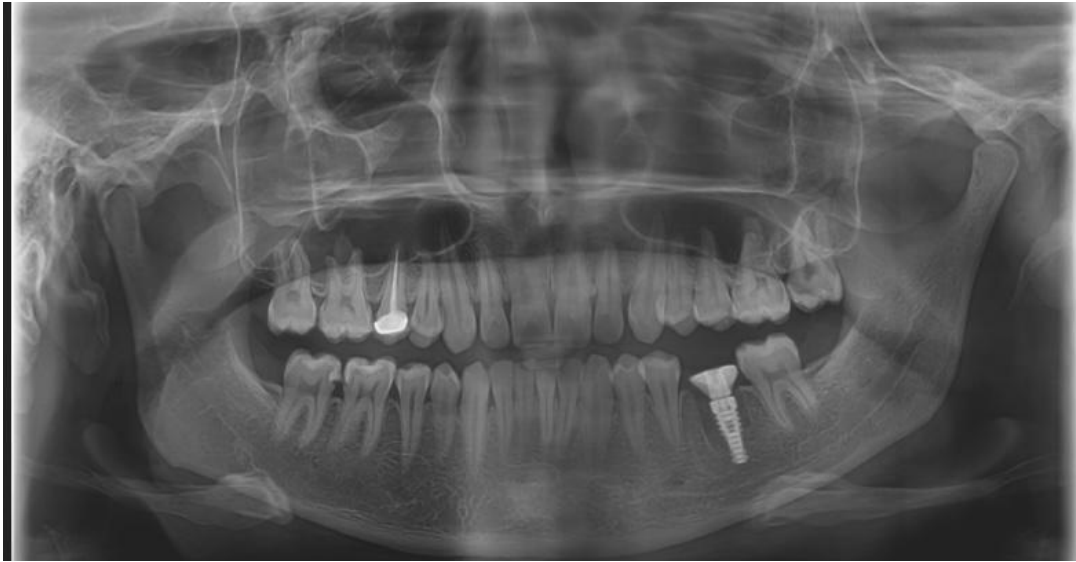

Figure 10 Post Implant and SSA Abutment OPG

A follow up after 21 days was made

The soft tissue of surgical site was aspected, which showed a favourable healing and had no signs of inflammation. After 12 weeks of osseointegration, soft tissue around the SSA abutment was healthy, and the buccal contour was maintained. Removal of the abutment at the time of impression-taking showed a healthy and anatomical prosthetic emergence profile and a well-designed transmucosal portion. In Prosthetic Procedure, a tissue/ gingival level scan was made.

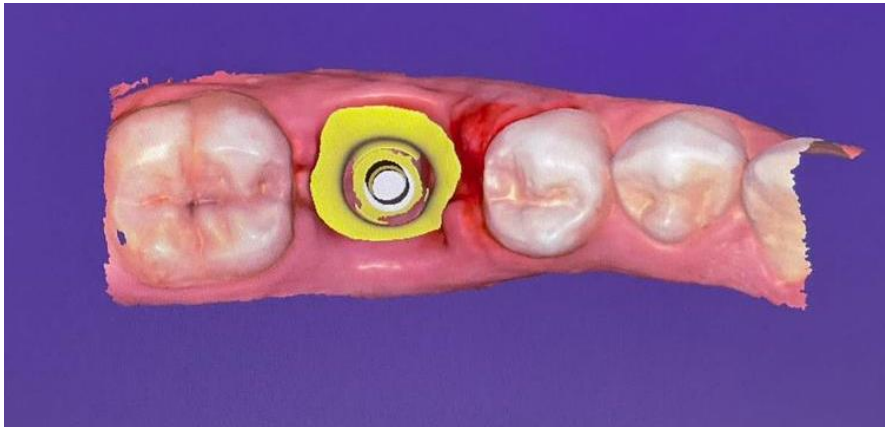

Figure 11 Planning of prosthesis using exocad

Planning of prosthesis was done using Exocad (fig 11, 12)

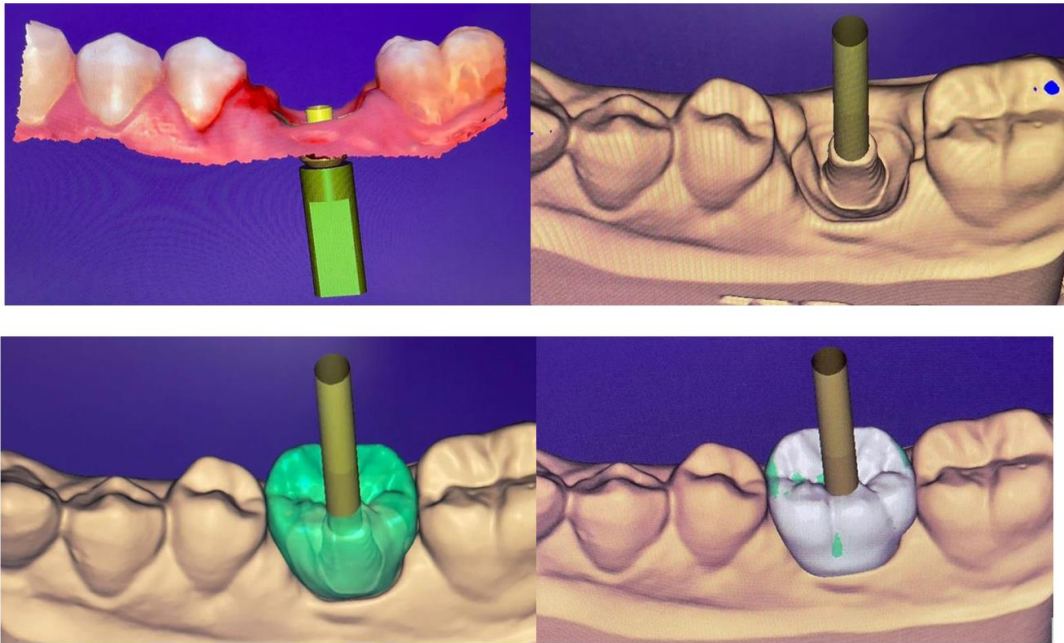


Figure 12 Planning of prosthesis

A digital impression (Medit I-500) using Scanbody for bioline implant was taken for implant-supported restoration. Finally, an implant screw-retained crown was designed on the exocadSoftware and milled out of a monolithic lithium disilicate block (Emax CAD, Ivoclar) (fig 12)

A Bausch Articulating paper of 100 microns were used to check for any occlusal disharmony.(fig 13)

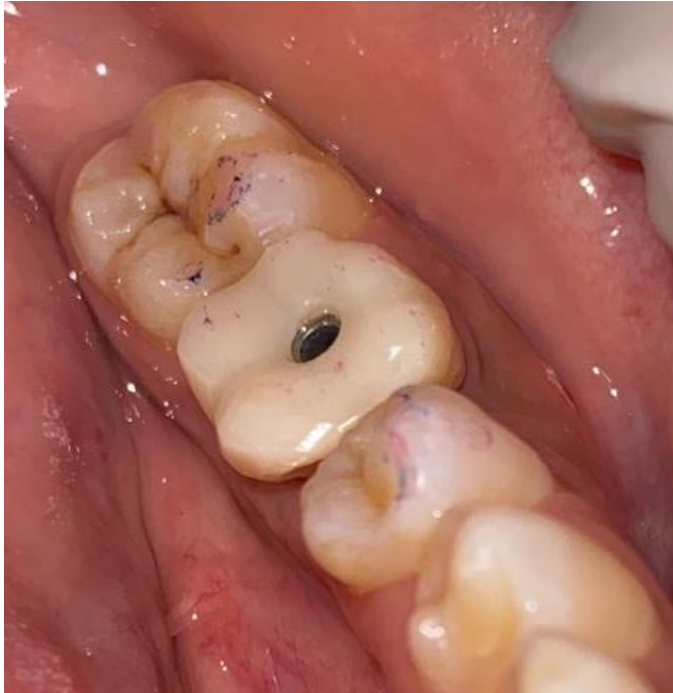

Figure 13 occlusal equilibration

We can notice the dimensional buccal volume discrepancy in the tooth where sealing socket abutment was not used, and the soft tissue was collapsed.(fig 14) on the contrary preservation of buccal contour is done through SSA strategy.(fig 15). The adequate emergence profile of the peri-implant soft tissues precisely fits with the transmucosal anatomy of the ceramic crown

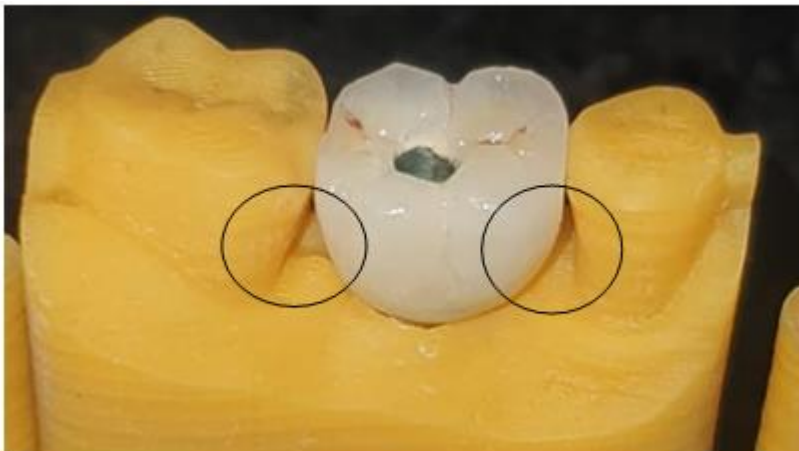


Figure 13 Notice the open embrasure area

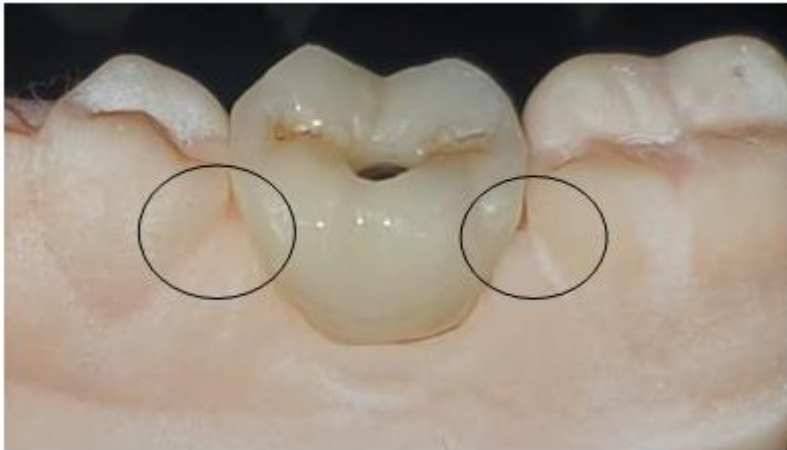

Figure 14 enhanced emergence profile achieved by bnyssa technique

Final insertion torque (35 N/cm) was applied, and the access hole was covered with restorative composite. A post-operative periapical radiograph was taken to verify the seating and marginal integrity after insertion. The access hole was covered with Teflon tape and a composite resin. (fig 16)

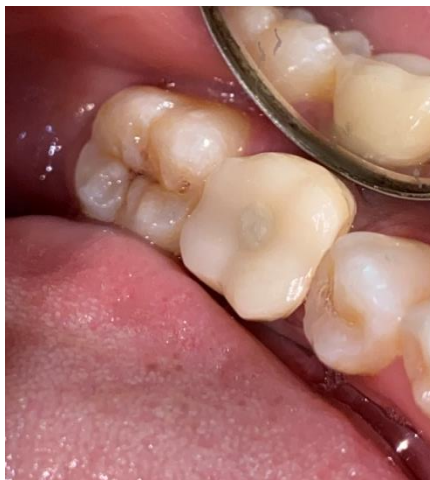

Figure 15 final prosthesis

### **Conclusion**

From a prosthetic standpoint, the transmucosal portion of the SSA is shaped as described:

A. Submergence profile (closer to the implant) with a narrow portion to accommodate for biological space and proper soft tissue healing (Finelle & al. 2015).

B. Emergence profile (closer to the cervical margin) matching the anatomy of the previous existing natural crown (Chu & al. 2012).

At the 6 month follow-up, the clinical situation was stable. No biological or technical complications were reported. Clinical assessment showed a stable soft tissue position and volume (buccal contour and papilla). This case report demonstrates the clinical benefits in terms of the surgical and prosthetic aspects of the molar treatment after extraction: 1. Surgically, the CAD/CAM device behaves as a mechanical barrier that ensures stabilization of the blood clot in a confined alveolar socket space favorable for the regeneration process. The SSA aims to “seal” the socket without the use of invasive techniques such as flaps, incisions and sutures. As there is no attempt at a primary closure procedure, the mucogingival junction is not displaced and the papilla architecture is maintained in its original anatomical position. Consequently, post-operative discomfort is expected to be very low.

### References

1. Atieh MA, Payne AG, Duncan WJ, de Silva RK, Cullinan MP. Immediate placement or immediate restoration/loading of single implants for molar tooth replacement: a systematic review and meta-analysis. *Int J Oral Maxillofac Implants.* 2010;25:401–15
2. Finelle G, Lee SJ. Guided Immediate Implant Placement with Wound Closure by Computer-Aided Design/Computer-Assisted Manufacture Sealing Socket Abutment: Case Report – *Int J Oral Maxillofac Implants.* 2017 Mar/Apr;32(2):e63-e67. doi: 10.11607/jomi.4770
3. Finelle G, Sanz Martin I, Knafo B, Figué M, Popelut A. Digitalized CAD-CAM protocol for the fabrication of customized Sealing socket healing abutments (SSA) in immediate implants in molar sites. A Case series. *Int J Comput Dent.* 2019;22(2):187-204.
4. Finelle G; Knafo B, Figué M, Popelut A, Sanz Martin I. Sealing socket abutments (SSA) in molar immediate implants with a digitalized CAD-CAM protocol. Soft tissue contour changes and radiographic outcomes after 2 years. (*IJPRD*)
5. Chu SJ, Salama MA, Salama H, Garber DA, Saito H, Sarnachiaro GO, Tarnow DP. The dual-zone therapeutic concept of managing immediate implant placement and provisional restoration in anterior extraction sockets. *Compend Contin Educ Dent.* 2012 Jul-Aug;33(7):524-32, 534