

How to Cite:

Venksteswararao, K., Raviraju, T., & Addepalli, S. K. (2022). A study on sarcoidosis with clinical profile, diagnosis and treatment: A clinic's perspective. *International Journal of Health Sciences*, 6(S9), 2507–2517. <https://doi.org/10.53730/ijhs.v6nS9.12968>

A study on sarcoidosis with clinical profile, diagnosis and treatment: A clinic's perspective

K. Venksteswararao

Associate Professor, Department of Pulmonary Medicine, GITAM Institute of Medical Sciences and Research (GIMSR), GITAM Deemed to be University, Visakhapatnam-530045, Andhra Pradesh, India.

Corresponding author email: kvraochest@gmail.com

T. Raviraju

Professor of Nephrology and Honorary adviser, GITAM Institute of Medical Sciences and Research (GIMSR), GITAM Deemed to be University, Visakhapatnam-530045, Andhra Pradesh, India.

Syam Kumar Addepalli

Associate Professor, Department of Pharmacology, GITAM Institute of Medical sciences and Research (GIMSR), GITAM Deemed to be University, Visakhapatnam-530045, Andhra Pradesh, India.

ORCID ID: 0000-0001-8733-799X, Scopus ID: 248415.

Abstract---Background: Sarcoidosis is a multisystem granulomatous disease of unknown etiology and a close mimic of Tuberculosis in TB endemic areas which poses a diagnostic challenge. Objective: The main objective of the study is to determine the prevalence of Sarcoidosis with respect to its clinical profile, diagnosis and treatment. Methodology: The present study is a descriptive study with 20 documented cases of Sarcoidosis from South India; the study span was from 2011 to 2021 with particular reference to cardiac and other organ involvement. Results: The results showed pulmonary involvement in 100% of patients followed by peripheral lymph node involvement in 70% of patients which offered easy and cost effective diagnosis. Cardiac involvement was noted in 15% of patients as against scarce case reports from India. Ocular and Cutaneous involvement was seen in 15% of patients each. Kidneys and Parotids were involved in 5% of patients. It should be suspected in any patient with appropriate clinical/radiological findings and the diagnosis of non-caseating granuloma should be made from an easily accessible peripheral site, followed by bronchoscopic and other methods. It should be differentiated from Tuberculosis and other granulomatous lesions. It is a steroid responsive condition and carries good prognosis.

Keywords---Sarcoidosis, Granuloma, Mediastinal adenopathy, Micronodules on HRCT, Multi system disease

Introduction

Sarcoidosis is a multisystem granulomatous disease of unknown etiology that can affect any organ/organs of the body, with the most common organ of involvement being lungs and mediastinal lymph nodes. Simultaneous systemic involvement can be seen in about one third of cases. Occurrence of Sarcoidosis is relatively infrequent in the Asian population with an incidence of 1 to 3 cases per one lakh population when compared to the West, African Americans show highest incidence of 17-35 per one lakh population followed by Whites with 5-12 per one lakh population^[1,2,3]. Diagnosis of Sarcoidosis depends on appropriate clinical and radiologic presentation, demonstration of granuloma by either cytology/Histopathology from an accessible organ and exclusion of other causes of granuloma. Response to therapy is good in most of the cases using oral corticosteroids as first line drugs, followed by disease modifying anti rheumatic drugs, and biologicals like Infliximab as second and third line drugs. Many papers have been published from India, largely from Northern and Eastern parts of India from Tertiary care Hospitals ^[4,5,6]. My present article is a case series of Sarcoidosis from Southern India, the study span was from 2011 to 2021. Sarcoidosis is a close mimic of Tuberculosis and due to its relative rarity, and lack of awareness among clinicians, its diagnosis poses challenges specially from low prevalence countries. Above all, 24% of Tuberculosis granulomas are non-caseating. Hence careful clinical examination, search for other organ involvement, response to treatment and long term follow up are essential. Timely diagnosis limits morbidity and mortality as significant number of these patients receives anti -tuberculosis treatment in low prevalence areas.

Materials and Methods

The present study was a descriptive study of Sarcoidosis which includes 20 documented cases from 2011 with follow up of most of the cases till now. The inclusion criteria taken was proven non-caseating granuloma in a suspected case of Sarcoidosis in an appropriate clinical setting. The exclusion criteria taken were to exclude any patient with cytology/histology proven granulomas showing caseation necrosis, visible TB bacilli on smear/culture. Diagnostic modality was Fine needle aspiration cytology/histopathologic examination of easily accessible lesions like Enlarged peripheral lymph nodes, skin nodules, enlarged parotid gland, mainly for cost effectiveness and safety. Bronchoscopic mode was used in 30% of cases for diagnosis using bronchial mucosal biopsy or endo-bronchial ultrasound guided mediastinal node biopsy. Treatment included oral corticosteroids as first line drugs, followed by low dose corticosteroids and oral Methotrexate in those who could not tolerate high dose steroids or with contraindication for steroid usage^[7, 8].

Results

Of the 20 patients, females predominate over males with a ratio of 3:2 and the mean age distribution was 45 years with a range of 26 to 65 years. Among clinical features, constitutional symptoms were seen in 45% of patients, cough and dyspnoea were the presenting symptoms in 85% of patients, 10% of patients presented with chest pain, the one in this series presented with contained rupture of left ventricle due to granulomatous infiltration of myocardium.

Regarding organ involvement, all 20 patients in this series had pulmonary involvement in the form of mediastinal lymphadenopathy/pulmonary infiltrates or both. Peripheral lymphadenopathy was seen in 70% of patients either clinically or sonographically. 15% of patients had cardiac involvement diagnosed by dedicated cardiac MRI/dedicated FDG-PET scan. 10% of patients had Eye involvement due to Uveitis. 15% of patients showed skin involvement, one with skin nodules, one with Lupus pernio and the other one with scar infiltration.

One female patient had renal involvement in the form of interstitial nephritis with extensive pulmonary infiltrations with respiratory failure. One patient presented with Bilateral Parotidomegaly with lacrimal gland enlargement (Heerfordt's syndrome). In One case non-caseating granuloma was seen [Figure 3].

Chest X-ray Presentation (Scadding staging system)[Figure 1, Figure 5, Figure 7]:

Stage 1: 10; Stage 2: 70%; Stage 3: 20 %

HRCT Chest:done in majority of patients which showed hilar/mediastinal adenopathy/characteristic perilymphatic nodular distribution [Figure 2]. Two patients had diffuse patchy ground glass opacities and one patient developed upper lobe fibrosis. FDG-PET Scan [Figure 4 and Figure 6] was done in two cases which showed avid patchy uptake by ventricular walls in a pattern consistent with Sarcoidosis. Dedicated cardiac MRI Scan was done in those two suspected cases which show edlate gadolinium enhancement s/o sarcoidosis. Diagnosis could be established in 70% of patients by Fine needle aspiration/histopathology from an easily accessible peripheral lymph nodes/Parotid gland. Bronchoscopic methods were helpful 25% of cases. Renal biopsy was done in one patient. Therapeutic response: 75% responded to oral corticosteroids as per recommendations of American Thoracic Society/European Respiratory Society/World Association of Sarcoidosis and other granulomatous diseases.15% responded to low dose Oral Corticosteroids/Oral Methotrexate. One patient did not respond and died of cardio respiratory failure. 75% of patients remained in remission whereas 20% of patients were retreated for relapse. Mortality was seen in 5% of patients due to cardiorespiratory failure.

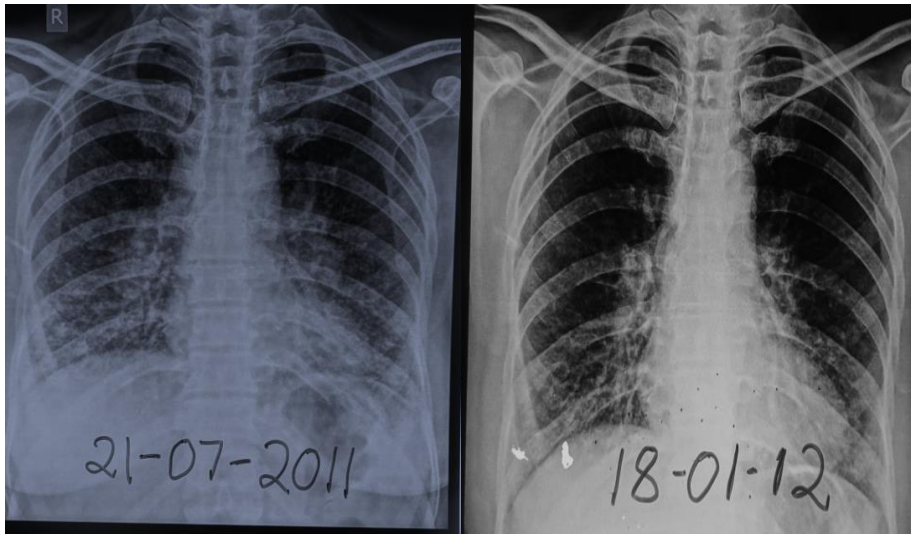


Figure 1: Chest x-ray before and after treatment

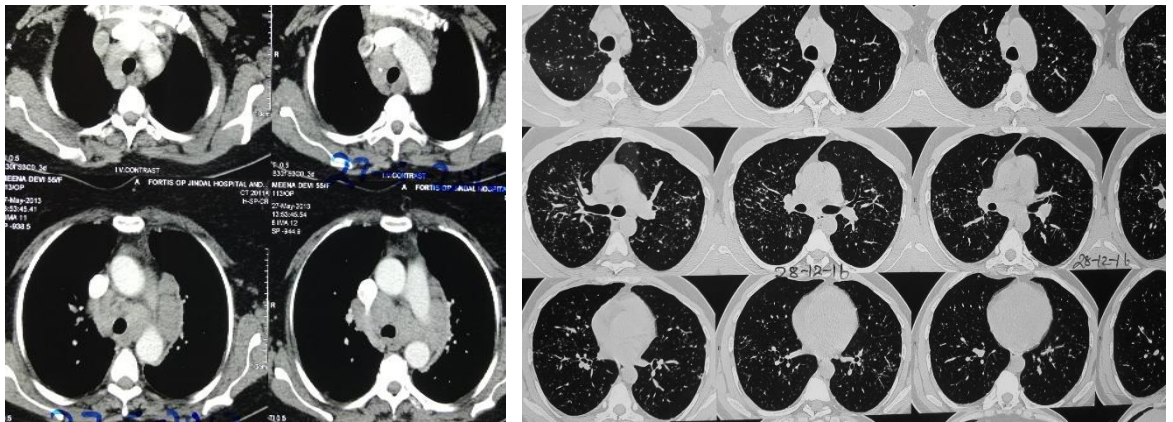


Figure 2a:HRCT Chest in a patient showing BHL with mediastinal nodal involvement

Figure 2b:HRCT Chest with perilymphatic distribution of nodules in a cardiac Sarcoidosis patient

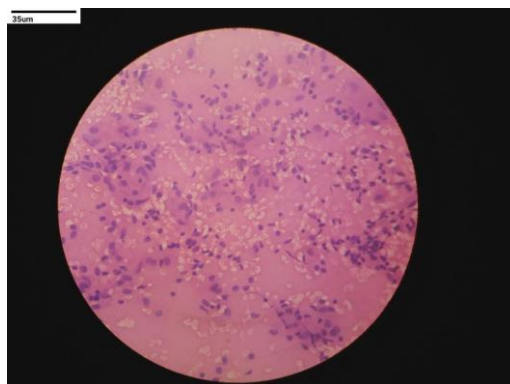


Figure 3: Non-caseating granuloma

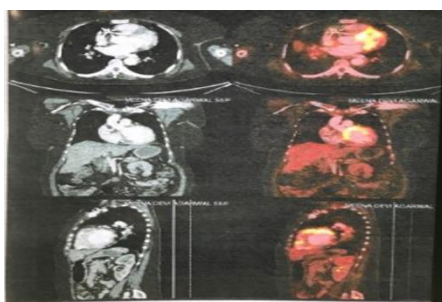


Figure 4: Dedicated cardiac PET Showing patchy uptake of same patient

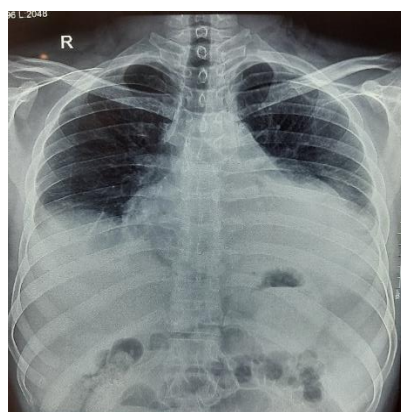


Figure 5: Chest X-ray on admission

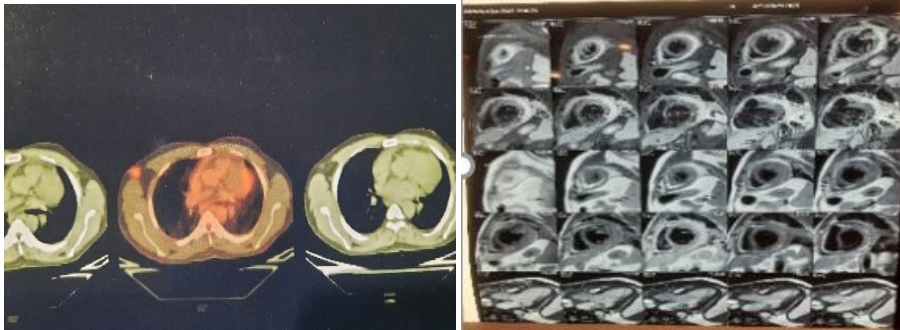


Figure 6: FDG-PET Showing patchy uptake Cardiac MRI showing gadolinium enhancement

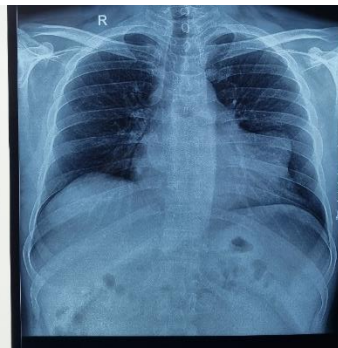

Figure 7: Current chest X-ray showing left ventricular aneurysms

Discussion

With improved awareness and improved diagnostics, more and more cases of Sarcoidosis are being reported from a low prevalence country like India, specially from northern, eastern and western parts of India. My study spans from 2011 to 2021 with a total of 20 cases of documented Sarcoidosis both Pulmonary and extra pulmonary by cytological/histopathologic methods. Asia is reported to have lowest incidence of 1 to 3 cases per one lakh population. Indian registry of sarcoidosis is not available although one reference centres from North India reports 6.5 cases per one lakh population. In my case series, Female sex showed dominance over male with a ratio of 3:2 and the average age distribution was 46 years with a range of 26 years to 65 years. An approach for the diagnosis was described in Table 1.

Table 1: An approach to diagnosis [7]

1. Clinico radiographic Presentation
(History, Physical, Imaging, Initial Base Line Evaluation)
2. Specific clinical presentations where tissue biopsy is not required:
 - Lofgren's syndrome
 - Heerfordt's syndrome
 - Asymptomatic bilateral hilar adenopathy on CXR.
 - "Lambda+ Panda sign on Gallium 67 scan
3. Clinical presentations where tissue biopsy is necessary looking for

NCG

- Biopsy of suspicious lesion
 - Biopsy of the Lung or Hilar/Mediastinal Lymph Node
 - Blind biopsy of accessible site
4. Exclude other Granulomatous disease
 5. Document systemic involvement: clinical evidence of additional organ(s) involved

Table 2: Organ involvement in Sarcoidosis

Organ System	Western Studies (%)	Previous Indian Studies (%)	Joshi et al. (%) (n=34)	Current study (%) (n=20)
Thoracic	88-89	61-97	100	100
Lymphoid system	8-27	19-42	12	70
Parotid enlargement	0.5-6	3-15	3	5
Skin	11-34	2-20	12	15
Ocular	4-27	8-40	3	15
CNS	0.3-6	1-11	6	-
Heart	3	0-12	3	15
G-I tract Hepatomegaly	12	14-42	6	5
Splenomegaly	0.3-10	2-27	9	-
Exocrine glands	6-40	-	3	5
Endocrine	2-10	-	6	-
Renal	2-50	10-49	6	5
Anaemia	4-20	-	6	-
Tuberculin Test negative	55-70	59-97	91	-

Pulmonary involvement was seen in 100% of patients, over 85% of patients presented with cough and exertional dyspnoea and constitutional symptoms like malaise, arthralgias, and fatigue were seen in 45% of patients [Table 2]. Physical examination showed lung rales in less than 20% of patients. Clubbing is rare. An abnormal chest X-ray gives clue for pulmonary involvement and in a proven case, other organ involvement needs to be looked for because of its systemic nature. Reported literature shows stage-1 sarcoidosis to be of 40-50%, about 30-40% in stage-2, 15-20% in stage-3, and about 2-5% in stage-4.

Table 3: Radiographic staging of sarcoidosis at presentation according to the Scadding criteria

				Current Study	
Radiographic stage	Radiographic description	Frequency %	Resolution %	Frequency	Resolution
0	Normal	5-15			
1	BHL	25-65	60-90	10	50
2	BHL and pulmonary infiltrates	20-40	40-70	70	90

3	Pulmonary infiltrates without BHL	10-15	10-20	20	90
4	Pulmonary fibrosis	5	0	0	0

HRCT Chest is more specific when compared to CXR and common findings [Table 3] include bilateral hilar adenopathy- along with 4R/7/5/11L nodal stations(Naruke)involvement. Only mediastinal adenopathy without hilar adenopathy is uncommon and is seen in less than4%. Parenchymal involvement is seen in the form of bilateral predominantly peribronchovascular, sub pleural and interlobular septal distribution of micro nodules with upper lobe predominance. In my series HRCT Chest was done in more than 50% of cases which showed both nodular parenchymal involvement along with mediastinal nodal involvement. Diffuse patchy ground glass hazinesswas seen in15% of patients which resolved completely with treatment. Literature shows Ground glass involvement ranges from 16% to18%. [7] Over 70% of patients with pulmonary involvement responded to oral corticosteroids and remained in remission. Relapsed patients responded to low dose oral corticosteroids and oral Methotrexate at a dose of 10 to 15 mg per week. Overall duration of treatment given was one year in my series with subsequent follow up [8, 9, 10, 11, 12, 13]. Cardiac sarcoidosis was seen in 15% of my patients in my series, reports of incidence of Cardiac sarcoidosis are sparse from India. My cases were diagnosed as per recommendations of Heart Rhythm Society, 2014 second pathway (Expert consensus recommendations on criteria for diagnosis of cardiac sarcoidosis) with cervical lymph nodal biopsy showing non-caseating granulomas. As per ACCESS (A Case Control Etiologic Study of Sarcoidosis) the reported incidence of cardiac Sarcoidosis was 2%set by strict criteria [9]. Others reported 24% basing on ECG abnormalities[10,11]. Japanese post-mortem studies showed the prevalence to be as high as 50 to 70%. Data from a large Indian study showed it to be 5.2%[2,4].Cardiac involvement is seen in the form of Arrhythmias and Cardiomyopathy. Most common arrhythmias are AV Block followed by ventricular and supra ventricular arrhythmias presenting symptoms would be palpitations or syncope or sudden cardiac death. Cardiomyopathy presentation is seen 10 to 20% of patients. One study reported isolated cardiac sarcoidosis in two thirds of all cases of cardiac sarcoidosis [11, 12, 13].The first patient was a male,59 year old, presented with complete heart block with perilymphatic distribution of micronodules with mediastinal nodal involvement, had a permanent pacemaker implanted and treated with Oral Corticosteroids but he subsequently developed progressive lung fibrosis and died. The second patient was a female, 58 year old, had mediastinal nodal involvement with cervical adenopathy, excision biopsy showed granulomatous lesion, lost follow up, again presented after two years with complete heart block in emergency, permanent pacemaker implantation was done, she has been on low dose steroids along with Methotrexate. The third patient presented with constitutional symptoms of two months and chest pain of a few days duration and intense pain of few hours duration which brought him to Emergency medical room and was found to have contained rupture of left ventricle with LV Dysfunction. His HRCT Scan showed mediastinal lymph nodal involvement and FDG-PET Scan and dedicated cardiac MRI showed Sarcoid characteristic patchy uptake of FDG by left ventricular wall on PET Scan and late gadolinium enhancement on MRI. Diagnosis was established by Cervical lymph node biopsy. He has been initiated on low dose Oral corticosteroids and oral

Methotrexate, improved symptomatically along with improved LV function but he developed multiple left ventricular aneurysms. Extra Thoracic Lymph nodal involvement was seen in 70% of my patients clinically or by sonography which had facilitated cost effective diagnosis, and this has particular relevance in resource limited countries. Bronchoscopic methods were used in 30% of cases. Ocular Sarcoidosis was seen in 10% of patients in accordance with world prevalence figures of 10-25%^[14, 15, 16]. One Patient responded well with oral OCS, the other one lost follow up. Uveitis is the most common type of ocular involvement which causes visual impairment. Non sight threatening lesions are conjunctival nodules, scleritis/episcleritis and orbital involvement.

One patient in my series presented with Heerfordt syndrome, one with Lupus pernio, both showed remarkable improvement with oral corticosteroids and one with Esophageal stricture and he has been on serial endoscopic dilatations. Lofgren's syndrome which is common in Northern Europe, was not seen. Treatment guidelines as recommended by ATS/ERS/WASOG have been followed with the first line drug of choice being Oral Prednisolone with a dose of 20 to 40 mg with subsequent tapering and treatment was stopped after one year. 15% showed relapse and went into remission with low dose OCS and Methotrexate. One Patient died of cardiac sarcoidosis with interstitial pulmonary fibrosis which reflected a mortality of about 5% in my series. In the present study the treatment response was followed by clinical and radiologic improvement.

Conclusion

Sarcoidosis is a multisystem granulomatous disease of unknown etiology and closely mimics Tuberculosis and poses diagnostic challenge in tuberculous endemic areas. Sarcoidosis can involve any organ/organs with presentation to different specialities. With improved clinician awareness and with recent phenomenal development in Imageology and Interventional Bronchology, the true incidence can be known in low prevalence areas and the timely diagnosis can limit/prevent morbidity and mortality. The diagnosis should be considered in any patient with appropriate clinical presentation, demonstration of non-caseating granuloma from an easily accessible site and after exclusion of other possible causes of granulomatous disorder. Diligent search should be made for easily accessible sites for diagnosis as enlarged peripheral lymph nodes, glands, skin nodules offer cost effective diagnosis in resource limited areas. Cardiac Sarcoidosis is not that uncommon as my case series shows so also Ocular sarcoidosis. Particular search should be made for cardiac, Neurologic and ocular involvement as these deserve treatment. Sarcoidosis carries good prognosis with present therapeutic recommendations with low mortality of less than 5% as per current literature.

The author firmly believes in 'Absolute certainty in diagnosis is unattainable, no matter how much information we gather, how many observations we make, or how many tests we perform. Our task is not to attain certainty but rather to reduce the level of diagnostic uncertainty enough to make optimal therapeutic decision.

Strengths of the study: Documented cases with long term follow up.

Limitations: Limited number of patients.

Conflicts of interest: Nil

Institutional Ethics Committee permission: IEC has been taken and none of the patient's personal details have been revealed and consenting procedures have been followed meticulously.

References

1. Arkema EV ,Grunevald J. Sarcoidosis incidence and prevalence , a nationwide register- based assessment in Sweden. EURResp2016;48(6):1690-1699.
2. Baughman RP, Field S. Sarcoidosis in America: analysis based on health care use. Ann Am Thoracic soc 2016;13(8):244-1252.
3. BaughmanRP,Tierstein et al. A case control etiologic study of Sarcoidosis(ACCESS)Research group: clinicalcharacteristics of patients in a case control study of sarcoidosis Am J JRespi. Criti.Med2001;164(10,pt 1)1885-1889.
4. Caliskan C, Prasse A. Treating Sarcoidosis and potential new drugs. ERS Monograph.2022:328-336.
5. David Birnie,Andrew C.T; Cardiac Sarcoidosis , Clinics in Chest Medicine,Dec 2015 ,vol 36,pg 657-668.
6. HamzehNY ,Weinberger HD ,Management of cardiac sarcoidosis in the united states, a Delphi study. Chest 2012;141(1),154-162.
7. Karan M, PB Sryma PB. Clinical Profile of 327 patients with Sarcoidosis in India: An Ambispective Cohort Study in a Tuberculosis (TB) endemic population. Lung India2022;39:51-7.
8. KassirerJP.Our stubborn quest for diagnostic certainty.A cause of excessive testing.N Engl J Med 1989; 320:1489-91.
9. Nagai S ,Yokomatsuet al Treatment with low dose corticosteroid and Methotrexate in Sarcoidosis patients with cardiac lesions. Inter med 2014;53(5)427-433.
10. Pasadhika S Rosenbaum JT .Ocularsarcoidosiscliche med 2015;36(4);669-683..
11. PatompongUngprasert Jay H, Matteson et al. Clinical Manifestations, Diagnosis,and Treatment of Sarcoidosis,Mayo cli proc inn qual 2019;3(3)358-375.
12. Raj Kumar. Sarcoidosis North Indian Population : a retrospective study, V P Chest Institute, Chest Dis Allied Sci 2012;54-99-104.
13. Remy-Jardin M. Pulmonary sarcoidosis :role of CT in the evaluation of Disease activity and functional impairment and in prognosis assessment..Radiology 1994;191(3):675-80.
14. Talwar D, IyerH . Pulmonary Sarcoidosis. Indian J Rheumatol 2021;16:S47-57
15. Ungprasert P, Carmona EM. Epidemiology of Sarcoidosis 1946 –2013 ; a population based study. MayoCln proc 2016; 91(2):183-188

16. Valeyre D. ERS Clinical practice guidelines on treatment of sarcoidosis. *Eur.Res J.* 2021;58:2004079.