

How to Cite:

Ahmed, M. A. M., AbdelAllah, M. M. A., Raslan, E. K. H., Gouda, W. R. A., Dawaba, M. M. M., El-Ghafar, I. S. A., Ali, A. M. A., & Abdelmonem, M. H. (2021). Efficiency of different miniscrew positions for maxillary incisor intrusion: A comparative cone beam study. *International Journal of Health Sciences*, 5(S2), 526–532.

<https://doi.org/10.53730/ijhs.v5nS2.13070>

Efficiency of different miniscrew positions for maxillary incisor intrusion: A comparative cone beam study

Mohamed Ahmed Mohamed Ahmed

Asst. Professor, Department of Orthodontics, Faculty of dental medicine, Al-Azhar University (Assiut Branch), Egypt

Mostafa Magdi Abdelmonem AbdelAllah

Lecturer of orthodontic, Department of Orthodontics, Faculty of dental medicine, Al-Azhar University (Assiut Branch), Egypt

Esmail Kamal Hewy Raslan

Lecturer of orthodontic, Department of Orthodontics, Faculty of dental medicine, Al-Azhar University (Assiut Branch), Egypt

Wesameldin Rafaat Ali Gouda

Lecturer of orthodontic, Department of Orthodontics, Faculty of dental medicine, Al-Azhar University (Assiut Branch), Egypt

*Corresponding author email: wesamguda.el.8.540@azhar.edu.eg

Mostafa Mohamad Mahmoud Dawaba

Lecturer of orthodontic, Department of Orthodontics, Faculty of dental medicine, Al-Azhar University (Assiut Branch), Egypt

Ibrahim Saad Abd El-Ghafar

Lecturer of orthodontic, Department of Orthodontics, Faculty of dental medicine, Al-Azhar University (Assiut Branch), Egypt

Ahmed Mahmoud Ahmed Ali

Lecturer of orthodontic, Department of Orthodontics, Faculty of dental medicine, Al-Azhar University (Assiut Branch), Egypt

Marwa Hassan Abdelmonem

Lecturer of orthodontic, Department of Orthodontics, Faculty of dental medicine for girls, Al-Azhar University, Egypt

Abstract---Aim: To evaluate the treatment efficacy of two different position of mini-implant-assisted methods to intrude the maxillary

incisors using cone-beam computed tomography (CBCT). Patients and Methods: The study included 26 patients with elongated maxillary incisors and a deep bite, ranging in age from 12 to 18 years. One group received anterior mini-implants, whereas the other received posterior ones at random. The AMG used elastic chains to apply about 40 g of force per side, while the PMG used beta-titanium wires. This investigation used CBCT scans that were performed before and after an intrusion that lasted 18 weeks. Result: Significant changes in the labial inclination of all incisors, which were greater in PMG than AMG. Conclusion: Both mechanics result in increased labial tilting, but posterior mini-implants assisted maxillary incisor intrusion is greater, so it is preferred when the patient's incisors is upright position.

Keywords---maxillary incisors, intrusion, cone-beam computed tomography.

Introduction

Deep bites may have a detrimental effect on an individual's aesthetic appearance. Lateral cephalometric radiographs may reveal anterior deep bites because of the maxillary Incisors erupting excessively. Overeruption of the lower lip on the lateral Cephalometric radiography is performed when the lower lip extends more than 4 millimetres beyond the maxillary central incisors [1]. During orthodontic therapy, a severe overbite is often addressed [2, 3]. Deep overbites may be corrected in several ways, including invading the maxillary or mandibular incisors, extruding the buccal segments, or a combination of these procedures. This is determined by the diagnostic and therapeutic objectives. Recent work has suggested an alternative to traditional mechanics: incorporating mml-implants into intrusion mechanisms. Conventional mechanics have a detrimental impact on anchoring segments, such as the buccal segment being shorten [3,4]and inclination of posterior teeth distally [5,6]. During reported incisor incursion research, mmi-implants are placed in the front area between the centrals [7, 8] and side incisors [9] or between the lateral and canine teeth [5,6,9,10,11].Currently, when fast maxillary expansion and molar intrusion are being investigated, cone-beam computed tomography (CBC T) is the technique of choice for such study. Few research [12] has examined root resorption and treatment effectiveness because of incisor intrusion using three-dimensional imaging, although these investigations are becoming more frequent.

Patients and Methods

According to the sample size equation, a random sample of 26 patients (12 men and 12 women) with deep bites and long maxillary incisors were chosen from the orthodontic clinic at AlAzhar University's Assiut branch who were randomly picked.

The study's participants were adults who met the following criteria and required maxillary incisor intrusion:

- overbite of 65% or more.
- Angle Class I or II
- Crowding of the maxillary front teeth that are more than 5 millimetres
- upper incisors locate under the functional occlusal plane

Exclusion criteria

It was decided that patients who met the following criteria would be excluded from the study:

- Any trauma or endodontic therapy on the maxillary incisors was noted.
- An illness that affects the whole body regularly such as diabetes.
- The patient's dental hygiene was appalling.

One group receive anterior mini-implants (AMG), while the other received posterior mini-implants (PMG). The detailed case history was taken for the patients and all patients were examined for conformity with criteria of inclusion in the study. Then for each patient, the impression was taken, and a study cast was made then intraoral and extraoral photographs were taken before treatment. Panoramic views for each patient were taken before treatment as a routine record for examination of the teeth that had been used in the study.

Clinical procedure

Preparation of the subject

After obtaining the pre-treatment records, both groups received a straight wire appliance (Ormco Roth 0.018-inch slot brackets) which was bonded to maxillary incisors with light cure Ormco composite. Stainless steel figure-eight ligatures' ties of 0.017 * 0.025 -inch wires were utilized to consolidate teeth after successive levelling and alignment archwires could be employed according to specific case needs.

Mini-implant placement

Two different-sized mini-implants manufactured of biocompatible titanium were inserted in various locations according to each group using a screwdriver tool. Self-drilling mini-implants in the AMG with a diameter of 1.4 mm and a length of 6 mm were inserted between the maxillary laterals and canines using periapical films to determine the appropriate placement. These were chosen due to the anterior region's limited interradicular space. The mini-implants were inserted in the PMG between the second premolar and the first molar using periapical films to identify the appropriate placement. Mini-implants with a diameter of 1.6 mm and a length of 7 mm were employed to mitigate the disadvantage of counterclockwise mini-implant stability on the right side, which is caused by the planned entry mechanics and the greater interradicular gap in this area.

Mini-implant evaluation

The mini-implants were examined for mobility and gingival irritation around the screw neck prior to force loading and at each clinical visit. The connected gingiva

surrounding the head of the mini-implant was evaluated for health based on its colour, bleeding propensity, and overgrowth.

The loading process is as follows: Before each group was loaded with Invasion force, CBCT scans were performed. In AMG, mmi-implants connected to the archwire were intruded using an elastic power chain. Burston's three-part intrusion arch was changed as part of PMG to accommodate the mini-implants. To fit the 0.032-inch beta titanium wire (TMA, Ormco) through the hole in the mini-implant head, one end was thinned, while the other end was bent and clasped to the anterior archwire for security. Force levels were adjusted at a rate of 40 g per side in each anterior and posterior mini-implant group using a force gauge, with force renewal happening every three weeks. To compare the initial CBCT pictures with those obtained 4.5 months following the intrusion, CBCT scans were performed 4.5 months later.

Evaluation procedure

To determine the efficacy of each intrusion strategy, one angular and two linear measurements were performed. Numerous measurements were collected, all of which were recorded on a single piece of x-ray film and then utilized to construct a three-dimensional model of the mouth. An angle (angle between palatal plane and left central incisor' long axis), a distance (1) (linear distant from perpendicular to palatal plane to the left central incisor' center of rotation (CR)) and distant (2) (linear distant from perpendicular to T plane (plane passing through posterior nasal spine and perpendicular to the palatal plane) to the left central incisor' center of rotation (CR)).

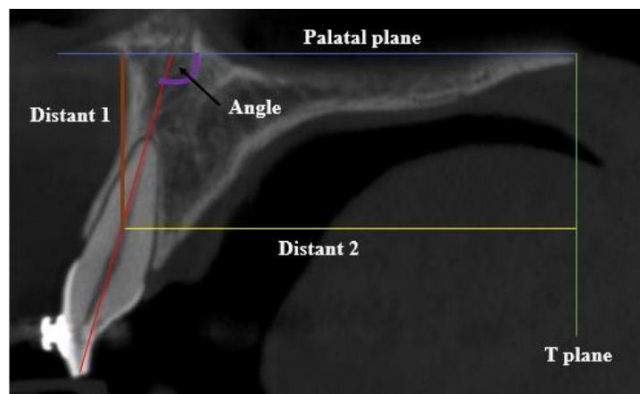


Figure 1. Show different variables

Statistical analysis

Before and after the intrusion, all measurements were submitted to descriptive statistics. The repeatability and reliability of 20 images were evaluated using an intraobserver (intraclass correlation coefficient). The mean changes in both groups were compared using an independent t-test, and the paired t-test was performed to evaluate if the differences were statistically significant. For all statistical analysis and testing, SPSS version 22 was utilized.

Results

Due to one patient in each group not continuing therapy for various reasons, the final assessment included twenty-four individuals. Table (1) shows treatment mechanics-induced intra and inter-group changes and differences. The AMG had substantially more intruded incisors (decreased CR-PP). The AMG and PMG had mean intrusion rates of 0.68 millimeters per month and 0.42 millimeters per month, respectively. After an average of 4.5 months of therapy, patients had an average incursion measurement of between 1.75 millimeters and 2.75 millimeters. There was more distal migration in the incisor CR (decreased CR-T) and labial tilting (increased 1-PP) in the PMG than in the other groups

Table 1
Preintrusion (T1) and Postintrusion (T2) CBCT Measurement Changes and Intergroup

| Variables | Anterior Mini-Implant Group | | | Posterior Mini-Implant Group | | | Intergroup difference |
|------------|-----------------------------|-------|--------|------------------------------|-------|--------|-----------------------|
| | X | SD | P | X | SD | P | |
| CR-PP (mm) | -2.44 | ±0.18 | <0.001 | -1.41 | ±0.21 | <0.001 | <0.001 |
| CR-T (mm) | -0.61 | ±0.10 | <0.001 | -1.44 | ±0.16 | <0.001 | <0.001 |
| 1-PP (°) | 6.33 | ±0.22 | <0.001 | 13.21 | ±0.58 | <0.001 | <0.001 |

X indicates mean change; SD, standard deviation; * P < .05; ** P < .001

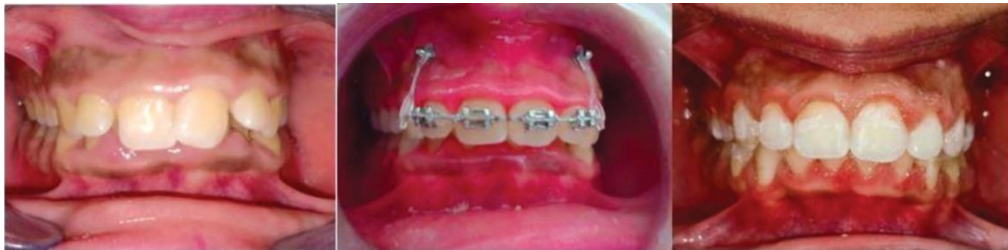

Figure 2. a case presenting AMG before, during, and after intrusion

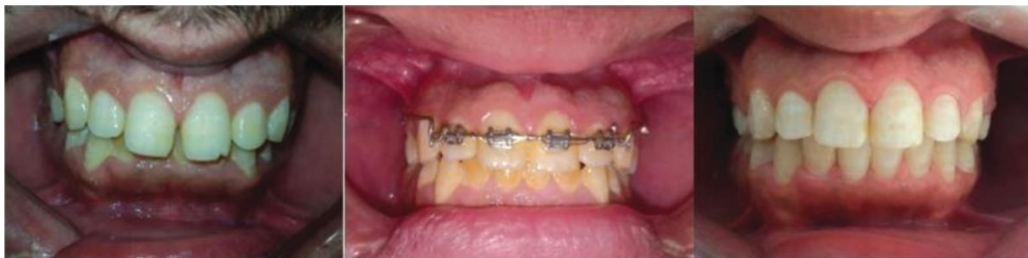

Figure 3. a case presenting PMG before, during, and after the intrusion

Discussion

Mini-implants have been increasingly popular in recent years due to their reduced complexity and lack of adverse effects compared to more traditional techniques for incisor intrusion. It's critical to weigh the risk of root resorption against the

potential benefit of the treatment. The present study compares two different positions of mini-implant assisted maxillary Incisor intrusion to find other advantages of mini-implant assisted maxillary incisor intrusion, whereas many previous studies [13-15] have compared conventional methods and mini-implant assisted methods to intrude the maxillary incisors. In recent clinical research, however, it was shown that the amount of Incisor intrusion did not change when forces varied from 40 to 80 g, indicating that Intrusion does not necessitate the use of large amounts of force [16]

In the previous work [17], measuring tune comprised both the levelling and intrusion phases, which are frequently employed to detect early resorption signs; however, for the current investigation, just the intrusion phase was utilized to compare the two techniques side by side. To find EARR, the most utilized test is periapical radiography. This is because this small, office-based radiographic equipment is less expensive than larger, hospital-based ones [18]. Cone-beam computed tomography was used in this investigation to detect several variables (variables affecting therapy efficacy) simultaneously and in greater detail. If you're wondering about where the mmi-implant was placed in this study, it was placed between the lateral incisors and the canine in AMG to be near to the center of four Incisors resistant, while in the posterior mini-implant PMG it was used for both retraction and intrusion in cases that required retraction and intrusion, so it placed between the second premolar and the first molar in PMG.

In just one study [12], the EARR of maxillary incisors exposed to intrusive pressures utilizing mini-screws in the anterior and posterior area for anchoring was compared using CBCT images. That research's findings agreed with the current study, which found that the anterior group's mean monthly intrusion value was 0.68 mm, while the other group's value was only 0.42 mm over that period. After an average of 4.5 months of therapy, patients had an average intrusion measurement of between 1.75 millimetres and 2.75 millimetres. An increase in treatment time and renewal interval period may have contributed to the small difference between groups in the present study.

References

1. Aras I, Tuncer AV. Comparison of anterior and posterior mini-implant-assisted maxillary incisor intrusion: Root resorption and treatment efficiency. *The Angle Orthodontist*. 2016;86(5):746-52.
2. Årtun J, Smale I, Behbehani F, Doppel D, Van't Hof M, Kuijpers-Jagtman AM. Apical root resorption six and 12 months after initiation of fixed orthodontic appliance therapy. *The Angle Orthodontist*. 2005;75(6):919-26.
3. Burstone CJ, editor *Biomechanics of deep overbite correction*. Seminars in orthodontics; 2001: Elsevier.
4. Burstone CR. Deep overbite correction by intrusion. *American journal of orthodontics*. 1977;72(1):1-22.
5. Costopoulos G, Nanda R. An evaluation of root resorption incident to orthodontic intrusion. *American Journal of Orthodontics and Dentofacial Orthopedics*. 1996;109(5):543-8.
6. Deguchi T, Murakami T, Kuroda S, Yabuuchi T, Kamioka H, Takano-Yamamoto T. Comparison of the intrusion effects on the maxillary incisors

- between implant anchorage and J-hook headgear. *American journal of orthodontics and dentofacial orthopedics*. 2008;133(5):654-60.
7. Gegler A, Fontanella V. In vitro evaluation of a method for obtaining periapical radiographs for diagnosis of external apical root resorption. *The European Journal of Orthodontics*. 2008;30(3):315-9.
 8. Goerigk B, Diedrich P, Wehrbein H. Intrusion of the anterior teeth with the segmented-arch technic of Burstone--a clinical study. *Fortschritte der Kieferorthopadie*. 1992;53(1):16-25.
 9. Kim T-W, Kim H, Lee S-J. Correction of deep overbite and gummy smile by using a mini-implant with a segmented wire in a growing Class II Division 2 patient. *American journal of orthodontics and dentofacial orthopedics*. 2006;130(5):676-85.
 10. Lewis P. Correction of deep anterior overbite A report of three cases. *American Journal of Orthodontics and Dentofacial Orthopedics*. 1987;91(4):342-5.
 11. McFadden WM, Engstrom C, Engstrom H, Anholm JM. A study of the relationship between incisor intrusion and root shortening. *American Journal of Orthodontics and Dentofacial Orthopedics*. 1989;96(5):390-6.
 12. Ohnishi H, Yagi T, Yasuda Y, Takada K. A mini-implant for orthodontic anchorage in a deep overbite case. *The Angle Orthodontist*. 2005;75(3):444-52.
 13. Polat-Özsoy Ö, Arman-Özçirpıcı A, Veziroğlu F, Çetinşahin A. Comparison of the intrusive effects of miniscrews and utility arches. *American journal of orthodontics and dentofacial orthopedics*. 2011;139(4):526-32.
 14. Polat-Ozsoy O, Arman-Ozcirpici A, Veziroglu F. Miniscrews for upper incisor intrusion. *The European Journal of Orthodontics*. 2009;31(4):412-6.
 15. Şenışık NE, Türkkahraman H. Treatment effects of intrusion arches and mini-implant systems in deepbite patients. *American journal of orthodontics and dentofacial orthopedics*. 2012;141(6):723-33.
 16. Upadhyay M, Nagaraj K, Yadav S, Saxena R. Mini-implants for en masse intrusion of maxillary anterior teeth in a severe Class II division 2 malocclusion. *Journal of orthodontics*. 2008;35(2):79-89.
 17. Van Steenberghe E, Burstone C, Prah-Andersen B, Aartman I. The influence of force magnitude on intrusion of the maxillary segment. *The Angle Orthodontist*. 2005;75(5):723-9.
 18. van Steenberghe E, Burstone CJ, Prah-Andersen B, Aartman IH. Influence of buccal segment size on prevention of side effects from incisor intrusion. *American journal of orthodontics and dentofacial orthopedics*. 2006;129(5):658-65.