

**How to Cite:**

Hathila, S. B., Rajani, S., Gupta, S., Suttarwala, I., Bhardwaj, R., Gohil, H., & Vaniya, V. H. (2022). Morphometry of coronary sinus and its role in cardiac cannulation. *International Journal of Health Sciences*, 6(S8), 4595–4600. <https://doi.org/10.53730/ijhs.v6nS8.13247>

## **Morphometry of coronary sinus and its role in cardiac cannulation**

**Dr. Shital Bhisma Hathila**

Ph.D. Research Scholar & Assistant Professor, Anatomy Department, Medical College, Baroda Gujarat

**Dr, Sangeeta Rajani**

Assistant Professor, Anatomy Department, Medical College, Baroda Gujarat

**Dr. Sumit Gupta**

Associate Professor, Anatomy Department, Government Medical College, Rangbari Road, Kota, Rajasthan

**Dr. Ila Suttarwala**

Associate Professor (Corresponding Author), Anatomy Department, Medical College Baroda, Gujarat  
Corresponding author email: [ilasutterwala@gmail.com](mailto:ilasutterwala@gmail.com)

**Dr. Rashmi Bhardwaj**

Assistant Professor, Anatomy Department, Autonomous State Medical College, Etah

**Dr. Harshal Gohil**

Assistant Professor, Department of Community Medicine, Dr.K.C.Patel Medical College & Research Institute, Bharuch, Gujarat

**Dr.V. H. Vaniya**

Professor, Anatomy Department, Medical College, Baroda, Gujarat

**Abstract**--Introduction:- The coronary sinus is a collection of veins, joined together to form a large vessel that collects blood from the heart muscle (myocardium) <sup>1</sup>. Most cardiac veins drain into the wide coronary sinus, 2 or 3 cm long, lying in the posterior atrioventricular groove between the left atrium and ventricle.<sup>2</sup> The sinus opens into the right atrium between the opening of the inferior vena cava and the right atrioventricular orifice. An endocardial fold may guard the entrance of sinus valve of the coronary sinus or Thebesian Valve. The fold may be absent or may cover the ostium of the sinus completely or partially. Material & Method:- The present

study was conducted in the anatomy department of medical college Baroda, Gujarat. One hundred formalin-fixed hearts specimens were taken for the study. The dimensions of the coronary sinus ostium in millimetres was measured with the help of digital vernier calliper. Craniocaudal and transverse length were measured and recorded in Microsoft excel. Result :- In the current study, we observed that 58 hearts had the coronary sinus with a thebesian Valve and the rest 42 were without a thebesian Valve. The Craniocaudal Diameters and transverse Diameters with and without thebesian Valve were  $6.84 \pm 2.85$  mm with a minimum of 1.11 mm and maximum of 11.44 mm,  $8.23 \pm 2.69$  mm with a minimum of 1.91 mm, and maximum 16.32 mm,  $6.66 \pm 2.69$  mm with a minimum of 1.69 mm and maximum 17.48 mm and  $8.08 \pm 2.85$  mm with a minimum of 3.62 mm and maximum 18.51 mm respectively. Conclusion: -The Thebesian Valve is an embryological remnant of the sinoatrial Valve, guarding the coronary sinus ostium. Advanced interventional cardiac diagnostic and therapeutic tools include the cannulation of coronary sinus ostium. The presence of thebesian valve has been reported to lead obstructed or failed coronary sinus cannulation.

**Keywords**---morphometry, coronary sinus, cardiac cannulation.

## Introduction

The coronary sinus is a collection of veins joined together to form a large vessel that collects blood from the heart muscle (myocardium) <sup>1</sup>. Most of the venous return of heart is into the wide coronary sinus, while some directly drain into the right atrial wall and ultimately into cavity through small veins.<sup>2</sup> The sinus opens into the right atrium between the opening of the inferior vena cava and the right atrioventricular orifice. An endocardial fold may guard the entrance-valve of the coronary sinus or thebesian Valve. The fold may be absent or may cover the ostium of the sinus completely or partially. The tributaries of the coronary sinus are the great, small and middle cardiac veins, the posterior vein of the left ventricle and the oblique vein of the left atrium. Isolated absence of the coronary sinus has been reported, with coronary venous drainage into the pulmonary trunk<sup>3</sup>. The coronary sinus plays an essential role in interventional cardiology, resulting in renewed interest in the coronary sinus as an access route to deprived myocardium. Advances in technology, such as percutaneous catheter techniques, have improved access to the coronary venous system and allowed for a physiological adaptation of coronary sinus retro perfusion techniques. Nowadays, primary coronary sinus accessing techniques, i.e. Ablation procedure of an arrhythmia source, Cardiac resynchronisation therapy, synchronised retro perfusion (SRP), retrograde cardioplegia delivery, is a popular method of myocardial protection during aortic cross-clamping, retro infusion of pharmaceutical agents in the normal working heart and pressure-controlled intermittent coronary sinus occlusion (PICSO) have been documented as providing superior protection of jeopardised myocardium in selected patients.

## Material & Method

This was a cross-sectional observational study carried out after obtaining approval from the ethics committee at Anatomy Department, Medical College Baroda, Gujarat. Hundred properly embalmed and formalin-fixed adult cadaveric heart specimens which retained their morphological features were selected for the study. Specimens with deformities and calcified valves were excluded. Dissection was done according to the standard method. A linear incision was made extending from the superior vena cava to the inferior vena cava, such as Eustachian Valve remained intact to expose the right atrial cavity. Another curved incision was made along the sulcus terminalis for a roomy window of the right atrium. Coronary sinus was identified. The Craniocaudal Length and transverse length of coronary sinus ostium were measured with help of digital vernier caliper in millimetre. The data was tabulated, analysed in Microsoft Excel & relevant photographs of the examined specimen were taken using a digital camera.

## Observation & Result

In our current study we observed that the 58-heart having the coronary sinus with thebesian valve and rest 42 without thebesian Valve as given in table no1.

Table 1: Percentage Distribution of Coronary Sinus with And Without Thebesian Valve

Total Number of Heart Specimens of Coronary Sinus	Parameter	Number	%
100	Coronary Sinus with Thebesian Valve	58	58%
	Coronary Sinus Without Thebesian Valve	42	42%

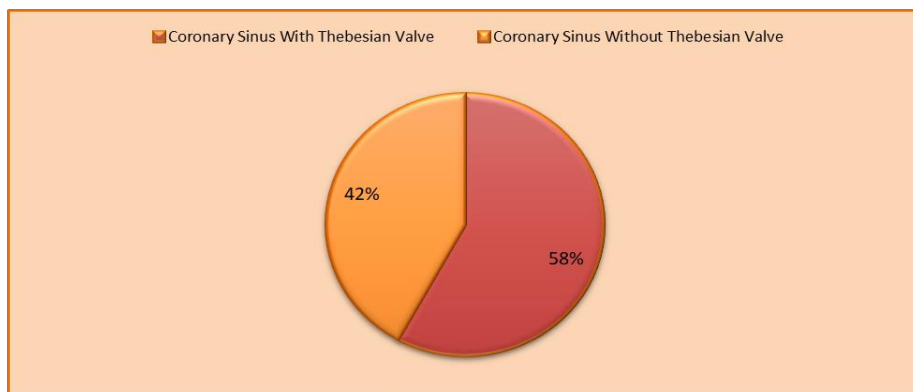
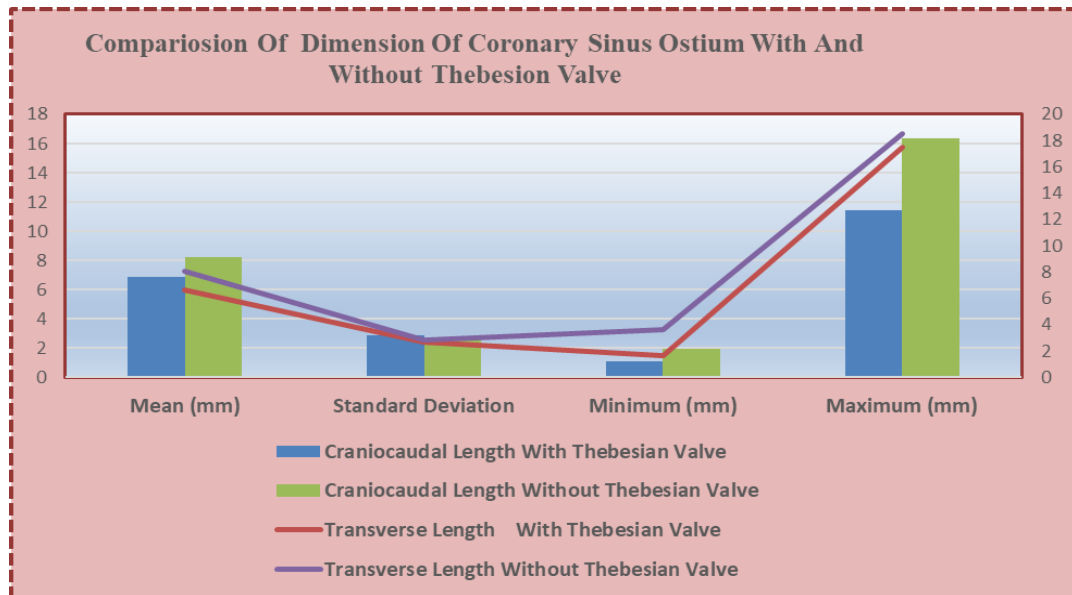


Chart :1 Showing The Distribution Of Coronary Sinus With And Without Thebesian Valve

In the current study, the mean craniocaudal length with a Thebesian valve is 6.84 mm with a standard deviation of 2.85 mm, a minimum length of 1.11 mm, and a maximum length of 11.44 mm. The mean craniocaudal length without a Thebesian valve is higher in comparison to without thebesian valve is 8.23 mm with a standard deviation of 2.69 mm, a minimum length of 1.92 mm, and a maximum length of 16.32 mm. We also observed in the current study, the mean transverse length with a Thebesian valve is 6.66 mm with a standard deviation of 2.69 mm, a minimum length of 1.69 mm and a maximum length of 17.48 mm. The mean transverse length without a Thebesian valve is higher in comparison to with thebesian valve is 8.08 mm with a standard deviation of 2.85 mm, a minimum length of 3.62 mm and a maximum length of 18.51 mm.

Table 2 Measurement of Coronary Sinus With and Without Thebesian Valve

Parameter		Mean (mm)	Standard Deviation	Minimum (mm)	Maximum (mm)
With Thebesian Valve	Craniocaudal Length	6.84	2.85	1.11	11.44
	Transverse Length	6.66	2.69	1.69	17.48
Without Thebesian Valve	Craniocaudal Length	8.23	2.69	1.92	16.32
	Transverse Length	8.08	2.85	3.62	18.51



Graph: 1 Showing The Dimensions of Coronary Sinus Ostium with or Without Thebesian Valve

## Discussion

In our present study, we observed that 58 (58%) hearts have the thebesian Valve and are absent in 42 (42%). While comparing our study with Sanjib Kumar Ghosh et al. <sup>5</sup>, they studied 150 heart specimens. They observed the presence of

thebesian valve in 118 (78.7 %) heart specimens and absent in the remaining 32 (21.3 %). Another study by D J Anh et al. <sup>6</sup>, who studied 98 patients by using the endocardial visualization catheter (EVC) and observed that the thebesian valve was seen in 54% of patients. Another similar study by Mak et al.<sup>7</sup> who study 75 cadaveric hearts and find that the presence of the thebesian Valve in 55 (73%) hearts. Another similar study by PejkoVIC et al<sup>8</sup>, who checked on 150 cadaveric heart specimens and observed thebesian valve in 120 (80%) hearts. The study suggested that more hearts have a thebesian valve, which correlates with our finding.

In our present study, we found the craniocaudal length with thebesian valve was  $6.84 \pm 2.85$  mm with a minimum of 1.11 mm and a maximum of 11.44 mm and transverse length with thebesian valve  $6.66 \pm 2.69$  mm with a minimum of 1.69 mm and maximum of 17.48 mm. While comparing our study with Sanjib Kumar Ghosh et al. <sup>5</sup> observed that the craniocaudal length with thebesian valve was  $11.2 \pm 1.4$  mm and transverse length was  $9.6 \pm 0.8$  mm which was similar with our study. Similar findings were also reported Mak et al.<sup>7</sup>. They observed that the craniocaudal length with thebesian valve was  $9.3 \pm 2.9$  mm and transverse length was  $9.4 \pm 2.9$  mm. Another study by Karaca et al<sup>8</sup>, a study on 55 cadaveric hearts and observed dimensions of the coronary sinus without thebesian valve was 9.47 mm, which was similar with our analysis. Another survey by Hellerstein et al.<sup>10</sup>, diameters of the craniocaudal and transverse diameter 11.1 mm.

In our current study, the craniocaudal length without thebesian valve were  $8.23 \pm 2.69$  mm with a minimum of 1.92 mm and a maximum of 16.32 mm and transverse diameters were  $8.08 \pm 2.85$  mm with a minimum of 3.62 mm and a maximum of 18.51 mm. While comparing our study Sanjib Kumar Ghosh. <sup>5</sup> observed that the craniocaudal diameters without thebesian valve was  $9.4 \pm 2.1$  mm. The transverse diameters was  $8.08 \pm 2.85$  mm, which was similar to our study. Another study of Mak et al.<sup>7</sup> observed that the craniocaudal diameter without thebesian valve was  $7.9 \pm 2.7$  mm. and the transverse diameter was  $7.3 \pm 2.8$  mm.

## Conclusion

The Thebesian Valve is an embryological remnant of the sinoatrial Valve, guarding the coronary sinus ostium. Advanced invasive and interventional cardiac diagnostic and therapeutic tools include the coronary sinus ostium cannula. Obstructive Thebesian valves have been reported to lead to failed coronary sinus cannulation.

## References

1. Anh DJ, Eversull CS, Chen HA, Mofrad P, Mourlas NJ, Mead RH (2008) Characterization of human coronary sinus valves by direct visualization during biventricular pacemaker implantation. *Pacing Clin Electrophysiol* 31:78-82
2. Coronary sinus: Anatomy, tributaries, drainage | Kenhub

3. Hellerstein HK, Orbison JL (1951) Anatomic variations of the orifice of the human coronary sinus. *Circulation* 3:514–523
4. Karaca M, Bilge O, Dinckal MH, Ucerler H (2005) The anatomic barriers in the coronary sinus: implications for clinical procedures. *J Interv Card Electrophysiol* 14(2):89–94.
5. Mak GS, Hill AJ, Moisiuc F, Krishnan SC (2009) Variations in Thebesian valve anatomy and coronary sinus ostium: implications for invasive electrophysiology procedures. *Europace* 11:1188–1192.
6. Ogawa K, Hishitani T, Hoshino K (2013) Absence of the coronary sinus with coronary venous drainage into the main pulmonary artery. *Cardiol Young* 23:759–62
7. PejkoVIC B, Krajnc I, Anderhuber F, Kosutic D (2008) Anatomical variations of the coronary sinus ostium area of the human heart. *J Int Med Res* 36(2):314–321.
8. Sanjib Kumar Ghosh • Shashi Raheja • Anita Tuli Obstructive Thebesian valve: anatomical study and implications for invasive cardiologic procedure *Anat Sci Int* (2014) 89:85–94 DOI 10.1007/s12565-013-0203-0
9. Shah, Sanket S.; Teague, Shawn D.; Lu, Jimmy C.; Dorfman, Adam L.; Kazerooni, Ella A.; Agarwal, Prachi P. (July 2012). "Imaging of the Coronary Sinus: Normal Anatomy and Congenital Abnormalities". *RadioGraphics*. 32 (4): 991– 1008. doi:10.1148/rg.324105220. ISSN 0271-5333.
10. Werner Mohl coronary sinus interventions from concept to clinics *journal of cardiac surgery* 2:467-493 December 1987