

How to Cite:

Sahep, L. F., Omar, R. A., & Nazhat, H. H. (2022). Tramadol as local anesthetic drug for maxillary sinuses trephination in equine species: Donkey model. *International Journal of Health Sciences*, 6(S8), 4842–4852. <https://doi.org/10.53730/ijhs.v6nS8.13307>

Tramadol as local anesthetic drug for maxillary sinuses trephination in equine species: Donkey model

Sahep L. F

Department of Surgery and Obstetric, Collage of Veterinary Medicine, University of Baghdad, Baghdad, Iraq

Omar R. A

Department of Physiology, Biochemistry and Pharmacology, College of Veterinary Medicine, University of Baghdad, Baghdad, Iraq

Corresponding author email: raffal_omar@covm.uobaghdad.edu.iq

Nazhat H. H

Department of Surgery and Obstetric, Collage of Veterinary Medicine, University of Baghdad, Baghdad, Iraq

Abstract--This project was designed to study the incidence, onset, duration and potency of tramadol, in donkeys can be evaluated as local anesthetic drug by infiltration in maxillary sinus for trephination. In this study, five adult donkeys of both sexes of local breed were used for induce trephination of maxillary sinus that was given 2% xylazine hydrochloride intravenously followed by local infiltration of 5% tramadol with aseptic technique. Parameters were used for evaluation, physical and clinical examination which includes: degree of chewing, degree of pain during palpation, measuring of anesthetic time, secretion of lacrimal gland was measured after induction of anesthetic drug locally. The results demonstrated that there are no any significant changes in heart rate, respiratory rate and rectal body temperature. While the anesthetic parameters showed no any significant changes about pain during palpation and absent of chewing movement with secretion of lacrimal gland was seen. Increase in anesthesia duration time from 30-45 minute and with the potency and recovery was excellent after surgical operation.

Keywords---tramadol, local anesthesia, trephining.

Introduction

The using of anesthetic procedures and agents, with local anesthesia had an old as history using in surgery field. Due to advances in knowledge of anesthetic efforts, many diagnostic procedures and number of surgical operation can be performed under local anesthesia (1, 2). Local anesthetics agents that reversibly interfere with neural conduction and are widely used to provide pain control in surgical operation, and the ideal local anesthetic solution should be provide best fit for the animals' systemic condition, which are effective in general, that finally leads to best surgical interference (3-5). Many chemical agents have been developed and produced for local anesthetic purposes, and only a certain number of these substances are currently use (6, 7). Tramadol hydrochloride (tramadol HCl), is known for its strong analgesic activity and has been used widely in medicine for many years (8-10). Recent studies showed that tramadol HCL known as a local anesthetic action on peripheral nerves and used to treat acute and chronic pain of moderate to severe intensity to remove painful condition after recovery from surgery with minimum side effect (11-13). Equine sinus trephination is a common surgical procedure that accompanied with chronic inflammatory condition of Para nasal sinuses in sedated standing animal to provide better visualization of operative site by local anesthetic drug, to reduce risk and cost that associated with general anesthesia in equine practice (4, 14, 15). Many researchers have focus in their scientific work on the local mechanisms action of tramadol HCL, it is atypical opioid, but its local mechanisms of action have not yet been fully understood (16-18). Many studies refer to the local anesthetic effects of tramadol HCL as follows: anesthetic and opioid /analgesic (19-21). Recent studies have been shown the possible local mechanisms action of tramadol by favoring the opening of nonspecific voltage-dependent potassium (K^+) channels (22), acting in the nitric oxide pathway (23), and the a agonistic action on vanilloid receptor 1 (TRPV-1 transient receptor potential vanilloid-1) that apart from local analgesic effect can exert undesired local side effects such as burning pain and erythema, with high concentration of tramadol blockade of the N-methyl-D-aspartate receptors, local anesthetic effect of tramadol can be explained by direct blocking of voltage-dependent sodium (Na^+) channels (24-26). Therefore, this project was designed to evaluate the effect of tramadol HCL as local anesthetic drug in donkeys as equine model based on its daily clinical and physical examination.

Materials and Methods

Experimental animals

A number of five adult male and female local breed donkeys (aged 2-8 years old and weighing 65.2-87.5 kg) were used in this study. They were kept in animal farm in the Surgery Department/College of Veterinary Medicine/University of Baghdad/Iraq, for two weeks prior to operation for more adaptation as approved by the Ethics Committee of the College of Veterinary Medicine/Animal care. All animals was given 2% Xylazine

Surgical operation

Under aseptic condition an IV, injection was performed using 23-gauge mm needle syringe in the jugular vein for administration of xylazine at dosage of 1.1 mg/kg intravenously as pre-anesthetic followed by local infiltration of 5% tramadol at dose of 10 ml. The parameters which were used for evaluation of efficacy and potency of tramadol are physical examination, degree of chewing movement, degree of pain during palpation, measuring of anesthesia time and secretion of lacrimal gland.


Anesthesia protocol

Preparation the site of operation

The aseptic technique was followed in the present study, the animal in standing position were restrained by administration of 2% xylazine from 4-8 ml, prepared the site of operation by clipping and shaving of hair, washing with tap water and soap then disinfect the area by 70% ethyl alcohol. The site of maxillary sinus incision, was covered with sterile drapes.

Surgical technique

The maxillary sinuses are located at the lateral side of each side of the skull, the dorsal border located from the infraorbital foramen to the medial canthus of the eye, while the ventral border lined from the infraorbital foramen to the anterior edge of the Facial crest, and the posterior border lined from the medial canthus toward the end edge of the facial crest. A 10 cm skin incision was made at the rostral border of the maxillary sinuses, dissect the under lining tissue, stopped the bleeding, the periosteum above the bone skull was dissected, then using the portal trephines to remove part of the maxillary sinuses bone with rotating movement, the skin was closed by 2/0 non absorbable suture material with simple interrupted pattern. Dressing of sterile gauze soaked with Iodine disinfectant to protect the skin incision.



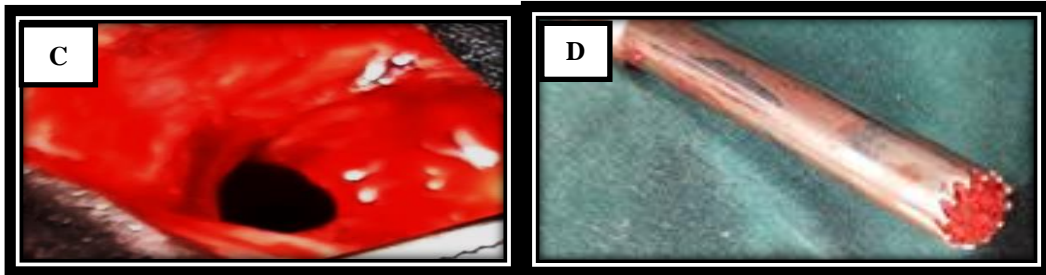


Figure 1. Steps of surgical operation (A) Dissection to expose the muscle and periosteal tissue, (B) Drilling of the maxillary bone with rotating movement by trephine instrument, (C) Maxillary opening after removal part of maxillary sinus, (D) Maxillary opening with same size of bone trephine instrument.

Post-operative examination

To prevent any complication, the systemic antibiotic were administered, Procaine penicillin G 100000 IU, by the intramuscular route every 72 h for 5 days postoperative with clinical observation to the site of operation in maxillary sinus area were performed every day.

Statistical analysis

The Statistical Analysis System- SAS (2018) program was used to detect the effect of difference factors in study of parameters. T-test was used to significant compare between means in this study (27, 28).

Results

Physical parameters

- a) Heart rate: (beats/ minutes) by auscultation using a stethoscope). the heart rate was measured before anesthesia at zero time and after anesthesia at first 1 minute from beginning of induction time (Figure 2)
- b) Respiratory rate: (breath/min) was counted by observation the Movement of the chest and abdominal muscle that recorded before anesthesia at zero time and after anesthesia at 2 minute were the induction time was begin (Figure 3)
- c) Rectal temperature: was recorded by a digital thermometer before anesthesia at zero time and after anesthesia at 3 minute from beginning of induction time (Figure 4).

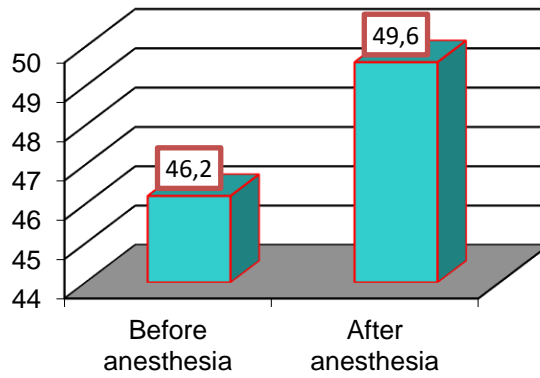


Figure 2: Difference in heart rate before and after anesthesia.

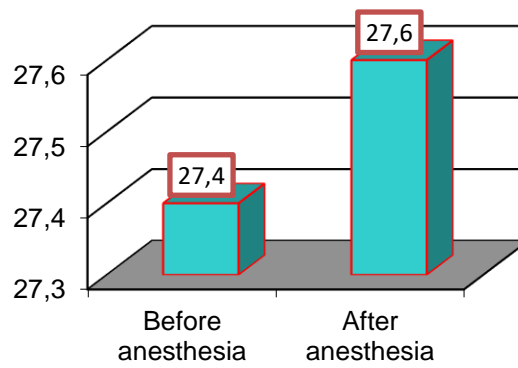


Figure 3: Difference in respiratory rate before and after anesthesia.

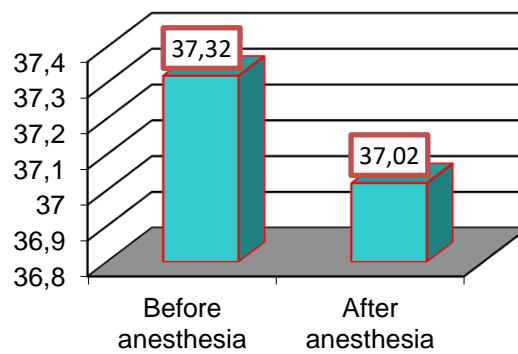


Figure 4: Difference in rectal temperature before and after anesthesia

Table 1. The differences in heart rate, respiratory rate, rectal temperature before and after anesthesia

Anesthesia	Mean \pm SE		
	Temperature - C	Heart rate	Respiratory rate
Before anesthesia	37.32 \pm 0.55	46.20 \pm 1.65	27.40 \pm 2.52
After anesthesia	37.02 \pm 0.59	49.60 \pm 1.96	27.60 \pm 1.03
T-test	1.871 NS	5.924 NS	6.281 NS
P-value	0.721	0.222	0.943

Clinical parameters

Degree of chewing movement

The result of this parameter depend on the observation the movement of upper and lower jaw from the onset time of local anesthetic drug injection until reach to recovery time (Table 2).

Table 2: Score card for chewing movement

Score	Quality	Character
0	No	Animal refuse to eat, the mouth completely closed.
1	Slightly	Animal with little attempt to open mouth, no saliva drooling with slight movement of tongue.
2	Frequent	Only tongue from anterior part of mouth will be seen, saliva present, the animal continues to chew the bolus, but with prolonged time.
3	Strong	All anterior part of the mouth will be seen, tongue protrusion, with excessive saliva drooling.

The results show thatthe movement of upper and lower jaw was absent, the animal refuse to eat, the mouth completely closed from the onset of anesthesia with tramadol till the surgical procedure was completed (Table 5).

Degree of pain during palpation

This depends on the dose of local anesthetic drug that was injected to provide anesthesia along the surgical procedure periods (Table 3).

Table 3: Score card for degree of pain during palpation that detected by pinching method

Score	Degree	Character
0	Excellent	No effect.
1	Good	Response present with excitement sings.
2	Poor sensation	Animal will be stood and show movement in head with severe pain

The results show that the degree of pain was excellent there's no pain during palpation from the onset of anesthesia till the surgical procedure was completed (Table 5)

Secretion of lacrimal gland

This depend on the observation of tear as aqueous solution from the lacrimal canal (that extend from the dorsal border of maxillary sinus to the medial canthus of the eye, during anesthesia that include this location May be detect the effect of local anesthetic drug on canal secretion according to sings of each score (Table 4).

Table 4: Score card for secretion of lacrimal gland under local anesthesia

Score	Response
1	Absent (anesthesia inhibit secretion of lacrimal gland)
2	Present (anesthesia not effect on lacrimal gland secretion)
3	Variable (anesthesia may not effect on lacrimal gland secretion completely the tears may be absent then disappear)

The results show after local infiltration of tramadol in maxillary sinus and induction time was beginning we notice that the secretion of tears from the lacrimal gland was absent (Table 5)

Table 5: Shows mean of clinical parameters \pm SE of scores after local injection of tramadol

Mean \pm SE for Scores			
Degree of chewing movement	Degree of pain during palpation	Secretion of lacrimal gland	T-testP-value
0.00 \pm 0.00	0.00 \pm 0.00	1.00 \pm 0.00	0.333 * (0.045)
T-test (p-value)	NS	NS	NS
Non-significant			

Discussion

The results of the current study showed, that the heart rate was obvious increased after anesthesia due to developed of atrioventricular block that caused by systemic effect of local anesthetic drug on Na⁺ channels and effect of tramadol on Na⁺ and K⁺ channels lead to slightly increased heart rate and significant increased cardiac index and stroke volume agree with Yamashita *et al.* (29). The effect of the alpha-2 agonist in which xylazine administration lead to effect on myocardial contractility and cardiac output lead to effect on central sympathetic outflow which lead to increased heart rate (30-33). Also, tramadol have effect on systolic and diastolic blood pressure due to an opioid sympathomimetic mechanism, but they are not clinically significant at recommended dose this agree with Stamford (34) so, our results in both drugs showed no significant changes in heart rate onset of anesthesia till the end of experiment.the respiratory rate produce less respiratory depression after anesthesia (35) because tramadol

cause CNS inhibition by alpha-2 adrenoreceptors stimulation that effect on respiratory muscle activity leading to inhibit K⁺ channels and increase calcium ion that cause decrease of vascularization of respiratory muscle this result agree with Waldhoer *et al.* (36). The decrease of temperature in tramadol group due to release of monoamines in the anterior hypothalamus since the noradrenaline that inhibited by tramadol (37) lead to reduce the 5-hydroxytryptamin (5-HT) agree with Bigham *et al.* (38) as it affect on body temperature. Ibeas *et al.* (39) mentioned that the hypothalamus might be attributed to decrease in the skeletal muscle tone and metabolic rate with muscle relaxation leading to depression of the thermoregulatory center in the brain. after injection of tramadol as infiltration in maxillary sinus area and observation the chewing movement including upper and lower jaw when we was attempt to offered the food to animals after the induction time of local anesthetic drug, the that there's no response and animal refuse to eat the mouth completely closed. Donald *et al.* (40) mentioned that the duration of chewing depend on the movement of upper and lower jaw sequence that required to movement of both jaw to break down the bolus. This movement was absent due to effect of opioid on number of peripheral nerves (41) that cause inhibition of non-specific voltage dependent Na⁺ channels at this area (42) especially with tramadol when increased the concentration leading to blockade of the NMDA receptor leading to direct blocking of Na⁺ channels that cause inhibition to maxillary labial nerve of upper and lower jaw according to also it have direct effect on channels that related with calcium ion concentration in muscle cell of the jaw that inhibited due to control of tramadol on blood supply of the muscle by vasoconstrictor activity leading to relaxation to the movement of upper and lower jaw (43). The tramadol control to pain locally by inhibition the nociceptive wide dynamic neurons leading to release of transmitter of afferent signals to higher brain center agree with Doherty *et al.* (44) to provide loss of pain locally with analgesic effect systemically, in addition the tramadol inhibit nor-epinephrine and serotonin which enhance the decrease sensation of the pain (45). After local infiltration of local anesthetic drug in maxillary sinus and induction time was beginning we notice that the secretion of tears from the lacrimal gland was absent due to present of some anatomical feature between lacrimal gland and maxillary sinus innervation (46). The secretion of this gland is a response to parasympathetic and sympathetic stimulation that originated from facial nerve and petro palatine nerve that formed post synaptic ganglia with branch of maxillary nerve that reach to lacrimal gland inhibition of this innervations binding feature lead to inhibit secretion of tears that accumulated in canal that pass from dorsal part of maxillary sinus and opened through the duct in medial canthus of the eye (47). The result from this study that the local anesthesia of maxillary sinus was lead to local inhibition to gag ilia that responsible for parasympathetic stimulation of lacrimal gland secretion our result agree with Sullivan (48).

Ethics

All the procedures were approved by the Ethics Committee of the College of Veterinary Medicine/Animal Care (1349/P-G 2022/6/30).

Conflict of Interest

The authors declare that they no conflict of interest.

References

1. Abdeshahi, S. K., Hashemipour, M. A., Mesgarzadeh, V., Payam, A. S., and Monfared, A. H. (2013). Effect of hypnosis on induction of local anaesthesia, pain perception, control of haemorrhage and anxiety during extraction of third molars: a case-control study. *Journal of Cranio-Maxillofacial Surgery*, 41(4), 310-315.
2. Al-gharban, H. A., and Dhahir, S.H. (2015). Serological diagnosis of persistent infection with *Anaplasma marginale* bacteria in cattle. *The Iraqi Journal of Veterinary Medicine*, 39(1), 33-39.
3. Ali, A.F. (2011) Evaluation of general anesthetic regime using romifidine, midazolam and ketamine in donkey. M.Sc. Thesis Baghdad Vet. Collage/Baghdad University, Baghdad-Iraq.
4. Balakrishnan, V. E. (2020). Tramadol in Oral Surgery–A Literature Review. *Indian Journal of Forensic Medicine and Toxicology*, 14(4), 1058-1060.
5. Baraka SZ, lane –Smyth J, lawless and Townsend N. (2008) Trephination of the equine rostral sinus: efficacy and safety of two trephine sites. *Vet surge*, 37, 278-282.
6. Barakzai S.Z andPerkins S., (2005) .the equine Para nasal sinus –part 3. *Uk Vet*, 10 (1), 18-25.
7. Bigham, A. S., Habibian, S., Ghasemian, F., and Layeghi, S. (2010). Caudal epidural injection of lidocaine, tramadol, and lidocaine-tramadol for epidural anesthesia in cattle. *Journal of Veterinary Pharmacology and Therapeutics*, 33(5), 439-443.
8. Brain C. Gliger, 2022. *Equine Ophthalmology*, 4th Edition ,comprehensive references covering all aspects of equine ophthalmology, perfectly suited to general practitioners.
9. Caryn E., Kirk N. Gelatt plummer, 2022. *Essential Veterinary Ophthalmology*, pp: 303.
10. Caryn E., Kirk N. Gelatt plummer,2022.*Essential Veterinary Ophthalmology* pp:303.
11. Changmin, H., Jianguo, C., Dongming, L., Guohong, L., and Mingxing, D. (2010). Effects of xylazole alone and in combination with ketamine on the metabolic and neurohumoral responses in healthy dogs. *Veterinary anaesthesia and analgesia*, 37(4), 322-328.
12. Đanić, P., Salarić, I., and Macan, D. (2017). New Findings on Local Tramadol Use in Oral Surgery. *Acta Stomatologica Croatica*, 51(4), 336-344.
13. Davis, A., and Gilger, B. (2022). Squamous cell carcinoma. In *Comparative Veterinary Anatomy* (pp. 566-575). Academic Press.
14. Doherty, T. and Valverde, A.(2006). *Manual of Equine Anesthesia and Analgesia*. Pharm. Of drugs used in equine anesthesia, 145-146.
15. Donald, Alice F. Healy, Irving B. Weiner K. Freedheim. (2003). *Handbook of physiology –Experimental physiology mechanisims*, pp: 399.
16. Ebenezer, V. (2020). Tramadol in Oral Surgery-A Literature Review. *Indian Journal of Forensic Medicine and Toxicology*, 14(4).
17. Ebenezer, V. (2020). Tramadol in Oral Surgery-A Literature Review. *Indian Journal of Forensic Medicine and Toxicology*, 14(4).
18. Ege, B., Calisir, M., Al-Haideri, Y., Ege, M., and Gungormus, M. (2018). Comparison of local anesthetic efficiency of tramadol hydrochloride and

- lidocaine hydrochloride. *Journal of Oral and Maxillofacial Surgery*, 76(4), 744-751.
19. Fahime, I.; Ismail, M., and Osman, O. H.(1973). Role of 5-hydroxytryptamin-induce hypothermia in animals . *Br. J. pharmacy*. 48(4):570-576.
 20. Gharban, H. A., and Yousif, A. A. (2020). Serological and Molecular Phylogenetic Detection of *Coxiella burnetii* in Lactating Cows, Iraq. *The Iraqi Journal of Veterinary Medicine*, 44(E0), 42-50.
 21. Giacomo Gianotti, Ciara A. Barr, 2019. Textbook of opioid analgesia, tramadol in veterinary medicine, animal anesthesia PP: 334.
 22. Giorgi, M. et al, (2010) .pharmacokinetics of tramadol and its metabolites M1, M2 , M3, M4 and M5 in horses following fasted release single dose administration. *Journal of Equine Veterinary Science*, 27 (1), 467-512.
 23. Greisheimer , E. (1949). The physiological effect of anesthesia. *The American Journal of Nursing*; 49(6): 337-343.
 24. Hall, L.W. and Clark, K.W.(1991). *Veterinary anesthesia*. 9th edition. Bailliere Tiddall/W.B. Saunders. UK.Pp.339-351.
 25. Ho, K. M. (2019). Use of tramadol to attenuate severe dyskinesia in anti-N-methyl-D-aspartate receptor encephalitis. *Anaesthesia and Intensive Care*, 47(6), 561-562.
 26. Ibeas, K., Herrero, L., Mera, P., and Serra, D. (2021). Hypothalamus-skeletal muscle crosstalk during exercise and its role in metabolism modulation. *Biochemical Pharmacology*, 190, 114640.
 27. Imani, F., Entezary, S. R., Alebouyeh, M. R., and Parhizgar, S. (2011). The maternal and neonatal effects of adding tramadol to 2% lidocaine in epidural anesthesia for cesarean section. *Anesthesiology and pain medicine*, 1(1), 25.
 28. John A.Stick,2018.Textbook of Equine Surgery 5th Edition by Diplomat, ACVS professor, Department of large animal clinical sciences College of Veterinary Medicine. Pp: 316-210.
 29. Kargı, E., Işıkdemir, A., Tokgöz, H., Erol, B., Işıkdemir, F., Hancı, V., and Payaşı, C. (2010). Comparison of local anesthetic effects of tramadol with prilocaine during circumcision procedure. *Urology*, 75(3), 672-675.
 30. Kästner, S. B. (2006). A2-agonists in sheep: a review. *Veterinary Anaesthesia and Analgesia*, 33(2), 79-96.
 31. Kay, 2015. *Standard Handbook of Veterinary Drugs*, 4th Edition .Tramadol effect on clinical variable and the mechanical nociceptive threshold in horses, 44 (3), 517-523.
 32. Kul, M., Koc, Y., Alkan, F., and Ogurtan, Z. (2000). The effects of xylazine-ketamine and diazepam-ketamine on arterial blood pressure and blood gases in dogs. *Online Journal of Veterinary Research*, 4, 124-132.
 33. Lamana, S. M. S., Napimoga, M. H., Nascimento, A. P. C., Freitas, F. F., de Araujo, D. R., Quinteiro, M. S., ... and Clemente-Napimoga, J. T. (2017). The anti-inflammatory effect of tramadol in the temporomandibular joint of rats. *European journal of pharmacology*, 807, 82-90.
 34. Mert, T., Gunes, Y., and Gunay, I. (2007). Local analgesic efficacy of tramadol following intraplantar injection. *European journal of pharmacology*, 558(1-3), 68-72.
 35. Ogata, J., Minami, K., Uezono, Y., Okamoto, T., Shiraiishi, M., Shigematsu, A., and Ueta, Y. (2004). The inhibitory effects of tramadol on 5-hydroxytryptamine type 2C receptors expressed in *Xenopus oocytes*. *Anesthesia and Analgesia*, 98(5), 1401-1406.

36. Ogle, O. E., and Mahjoubi, G. (2012). Local anesthesia: agents, techniques, and complications. *Dental Clinics*, 56(1), 133-148.
37. Pang WW, Huang PY, Chang DP, Huang MH., 1992. The peripheral analgesic effects of tramadol injection pain: Comparison with lidocaine. *Regenerative Anesthesia ,pain Medicine ;24:246-249.*
38. Passavanti, M. B., Piccinno, G., Alfieri, A., Di Franco, S., Sansone, P., Mangoni, G., and Fiore, M. (2020). Local infiltration of tramadol as an effective strategy to reduce post-operative pain: a systematic review protocol and meta-analysis. *Systematic Reviews*, 9(1), 1-6.
39. Pozos, A. J., Martinez, R., Aguirre, P., and Perez, J. (2006). The effects of tramadol added to articaine on anesthesia duration. *Oral Surgery, Oral Medicine, Oral Pathology, Oral Radiology, and Endodontology*, 102(5), 614-617.
40. Rodríguez-Wong, L., Pozos-Guillen, A., Silva-Herzog, D., and Chavarría-Bolaños, D. (2016). Efficacy of mepivacaine–tramadol combination on the success of inferior alveolar nerve blocks in patients with symptomatic irreversible pulpitis: a randomized clinical trial. *International Endodontic Journal*, 49(4), 325-333.
41. Sousa, A. M., and Ashmawi, H. A. (2015). Local analgesic effect of tramadol is not mediated by opioid receptors in early postoperative pain in rats. *Revista Brasileira de Anestesiologia*, 65, 186-190.
42. Stamford, J. A. (1995). Descending control of pain. *British journal of anaesthesia*, 75(2), 217-227.
43. Sullivan, B. L. (2012). Con: early extubation in the operating room following cardiac surgery. In *Seminars in Cardiothoracic and Vascular Anesthesia*. Sage CA: Los Angeles, CA: SAGE Publications, 16 (4), 187-189.
44. Turunen, J. (2007). Pain and Pain Management in Finnish General Population (Suomalaisen aikuisväestön kivut ja kivunhoitokeinot). *Kuopion yliopisto*.
45. Uzun, M., Onder, F., Atalan, G., Cenesiz, M., Kaya, M., and Yildiz, S. (2006). Effects of xylazine, medetomidine, detomidine, and diazepam on sedation, heart and respiratory rates, and cloacal temperature in rock partridges (*Alectoris graeca*). *Journal of Zoo and Wildlife Medicine*, 37(2), 135-140.
46. Vickers, M. D., O'flaherty, D., Szekely, S. M., Read, M., and Yoshizumi, J. (1992). Tramadol: pain relief by an opioid without depression of respiration. *Anaesthesia*, 47(4), 291-296.
47. Waldhoer, M., Bartlett, S. E., and Whistler, J. L. (2004). Opioid receptors. *Annual review of biochemistry*, 73(1), 953-990.
48. Yamashita, S., Yamaguchi, H., Sakaguchi, M., Satsumae, T., Yamamoto, S., and Shinya, F. (2000). Longer-term diabetic patients have a more frequent incidence of nosocomial infections after elective gastrectomy. *Anesthesia and Analgesia*, 91(5), 1176-1181.