

How to Cite:

Lathwal, A., Pawah, S., Jain, N., & Gupta, A. (2022). Comparative evaluation of gingival displacement produced by three different gingival retraction materials: An in-vivo study. *International Journal of Health Sciences*, 6(S9), 3332–3348. <https://doi.org/10.53730/ijhs.v6nS9.13323>

Comparative evaluation of gingival displacement produced by three different gingival retraction materials: An in-vivo study

Anjali Lathwal

PG Student, Department of Prosthodontics, Crown & Bridge, Sudha Rustagi College of Dental Sciences and Research, Faridabad
Corresponding Author Email: anjaliathwal103@gmail.com

Salil Pawah

Professor & Head, Department of Prosthodontics, Crown & Bridge, Sudha Rustagi College of Dental Sciences and Research, Faridabad

Neha Jain

Professor, Department of Prosthodontics, Crown & Bridge, Sudha Rustagi College of Dental Sciences and Research, Faridabad

Amit Gupta

Professor, Department of Prosthodontics, Crown & Bridge, Sudha Rustagi College of Dental Sciences and Research, Faridabad

Abstract---Aim: To compare and evaluate the gingival displacement produced by three different gingival retraction materials. Materials and Methods: A study was conducted to evaluate the gingival displacement produced by three gingival retraction materials. 12 subjects were selected for the study. T-stat retraction paste system (Nexobio co.Ltd,Korea), 3M ESPE Retraction Paste (3M Deutschland GmbH, Germany), Roeko Stay- put retraction cord (Coltene Whaledent Pvt. Ltd.) were used in the study. Results: Out of the three materials used, lateral displacement was maximum with the Stay-put retraction cord followed by 3M retraction paste and least by T-Stat retraction paste. All the materials produced acceptable amount of vertical gingival retraction. When compared Stay-put retraction cord was found to be most effective among the three materials. On comparison of the cordless retraction materials, it was found that the material which was more viscous in consistency (3M retraction paste) was able to produce more lateral gingival displacement than the material having less viscosity (T-stat retraction paste) even though both the cordless materials provided almost similar amount of vertical gingival displacement. The overall gingival retraction produced by the Stay-put cord was the highest followed by 3M retraction paste and least by the

T-stat retraction paste. Conclusion: Accurate impressions that capture the prepared margin and finish line are paramount to achieve successful, well-fitting indirect restorations. A vital component in impression making is a traumatic gingival displacement. Modern impression materials and techniques have improved the accuracy of impression making, however, the fundamentals for all current techniques still require management of the gingival tissues adjacent to the preparation, moisture control and adequate placement of the material around the finish line.

Keywords---Cordless retraction, Gingival displacement, FPD impressions, Retraction cord

Introduction

Indirect fixed prosthodontic restorations are widely used for the restoration of teeth. The need for the precise prosthesis, for which the accurate impression of the prosthetic field and in particular of the prepared teeth is decisive. This is critical in both tooth- supported as well as implant supported fixed prosthesis for accurate marginal positioning of the final restoration.¹ One of the main and frequently arising problems in impression making for fabrication of FPDs is to provide accessibility of the impression material not only to, but also beyond the preparation line. The primary reason for this inadequacy was identified as deficient gingival displacement technique.²

The retraction of free gingival margin is a long established and well-known technique which allows the penetration of the impression material into the gingival sulcus that guarantees the exposure and visibility of the underlying unprepared tooth and proper contours of finish line preparation resulting in a high-quality final impression.³

Numerous materials and methods are described in the scientific literature for gingival retraction which accomplish this outlined criterion and can be considered for the gingival retraction for improved clinical outcomes. Electro-surgery, rotary curettage and lasers are also used to reshape and remove gingival tissues to control bleeding and to create access for margin preparation but are used less often due to their higher cost.⁴

Recently, three new retraction systems have been introduced, copper wire reinforced retraction cord (Stay-put), T-stat (aluminum chloride paste system) and 3M Retraction capsule system (based on aluminium chloride). However, studies have not yet been reported to compare the clinical efficacy of these newly available materials.

Thus, the present clinical study is designed and executed to compare the effectiveness of these three different retraction materials in terms of their gingival retraction efficacy that will eventually determine their effectiveness to maintain the marginal integrity of fixed restoration for the long-term clinical success.

Materials and Methodology

Materials:

1. Gingival retraction materials:

- Roeko Stay- put retraction cord of size 00 and size 01(Coltene Whaledent Pvt. Ltd.) along with Easy Stat (20% Ferric sulphate)
- 3M ESPE Retraction Paste (3M Deutschland GmbH, Germany) containing 15% $AlCl_3$
- T-stat retraction paste system (Nexobio co.Ltd,Korea) containing 15% $AlCl_3$

2. Addition Silicone Impression material

- Flexceed Vinyl Polysiloxane Impression material (GC India Dental Pvt.Ltd)
- Type 0: Putty consistency
- Type 3: Light bodied consistency

3. Surfactant (Harvest Dental,USA)

4. Type IV die stone (Kalabhai, Kalrock)

Methodology

The study was carried out in the Department of Prosthodontics, Crown and Bridge, Sudha Rustagi College of Dental Sciences and Research for which 12 subjects were selected.

Inclusion Criteria

- Individuals having complete dentition
- Individuals between the age group of 18-30 years of age
- Individuals having good periodontal health
- Gingival sulcus depth between 1-2mm and absence of deep periodontal pockets
- Normal contour of gingiva
- No bleeding on probing
- Absence of plaque accumulation

Exclusion Criteria

- Individuals with crowding, rotation, restored teeth and cervical abrasion.
- Signs of periodontal disease
- Patients undergoing orthodontic treatment
- Medically compromised patients (diabetes, CVS disorders, hypertension, pregnant and lactating mothers)
- Individuals allergic to aluminum chloride and ferric sulphate

All the 12 subjects were subjected to the retraction materials according to the study design as shown in (Table I).

Table I: Sample Grouping

Group Name	Retraction material	Composition	Sample size
Group I (Control group)	No Retraction	NA	12
Group II	Retraction using T-Stat Retraction paste	15% Aluminum chloride (AlCl_3)	12
Group III	Retraction using 3M ESPE Retraction paste	15% Aluminum Chloride (AlCl_3)	12
Group IV	Retraction using Roeko Stay -put cord impregnated with 20% Ferric Sulphate [$\text{Fe}_2(\text{SO}_4)_3$]		12

Impression making for control group (Group I):

Impressions of the mandibular 2nd premolar were made for the pre-retraction values of all individuals using sectional trays. All the impressions were made by two-step putty wash technique using Addition silicone impression material Flexceed Vinyl Polysiloxane Impression material (GC India Dental Pvt.Ltd) and casts were obtained in Type IV die stone (Kalabhai, Kalrock). Gingival retraction procedure was carried out using the different retraction materials on the buccal aspect of the selected mandibular 2nd pre-molar. In each individual a gap of minimum 7 days was kept between the three post- displacement impressions to avoid tissue fatigue according to the Latin block design as shown in (Table II).

Making of two-step putty wash Impression:

After the material was set it was removed from the mouth. The spacer was removed and the impression was rinsed and dried. For making the wash impression the intra- oral tip was attached to the mixing tip of the cartridge. The light body was placed onto the buccal aspect of either right or left mandibular 2nd pre-molar and over the putty impression and then tray was seated in the mouth for final impression. After the material was set it was removed from the mouth and rinsed under running tap water. (Figure II A)

Table II: Latin Block Design

Subject	Day 1	Day 2	Day 9	Day 16
1	M_0	M_1	M_2	M_3
2	M_0	M_2	M_3	M_1
3	M_0	M_3	M_1	M_2
-	-	-	-	-
-	-	-	-	-

-	-	-	-	-
10	M ₀	M ₁	M ₂	M ₃
11	M ₀	M ₂	M ₃	M ₁
12	M ₀	M ₃	M ₁	M ₂

M₀- Baseline impression

M₂-3M ESPE Retraction Capsule

M₁ - Nexobio T-Stat retraction Paste

M₃-Stay put retraction cord

Retraction procedure for Group II: Using T-stat retraction paste system (Nexobio co.Ltd, Korea)

After rinsing and air drying the selected tooth, the paste was extruded slowly into the sulcus while maintaining the application tip just above the sulcus and aligned approximately parallel to vertical axis of tooth (Figure I A). Sufficient material was extruded into the sulcus to achieve adequate tissue retraction. The material was allowed to remain in the sulcus for at least 2-3 minutes. The treatment site was then examined to verify complete removal of the retraction material prior to making the impression.

Retraction procedure for Group III: Using 3M ESPE Retraction Paste (3M Deutschland GmbH, Germany)

After removing the sealing cap from the capsule tip small quantity of material was dispensed and discarded. After rinsing and air drying the sulcus thoroughly, the capsule tip was introduced into the sulcus. The capsule tip was moved slowly and evenly around the buccal aspect of the selected tooth by pressing out the paste and filling the sulcus all around with enough retraction paste so that an excess appears (Figure I B). The retraction paste was allowed to be seated for at least 2-3 minutes in the sulcus keeping the moisture away from the site. Retraction paste was then removed completely from the sulcus using a mixture of air and water with the aid of a suction device.

Retraction procedure for Group IV: Using Roeko Stay- put retraction cord (Coltene Whaledent Pvt. Ltd.) impregnated with hemostatic solution (Easy Stat containing 20% Ferric sulphate)

Stay put retraction cord of required length was cut and then soaked in the Easy stat solution kept in the dappen dish for 2-3 minutes before the placement in the gingival sulcus. After selection and isolation of the tooth, cord was taken and placed firstly in the center of buccal aspect of the tooth with the help of cord packer and then was packed towards the end of the cord by applying the slight downward pressure to fully pack the gingival sulcus (Figure I C). Cord was left in the sulcus for 2-3 minutes until the retraction was done and then removed with the help of tweezers. Thorough rinsing and air drying the sulcus was done before proceeding with the impression.

Making of the sectioned die:

Mesiodistal width of the premolar was measured with help of Digital vernier caliper (Figure. II B), and the axial center of the tooth was marked on the cast. The cast was positioned and stabilized on the platform of die cutting machine (Figure II C), and the cut was made on the marked central portion of the tooth in the buccolingual direction through the entire length of the cast. A second cut was made distal to the primary cut along the entire length of the cast such that a 3-4 mm thick mesio-distal slice was obtained. (Figure. II D) All the die sections were marked according to their respective groups using permanent marker for identification purpose.

Measuring the gingival displacement:

- To measure the gingival displacement, firstly the gingival sulcus width and depth were measured on the digital image of the mid -buccal region of the tooth by observing the sectioned die using image analysis software of Optical microscope (Olympus DSX10). All the measurements were made under 20X magnification (Figure III).
 - The width of the gingival sulcus was measured by drawing a straight line from the most coronal portion of the marginal gingiva to a point on buccal surface of the tooth. (denoted by CD line in Figure III) And the depth of the gingival sulcus was measured by drawing a straight line from the most apical point of the gingival sulcus to the tip of the buccal cusp of the sectioned pre-molar (denoted by AB line in Figure III).
 - For calculating the amount of gingival displacement, the pre-retraction values (gingival sulcus width and depth) were subtracted from the post-retraction values of each sample for both lateral and vertical displacement.
- $$\begin{aligned} \text{Lateral gingival (D)} &= \text{Post-retraction gingival sulcus width (B)} - \text{pre-retraction gingival sulcus width(A)} \\ \text{Vertical gingival (D')} &= \text{Post-retraction gingival sulcus depth (B')} - \text{pre-retraction gingival sulcus depth (A')} \end{aligned}$$

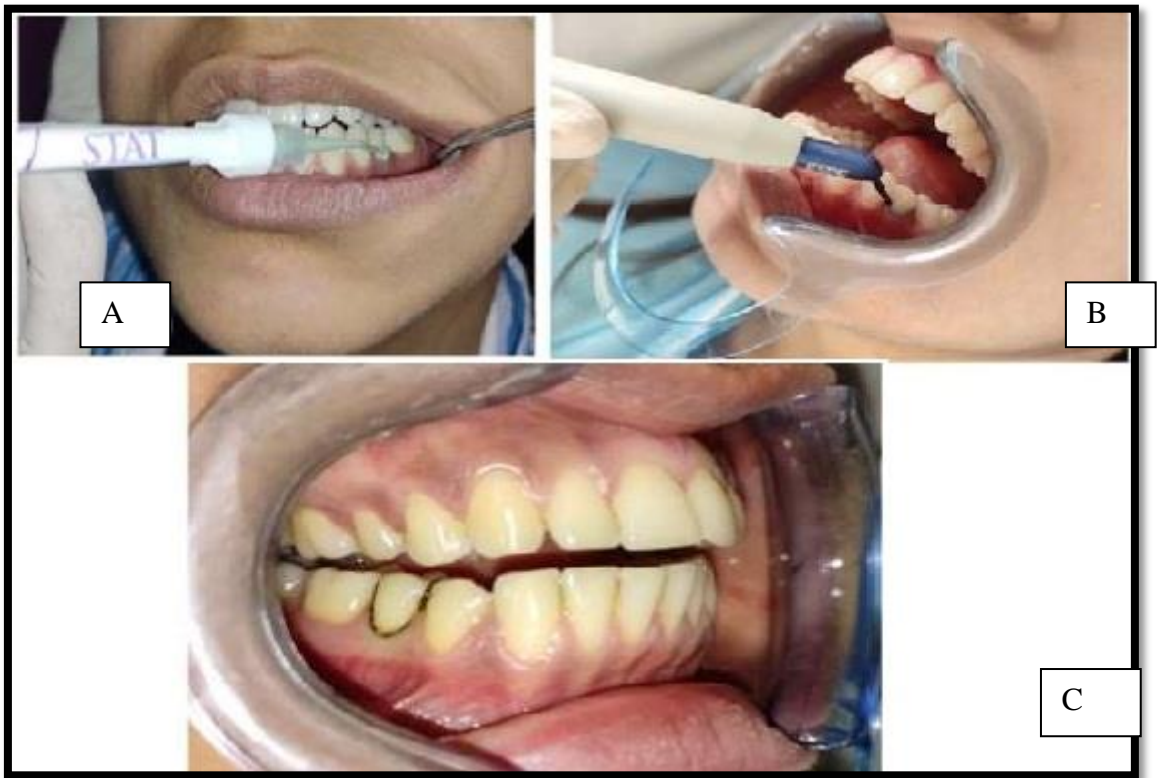

Figure I: (A) Retraction procedure using T-stat retraction paste system
(B) Retraction procedure using 3M ESPE retraction paste
(C) Retraction procedure using Stay-put retraction cord

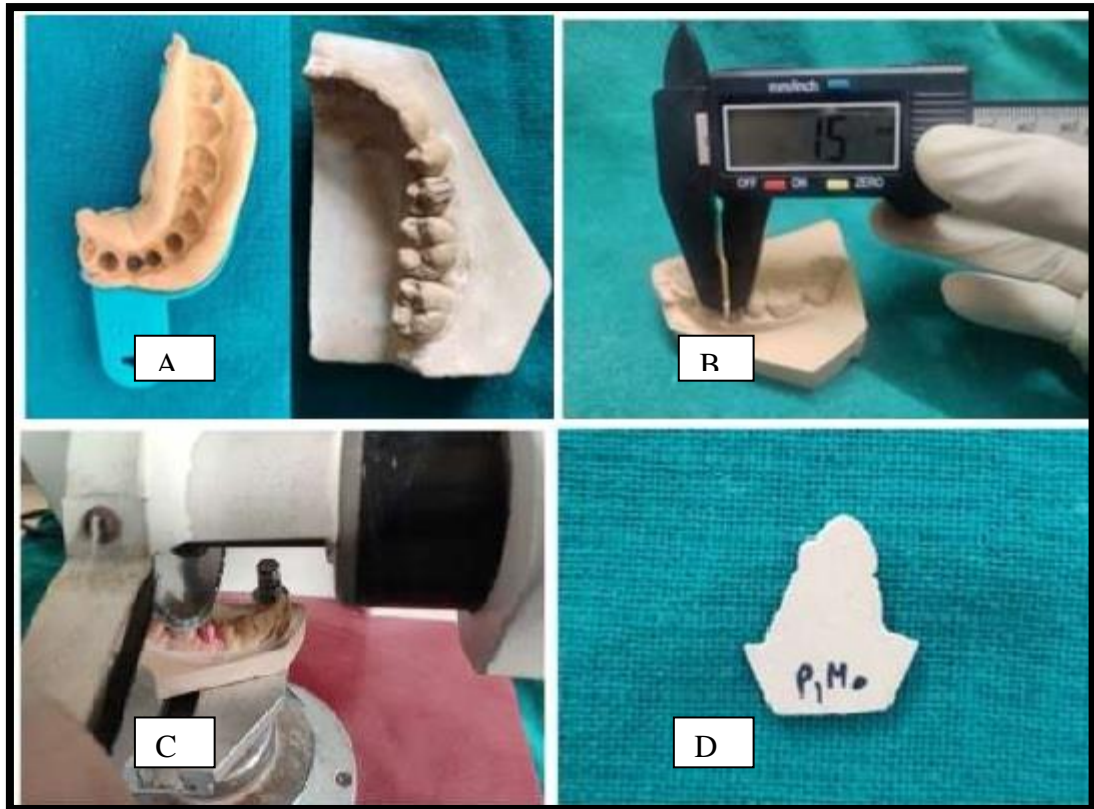


Figure II: (A) Post-displacement impression and retrieved cast
(B) Measurement of mesiodistal width of pre-molar using digital vernier caliper
(C) Sectioning of cast using die cutting machine
(D) Sectioned Die

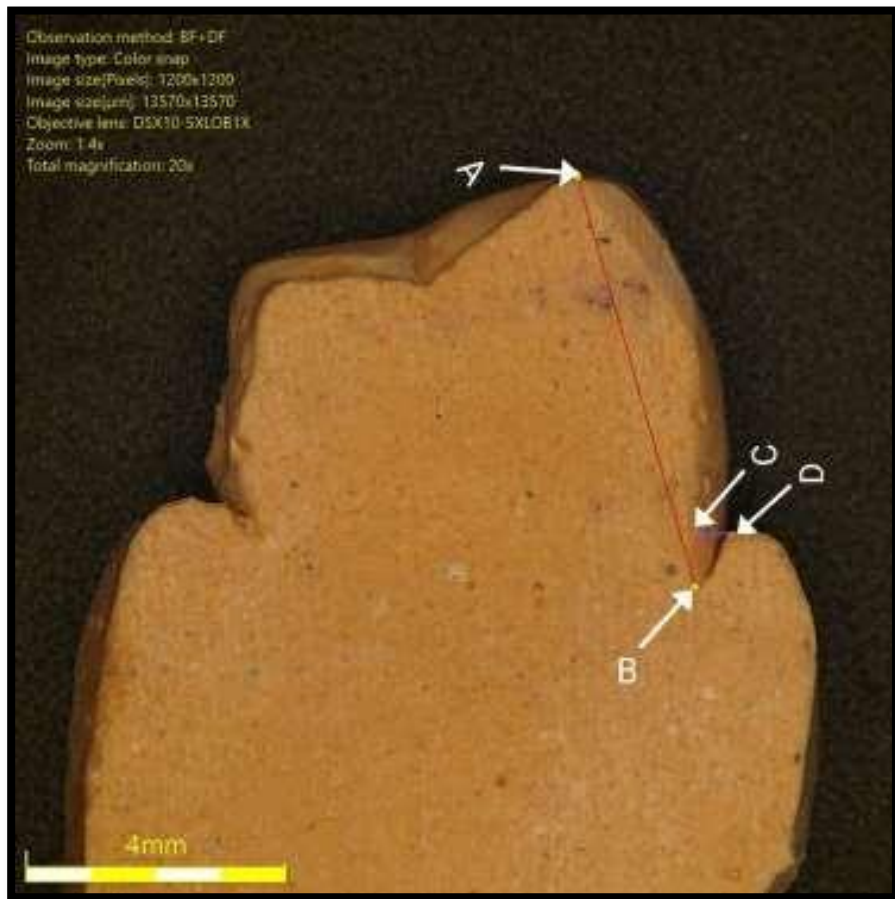


Figure III: Measuring of gingival sulcus width and depth using image analysis software of optical microscope

Statistical Analysis

Results of the study were formulated after statistical analysis of all the observations by One way ANOVA test followed by Post-Hoc test (Tuckey's test) for pairwise comparison.

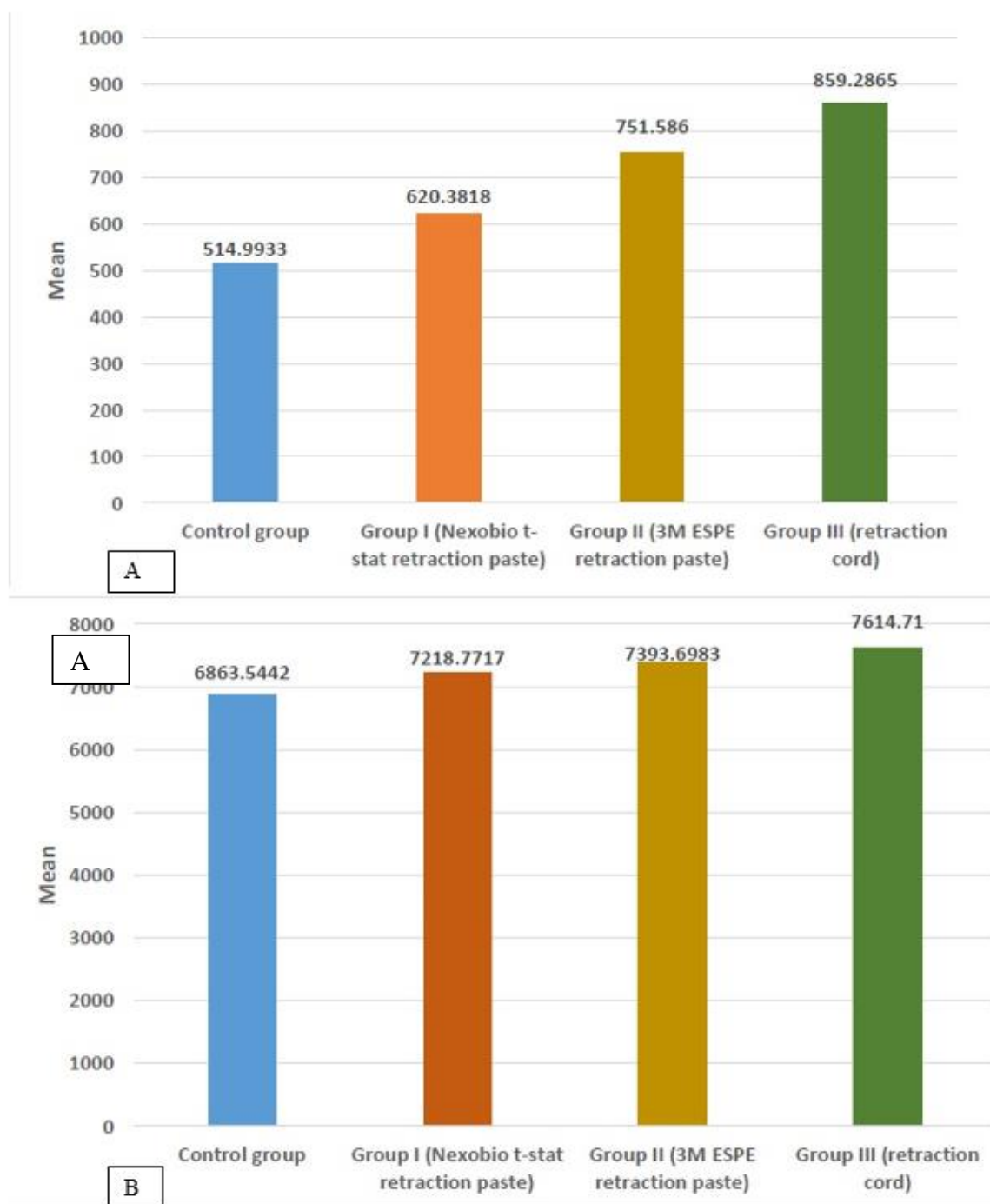
Results

Graph I (A&B) shows Intergroup comparison of gingival sulcus width and depth respectively.

Graph II (A&B) shows mean Lateral gingival retraction and Post hoc pairwise comparison of mean Lateral gingival retraction.

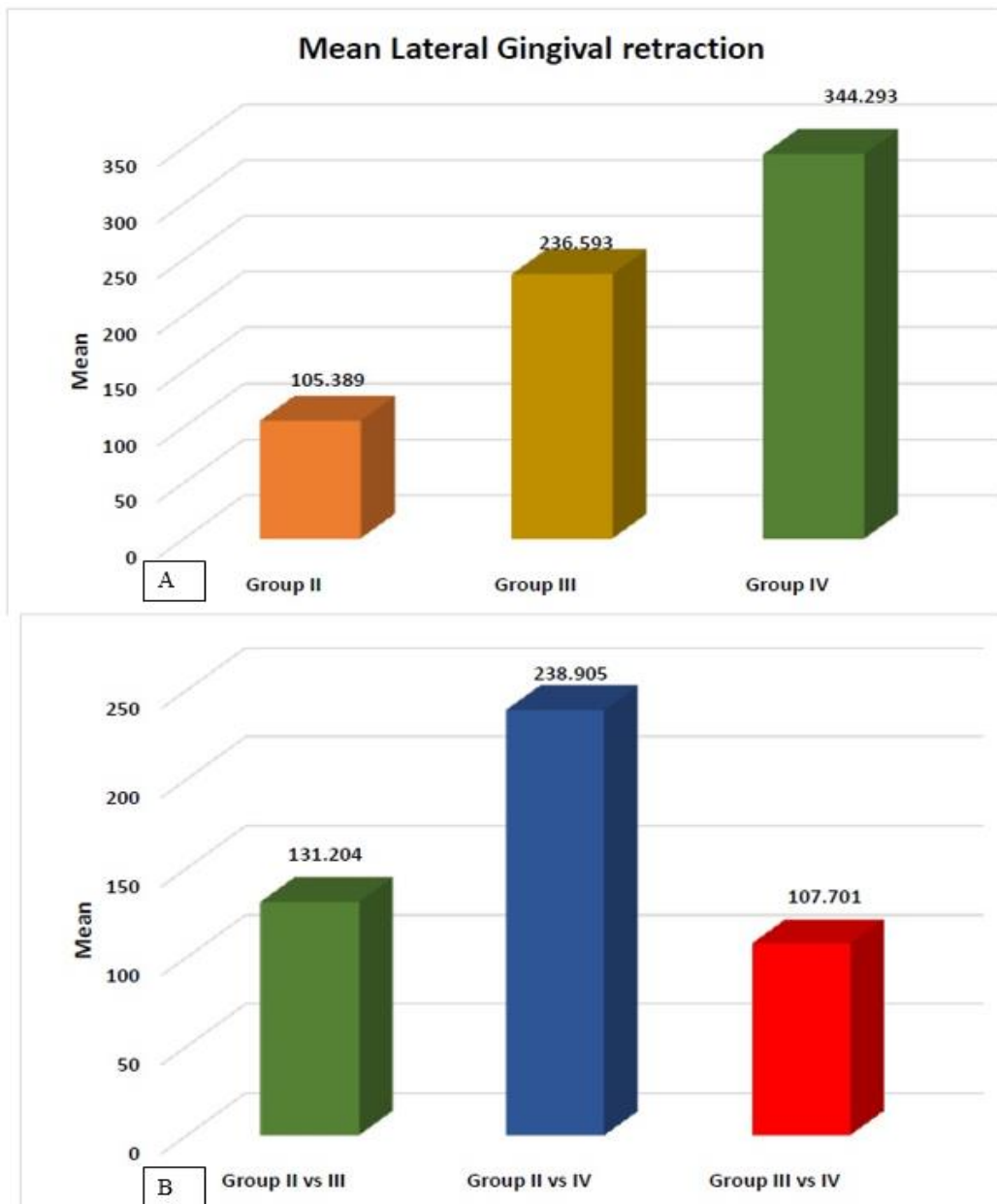
Graph III (A&B) shows mean Vertical gingival retraction and Post hoc pairwise comparison of mean Vertical gingival retraction.

Graph IV (A&B) shows mean Overall gingival retraction and Post hoc pairwise comparison of mean Overall gingival retraction.

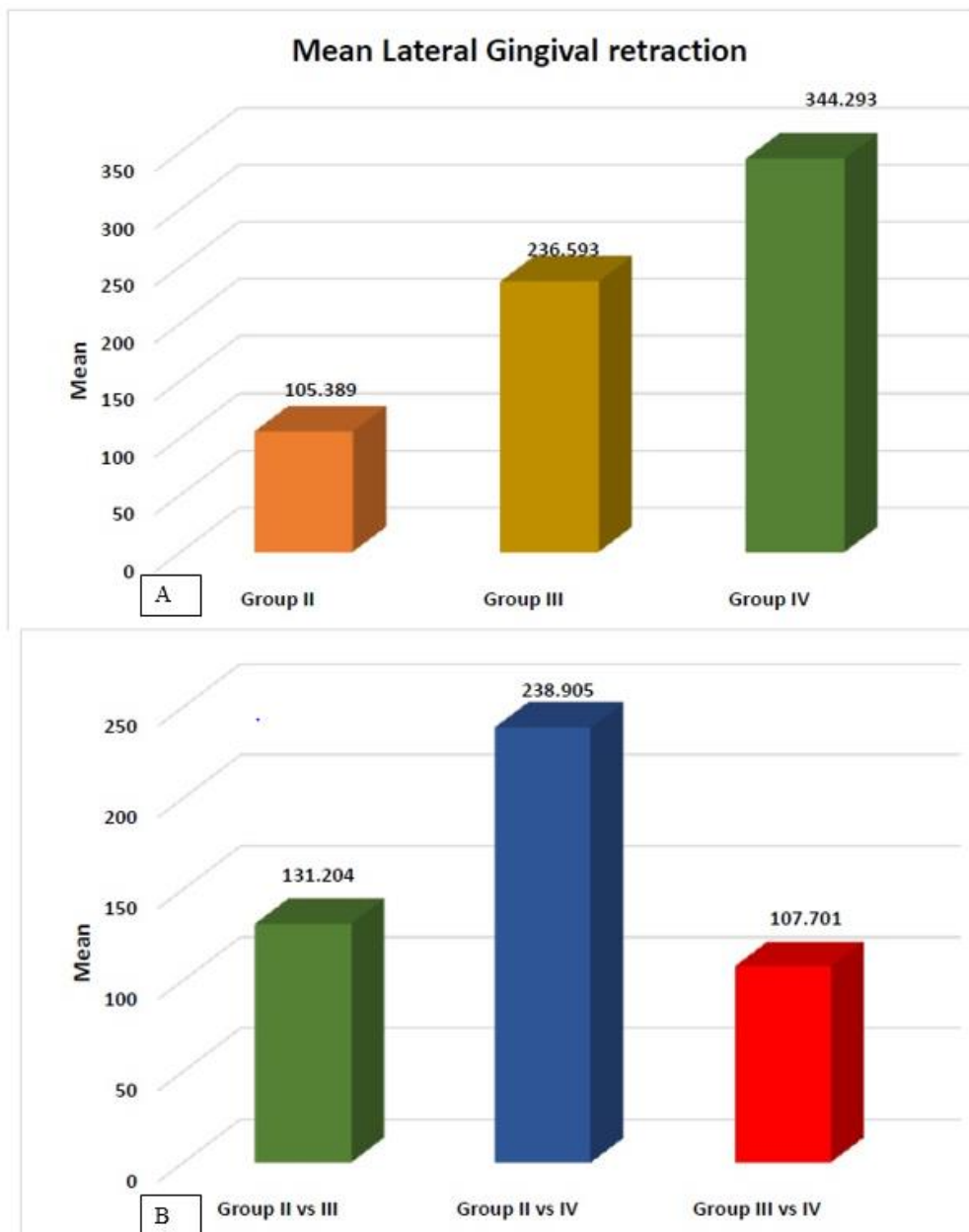


Graph I

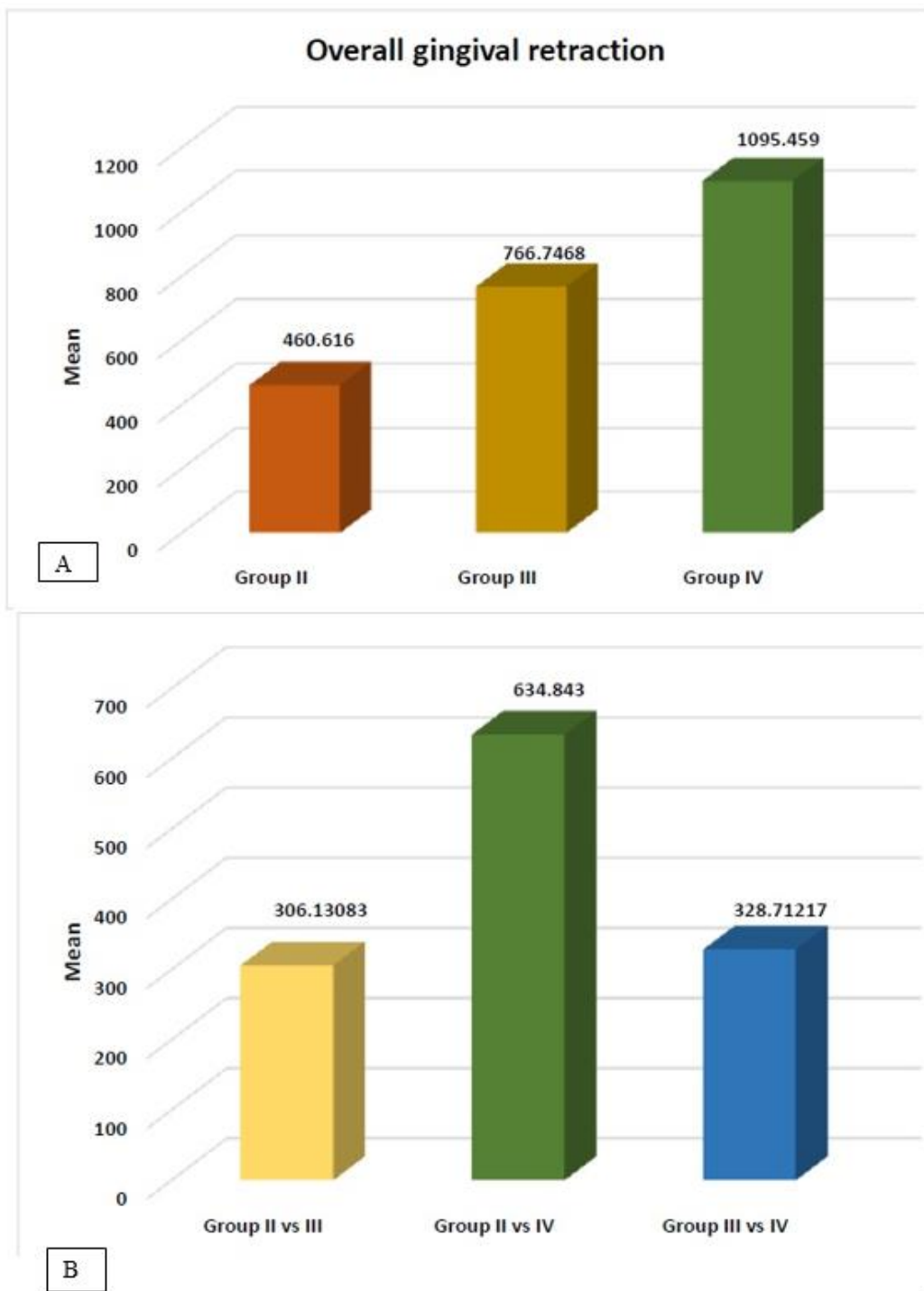
(A): Intergroup comparison of Gingival Sulcus Width
 (B): Intergroup comparison of Gingival Sulcus Depth



Graph II (A): Mean Lateral Gingival Retraction



Graph III (A): Mean Vertical Gingival Retraction
(B): Post hoc pairwise comparison of Mean Lateral Gingival Retraction



Graph IV (A): Mean Overall Gingival Retraction

(B): Post hoc pairwise comparison of Mean Overall Gingival Retraction

Discussion

One of the most challenging aspects of fixed prosthodontic treatment is the gingival tissue management while making an impression to obtain an excellent marginal fit of the fabricated restoration. This is only possible when gingival retraction procedure is carried out to displace the marginal gingiva laterally and vertically to expose the unprepared portion of the tooth apical to the finish line for clear demarcation of preparation margins in the prepared die.⁵

For chemo-mechanical method Roeko Stay- put retraction cord (braided type) of size 00 and size 01 (Coltene Whaledent Pvt. Ltd.) impregnated with Easy Stat (20% Ferric sulphate) solution was used. It was selected for its unique property of being wrapped around an ultrathin copper wire, which is supposed to provide better stability in the gingival sulcus due to its adaptability and pliable property.⁶ The cord was impregnated with Easy Stat (20% Ferric sulphate) solution to get the astringent effect while placing and removing of the cord from the sulcus. A study conducted by Weir and Williams concluded that dry retraction cords caused maximum bleeding on removal. Furthermore, the placement of retraction cord into the gingival sulcus may cause injury to sulcular epithelium and may induce bleeding on removal.⁷ Thus, decision of using chemically impregnated cord rather than plain cord was made.

In this study, 3M ESPE Retraction Paste (3M Deutschland GmbH, Germany) and T-stat retraction paste system (Nexobio co.Ltd,Korea) were selected. Both the materials contain 15% aluminum chloride paste system slightly differing in their consistency and delivery system.

The study was performed on unprepared mandibular 2nd pre-molar. 2nd pre-molar was chosen to avoid any pigmentation and discoloration caused by chemical agents in anterior region and to get better accessibility than the posterior teeth. Laufer et al found that the mid-buccal sulcus remained open longer than the transitional line angle.⁸ Thus, the measurements for the gingival retraction were taken from the mid-buccal sulcus area.

Addition Silicone Impression material (Flexceed Vinyl Polysiloxane Impression material (GC India Dental Pvt.Ltd) was used for making dimensionally accurate impressions. Lacy et al. conducted a quantitative comparison of the accuracy and dimensional stability of representative products in each class of polyether, polysulfides, and PVS and showed that PVSs are the most stable of elastomeric impression materials.⁹

In the present study, the amount of gingival displacement was measured on the 3-4 mm thick buccolingual section of the cast under optical microscope with image analyzer software. This method was similar to the technique followed by Bowles et al., and Chaudhari et al.^{10,11} Y.G. Naveen and Patil R concluded from their study that dimensionally accurate and defect free impressions were obtained in sulcus width of 0.15 mm and wider.¹² The Impressions with less sulcular width have higher incidents of distortion, voids, tearing of impression material, and reduction in marginal accuracy.¹³

In the present study it was observed that all the three retraction materials used achieved a minimum sulcus width of 0.40mm, 0.58mm and 0.53 mm respectively which correspond to the critical sulcular width of 0.2 mm at the level of finish line. Also, comparison of the means of the experimental groups; 0.62mm, 0.75mm and 0.85mm corresponding to Group II, Group III, and Group IV showed higher values than control group (0.51mm) with statistically significant difference. This means that all three materials are capable of producing some amount of lateral displacement.

Among the experimental groups, Group IV (stay-put retraction cord) showed the highest amount of lateral gingival displacement, i.e., 0.34mm. Next in line the Group III (3M retraction capsule) showed 0.23mm displacement. The least amount of displacement was found with Group II (T-stat retraction paste), i.e., 0.10mm. The results obtained appear to concur with the findings of a previous study conducted by Gupta et al. He compared the Stay-put retraction cord with the two cordless retraction materials i.e Expasyl and Magic form cord. The stay-put gingival retraction cord showed more amount of gingival displacement than gingival retraction paste.¹⁴

Results of the present study are also in agreement with the study conducted by Chaudhari et al. He compared the cord impregnated with aluminum chloride; cord impregnated with tetrahydrozoline to Expasyl gingival retraction paste which is a cordless material. Cordless material showed the least amount of gingival displacement when compared with the impregnated cord.¹¹

Prasanna et al in their study observed that paste systems showed an increase of 0.26mm in sulcus width whereas retraction cords showed only 0.21mm increase in sulcus width.¹⁵ The study conducted by Yang et al also concluded that cord produced slightly less gingival retraction (0.28mm) than Expasyl paste (0.29mm).¹⁶ The contradictory results of these studies might be due to the fact that restricted assess to the area and elasticity of the gingival cuff may tend to limit the penetration of the cord which might have resulted in less amount of gingival retraction caused by the cords.

In the current study, it was also observed that though the retraction materials in the group III (3M Retraction paste) and Group IV (Stay-put retraction cord) produced sulcus width of >0.2 mm, but the amount of retraction produced by both these materials showed no statistically significant difference (p value =0.07). The data obtained is in concordance to the results obtained in previous studies carried out by Yang et al and Acar et al where authors found no significant difference between cords and paste system.^{16,17}

In this study, comparison of two cordless gingival retraction pastes showed that Group III (3M retraction paste) provided more retraction values than the Group II (T stat retraction paste). This is in agreement with findings of a previous study conducted by Agarwal A in which the authors concluded that amount of mean horizontal gingival retraction attained by less viscous syringeable retraction system (Dryz) was less when compared to the more viscous cordless method (Expasyl).¹⁸

Intergroup comparison of mean gingival sulcus depth showed overall significant difference ($p=0.03$) from the control group when compared using one way ANOVA test which means that all the three experimental materials were capable of producing some amount of vertical displacement when compared to control group. Post hoc pairwise comparison of mean gingival sulcus depth shows significant difference ($p=0.02$) in the gingival sulcus depth of Group I (control group) vs Group IV (Stay-put retraction cord) which signifies that only Group IV i.e. retraction cord was able to displace the gingiva significantly.

The overall mean gingival retraction produced by all the test groups (Group II, III and Group IV) was found significant when compared using One way ANOVA test ($p=0.001$). Post hoc pairwise comparison using Tukey's test showed statistically significant difference only between Group II (T-stat retraction paste) and Group IV (Stay-put Retraction cord). The results signifies that the overall gingival retraction produced by the Group IV (Stay-put cord) was the highest followed by Group III (3M retraction paste) and least with the Group II (Tstat retraction paste).

Within the limited scope of the present study, it can be concluded that all the three retraction materials are reasonably acceptable as per the results, as all the three provided retraction more than the minimum amount of retraction (0.22mm) required for any fixed partial denture impressions. The results signifies that the gingival retraction produced by the Group IV (Stay-put cord) was the highest followed by Group III (3M retraction paste) and least with the Group II (T-stat retraction paste). It can be concluded from the study that the retraction cord is the most efficient gingival retraction material for clinical use.

Conclusion

Accurate impressions that capture the prepared margin and finish line are paramount to achieve successful, well-fitting indirect restorations. A vital component in impression making is atraumatic gingival displacement. Modern impression materials and techniques have improved the accuracy of impression making, however, the fundamentals for all current techniques still require management of the gingival tissues adjacent to the preparation, moisture control and adequate placement of the material around the finish line.

Bibliography

1. Safari S, Ma VS, Mi VS, Hoseini GF, Hamed M. Gingival retraction methods for fabrication of fixed partial denture: literature review. *J Dent Biomater* 2016;3(2):205-13.
2. Samet N, Shohat M, Livny A, Weiss EI. A clinical evaluation of fixed partial denture impressions. *J Prosthet Dent* 2005;94(2):112-7.
3. Katreva I, Doychinova M. Adequate gingival retraction as prerequisite for fabrication of precise fixed partial dentures-algorithm for clinical implementation. *Scripta Scientifica Medicinae Dentalis*. 2017;3(2):13-7.
4. Shillingburg HT, Sather DA, Wilson EL, Cain JR, Mitchell DL, Blanco LJ et al. *Fundamentals of fixed prosthodontics*. 4th ed. Quintessence Publishing Company; 2012:273p.
5. Benson BW, Bomberg TJ, Hatch RA, Hoffman W., Jr Tissue displacement

- methods in fixed prosthodontics. *J Prosthet Dent.* 1986;55:175-81.
6. Qureshi SM, Anasane NS, Kakade D. Comparative evaluation of the amount of gingival displacement using three recent gingival retraction systems-In vivo study. *Contemp Clin Dent.* 2020;11(1):28-33.
 7. Weir DJ, Williams BH. Clinical effectiveness of mechanical-chemical tissue displacement methods. *J Prosthet Dent.* 1984;51(3):326-9.
 8. Laufer BZ, Baharav H, Cardash HS. The linear accuracy of impressions and stone dies as affected by the thickness of the impression margin. *Int J Prosthodont.* 1994;7(3):247-52.
 9. Lacy AM, Fukui H, Bellman T, Jendresen MD. Time-dependent accuracy of elastomer impression materials. Part II: Polyether, polysulfides, and polyvinylsiloxane. *J Prosthet Dent.* 1981;45:329-33.
 10. Bowles WH, Tardy SJ, Vahadi A. Evaluation of new gingival retraction agents. *J Dent Res.* 1991;70(11):1447-9.
 11. Chaudhari J, Prajapati P, Patel J, Sethuraman R, Naveen YG. Comparative evaluation of the amount of gingival displacement produced by three different gingival retraction systems: An in vivo study. *Contemp Clin Dent.* 2015;6(2):189-95.
 12. Naveen YG, Patil R. Effect of the impression margin thickness on the linear accuracy of impression and stone dies: an in vitro study. *J Indian Prosthodont Soc.* 2013;13(1):13-8.
 13. Laufer BZ, Baharav H, Ganor Y, Cardash HS. The effect of marginal thickness on the distortion of different impression materials. *J Prosthet Dent.* 1996;76:466-71.
 14. Gupta A, Prithviraj DR, Gupta D, Shruti DP. Clinical evaluation of three new gingival retraction systems: A research report. *J Indian Prosthodont Soc.* 2013;13(1):36- 42.
 15. Prasanna GR, Reddy K, Kumar RN, Shivaprakash S. Evaluation of efficacy of different gingival displacement materials on gingival sulcus width. *J Contemp Dent Pract.* 2013;14(2):217-21.
 16. Yang JC, Tsai CM, Chen MS, Wei JY, Lee SY, Lin CT. Clinical study of a newly developed injection-type gingival retraction material. *Chinese Dental Journal.* 2005;24(3):147-51.
 17. Acar O, Erkut S, Ozcelik TB, Ozdemir E, Akcil M. A clinical comparison of cordless and conventional displacement systems regarding clinical performance and impression quality. *J Prosthet Dent.* 2014;111(5):388-94.
 18. Agarwal A, Lahori M, Arora S. A comparative evaluation of two contemporary cordless methods of gingival retraction - An in vivo study. *J Interdiscip Dentistry* 2019;9:51-8.