

How to Cite:

Zahedpasha , M., Ghorbani , H., Johari, M., Shirgahitalari, F., Hamedirad , F., & Khafri , S.
Evaluation of the anterior maxillary bone for implant placement and its relationship with the final
restoration using Cone Beam Computed Tomography (CBCT) images. *International Journal of Health
Sciences*, 6089-6104. Retrieved from
<https://sciencescholar.us/journal/index.php/ijhs/article/view/13437>

Evaluation of the anterior maxillary bone for implant placement and its relationship with the final restoration using Cone Beam Computed Tomography (CBCT) images

Mahsa Zahedpasha (Zahedpasha M.), Dr (DDS)

Student Research Committee, Babol University of Medical Sciences, Babol, I.R. Iran

Hakimeh Ghorbani (Ghorbani H.), Dr (DDS, MSD)

Assistant Professor, Oral Health Research Center, Health Research Institute,
Babol University of Medical Sciences, Babol, I.R. Iran

M Johari (Johari M.), Dr (DDS, MSD)

Assistant Professor, Oral Health Research Center, Health Research Institute,
Babol University of Medical Sciences, Babol, I.R. Iran

Foruzesh Shirgahitalari (Shirgaei talari F.), Dr (DDS, MSD)

Assistant Professor, Dental materials research center, health research institute
Babol university of medical sciences. Babol Iran

Fahimeh Hamedirad (Hamedirad F.), Dr (DDS, MSD)

Assistant Professor, Oral Health Research Center, Health Research Institute,
Babol University of Medical Sciences, Babol, I.R. Iran and Assistant Professor, DDS,
MS, Oral Health Research Center , Health Research Institute , Babol University of
Medical Sciences. Babol, I.R. Iran. (Orcid:0000-0001-8615-0728)

Phone number: 00989151109032

Postal address (also work address): Prosthodontics department of the Dental
Faculty of Babol University of Medical Sciences –Felestin square- Babol-
Mazandaran- Iran- Zip: 47176-43633

Work place Tel : 00981132291408-9

Home Tel: 00981132333788

Fax: 00981132291093

Corresponding Author email: Fahimeh.hamedirad@gmail.com

Soraya Khafri (Khafri S.), (PHD)

Assistant Professor, Infertility and Reproductive Health Research Center, Health
Research Institute, Babol University of Medical Sciences, Babol, I.R. Iran

Abstract---Statement of the Problem: The thickness and height of the facial wall of the alveolar bone in anterior part of maxilla is a critical factor to achieving esthetic and success of implant insertion. Objectives: The aim of present study was evaluating the anterior maxillary bone by cone beam computed tomography (CBCT) images. Methods :In this in vitro study, 200 CBCT images of the anterior maxillary teeth were examined. Each tooth was classified according to the sagittal root position and the measurements were done by one practitioner. Results: The following variables were significantly associated with gender (male predilection): tooth-ridge angulation (TRA)in the right lateral teeth; concavity angulation (CA)in the right central and lateral teeth; concavity depth (CD) in the right lateral teeth and both canines; concavity location (CL)in the right canine; buccal bone height (BH)and palatal bone height (PH) in the left canine. Age was associated with CLand ridge angulation in none of the teeth; with TRA and CD in all anterior teeth; bone density in the right lateral teeth; with CA in both lateral teeth; with BH in both central teeth; with PHin the right central and left lateral teeth; and with TA in both lateral teeth and canines. Conclusion: The placement of implants in maxillary canines site compared to central teeth is harder , due to facial position of the root, thin facial bone, low CA, high CD.

Keywords---*CBCT image, Maxillary bone, Implant placement.*

Introduction

Radiography is one of the important diagnostic tools utilized in dentistry operation [1]. Cone beam computed tomography (CBCT), an emerging digital imaging technique, provides investigation of craniofacial hard and soft tissues via different planes [1,2]it reproduce excellent images and has one tenth amount of radiation than conventional CT scanning technique[2]. Before implant replacement CBCT is done to evaluate the bone quality and quantity [2].

One of treatment options in anterior tooth replacement is implant treatment [3]. As in this section esthetic is critical for best results Several factors should be noticed :buccal bone thickness and bone height specially in immediate implantation are critical [4].

The thickness and form of alveolar bone is different between patients. Some factors like maxillary bone jaw morphology, position of the upper incisors, and facial type (e.g. shorter face type persons have greater alveolar bone thickness compared to long face ones), inclination of the incisors, and degree of jaw protrusion [5]affect the thickness and form of alveolar bone .Moradet al.[6] reported the mean thicknesses of 1–1.2 mm in the maxillary anterior tooth regions, respectively. Jin et al. [7]reported a thickness <2 mm in the Canine region. These volumes are ethnic populations related [3,6] , gender, side of the tooth, face type, and soft tissue type may also have effect on the thickness and height of the facial wall of the alveolar bone. However, alveolar bone

measurements have not yet been studied in Iranian populations. So current investigation used CBCT images to measure alveolar bone in the aesthetic zone of the maxillary anterior teeth in an Iranian adult population patients, focusing on the quantifications relation with gender and age.

Materials and Methods

The study was designed as a crosssectional radiographic study to evaluate the quality and quantity of anterior maxillary bone(left canine to right canine) in order to immediate implant placement by using CBCT images. CBCT images were taken from the archives of a private oral and maxillofacial radiology center in Babol, Iran. The CBCT images required for this study were 200 which should have all 6 anterior maxillary teeth. Any image that showed signs of periapical pathologic lesion, previous apical surgery, root fracture and root resorption in the region of interest and any images that presented with lack of clarity or too much scattering were excluded.

All CBCT scans were made with Planmeca Promax 3D S3 (Finland, Helsinki) (Field of view 8×10) and processed with Planmeca Romexis viewer software. In order to determine relative tooth inclination, the maxilla was positioned horizontal to the anterior nasal spine-posterior nasal spine plane. (the normal inclination is defined 110 ± 5 degree) [1,3]. Each tooth was classified according to axial and buccolingual position in the bone. (Figure 1) [8].

To determine the height and thickness of the bone, two reference lines were drawn. The first line was drawn from the center of long axis of tooth, while the second line was drawn perpendicular to the apex. The bone height was measured in millimeters (mm) for facial and palatal bones from the bone crest to the apical line, parallel to the long axis of the tooth. (Figure 2A) The bone thickness was measured in four different locations parallel to the apical plane: A) crestal area; B) midroot; C) apex; and D) 4 mm above the apex (parallel to the apical line). At location A, the bone thickness was 1 mm from the crestal bone. At location C, the bone thickness was measured at the apical line. At location B, thickness was measured midway between point A and point C (Figure 2B) [8].

The following distances and angles were measured to determine the morphology of the alveolar ridge:

- 1) Ridge angulation (RA): It is the angle between the ridge midline and the maxillary plane. The ridge midline was determined by connecting three buccolingual midpoints at vertical distances of 2, 6, and 12 mm from the alveolar crest. The maxillary plane is defined as the line that connects the anterior nasal spine (ANS) to the posterior nasal spine (PNS) point.
- 2) Tooth angulation (TA): It is the angle between line A (the line between incisors and the apex, dividing the tooth into palatal and facial parts) and the maxillary plane (Figure 3A).

- 3) Tooth-ridge angle (TRA): It is the angle between line A and line B; line B represents the line running through the faciopalatal midpoint of the alveolar process (Figure 3A) [9,10].
- 4) Concavity depth (CD): It is the distance between the deepest point of the facial plate (point D) and a vertical reference line perpendicular to the maxillary plane, passing through the most external point of the facial plate (point C) (Figure 3B).
- 5) Concavity angulation (CA): It is the angle between line D-C (the line connecting point D to point C) and line D-P (the line connecting point D to point P, with point P defined as the most external point of the facial plate, coronal to point D) (Figure 3B).
- 6) Concavity location (CL): It is the vertical distance between point D and the line connecting the cemento-enamel junction (CEJ) of teeth (Figure 3B)[9,10].

To evaluate the bone quality of the anterior maxilla, bone density was defined as Hounsfield units using a device. The Hounsfield unit is a simple and rapid technique to assess bone quality in patients with available CT scans [11]. All CBCT images were reviewed by an observer with no information about the patients' clinical status; the judgments and conclusions were solely based on radiographic images. Also, to ensure the reliability of the results, 10% of the samples were randomly re-examined in an interval of two weeks.

Data were evaluated in SPSS version 25, using descriptive statistics, including number (percentage) and mean±standard deviation (SD). Results were compared between the groups in terms of gender and age, using independent t-test, Chi-square, and ANOVA test.

Results

In this study, the anterior maxillary bone was examined in 200 CBCT images (each image covering all six anterior teeth). The images were obtained from a statistical population, including 110 female patients (55%) and 90 male patients (45%), aged 15-66 years (mean age: 39.35 years). The distribution of tooth classes, based on the inclination and sagittal root position, is shown in Figure 1. The tooth classification had a significant relationship with gender ($P < 0.001$). The distribution of tooth classes in men and women was as follows (Figure 4)

Women: Class III > Class II > Class IV > Class V > Class I > Class VI > Class VII

Men: Class III > Class II > Class V > Class I > Class IV > Class VI

Measurement of the buccal and palatal bone thickness showed that the buccal bone thickness had a significant relationship with gender only in location A (at the crest); at this location, men had a thicker buccal bone ($P = 0.005$). The palatal bone thickness had a significant relationship with gender in location B (midroot), location C (apex), and location D (4 mm apical from the apex); men showed

thicker palatal bones in these locations ($P < 0.001$, $P < 0.001$, and $P = 0.042$, respectively).

However, the bone density, TA, and RA had no significant relationship with gender. The TRA had a significant relationship with gender only in tooth 10. In tooth 10, men had more TRA than women. The average CA, CD, and CL for each tooth, as well as differences between gender, are presented in Table I, Table II, and Table III.

Effect of age:

The RA and CL showed no significant relationship with age in any of the six anterior teeth, whereas the TRA and CD had significant associations with age in each of the six anterior teeth. Also, the bone density showed a significant relationship with age in tooth 10 ($P = 0.009$). Besides, the CA had a significant relationship with age in tooth 7 and tooth 10 ($P = 0.044$ and $P = 0.021$, respectively). The buccal bone height (BH) showed a significant relationship with age in tooth 9 and tooth 8 ($P = 0.002$ and $P = 0.040$, respectively). Also, the palatal height (PH) had a significant relationship with age in tooth 9 and tooth 7 ($P < 0.001$ and $P = 0.043$, respectively). Finally, the TA showed a significant relationship with age in tooth 10, 11, 7, and 6 ($P = 0.037$, $P = 0.006$, $P = 0.011$, and $P = 0.003$, respectively).

Discussion:

The most important factor in the long-term survival of implants is the implant location in the jaw bone. If the implant is positioned correctly at the same angulation as the roots into the bone, the final restoration will be in the correct position [12]. Therefore, before a dental implant surgery, analysis of 3D radiographic images is an important diagnostic step in determining the root direction of the tooth, the adjacent anatomical areas, and the buccal bone thickness. For this purpose, it is necessary to prepare CBCT images before an implant surgery [13].

The reason for choosing CBCT images in this study was the lower radiation dose of CBCT, better representation of hard tissues, higher image resolution, and more accurate linear measurements compared to CT imaging. These advantages have made CBCT an implant-specific imaging technique [14]. According to the results of this study, the average bone density of the anterior maxillary bone was 445.94 ± 200.71 , while in a study by Y Hao et al. on Asian people, the average bone density of the anterior maxillary bone was 460.25 ± 136.42 [15]. The discrepancy between the findings may be due to differences between male and female populations of the two studies.

In the present study, the mean TA and RA were 103.58 ± 9.14 and 114.72 ± 31.62 , respectively. The highest TA and RA were related to the central, lateral, and canine teeth, respectively. The mean TRA was 10.35 ± 4.74 , and the highest TRA was related to the central teeth, canines, and lateral teeth, respectively. In this regard, a study by Nasrollahi N et al. from Iran reported similar results to our study, as the largest tooth and ridge angles were observed in the central, canine, and lateral teeth, respectively [16]. However, in a study by Wang HM from China, the TRA

angle was larger in the canines than in the incisors; differences between the results may be due to racial differences or different definitions of measurement points in these two studies [17].

In a study by Seung-Lok Lee from Korea, the curvature angulation of the buccal bone (drawing a line through the P, Q and R points : QPQR) was measured. Although the QPQR was approximately the same as the CA angle in the present study, the CA was measured above the apex in our study. This result is in line with our study, as the largest CA was related to the canine, lateral, and central teeth, respectively [18].

This finding can be explained by the average Collum angle in the anterior teeth. The Collum angle is the angle between the long axis of the crown and the long axis of the root. Normally, the largest Collum angle is attributed to the lateral, central, and canine teeth, respectively.

The canine teeth have the largest Collum angle of all types of malocclusions; however, in the central and lateral teeth, this angle is related to the type of malocclusion [19]. The mentioned finding seems logical due to the position of the occlusal plane and canine angulation, because from incisors to canine teeth, the crown of the tooth gradually becomes more buccal, and the root becomes more palatal. However, the present results regarding CD differ from those reported by Ahmed from Egypt [20].

In their study, the canines had the highest CD, [19] while in the present study, the highest CL was related to the lateral teeth, and the lowest CL was attributed to the lateral ones; this result may be attributed to the short length of the root in lateral teeth. Among maxillary anterior teeth, the maximum root length was related to canines, central teeth, and lateral teeth, respectively [21].

The mean BH of the anterior maxillary bone was 12.24 ± 2.62 in the present study. The highest BH was related to the canines, lateral teeth, and central teeth, respectively. This result can be explained by the root distance of anterior teeth from anatomical structures, such as the floor of the nasal cavity and maxillary sinus. The average distance between the roots of anterior teeth and these structures was 8.54 mm in central teeth, 9.49 mm in lateral teeth, and 5.39 mm in canines; [22] this result is in line with the findings reported by Dina Ahmed et al. [20].

The maximum thickness of the buccal bone was observed at 4 mm from the apex, and its lowest thickness was observed at the midroot; this result can be justified, as location D is 4 mm away from the apex. Moreover, most teeth were categorized in class 2 or class 3 (in a retroclined position, with the root in the facial third of the bone). Given the position of the root, the thickness of the buccal bone was very low in location B. In a study by Porto, among anterior maxillary teeth, the lowest bone thickness was related to the buccal and palatal bones in the maxillary canines [23]. However, these results are inconsistent with our study due to differences in the measurement criteria.

In the present study, similar to many other studies, the bone around the anterior maxillary teeth was very thin in each location [8,10,18,24,25]. According to the present results, dental class (sagittal root position) had a significant relationship with the type of tooth. Among six anterior teeth evaluated, class 3 was the most common class, and class 7 was the least common one. In a study by Gluckman et al., class 2 was the most common class, while class 5 was the least common one [8].

In the current study, the relationship between the studied parameters and gender was examined. It was found that bone density, RA, and TA had no significant relationships with gender in any of the six anterior teeth. However, variables with a significant relationship with gender (male predilection) were as follows: TRA in tooth 10; CA in tooth 9 and tooth 10; CD in tooth 10, tooth 11, and tooth 6; CL in tooth 11; and BH and PH in tooth 6. In the study by Gluckman et al., there was no significant relationship between the bone height and gender in the central teeth. In canines, BH and PH were higher in men than in women; also, in lateral teeth, PH was higher in men than in women [8].

The greater bone height in men can be attributed to their larger size compared to women. However, in a study by Panjnoush et al., CD and CA showed no significant relationship with gender [26]. The buccal bone thickness at the level of the bone crest was significantly higher in women than in men, and the palatal bone thickness was significantly higher in men than in women in the middle of the root, at the apex, and at 4 mm from the apex.

The relationship between the studied parameters and age was also investigated in this study. Tooth classification, CL, and RA showed no significant relationship with age in any of the six anterior teeth. The TRA and CD had significant relationships with age in all of the anterior teeth. Also, bone density showed a significant relationship with age in tooth 10. The BH had a significant relationship with age in tooth 8, tooth 9, and tooth 10. Moreover, the PH showed a significant relationship with age in tooth 7 and tooth 9. Besides, the CA showed a significant relationship with age in tooth 7 and tooth 10. Finally, TA showed a significant relationship with age in teeth 6, 8, 10, and 11.

Contrary to our findings, Ahmed et al. found no significant relationship between CD and age [20]. Moreover, in the study by Panjnoush et al., the CD and CA were measured at a 1-mm distance from the floor of the nasal cavity at the midpoint of the lateral and maxillary canines [26]. Based on the results, the CA and CD had no significant relationship with age. Since their measurement criteria were different from our study, differences in the results were expected. Contrary to our study, Wang et al. found no significant relationship between TRA and age [17].

Conclusion:

Despite the limitations of this study, including the small sample size, age limitation of patients with six anterior teeth, clinician errors, and racial differences, the results suggested the sensitivity of the anterior maxillary region for implant placement. This high sensitivity was attributed to factors, such as

esthetic considerations, facial position of the root, thin facial bone, low CA, high CD, and greater height of buccal and palatal bones.

Acknowledgment: We thank Oral Health Research Center, Health Research Institute, Babol University of Medical Sciences, Babol, I.R. Iran for supporting the project.

Conflict of Interest: The authors have no conflicts of interest to disclose.

References

- 1- Author, C., Scarfe, W.C., Farman, A.G., Sukovic, P. Clinical applications of cone-beam computed tomography in dental practice. *J Can Dent Assoc.* 2006; 72:75-80.
- 2- Kumar, M., Shanavas, M., Sidappa, A., Kiran, M. Cone beam computed tomography - know its secrets. *Int J Oral Health Dent.* 2015;7:64-68.
- 3- Zhou, Z., Chen, W., Shen, M., Sun, C., Li, J., Chen, N. Cone beam computed tomographic analyses of alveolar bone anatomy at the maxillary anterior region in Chinese adults. *J Biomed Res.* 2014;28:498-505.
- 4- Caiazzo, A., Brugnami, F., Mehra, P. Buccal plate preservation with immediate post-extraction implant placement and provisionalization: preliminary results of a new technique. *Int J Oral Maxillofac Surg.* 2013;42:666-670.
- 5- Gracco, A., Lombardo, L., Mancuso, G., Gravina, V., Siciliani, G. Upper incisor position and bony support in untreated patients as seen on CBCT. *Angle Orthod.* 2009;79:692-702.
- 6- Morad, G., Behnia, H., Motamedian, S.R., Shahab, S., Gholamin, P., Khosraviani, K., Nowzari, H., Khojasteh, A. Thickness of labial alveolar bone overlying healthy maxillary and mandibular anterior teeth. *J Periodontol.* 2011; 83:187-197.
- 7- Jin, S.H. et al. The thickness of alveolar bone at the maxillary canine and premolar teeth in normal occlusion. *J Periodontal Implant Sci.* 2012; 42:173-178.
- 8- Gluckman H, Pontes CC, Du Toit J. Radial plane tooth position and bone wall dimensions in the anterior maxilla: A CBCT classification for immediate implant placement. *J Prosthet Dent.* 2018;120:50- 56.
- 9- Sung C-E, Cochran DL, Cheng W-C, Mau L-P, Huang P-H, Fan W-H, et al. Preoperative assessment of labial bone perforation for virtual immediate implant surgery in the maxillary esthetic zone: a computer simulation study. *J Am Dent Assoc.* 2015;146:80-88.
- 10- Chan H-L, Garaicoa-Pazmino C, Suarez F, Monje A, Benavides E, Oh T-J, et al. Incidence of implant buccal plate fenestration in the esthetic zone: a cone beam computed tomography study. *Int J Oral Maxillofac Imp.* 2014;29:171-177.
- 11- Zaidi Q, Danisa OA, Cheng W. Measurement techniques and utility of Hounsfield unit values for assessment of bone quality prior to spinal instrumentation: a review of current literature. *Spine.* 2019;44:239-244.

- 12-Jung Y-H, Cho B-H, Hwang JJ. Analysis of the root position of the maxillary incisors in the alveolar bone using cone-beam computed tomography. *Imaging Sci Dent*. 2017;47:181-188.
- 13-Misch C. *Dental implant prosthetics*, 2nd ed., Mosby , Philadelphia ,2014 , P: 273.
- 14-Cavézian R, Pasquet G. Imagerie cone beam et implants . *Rev Stomatol Chir Maxillofac Chir Oral*. 2012;113:245-258.
- 15-Hao Y, Zhao W, Wang Y, Yu J, Zou D. Assessments of jaw bone density at implant sites using 3D cone-beam computed tomography. *Eur Rev Med Pharmacol Sci* . 2014; 18: 1398- 1403.
- 16-Nasrollahi N, Bijani A, Haghani S. Evaluation of the buccolingual position of maxillary and mandibular anterior teeth by cone-beam computed tomography (CBCT) . *Casp J Dent Res*. 2020;9:42-48.
- 17-Wang H-m, Shen J-w, Yu M-f, Chen X-y, Jiang Q-h, He F-m. Analysis of facial bone wall dimensions and sagittal root position in the maxillary esthetic zone: a retrospective study using cone beam computed tomography. *Int J oral maxillofac implants*. 2014; 29:1123-1129.
- 18-Lee S-L, Kim H-J, Son M-K, Chung C-H. Anthropometric analysis of maxillary anterior buccal bone of Korean adults using cone-beam CT. *J Adv Prosthodont* . 2010 ;2 : 92-96.
- 19 - Ma, Erin Shane Wan, "Differential CBCT Analysis of Collum Angles in Maxillary and Mandibular Anterior Teeth in Patients with Different Malocclusions" (2016). UNLV Theses, Dissertations, Professional Papers, and Capstones. 2880. <http://dx.doi.org/10.34917/10083174>.
- 20-Ahmed DF, El Beshlawy DM. Assessment of anterior maxillary alveolar bone dimensions and morphology for immediate implant planning: A retrospective study using Planmeca Promax CBCT unit. *Egypt Dent J*. 2019 ; 65: 1267-1278.
- 21-Fantozzi G, Leuter C, Bernardi S, Nardi GM, Continenza MA. Analysis of the root morphology of European anterior teeth .*Arch Ital Anat Embriol*. 2013 ;118:78-91.
- 22-Ducommun J, Bornstein MM, Wong MCM, von Arx T. Distances of root apices to adjacent anatomical structures in the anterior maxilla: an analysis using cone beam computed tomography . *Clin Oral Investig*. 2019; 23 :2253-2263.
- 23-Porto OCL, SILVA BSdF, Silva JA, ESTRELA CRdA, ALENCAR AHGd, Bueno MdR, et al. CBCT assessment of bone thickness in maxillary and mandibular teeth: an anatomic study. *J Appl Oral Sci* . 2020; 28:9-21.
- 24-Januário AL, Duarte WR, Barriviera M, Mesti JC, Araújo MG, Lindhe J. Dimension of the facial bone wall in the anterior maxilla: a cone-beam computed tomography study. *Clin Oral Implants Res* . 2011; 22:1168-1171.
- 25-Joseph Gakonyo B, Implantology P, Mohamedali AJ, Mungure EK. Cone beam computed tomography assessment of the buccal bone thickness in anterior maxillary teeth: relevance to immediate implant placement .*Int J Oral Maxillofac Implants* . 2018;33: 880- 887.
- 26-Panjnoush M, Eil N, Kheirandish Y, Mofidi N, Shamshiri AR. Evaluation of the concavity depth and inclination in jaws using CBCT. *Caspian J Dent Res* . 2016;5:17-23.

Tables Concavity Angle Tooth	overall	men	women	P value*
9	132/02±22/52 a	136/15±19/41 a	128/62±24/36 a	0/005
10	145/67±9/33 b	149/96±200/17 b	144/61±7/76 b	0/028
11	153/29±12/25 c	154/06±16/52 c	152/67±7/07 c	0/211
8	140/38±19/82 b	142/79±18/90 a	138/40±20/42 d	0/221
7	144/60±7/78 b	145/89±9/03 b	143/55±8/47 d	0/568
6	154/06±7/33 c	154/94±7/90 c	153/34±6/78 c	0/519
P value**	<0/001	<0/001	<0/001	-

Table 1: Evaluation of Concavity Angle(CA) of six anterior maxillary teeth by sex

-Different lower letters in each column indicate a significant difference for BH between different teeth in each position at the level of $\alpha = 0.05$. and different upper letters in each column indicate a significant difference for PH between different teeth in each position at the level of $\alpha = 0.05$.

*Using Independent T test.

** Using one way ANOVA and in case of significant multiple comparisons using Tukey test

Concavity Depth	overall	men	women	P value*
Tooth				
9	2/64±1/73 a	2/63±2/20 a	2/65±1/24 a	0/135
10	2/89±2/07 a	3/18±2/95 a	2/65±0/79 b	0/003
11	2/51±1/98 a	2/75±2/85 a	2/32±0/70 a	0/004
8	2/24±1/78 b	2/27±2/13 a	2/21±1/43 a	0/282
7	2/92±1/49 a	3/07±1/90 a	2/81±1/04 b	0/111
6	2/41±1/51 b	2/57±2/11 a	2/27±0/70 a	0/026
P value**	<0/001	<0/001	<0/001	-

TableI 2:Evaluation of Concavity Depth(CD) of six anterior maxillary teeth by sex

-Different lower letters in each column indicate a significant difference for BH between

different teeth in each position at the level of $\alpha = 0.05$.and different upper letters in each column indicate a significant difference for PH between different teeth in each position at the level of α

= 0.05.

*Using Independent T test.

** Using one way ANOVA and in case of significant multiple comparisons using Tukey test

Concavity Location Tooth	overall	men	women	P value*
9	15/27 ₊₂ /90 a	15/77 ₊₃ /39	14/87 ₊₂ /35 a	0/077
10	14/34 ₊₂ /33 b	14/74 ₊₂ /82	14/01 ₊₁ /78 b	0/112
11	17/44 ₊₃ /14 c	18/29 ₊₃ /82	16/74 ₊₂ /22 c	0/040
8	15/45 ₊₂ /86 a	16/11 ₊₃ /23	14/91 ₊₂ /39 a	0/222
7	14/47 ₊₂ /55 b	15 ₊₂ /89	14/03 ₊₂ /16 a	0/149
6	17/53 ₊₃ /14 c	18/49 ₊₃ /58	16/75 ₊₂ /48 c	0/185
P value**	<0/001	0/120	<0/001	-

Table 3 :Evaluation of Concavity Location(CL) of six anterior maxillary teeth by sex

-Different lower letters in each column indicate a significant difference for BH between different teeth in each position at the level of $\alpha = 0.05$.and different upper letters in each column indicate a significant difference for PH between different teeth in each position at the level of $\alpha = 0.05$.

*Using Independent T test.

** Using one way ANOVA and in case of significant multiple comparisons using Tukey test

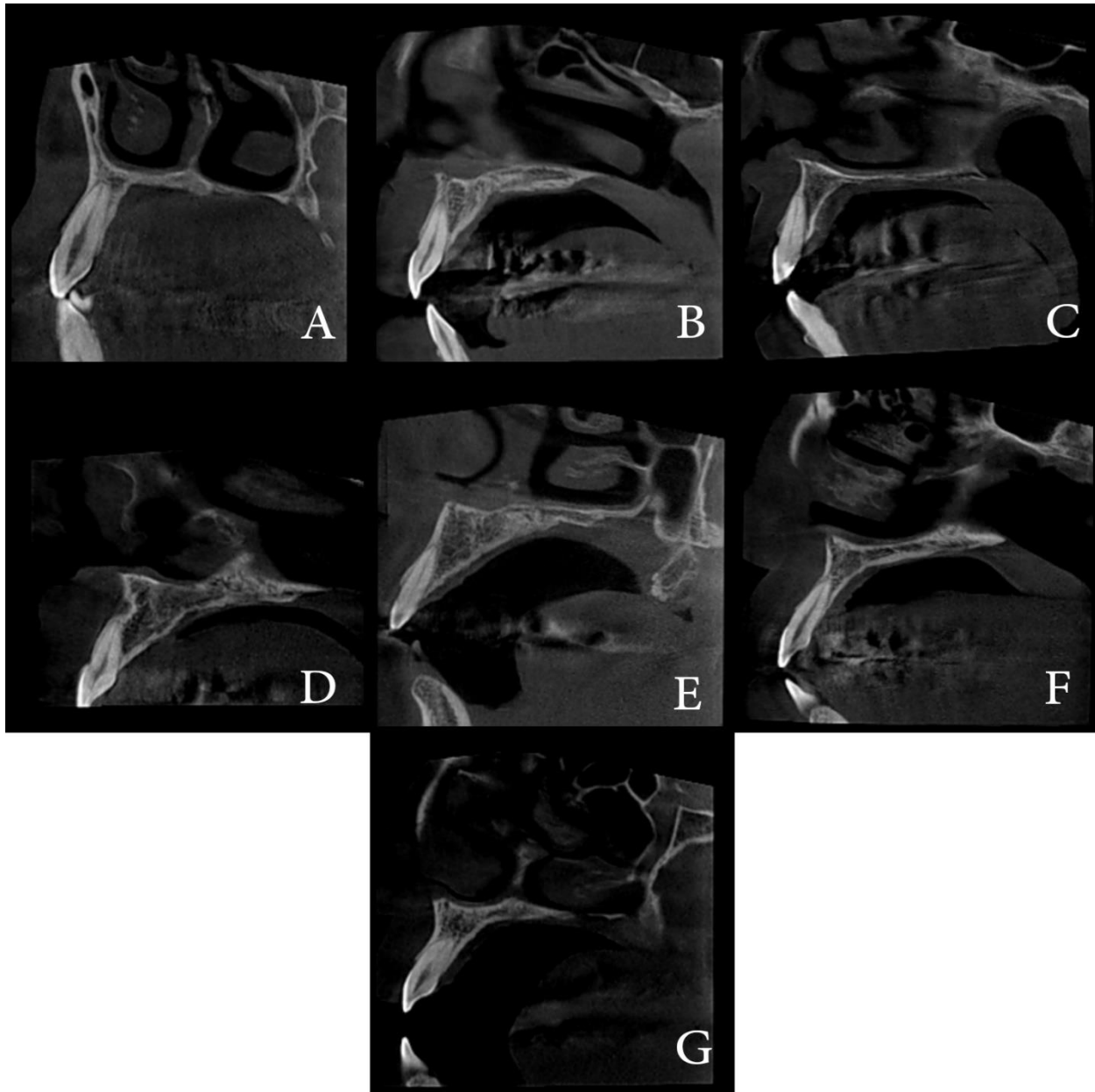
Figures :

Figure 1 :Classification of tooth inclination and sagittal root position

ClassI: The most apical point of the tooth is in the middle- one third of the bone(A)

,ClassII :Normal inclination/ The most apical point of the tooth is in the facial one-third of the bone(B)

Class III:Retrocline/The most apical point of the tooth is in the facial one-third of the bone(C)

ClassIV:The most apical point of the tooth is out of the socket and in the facial one-third of the bone(D).

ClassV:Procline/With thick palatal bone and thin facial bone/Facial bone thickness is increasing near the apex(E)

ClassVI:Thin palatal and facial bone (F)

ClassVII: The most apical point of the tooth is in the palatal one-third of the bone(G)

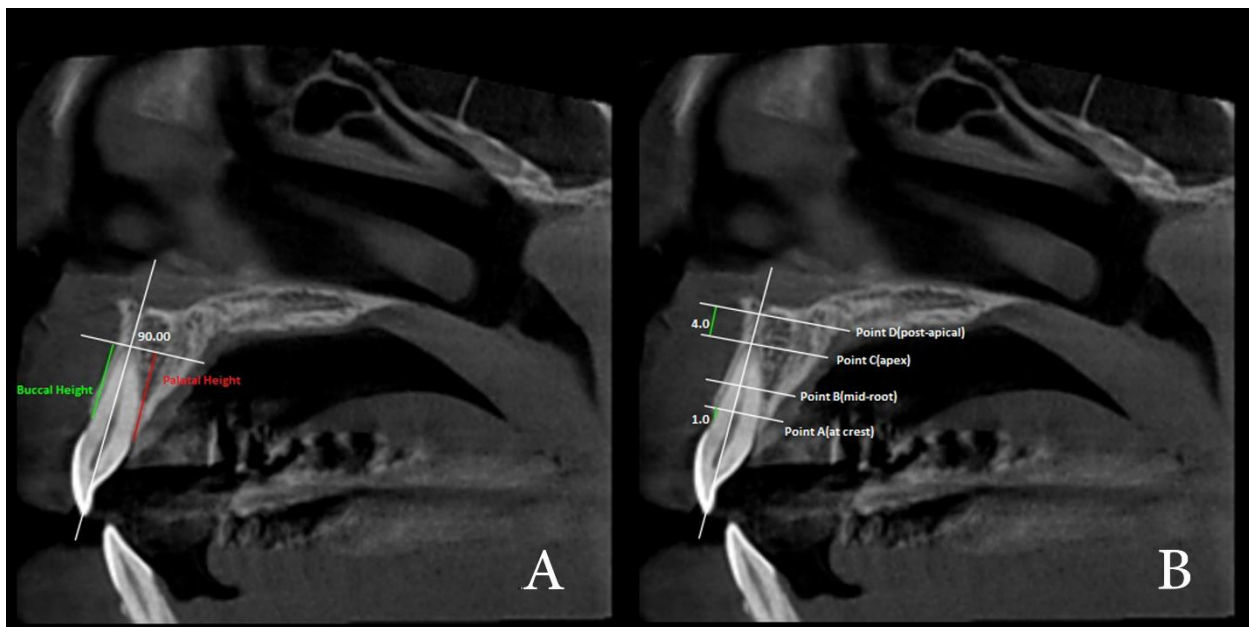


Figure 2: Reference lines for measuring bone height (A) and bone thickness (B)

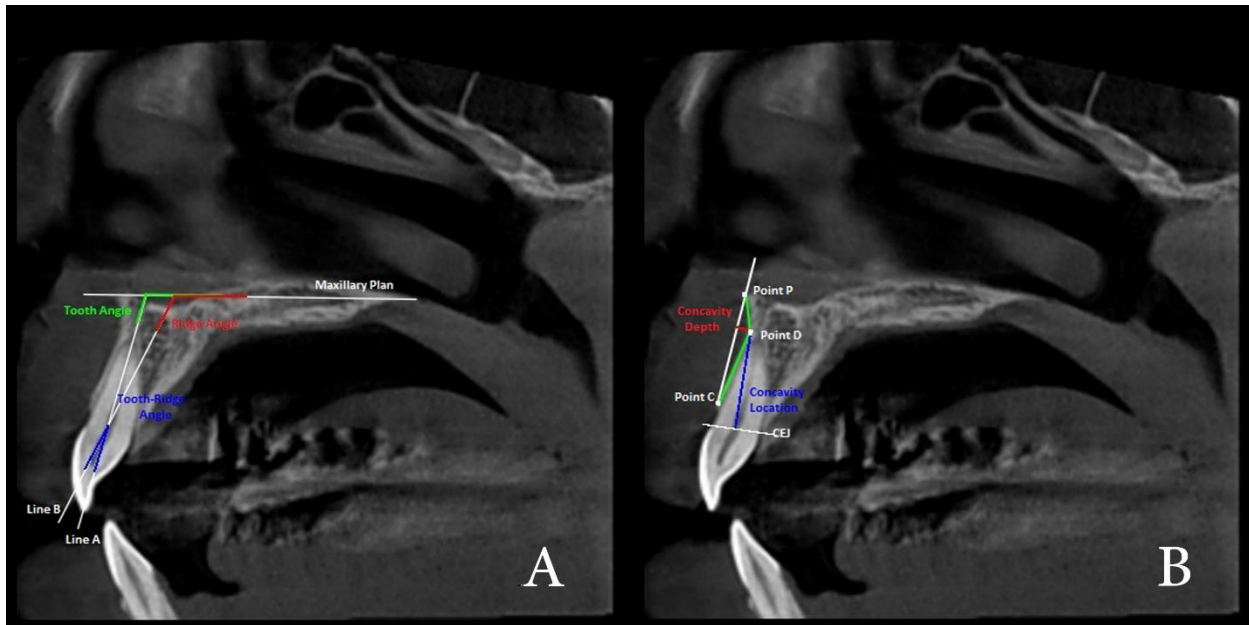


Figure 3 :Radiographic picture for measurements of morphologic features of maxillary anterior esthetic zone before implant placement. Tooth angulation (TA) and tooth-ridge angle (TRA) (fig.3A) ,c oncavity depth (CD) ,concavity angulation (CA) ,concavity location (CL) (fig. 3B) .

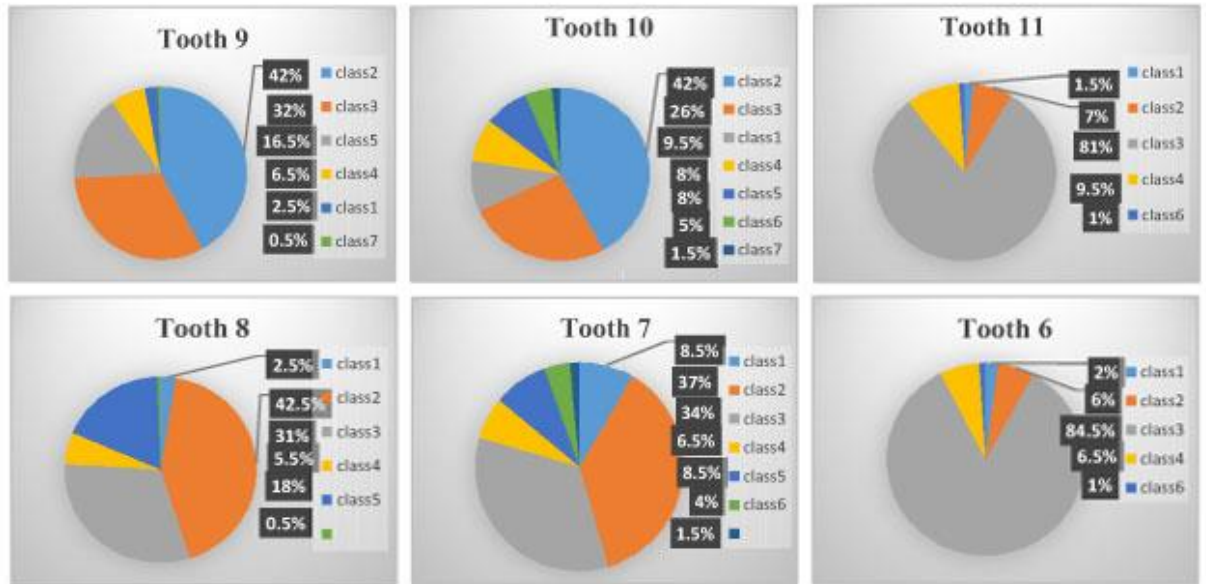


Figure 4 : Distribution of tooth classification based on the inclination and sagittal root position.