

How to Cite:

Rekha, C., Srinivasa, K., Devi, P. K., & Shashikumara, S. (2022). Ultrasound as a relevant primary mode of investigation in the non-traumatic acute abdomen in adults and its correlation with treatment. *International Journal of Health Sciences*, 6(S10), 254–266. Retrieved from <https://sciencescholar.us/journal/index.php/ijhs/article/view/13441>

Ultrasound as a relevant primary mode of investigation in the non-traumatic acute abdomen in adults and its correlation with treatment

Rekha C.

Department of Radio-diagnosis, Chamarajanagar Institute of Medical Sciences, Chamarajanagar-571313, Karnataka, India

Srinivasa K.

Department of Pharmacology, Chamarajanagar Institute of Medical Sciences, Chamarajanagar-571313, Karnataka, India

Poolan Devi K.

Department of Anesthesia, Mysore Medical College and Research centre, Mysore-57001, Karnataka, India

Shashikumara

Department of Pharmacology, Chamarajanagar Institute of Medical Sciences, Chamarajanagar-571313, Karnataka, India

Abstract--Objective: The purpose of this study was to determine the spectrum of abdominal disease as well as the diagnostic efficacy of ultrasound in non-traumatic acute abdominal patients at Chamarajanagar Institute of Medical Sciences (CIMS) and Chamarajanagar District Hospital. Materials and Methods: Retrospective study of 100 patients aged 14 and up who presented to the emergency department with non-traumatic acute abdomen and were admitted as inpatients and referred to the Radiology Department at CIMS, Chamarajanagar. A real-time ultrasound scanner-Alpha Prosound 6 from Aloka Technologies [(Curvilinear probe (frequency 1-15 MHz) (linear probe (frequency 1-15 MHz))] with Doppler capabilities was used to evaluate intra-abdominal organs, and the results were compared to clinical and surgical findings in those cases that were operated. The maximum age group in the study of 100 patients was 31-40 years (24 percent), and the mean age group was 57.84. In this study, the most common cause of acute abdomen in adults was renal colic (calculi), which was followed by appendicitis, appendicular mass, biliary disease, hydronephrosis, and others. Conclusion: Sonography

should be used as the primary mode of diagnosis for patients with a history of acute non-traumatic abdomen. This is especially important in areas where a higher level of investigation is not available. Clinical findings, laboratory values, and Contrast-Enhanced CT may be used to support non-conclusive cases.

Keywords--acute abdomen, accuracy, non-traumatic, renal disease, sonography.

Introduction

Acute abdomen is defined as a clinical syndrome characterized by acute abdominal pain of sudden onset [1]. Acute abdomen is the primary term for the uncertain emergency in the abdominal cavity [2]. Patients with acute abdomen are one of the major surgical emergency group[1]. Of all patients presenting to the Emergency Department, 4-5 percent have acute abdominal pain as reported in the *rsna* journal [3]. It can range from benign to surgical emergency [4]. Medical history and physical exam are the first diagnostic steps [3]. Identifying surgical patients is crucial for timely management [1]. Only one-quarter of acute abdomen patients need surgery [4]. Acute abdomen can be caused by a number of diseases [1]. The disease spectrum in this patient group is broad and varies by demographic pattern [3]. It is also critical to consider specific populations, such as the elderly or oncological patients, who may exhibit unusual illness symptoms. Because of these important implications, acute abdomen is divided into three categories: acute abdomen male, acute abdomen female, and acute abdomen children. [4].

The low clinical accuracy emphasises the importance of imaging in diagnosing the acute abdomen due to the significant overlap between symptoms and signs [1]. Following clinical evaluation, imaging's added value, particularly its impact on diagnostic accuracy, certainty, and patient treatment, is critical. [3] Investigative radiological imaging techniques include plain films, contrast studies, ultrasound, computed tomography (CT), and magnetic resonance imaging (MRI) [1]. Ultrasonography remains the primary imaging technique in the majority of cases, especially in young and female patients, for whom radiation exposure limits should be mandated [4]. Additional ultrasound benefits include the following: Ultrasonography is inexpensive, non-invasive, reliable, simple to perform, has no contraindications, and can be repeated as needed [5]. Ultrasound is widely accessible and widely available. [3]

It is a real-time dynamic examination that correlates to the point of maximum tenderness and can reveal the presence or absence of peristalsis [3]. Because ultrasound units are smaller and more portable, they are widely used in a variety of medical settings [5,6]. Plain radiographs continue to be an important initial study in the evaluation of patients with acute abdomen. In conditions such as hollow viscous perforation and intestinal obstruction, the abdominal film is of the utmost importance [1]. CT is useful when ultrasound is inconclusive and when there is a discrepancy between clinical signs and negative ultrasound imaging [4].

Materials and Methodology

Design and Settings

We conducted a retrospective study of one hundred adult patients ranging in age from more than 14 years to 80 years of both sexes who presented to the emergency department, outpatient, and inpatient departments at Chamarajanagar Institute of Medical Sciences (CIMS) and were referred for sonography between June 2017 and June 2018. The Institutional ethics committee granted IEC approval with reference number CIM/IEC-01/20(A)/2019. Cases were tracked using case records, laboratory values, imaging reports, surgical follow-up, computed tomography, and, if necessary, referral to a higher centre. Sonography was performed on patients using an Aloka Technologies Alpha Prosound 6 real-time ultrasound scanner machine. All patients were examined using a Curvilinear probe (frequency 1-15 MHz), a Linear probe (frequency 1-15 MHz), and Doppler as needed. The sample size was determined using previous literature [4,7]. The specific causes of non-traumatic acute abdominal (NTA) pain were estimated to be 8%, with a 95% confidence interval and 5% absolute accuracy. The sample size of 100 was determined using the formula $n = z^2 \frac{PQ}{L^2}$, where $z = 1.96$ at the 95 percent confidence interval and $p =$ estimated 0 (5 %). Taking into account the additional 10% for incomplete records (16), a total sample size of 95% was considered for the study.

Inclusion criteria

- Adult patients aged more than fourteen (>14) years to eighty years (80 years).
- Patients of both sexes.
- Patients presenting with associated symptoms that might be related to abdominal conditions.

Exclusion criteria

- Patients with a history of trauma of any kind.
- Patients with similar complaints were diagnosed and treated previously for the same.
- Female patients with the once diagnosed gynecological disease and pregnancy.

The graded compression procedure is the most commonly used Ultrasound technique for examining patients with acute abdominal pain. Interposing fat and bowel can be displaced or compressed using gradual compression to reveal underlying structures with this technique. [3]

Diagnosis

Clinical examination

Suspected clinical diagnosis

Relevant laboratory values and other supplementary investigations

Statistical analysis

Spreadsheet formulas 16.0 for Windows was used for statistical analysis. The descriptive data is expressed as a percentage.

Results and Discussion

Results of the present study can be tabulated as follows, considering the different parameters. Out of a total of one hundred adult patients with a history of non-traumatic acute abdomen enrolled in the present study, Males were 70 (70%), and females were 30 (30%). The most common age group was 31 -40 years, which comprised 24 patients males -19 (27.15%) and females 5 (16.67%). The mean age of presentation was 57.84 % [Table 1]. All patients had pain in the abdomen, followed by vomiting, pain in either of the flanks, pain in the right iliac fossa, pain in the right hypochondrium, dysuria, so on, and so forth. Many patients had multiple symptoms on presentations. [Table 2] 97 patients were sonographically positive, whereas 03 were sonographically negative. The majority of the cases were in the age group 31 -40 years (21), of which renal colic/ calculi was common (13). However, appendicular mass, appendicitis, gall bladder disease, and renal disease were found more commonly on imaging after follow-through of the clinical records. [Table 3& Table 4] Results were statistically computed concerning sensitivity, the specificity of sonographic diagnosis with that of clinical diagnosis, other laboratory values, and confirmation by computed Tomography (CECT) as required. [Table 5]

Table 1
Age wise and sex wise distribution of patients

Age of the patient	Males	Females	Total
>14 - 20	06 (8.58%)	02 (6.67%)	08 (8%)
21 - 30	15 (21.50%)	07 (23.34%)	22 (22%)
31 -40	19 (27.15%)	05 (16.67%)	24 (24%)
41 -50	12 (17.15%)	09 (30.0%)	21 (21%)
51 -60	11 (15.71%)	04 (13.33%)	15 (15%)
61 -70	06 (8.58%)	03 (10.0%)	09 (9%)
71 -80	01 (1.43%)	00	01 (1%)
Total	70 (70%)	30 (30%)	100

Table 2
Data showing various symptoms of patients

Symptoms	Number of patients	Percentage
Pain in abdomen	96	96%
vomiting	63	36%
Pain in flank(R/L)	17	9.71%
Pain in right iliac fossa	08	4.57%
Low backache	07	04%

Dysuria	06	3.42%
Pain in right hypochondrium	05	2.85%
Jaundice	04	2.28%
Diarrhoea	04	2.28%
Fever	03	1.71%
Haematuria	01	0.57%
Pain in suprapubic region	01	0.57%

Table 3
Sonographically positive and negative patient data

	Sonographically positive		Sonographically negative	
Males	70	(72.16%)	02	(66.66%)
females	27	(27.83%)	01	(33.33%)
Total	97	(97%)	03	(03 %)

Table 4
Age-wise distribution of sonographically diagnosed disease

USG diagnosis	>14-20y	21-30y	31-40y	41-50y	51-60y	61-70y	>70-80y	Total
Appendicitis	05 (62.5%)	06 (31.57%)	01 (4.76%)	--	01 (8.33%)	--	--	13 (14.77%)
Renal calculi	--	06 (31.57%)	13 (61.95)	12 (63.15%)	09 (75%)	04 (44.44%)	--	44 (50.0%)
Gall bladder disease (Cholelithiasis)	--	--	02 (9.52%)	03 (15.78%)	01 (8.3%)	03 (33.3%)	--	09 (10.22%)
Appendicular mass	01 (12.57%)	04 (21.05%)	--	01 (5.26%)	01 (8.3%)	--	--	07 (7.95%)
Hydronephrosis	--	03 (15.78%)	05 (23.80%)	03 (15.78%)	--	01 (11.55%)	--	12 (13.63%)
Normal	02 (25%)	--	--	--	--	01 (11.11%)	--	03 (3.40%)
Total	08	19	21	19	12	09	--	88

Table 5
Data showing number of Patients confirmed by computed tomography (CECT)

Males	10
Females	05
Total	15

Table 6
Data showing patients who were subjected to immediate surgery and treated conservatively followed by surgery

	Immediate Surgery		Treated conservatively followed by surgery	
	No. of Patients	%	No. of Patients	%
Males	17	80.95	04	66.66
Females	04	19.04	02	33.33
Total	21	100	06	100

Table 7
Distribution of correlation of clinical and sonographically diagnosed cases

Clinical diagnosis	No. of patients	Percentage
First clinical diagnosis	55	(56.70%)
Second clinical diagnosis	05	(5.15%)
Not matched with clinical diagnosis	26	(26.80%)
Clinically not diagnosed	03	(03%)
Sonographically normal	03	(03%)

Table 8
Data showing sensitivity and specificity of commonly diagnosed sonographic conditions

	Sensitivity	Specificity
Appendicular mass	100%	97.8%
Appendicitis	68.42%	98.7%
Gall bladder disease	85.7%	96.7%
Renal calculi	74.5%	78.9%
Hydronephrosis	100%	95.6%

Table 9
Table showing number of cases referred to higher centre for lithotripsy

Males	04
Females	03
Total	07

Table 10
Number of cases treated conservatively

Males	42
Females	11
Total	53

One hundred adult patients with a history of the non-traumatic acute abdomen were retrospectively reviewed in the present study concerning - Clinical diagnosis, Laboratory findings, and imaging correlation on Ultrasound and treatment (radiologic workup). The data was collected as per the clinical case sheet and statistically analyzed. (Table 1-10). All patients were examined by real-time ultrasonography machine –Alpha Prosound 6 of Aloka Technologies in the Department of Radiodiagnosis, Chamarajanagar Institute of Medical Sciences(CIMS) as described. This is similar to the study conducted by Andrews et al. concerning the number of patients (100), [Table 3] the survey methodology, and results [8]. Also, a similar study was conducted by Gathwal CK et al. in which a total of 140 patients were involved with inclusion and exclusion criteria similar to that of present study [9]. [Table 11]

In the present study, Abdominal pain (96%) was the main symptom, followed by vomiting (63%), fever 03(1.7%), diarrhea 04 (2.28%). This is similar to the study by Gathwal CK et al. in which presenting symptom was abdominal pain (100%), followed by vomiting 24 (17.14%), fever 04 (2.9%), diarrhea 01(0.7%). The most common diagnosis in the present study was renal disease (renal calculi) 44 (50%), followed by acute appendicitis 13 (14.77%), hydronephrosis 12 (13.33%), Gall bladder disease 9(10.22%), appendicular mass 7 (7.95%) respectively (Table 2).However, Gathwal CK et al. showed acute appendicitis 32(22.86%) as the most common diagnosis, followed by renal disease, acute cholecystitis. Probably this could be due to epidemic and demographic influence [9]. [Table 11]

Table 11
Comparison of results of the present study with that of Garhwal et al. can be shown as follows

	Present study (out of 100)	Gathwal et.al study (out of 140)
Conservative treatment	53 (54.63%)	76 (54.29%)
Conservative treatment followed by surgery	13 (13.40%)	11(7.86%)
Emergency surgery	21(21.65%)	53(37.86%)

The present study shows similar results shown concerning the number of patients conservatively treated, those treated conservatively and followed by surgery. [Table 6] This group included cases of appendicular mass and renal colic with hydronephrosis. Diagnosed cases on sonography were 97 (sonographically positive). Another three (03) patients showed no positive findings on ultrasound. [Table 3]. *Andrews's et al.* in their similar study, divided patients who underwent Ultrasound as the following groups [8]. [Table 12]

- Group A: A sonographic examination was used to make the diagnosis, which was not clinically expected.
- Group B: Ultrasonography confirmed the first clinically suspected diagnosis.
- Group C: Ultrasonography confirmed that the second or third differential diagnosis was correct.
- Group D: Ultrasonography had no impact on the diagnosis.

Table 12

This data can be compared to two other similar studies in tabular format as follows

Group	Andrews et al. study (100 patients)	Caterino's study(301 patients)	The present study(100 patients)
Group A	20 patients (20%)	38patients (12.7%)	24patients (24.74%)
Group B	60 patients (60%)	161 patients (53.3%)	65 patients (67.01%)
Group C	18 patients (18%)	23 patients (7.7%)	07 (7.21%)
Group D	2 patients (2%)	77 patients (25.5%)	03(3%)

In the present study, ultrasonography matched with the first clinically suspected diagnosis in 65 (67.01%) patients, second and third differential clinical diagnosis in 07 (7.21%) patients, comparable to the data as shown in table 16 above, which is similar to study by *Andrews et al.* (60%) and *Caterino's study* (53.3%). [Table 12]. Some of the essential diagnostic criteria were considered as follows with ultrasound findings in the study population.

Appendicitis

Imaging is needed only in equivocal cases or when the clinical diagnosis is in doubt [1].Ultrasound is the screening modality of choice for initial evaluation in suspected appendicitis [1]The aim of performing sonography in patients with suspected cases of acute appendicitis would be to come to a conclusion about probable diagnosis and subject them to surgery immediately as required. Also to look for other causes of pain and treat accordingly. [1,2]. [Image 1 & Image 2]

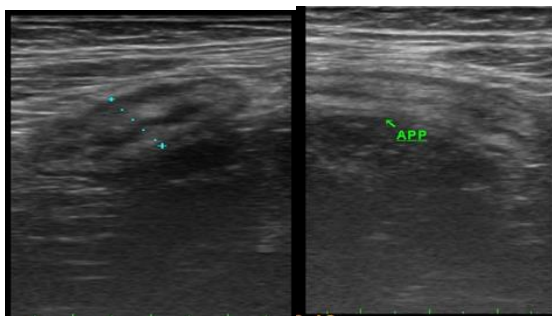


Image 1

Image 2

Acute appendicitis (appendix measures 11mm)

Many cases of appendicitis show direct visualisation of a concentric layered, blind-ended, Aperistaltic, non-compressible tube with gut signature arising from the base of the cecum with a diameter greater than 6mm. Jeffrey and colleagues concluded that the size of an appendix could distinguish between normal and acutely inflamed people [2]. Julien Puylaert described the benefits of graded compression in 1986 [2]. Graded compression sonography with a high-frequency linear transducer is a highly accurate technique with a sensitivity of 80-93 percent and a specificity of 95-97 percent for the diagnosis of acute appendicitis

[Table 8] [1]. The current study found similar sensitivity (100%) and specificity (97.8%) values for appendicitis. [Table 8] A false positive sonogram can occur in Chrons disease, caecal diverticulitis, and salpingitis [1]. False negative laparotomy is more common in young females with pelvic inflammatory disease and ovarian torsion [1].

Acute cholecystitis

Sonography is the most often used imaging technique for assessing the gallbladder [1]. Gall stones are the culprit in more than 90% of cases [2]. Patients appear with right quadrant discomfort, fever, leucocytosis, and elevated serum bilirubin [2]. For individuals clinically suspected of having acute cholecystitis, ultrasound should be regarded the primary imaging tool [7]. [Image 3]

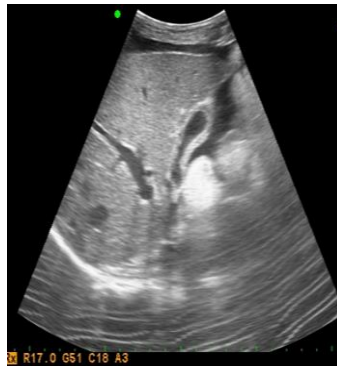

Image 3. Acute cholecystitis

Sonographic findings include gall bladder wall thickening (>3mm), lumen distension (>4cm), gall stones, pericholecystic fluid accumulation, and a positive sonographic Murphy's sign. The following criteria are used to diagnose acute cholecystitis: [5] - local evidence of inflammation (Murphy's sign), systemic sign of inflammation (elevated leucocytes). [Image 4]

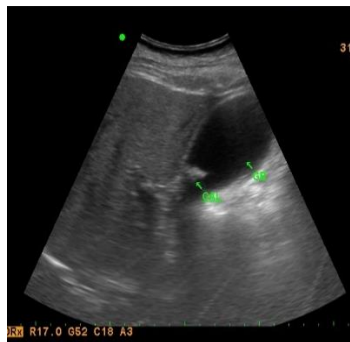

Figure 4. Gall bladder calculi (cholelithiasis)

Renal disease: Ureter pelvic junction (PUJ) blockage is a common finding in renal illness [2]. Sonography reveals pelvicaliectasia to the level of the PUJ, as well as significant ballooning of the renal pelvis [2]. [Image 5]

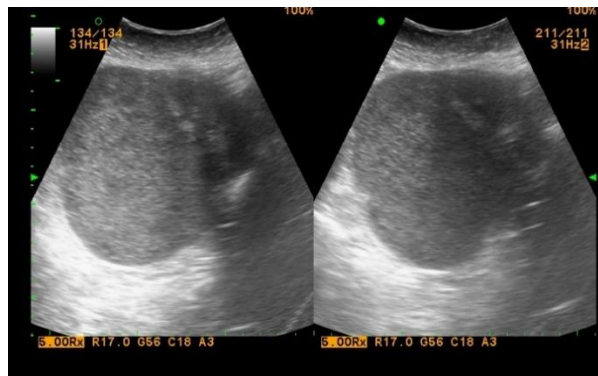

Image 5. Right adnexal mass in a female

Cystitis

is more prevalent in women and involves rectal flora colonisation of the urethra, the most common of which is *E. coli* [2]. [Image 6& Image 7]

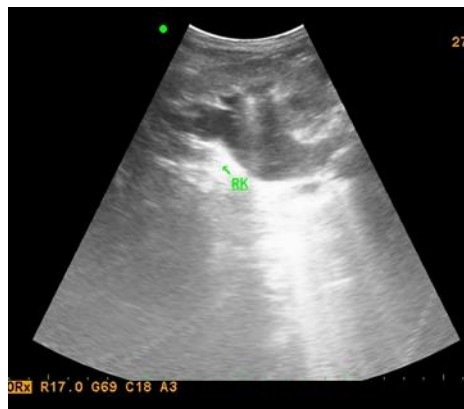

Image 6. Right renal calculus with hydronephrosis

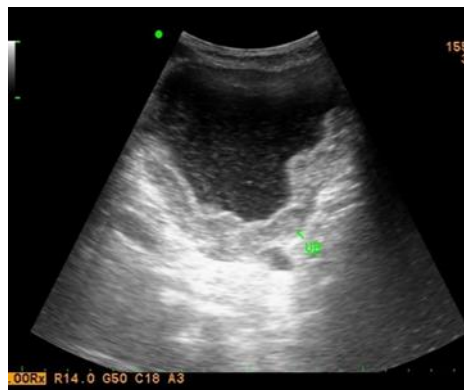

Image 7. Thickened wall of the urinary bladder with features of cystitis

Renal stones

Renal stones are common, affecting 12% of the population at some point in their lives [2]. Calcium oxalate (60-80 percent) is the most frequent form of stone [2]. Non-obstructive caliceal stones are usually asymptomatic, though patients may have haematuria or pain [2]. Clinical signs and symptoms of flank discomfort and infection arise when a stone shifts and creates infundibular or PUJ obstruction [2]. If a stone enters the ureter, the vast majority will lodge at the VUJ, the ureter's narrowest diameter of 1-5mm [2]. An echogenic centre with distal acute acoustic shadowing within the ureteric lumen will be diagnosed as a stone [2]. Approximately 80% of stones smaller than 5mm will pass naturally [2]. Imaging is used to confirm the diagnosis, identify stone size, position, and number, and check for related problems in patients with acute renal colic [2].

Patients with ureteral calculi more than 5mm in diameter are more likely to suffer hydronephrosis [11]. 10 mm stones are likely to be managed cautiously [11]. Sonography should be used first, rather than CT, for probable diagnosis and follow-up due to the lack of ionising radiation and reduced cost. If sonography is inconclusive, CT should be used [2]. Bladder calculi (vesical calculi) occurs most commonly due to either migration from the kidney or urinary stasis in the bladder [2]. Bladder calculi may be asymptomatic [2]. If symptomatic, patients will complain of pain in the suprapubic region with or without hematuria [2]. Other non-traumatic causes of acute abdomen in adults include perforation, intestinal blockage, acute pancreatitis, Mesenteric ischemia, diverticulitis, vascular reasons, and female pelvic inflammatory disorders [1]. Plain radiographs continue to be an important study in the evaluation of a patient with an acute abdomen [1]. Erect abdominal films are particularly useful in cases with hollow viscus perforation and intestinal blockage [1].

Conclusion

The most prevalent age group among the 100 patients in the current study was 31-40 years, with 24 patients males -19 (27.15 %) and females 5 (16.67 %). The average presentation age was 57.84 percent. The most prevalent symptom reported by patients in our study was abdominal discomfort (96%), followed by vomiting (36%), diarrhoea (2.28%), and fever (1%). (1.71%). Gathwal et al. found similar findings with abdominal discomfort (100%) and vomiting (36%), respectively [9]. Ultrasonography was able to diagnose 97 instances (97%), with 65 patients (67.01 percent) matching with the first clinical diagnosis and 07 (7.21 percent) matching with the second tentative clinical diagnosis. Three patients had the third clinical diagnostic. [Table 7]

Renal disease (renal colic/calculi) was the most common diagnosis in this study, followed by appendicitis, gall bladder disease, and appendicular tumor. Many similar investigations, however, have revealed that appendicitis is the most common diagnosis. This disparity could be explained by demographic factors. The overall diagnosis accuracy of ultrasonography in the current study was 74.22 %, which was comparable to Andrews et al which revealed an overall diagnostic accuracy of 78 percent [6]. [Table 12]. The current study found that appendicitis has a sensitivity of 68.42 percent and a specificity of 98.7 %. This is consistent

with earlier studies that suggest appendicitis has a high sensitivity and specificity. In the current investigation, ultrasound also demonstrated significant sensitivity and specificity for the diagnosis of several illnesses such as renal disease, hydronephrosis, and gall bladder disease. [Table 8]

Limitations of the study

Small sample size and study conducted in a single institution may be the main limitations of the current investigation. Because there are often inadequate standards in reports, it is common for imaging accuracy in patients with acute abdominal pain to not be reported in terms of well-known metrics like sensitivity, specificity, and predictive values. A diagnostic workup has produced favorable findings or outcomes if the treating physician deems a certain imaging examination to be helpful or diagnostic.

Acknowledgments

My sincere acknowledgment to Chamarajanagar Institute of Medical Sciences (CIMS), Dean and Head of the institution, Department of surgery, and staff departments. I also acknowledge the Department of Radiodiagnosis staff and all others who have been directly or otherwise involved in this project. I also acknowledge the patients who have been retrospectively involved in the study, my family members for their kind co-operation.

Conflict of Interest

There is no conflict of interest.

References

1. Adam, A., Dixon, A.K., Gillard, J.H., Schaefer-Prokop, C., Grainger, R.G., and Allison, D.J. (2014). *Grainger & Allison's Diagnostic Radiology*. Elsevier Health Sciences, Edinburgh, UK
2. Alexander RJ, Lee-Elliott C, Nash GF. Magnetic resonance imaging and the acute abdomen. *Br J Surg*. 2009 ;96(1):119.
3. Andrews MA, Patel NB, Jadav J, Patel NJ, Leuva HL, Shah RC. Role of abdominal Ultrasonography in diagnosis of acute abdomen. *Int J. Med Res Rev*. 2015; 3(3):313-316.
4. Carol M. Rumack, Stephanie R. Wilson, J. William Charboneau. (2017). *Diagnostic Ultrasound, 2-Volume Set*. Canada: Elsevier Canada.
5. Dubuisson V, Voiglio EJ, Grenier N, Le Bras Y, Thoma M, Launay-Savary MV. Imaging of non-traumatic abdominal emergencies in adults. *J Visc Surg*. 2015;152:57-64.
6. Julian B. C. M. Puylear, Friso M. Vander Zant, Arie M. Rijke. Sonography and the Acute Abdomen: Practical Considerations. *AJR* 1997; 168:179-186.
7. Khan MAB, Abu-Zidan FM. Point-of-care ultrasound for the acute abdomen in the primary health care. *Turk J Emerg Med*. 2020 Jan 28;20(1):1-11. doi: 10.4103/2452-2473.276384.

8. Puylaert JB, van der Zant FM, Rijke AM. Sonography and the acute abdomen: practical considerations. *AJR Am J Roentgenol.* 1997;168(1):179-86.
9. Telfer S, Fenyö G, Holt PR, de Dombal FT. Acute abdominal pain in patients over 50 years of age. *Scand J Gastroenterol Suppl.* 1988;144:47-50.
10. van Randen A, Laméris W, van Es HW, van Heesewijk HP, van Ramshorst B, Ten Hove W, Bouma WH, van Leeuwen MS, van Keulen EM, Bossuyt PM, Stoker J, Boermeester MA; OPTIMA Study Group. A comparison of the accuracy of ultrasound and computed tomography in common diagnoses causing acute abdominal pain. *Eur Radiol.* 2011 Jul;21(7):1535-45.