

How to Cite:

Al-aroomy, L. A., Alwadeai, M. S., Saleh, H. O., & Othman, A. A. (2022). Biomedical applications and effect of hyaluronic acid as a filler material: A review. *International Journal of Health Sciences*, 6(S8), 5623–5647.
<https://doi.org/10.53730/ijhs.v6nS8.13558>

Biomedical applications and effect of hyaluronic acid as a filler material: A review

Leena Ali Al-aroomy

Oral and Maxillofacial Pathology, Faculty of Dentistry, Ibb University, Yemen.
MSc, PhD, Oral and Maxillofacial Pathology, Faculty of Dentistry, Cairo University
Corresponding author email: leena.ali@dentistry.cu.edu.eg

Mohamed Salah Alwadeai

Lecturer in Oral and Maxillofacial Surgery, Faculty of Dentistry, Ibb University, Yemen
Email: Mohammed.alwadeai@dentistry.cu.edu.eg

Hiba Obad Saleh

MSc, PhD, Oral and Maxillofacial Surgery, Faculty of Dentistry, Cairo University
Email: hiba-obad@dentistry.cu.edu.eg

Ahlam Abdulsalam Othman

Associate Professor of Fixed Prosthodontics Department, Faculty of Dentistry, Sanaa University, Yemen
Email: ahlam.abdulsalam@yahoo.com

Abstract---Hyaluronic acid (HA) is a naturally occurring biodegradable polymer with a variety of applications in medicine including scaffolding for tissue engineering, dermatological fillers and viscosupplementation for osteoarthritis treatment. HA is present in most connective tissues as well as, in body fluids such as synovial fluid and in the vitreous humor of the eye. Due to its versatility, hyaluronic acid has been a major component of biomedical research and has seen application in several fields such as tissue engineering and cancer treatments. This review aims to outline hyaluronic acid's effect and applications in the biomedical world.

Keywords---hyaluronic acid, dermal fillers, inflammation, hyaluronan, hydrogel.

Introduction

The influence of sun exposure, gravity, and years of facial muscle movements starts to appear as wrinkles on the skin. During the aging process, basic changes in the skin, soft tissue, and skeletal support of the face occur resulting in a breakdown of the tissues under the skin leaving lines or other facial defects (Fakhari & Berkland, 2013). Dermal fillers can help fill in these lines and facial defects, temporarily restoring a smoother, more youthful looking appearance. Many dermal fillers have been used for reducing facial skin lines and wrinkles, and for providing lip augmentation. Hyaluronic acid is one of the most widely used dermal agents which has the properties of an ideal dermal filler (Farahani et al., 2012) An ideal dermal filler should be temporary but long-lasting (months to a year or longer), having minimum side effects and no allergenic effect, easy to administer, having minimum pain or no pain upon injection, and a reasonable cost for both the physician and the patient (Fakhari & Berkland, 2013).

Hyaluronic acid (HA) is a naturally occurring biodegradable polymer with a variety of applications in medicine including scaffolding for tissue engineering, dermatological fillers and viscosupplementation for osteoarthritis treatment. HA is present in most connective tissues as well as, in body fluids such as synovial fluid and in the vitreous humor of the eye (Fakhari & Berkland, 2013).

HA plays a key role in regulating extracellular matrix (ECM) organization and metabolism by influencing cell migration, proliferation and differentiation. Thus, it is dynamically involved in a number of biological and pathological processes such as embryogenesis, inflammation, metastasis, tumour progression, tissue turnover and wound healing (Olczyk et al., 2008). HA has features that make it an attractive substance for dermal filler use, such as its ability to bind to large amounts of water, its natural presence in the skin, and its low potential for adverse reactions (Tezel & Fredrickson, 2008). Hyaluronic acid injection can be used as a dermal filler to improve the skin's contour and reduce depressions in the skin due to scars, injury or lines. Although Hyaluronic acid fillers are non-toxic and non-immunogenic, hypersensitivity and granulomatous foreign body reaction have been reported (Farahani et al., 2012).

Hyaluronic acid History

In 1934, Meyer and his colleague Palmer isolated a previously unknown chemical substance from the vitreous body of cow's eyes. This substance contained two sugar molecules, one of which was uronic acid while the other was an amino sugar. They proposed the name "hyaluronic acid", derived from "hyalos", which is a Greek word for glass and uronic acid (Mangla et al., 2015). It was first medically used in humans in the late 1950's, as vitreous substitution or replacement. It was initially isolated from the human umbilical cord and shortly after from rooster combs, in a highly purified and high molecular weight (HMW) form (Necas, 2008). Recently, it was isolated from bacteria either through a process of fermentation or by direct isolation (Saranraj, 2014).

Structure

Glycosaminoglycans (GAG)s, also referred to as mucopolysaccharides, are large negatively charged unbranched polymers composed of repeating sugar units, one of which is an amino sugar. The main GAGs include chondroitin sulphate, keratan sulfate, heparin and HA. HA was found to be the most prevalent GAG, where it has been estimated that an average 60 kg human body weight contains 12 gm of HA (Matarasso et al., 2006). The term "hyaluronan", was introduced encompassing the different forms the molecule can take (Balazs and Denlinger 1989). These forms were either an acid form, (HA) or the salt form, (sodium hyaluronate), which exists under physiological conditions (Tamer, 2013). The primary structure of HA is composed of an unbranched linear chain, consisting of repeating units of the monosaccharide D-glucuronic acid and the amino sugar N-acetyl-D-glucosamine, linked together through alternating beta-1, 4 and beta-1, 3 glycosidic bonds (Fig. 1).

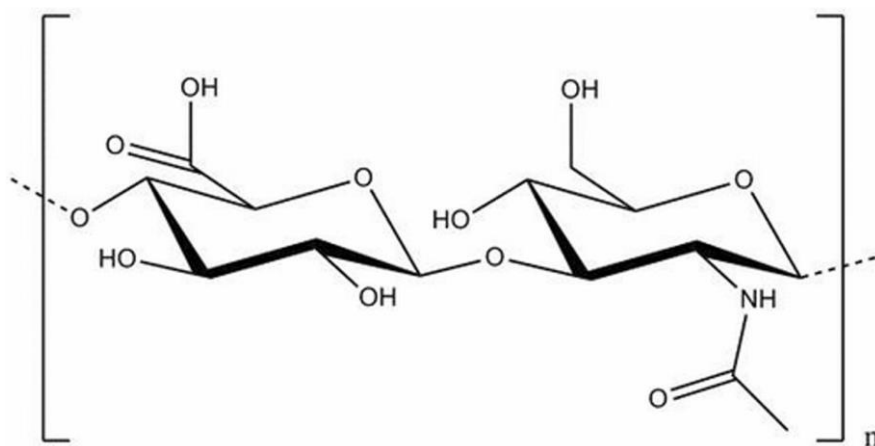


Figure (1).Chemical structure of hyaluronic acid (HA) (Sudha and Rose, 2014).

The number of repeated disaccharides in a completed hyaluronan molecule can reach 10 000 or more, a molecular mass of ~4 million daltons (each disaccharide is ~400 daltons). The average length of a disaccharide is ~1 nm. Thus, a hyaluronan molecule of 10 000 repeats could extend 10 μ m if stretched from end to end, a length approximately equal to the diameter of a human erythrocyte (Cowman and Matsuoka, 2005).

In solution, the hyaluronan polymer chain assumes a stiffened helical configuration attributed to the hydrogen bonding between the hydroxyl groups along the chain. As a result, an expanded hydrophilic random coil is formed, trapping approximately 1000 times of its weight in water. These chains entangle with each other at very low concentrations (as low as 1g/l) giving hyaluronan unusual rheological properties, making it ideal as a lubricant. It is evident that hyaluronan separates most tissue surfaces which slide along each other (Fakhari & Berklund, 2013). The viscoelasticity of HA solution was found to increase with the molecular weight and concentration of HA molecules. It also appeared to be pH-dependent and affected by the ionic strength of the environment, as a result of

the alteration of the intermolecular interactions between the HA molecules (Brown and Jones, 2005).

Synthesis& degradation

HA is predominantly produced by stromal cells, mainly fibroblasts in the extra cellular matrix (ECM) (Stern, 2003). HA is not synthesized in the cell's Golgi networks, as the case with most of the (GAG)s. The cellular synthesis of HA is a unique and highly controlled process. HA is naturally synthesized by a complex of cytoplasmic integral proteins, on the plasma membrane, called hyaluronan synthases (Choi et al., 2012). It is then extruded through the plasma membrane into the extracellular space, resulting in the synthesizing cell to be surrounded by a hyaluronan coat. The rate of biosynthesis is regulated by various factors such as growth factors (GF)s, hormones and inflammatory mediators (Stern, 2003). It is also well established that epithelial cells also synthesize HA (Pasonen-Seppanen et al., 2003).

In mammals, the enzymatic degradation of HA results from the action of three types of enzymes. Most of them are lysosomal and are known as Hyaluronidase (hyase) which were found to be five in number (HYAL 1-5), the other two enzymes are b-d-glucuronidase and (3-N-acetyl-hexosaminidase. These enzymes exist in various forms, intracellularly and in serum (Leach et al., 2004). Not all the HA molecules taken up by the cell are immediately degraded. Intact HA chains have been detected within the cell, in the cytoplasm, nucleus and nucleolus (Tammi et al., 2001). In somatic tissue, HA is degraded in a stepwise fashion as a result of a highly controlled catabolic pathway. HMW HA is tethered to the plasma cell surface, by HA receptors and cleaved into 20-kDa intermediate sized fragments (about 50 disaccharide units). These are further degraded into smaller units. Each of the resulting HA fragments have different biological activities (Scott and Heatley, 2002).

Small HA oligomers (6-20-kDa size range) were shown to be potent activators of dendritic cells, the antigen presenting cells of the immune system. Thus, they tend to be angiogenic, inflammatory and immunostimulatory (Termeer et al., 2000; 2003). Very small oligosaccharides (3-10-kDa disaccharide size range) have been found to inhibit anchorage-dependent tumour cell growth (Ghatak et al., 2002). On the other hand, HMW HA polysaccharides were found to be space filling molecules which hydrate the tissue. They were also found to be antiangiogenic, anti-inflammatory and immunosuppressive (Aya & Stern, 2014)

Metabolism & turnover

Half-life is known as the time required for half the quantity of a substance deposited to be eliminated or metabolized by normal biological processes. Turnover, however is the movement of an element into, through and out of a place (the rate at which it is depleted and replaced) (Tripathi, 2013). Some cells actively synthesize and catabolize hyaluronan throughout the lifetime of the tissue such as chondrocytes in cartilage cells, where the half life of the synthesized hyaluronan is 2-3 weeks in cartilage. On the other hand, the hyaluronan

synthesized by keratinocytes of the epidermis has a half life of less than a day (Laurent, 1998).

Sometimes cells either predominantly synthesize or catabolize hyaluronan, as cells of the dermis which actively synthesize more hyaluronan than they catabolize. It has been estimated that almost one-third of the total hyaluronan in the human body is metabolically removed and replaced during an average day (Papakonstantinou et al., 2012). In case of external HA, regardless of its route of administration, its tissue half-life ranges from half a day to two or three days (Fraser et al., 1997).

Turnover of the HA content in the tissue, occurs either by lymphatic drainage to the bloodstream or by local metabolism. In case of densely structured tissues with no lymphatic drainage, such as bone and cartilage, most of the HA turnover occurs by metabolic degradation in situ. In skin and joints, 20-30 % of the HA turnover occurs by local metabolism, while the rest is removed by lymphatic drainage (Fraser et al., 1997). An overall increase in the HA turnover, owing to both an increased rate of its synthesis and degradation, is seen in malignancies (Toole and Hascall, 2002).

Almost 90% of the hyaluronan molecules released from the tissue, were found to be captured by receptors on the reticulo-endothelial cells lining lymph nodes. There, they are catabolized internally in lysosomes, releasing low molecular weight (LMW) products like lactate and acetate (Agerup et al., 2005). Studies indicated that macrophage-like cells intertwined with the endothelial cells take up hyaluronan (Fraser and Laurent, 1989). On reaching the blood stream, about 85-90% of the HA was found to be eliminated in the liver, via receptor-facilitated uptake and catabolism in hepatic sinusoidal endothelial cells. Kidneys were found to extract about 10% , but only 1-2% is excreted in urine (Laurent and Fraser; 1991).

Distribution and function

HA is found to be abundant in mammalian skin, it constitutes a high fraction of the extra cellular matrix (ECM) of the dermis (Brown & Jones, 2005). Moreover, it has been reported to be abundant in tendon sheaths and bursae, lungs, kidney, brain, synovial fluid, vitreous body and certain specialized tissue such as the umbilical cord and rooster comb, during fetal development. HA is also found in small amounts in serous cavity fluids and in between muscle layers and very little in the liver. It persists between individual fibers, spindles and septa in skeletal and cardiac muscle, as well as smooth muscle fibers of gut and vessel walls. The lowest concentration was found to be in the blood serum (Laurent, 1995; Fraser et al., 1997).

In the ECM

Toole, (2013) reported that HA was found to be a part of the complex structure of the ECM and it has been documented in developmental processes, such as the prevention of cell fusion. HA is present at the pericellular zone (around fibroblast in ECM) and have an important influence on tissue morphogenesis during

development, especially on cell migration and adhesion, as well as protection against attacks from viruses, bacteria and immune cells. During normal cell division, hyaluronan synthesis increases, helping the dividing cell to disassociate from its substratum, thereby permitting cell movement by attracting large amounts of water to the area owing to its hygroscopic properties (Anderson, 2001).

Hyaluronan solutions, exhibit a non-ideal osmotic pressure, where the osmotic pressure increases exponentially rather than linearly with increasing hyaluronan concentrations. In tissues, this osmotic buffering capacity is reflected in its high resistance against water flow, acting as a barrier against rapid changes in water content. This is important in regulating water content in tissues. Along with other polysaccharides, hyaluronan helps regulate the transport of macromolecules through the extracellular space. The hyaluronan meshwork, acts as a sieve allowing the free movement of small molecules while immobilizing larger particles (Horkay et al., 2009).

HA plays several important organizational roles in the ECM, by binding with cells and other components through specific and nonspecific interactions. Hyaluronan binding proteins (hyaladherins) are a major constituent of the ECM, stabilizing its integrity (Kahmann et al., 2000). Many physiological functions of HA are thought to be related to its molecular structure, its physiochemical properties, as well as its specific interactions with hyaladherins such as CD44 (cell surface glycoprotein) and RHAMM (Receptor for Hyaluronic Acid Mediated Motility). These interactions result in the activation of a signaling cascade that influences cell behavior (Toole and Hascall 2002), such as stimulating fibroblast proliferation, migration and collagen production. Hyaluronan also contributes to tissue hydrodynamics by creating space for the movement of cells, as well as regulating diffusion of nutrients, metabolites and hormones (Stern, 2003).

Ellis and Schor, 1996 found that exogenous hyaluronan helped increase fibroblast migration to a wound site in a dose dependent fashion, where the higher the hyaluronan levels the greater the cell migration. This is mediated through the interaction of hyaluronan with the hyaluronan receptors CD44, ICAM-1 (Inter Cellular Adhesion Molecule-1) and RHAMM. This higher number of fibroblasts contributed to increased production of ECM and new collagen (Tolg et al., 2014). Hyaluronan moderates the inflammatory process, which is essential for initiating the healing process and normal tissue repair, as well as the stabilization of the granulation tissue (Aya & Stern, 2014).

Foschi et al., 1990, in a study on rats, noted that hyaluronan preparations helped improve tensile strength of healing wounds, probably due to its free radical scavenging properties. Cross-linked HA hydrogel films were also found to accelerate the healing of full-thickness wounds, presumably by providing a highly hydrated and non-immunogenic environment that is conducive to tissue repair (Dechert et al., 2006).

In the Skin

In addition to providing structure for the framework that exists in the ECM, HA is critical for creating pathways that allow the body to transport nourishing molecules to the outer layers of the skin and eliminate pollutants and metabolic waste products from the upper cells. More importantly, HA also plays a role in helping to regulate the life cycle of skin cells. HA is not only found in the dermis but significant amounts were also found in the visible epidermis (Papakonstantinou et al., 2012). There was evidence that high concentrations of HA actually increased the turnover of cells in the epidermis. This means that HA may help the body eliminate the dead outer layer of skin cells and force the skin to regenerate. Hyaluronan serves as a survival signal for keratinocytes, delaying their terminal differentiation and helping them survive longer (Papakonstantinou et al., 2012).

In the Oral Tissues

Hyaluronan was found to comprise almost 40% of the total GAG content of human gingiva. The constant turnover and replenishment of hyaluronan in gingival tissue may give rise to its constant presence in the gingival crevicular fluid, as a serum overload factor (Rajan et al., 2013). HA has been studied as a metabolite or diagnostic marker of inflammation, in gingival crevicular fluid (Embery et al., 1982). Hyaluronan was found to be absent in the gingival crevicular fluid only as a consequence of a pathological state, such as ulcerative gingivitis, where treatment was followed by its reappearance (Rajan et al., 2013). It has been reported that the two major GAGs detected in peri-implant sulcus fluid were hyaluronan and chondroitin 4 sulphate (Gupta, 2012).

Hyaluronan has been identified in all periodontal tissues in various quantities, being more prominent in the nonmineralized tissues, such as gingiva and periodontal ligaments, compared to mineralized tissues such as the cementum and alveolar bone (Embery et al., 2000). Periodontal connective tissue contains fibrillary structures like collagen, elastic fibers and reticular fibers in an amorphous matrix of GAGs. HA is the most abundant GAG in the ECM of the periodontal tissue, where it fulfills a variety of functions vital for the maintenance of healthy periodontal tissue (Mesa et al., 2002).

In Synovial Joints

HA coats the surface of the articular cartilage, as well as residing deeply in the cartilage among collagen fibrils and sulphated proteoglycans. It helps maintaining the normal cartilage matrix (Buckwalter et al., 2005). Although HA constitutes only a small fraction of the cartilage matrix, it plays a specific role in its stabilization and structural formation. The GAGs are bound to the HA by link-proteins to form mature articular proteoglycans. These cartilage proteoglycans (aggrecans) deposit between the collagen fibers and onto the chondrocytes, attracting water by osmosis (Thonar et al., 1999).

Exogenous HA was found to enhance chondrocyte HA and proteoglycan synthesis, as well as helping in reducing the production and activity of proinflammatory

mediators and matrix metalloproteinases (MMPs) and altering the behavior of immune cells. These functions were thought to be achieved through its ability to scavenge reactive oxygen-derived free radicals, inhibition of immune complex adherence to polymorphonuclear cells, inhibition of leukocyte and macrophage migration and aggregation as well as the regulation of fibroblast proliferation (Moreland, 2003). Cartilage destruction in rheumatoid arthritis and osteoarthritis, was found to be induced by ECM protein fragments such as fibronectin (Homandberg, 2001). Fibronectin fragments bind and penetrate cartilage, subsequently increasing level of MMPs and suppressing prostaglandin (PG) synthesis. HA had been shown to suppress cartilage damage both in vitro and in vivo (Homandberg et al., 1997). This protective effect was associated with its coating of the articular surface, suppression of stromelysin-1 release enhanced by fibronectin fragments, increased PG synthesis, and restoration of PGs in damaged cartilage (Singh et al., 2014).

In the TMJ, it was found that HA greatly enhanced the biomechanical stabilization of the articular components, through playing a major role in the feeding of the articular cartilage and lubrication of the joint components (Cascone et al., 2002). HA can also reduce the nerve impulses and sensitivity, associated with pain (Akmal et al., 2005).

In the Eyes

HA was found to help in the growth and migration of cells across the cornea enhancing wound healing and eye tissue regeneration (Miyachi et al., 1990). In addition, HA was also found on the surface of the eye and is often used as a lubricant for the corneal epithelium (Yokoi et al., 1997).

Medical applications

Orthopaedic Applications:

A single HA intra-articular injection was used to treat patients with temporomandibular (TMJ) disc displacement resulting in a significant improvement in the symptoms and the TMJ mobility for 6 months (Bertolami et al., 1993). It reduced pain, improved TMJ function and had a definite effect on the cell mediated immune response associated with inflammation in patients with internal derangement in TMJ disorders (Hirota, 1998).

Surgical Applications

Postoperative adhesions, which form between adjacent tissue layers following surgery, impede wound healing and often require additional surgical procedures. Barriers made from cross-linked HA, have been effectively used to prevent such adhesions. Furthermore, biomaterials such as dental implants, intraocular lenses and catheters have been treated with cross-linked HA to prevent adhesion of bacteria, thus preventing infection. Also, treatment of cardiovascular implants, such as vascular grafts and stents, with cross-linked HA has been found to be effective in increasing their blood compatibility, by reducing platelet adhesion and thrombus formation (Leach et al., 2004).

Dental Applications

Pulp healing in the molars of rats, was examined by light and electron microscopes, following mechanical pulp exposure and direct capping with HA. The results suggested that HMW HA provided a suitable environment for reparative dentin formation in pulp healing, without causing any necrotic and/or severe inflammatory reactions. This was thought to be through mesenchymal cell differentiation, indirect stimulation of odontoblast like cells and blood vessel invasion. Another indirect beneficial effect, on the induction of calcified tissue repair was through the effective maintenance, of several cytokines known to stimulate tissue repair, within the local environment (Sasaki and Kawamata-kido, 1995). HMW hyaluronan has also been shown to stimulate osteoinduction during wound healing (Bogović et al., 2011).

In case of gingivitis and periodontitis HA has been shown to have an anti-inflammatory effect (Pagnacco et al., 1997 and Jentsh et al., 2003). In patients with chronic periodontitis, HMW HA was found to reduce cellular proliferation in the gingival epithelial cells, fibroblasts and lymphocytes. This helps in abating the inflammatory process and improving the periodontal lesion (Mesa et al., 2002). In periodontitis treatment, the large size and high negative charge of HA, enabled it to absorb large amounts of water, exerting significant pressure on the surrounding tissue and resulting in the expansion of the extracellular space. This in turn results in a buffering action to the bite force on the periodontal ligaments (Cantore et al., 2010; Dahiya et al., 2013) HA may act as a biomaterial scaffold for molecules such as BMP-2 (Bone Morphogenic Protein-2) and PDGF-B (Platelet-derived growth factor beta). It was also used in guided bone regeneration techniques and tissue engineering research (Hunt et al., 2001).

The topical application of HA on alveolar bony defects in experimental animals was found to accelerate periodontal wound healing and new alveolar bone formation (Sukumar & Drizhal, 2007). This osteoconductive potential was thought to be a result of HA ability to stimulate chemotaxis, proliferation and the successive differentiation of mesenchymal cells. HA was also found to share bone induction characteristics with BMP-2 and osteopontin (Mendes et al., 2008). The local subgingival HA application adjunctive to scaling and root planning has shown potential benefits in the treatment of periodontitis, owing to its tissue healing and regenerative properties. This important role is achieved through the facilitation of cell migration and differentiation during tissue formation (Sukumar & Drizhal, 2007). HA has also been shown to be useful in the peri-implant maintenance of immediate function implants (De Araujo Nabre et al., 2007) and the non-surgical treatment of peri-implant pockets (De Araujo Nabre et al., 2009).

Tissue Engineering Applications

An autologous cell HA graft was used for gingival augmentation in mucogingival surgery, where fibroblasts were cultivated on a scaffold of fully esterified benzyl ester HA. Three months after surgery an increased amount of gingiva was obtained and a histological examination revealed a fully keratinized tissue on all treated sides without any discomfort for the patient (Prato et al., 2003). Hyaff (HA

benzyl esters) scaffolds cultured in vitro with keratinocytes and fibroblasts have been used to create materials similar to skin, including two distinct epidermal and dermal-like tissue layers (Leach et al., 2004).

HA-poly-D-lysine copolymer hydrogel, with viscoelastic properties similar to neural tissue has been developed for brain tissue engineering, providing a cell scaffold for either transplanted or resident cells. This represents a promising option for cellular replacement in cases of post-injury brain (Tian et al., 2005). In the field of intestinal tissue engineering, sheet membranes made of polymers of HA benzyl esters, were found to be promising substrata for intestinal cells adhesion and growth as well as the induction of cellular differentiation. This is particularly useful in the treatment of a wide number of gastrointestinal disorders leading to impaired function, such as short bowel syndrome (Esposito et al., 2006). HA sponges were implanted at dentin defect areas above an amputated dental pulp. Dental pulp proliferation, vessel invasion and cell-rich reorganizing tissue were observed. Based on the results, HA sponges were concluded to have an appropriate structure, biocompatibility and biodegradation when used as a scaffold for dental pulp regeneration (Inuyama et al., 2010).

Cosmetic and soft tissue augmentation

Soft tissue augmentation of the face is becoming an increasingly popular procedure. The number of available filling agents has also increased dramatically, improving the range of options available to patients and physicians. Understanding the different characteristics, capabilities, risks and limitations of the available dermal and subdermal fillers, can help physicians improve patients outcomes and reduce the risk of complications (Smith, 2008). The search for the ideal filler began more than a century ago. Soft tissue augmentation dates back to 1893, when Neuber first implemented autologous fat transfer for facial defects (Buck et al., 2009). Just a few years later, the injection of paraffin for cosmetic enhancement started becoming increasingly popular, until patients began developing severe foreign body and granulomatous reactions. The use of liquid silicone as a soft tissue filler began in the 1940's but then due to the resulting adverse effects, its approval has been precluded (Narins and Beer, 2006).

The use of bovine collagen started a new era of soft tissue augmentation. A small percentage of patients demonstrated allergy to it, so test injections were necessary up to 3 weeks in advance to the procedure. More recent alternatives included acellular human dermis (Dermalogen) and cultured fibroblasts (Isologen) which were associated with less immunological intolerance and longer duration (John and Price, 2009). The most widely used products fall into four major categories, autologous fat, collagens, HA and biosynthetic polymers. Injectable facial fillers are either harvested from the patients themselves (autologous implants) or another human (allogenic implants) or an animal or bacterium (xenogenic implants) or created in the lab (synthetic). Synthetic fillers are usually composed of a biosynthetic polymer combined with injectable carriers including hydrogels, beads and liquids (Vedamurthy, 2008; Buck et al., 2009).

Fillers can be classified in a number of different ways. One classification is made according to longevity into nonpermanent or temporary fillers, semipermanent

and permanent fillers (Vedamurthy, 2008). Nonpermanent or temporary fillers produce short lived results and eventually undergo resorption. Fillers of this type require repeated injections for long term results. These include collagen and HA. Semipermanent fillers last longer than temporary fillers and are expected to experience some resorption. Examples include calcium hydroxyapatite and poly-lactic acid. Permanent fillers produce long term results and indefinitely persist within the tissue which increases the potential of long term adverse effects. These include silicone and polyacrylamide hydrogels (Buck et al., 2009).

Permanent fillers also have two other main drawbacks. Filler misplacement necessitates surgical removal and its placement cannot be adjusted to account for ongoing age related facial changes (John and Price, 2009). Another classification is based on the site of placement, either dermal, subdermal or supraperiosteal (Vedamurthy, 2008). A common misnomer of injectables, is one which labels all fillers as dermal. The distinction between products used in superficial defects, injected directly into the dermis and others more appropriate for deeper defects is important. This is in order to avoid palpability and risk of permanent nodularity or contour abnormalities (Buck et al., 2009).

The most ideal filler should be easy to inject, provide reproducible results, possess longevity, be nonallergic (no skin testing required), noncarcinogenic, nonteratogenic and show no potential allergies from the injection itself. Once injected, it should be expected not to migrate and should be unpainful upon injection. A major accomplishment in 2010 was the development of commonly used fillers having lidocaine for patient comfort. It should be stored at room temperature and have a long shelf life. It also should be free from any transmissible diseases, have minimal potential for untoward effects and also be cost appropriate, that is affordable for both the patient and clinician (Gold, 2010).

HA has been utilized in cosmetic formulation because of its viscoelastic properties and excellent biocompatibility. It was reported to restore elasticity and achieve an antiwrinkle effect. Due to its free radical scavenging properties, it was found to be capable of protecting the skin against UV radiation (Trommer et al., 2003). Also due to its ability to form hydrated expanded matrices, HA either in stabilized form or in combination with other polymers has been successfully utilized as a component of commercial dermal fillers, used in soft tissue augmentation (Leach et al., 2004; Dechert et al., 2006).

Injectable HA has proven to be a successful and less invasive method in the treatment of defects, in patients who have endured multiple corrective surgeries. A 21 years old woman, who complained of upper lip asymmetry and poor volume after the surgical repair of a unilateral left-sided cleft lip and palate, was successfully treated with the injection of HA (Schweiger et al., 2008). In cases of lipoatrophy and improvement of skin appearance, volume augmentation of the back of the hand was also done, using stabilized injectable HA and produced satisfactory results with no significant adverse effects (Hartmann, 2010).

Hyaluronic acid fillers

The first HA dermal filler was developed by Balazs and his co-worker in 1989 triggering the HA revolution (Balazs and Denlinger, 1989). When used as a filler, HA products of nonanimal origin, known as NASHA (nonanimal stabilized hyaluronic acid), such as those produced by means of bacterial fermentation, have not been proven to have any sensitizing effect. Rates of hypersensitivity reactions were reported to be 1:5000 (Friedman et al., 2002). It has been found not to exhibit any tissue or species specificity, thus minimizing any potential immunological reaction or any other allergic potential. When water is drawn into the HA matrix, it creates a swelling pressure or turgor which enables the HA complex to withstand compressive forces (Gold, 2007). The hydrophilic nature of HA fillers allows it to maintain its shape using the body's own moisture (Monheit and Coleman, 2006). HA fillers also tend to form very highly, water soluble polymers (Bentkover, 2009).

A unique and major advantage of HA fillers, is its reversibility. HA fillers can be easily eliminated whenever necessary by the injection of commercially available hyaluronidase into the concerned area (Newman, 2009). Hyaluronidase is a soluble protein enzyme, which acts at the site of local injection to break down and hydrolyze HA (Brandt & Cazzaniga, 2008). This is particularly useful where filler elimination is easily and quickly required either because there is excess HA in the area or to accelerate the resolution of an adverse reaction to treatment or to the product (Smith, 2008).

An added benefit to the use of HA fillers was suggested by Wang et al., 2007 through having the ability to stimulate collagen neogenesis. The findings of the study indicated that NASHA injections alter cellular production of collagen by the stretching of existing collagen fibers, which in turn impose mechanical tension on nearby fibroblasts and initiate collagen synthesis. Other potential mechanisms thought to lead to such an effect were by the induction of connective tissue GFs such as transforming growth factor- β (TGF- β), as well as by inhibition of collagen breakdown.

Primary indications for HA fillers are photoaging wrinkles and in nasolabial folds, lip rhytides, marionette lines and volume enhancement such as lip filling and contouring, cheek augmentation and treatment of tear trough lines. Generally, HA is not ideal for superficial wrinkles but instead it is more suited for deep folds and volume augmentation. The more superficial the injection, the higher the risk of visibility. This led to various HA products being used for different parts of the face. Smaller molecular preparations have been developed and proved to have a good effect with superficial wrinkles (John and Price, 2009). The disadvantage of HA is that it is only effective for a short period of time. In the natural form, injectable HA lasts only for 1-2 days secondary to local degradation. HA fillers have longevities ranging from 6-12 months, depending on a lot of factors such as the implant location as well as the production process (Bentkover, 2009).

The production process

Crosslinking native HA results in larger, more stable molecules with similar biocompatibility and viscoelastic filling properties, as well as longer in vivo half-life. It also creates a larger macromolecule which transforms the HA fluid to a more cohesive gel (Ryssel et al., 2012). In addition to increasing the molecular weight, crosslinked HA is more elastic than non-crosslinked HA (Weidmann, 2009) (Fig.2).

The large gel mass produced by the cross-linking process, must then be broken up into smaller equal units to pass through a syringe. This is usually done by using a series of sieves, to produce a particular particle size. Large amounts of non cross-linked HA can be added to products produced with sieves so that these products will flow better. Another approach to processing the gel mass resulting from crosslinking, is to homogenize it instead of passing it through a sieve to break it into smaller equal units, in order to pass it through a syringe. This homogenized product, is a softer gel with a more uniform particle size and distribution (Tezel and Fredrickson, 2008).

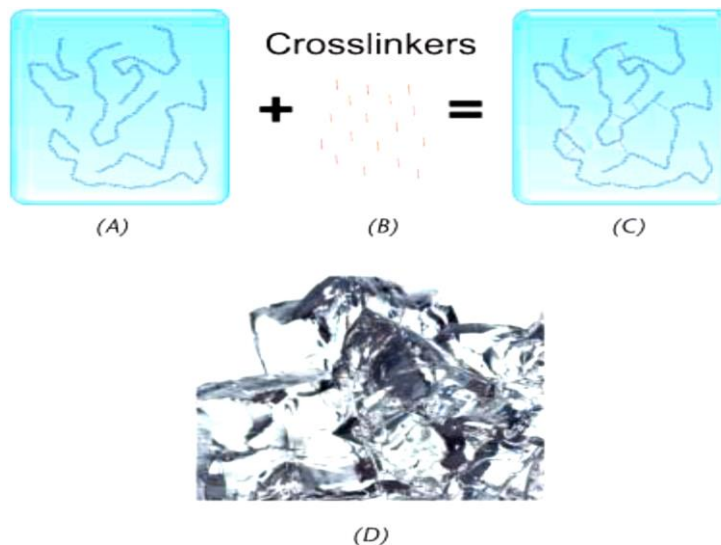


Figure 2. HA gel. Crosslinking HA polymer chains transform the HA solution (A) into a network (C). Crosslinker molecules (B) bind individual HA polymer chains to create a network (C), which manifests macroscopically as a gel mass (D) (Tezel and Fredrickson, 2008).

Variations in the manufacturing process of HA yield products with different viscoelasticities, different gel hardness, structure uniformities and different swelling degrees caused by water accumulation. These physical properties depend on the source derivation (animal versus bacteria); the crosslinking degree and method, the length of the molecular chain, the HA particle size and the HA concentration. The concentration is the measure of the soluble and insoluble HA, where the soluble (free or non-crosslinked) HA improves lubrication, while the insoluble HA contributes to the clinical effect. As a result of the variable production process, a wide variety of products are now commercially available for

different locations. All these factors are important in the classification of a HA filler, such as how and where the filler is best suited for use or whether it is monophasic or biphasic (John and Price, 2009; Gold, 2010).

There are three different technologies for manufacturing HA. According to the first method, a partly crosslinked portion of HA is suspended in a crosslinked portion, in order to make the subject injectable. These are described as biphasic products, such as Restylane, Perlane, Hyalform. According to the second method, HA is partially crosslinked (about 1-20%) and the final product is then filled into a syringe. These fillers are described as a monophasic product such as Juvederm, Eshthelis and Teosyal. The latest development is a highly crosslinked HA (70-90%) with no suspension at all, but still having the best injectability features (Weidmann, 2009).

The biology of facial fillers

The biologic characteristics of the facial filler such as local tissue reaction (including phagocytosis and granulomatous inflammation) crosslinking, particle concentration, immunogenicity, biofilm formation, gel hardness, and collagen neogenesis can influence the biologic behaviour of the filler (Bentkover, 2009). Phagocytosis is a result of a complex interplay between particle size, shape and other factors such as surface shape, surface tension, acuteness of contact angles and surface charge (Champion et al., 2008).

Champion and Mitragotri, in 2006 stated that particle shape plays a larger role in phagocytosis than the particle size. At phase one, particle shape dictates whether phagocytosis begins or not. At the second phase, size becomes a factor. Also, particle size seems to influence phagocytosis in cases where the particle volume is greater than the volume of the phagocyte. The phagocytic response seems to decrease with increasing particle size (Champion et al., 2008). The exact effect of surface charge is less clear, the positive surface charge increases phagocytosis and negative surface charge decreases phagocytosis (Bentkover, 2009).

Failure of effective phagocytosis can lead to granuloma formation, encapsulation and sometimes long term sequelae. Granulomatous infection occurs when aggregates of activated macrophages (multinuclear giant cells) are unable to ingest their target (Kumar et al., 2012). The macrophages take on a characteristic epithelioid appearance looking like squamous cells. These aggregates are then surrounded by lymphocytes, which begin to secrete cytokines enhancing macrophage activation. In older more stable granulomas, a surrounding fibroblast rim and connective tissue capsule develops, walling off the foreign body and preventing the progress of destructive inflammation (Bentkover, 2009).

HA filler complications

Common complications encountered with all types of soft tissue fillers can be categorized according to different criteria. These are the time of onset (early versus delayed), aesthetic relevance (minor versus major), casualty of the adverse reaction either according to the injection site reaction, improper injection technique, allergies and hypersensitivity reactions or vascular mediated effects

(Lafaille and Benedetto, 2010). Tissue reactions may occur because of the filler nature, even if the procedure is correctly executed. It may also arise because of the poor procedural technique. Other reactions depend on the product concentration used (Lowe et al., 2005). Papule or nodule formation, surface irregularity and asymmetry may result from improper injection technique (Brody, 2005). Adverse reactions can either occur immediately or be short termed (1-2 weeks) or long termed, ranging from several weeks to months. Short duration local injection site reactions, generally result from an acute infection response to tissue damage, as the result of the introduction of a foreign material (Edwards and Fantasia, 2007)

Injection site complications

The most common complication associated with HA injection are local injection related side effects which manifest as edema, pain, erythema, itching and ecchymosis (Lafaille and Benedetto, 2010). These adverse side effects are mild and usually last less than one week. Pain is considered to be a common adverse effect during HA injection. Several techniques can be used in order to minimize the pain associated with injections, which include: the utilization of the small needle gauge or blunt-tipped cannulas, the use of topical anesthetic agents, application of ice prior and after injection, vibratory distraction and nerve blocks (Carruthers and Carruthers, 2012). Ecchymosis and edema can be minimized by stopping the intake of aspirin, Nonsteroidal anti-inflammatory drugs (NSAID), supplements containing ginkgo biloba, vitamin E, omega-3, fish oil at least one week prior to the procedure. Some practitioners use the vascular laser to reduce post-injection bruises (Gilbert et al., 2012).

Hypersensitivity reactions

Safety data on non-animal-stabilized hyaluronic acid (NASHA) gel show that it has a favorable safety profile. One study on the use of NASHA found that localized hypersensitivity, which was defined as “swelling, erythema, and induration at the implant site, sometimes with edema in the surrounding tissue with a median duration of 15 days”, occurred in only 1 of every 1400 patients. Another study found only a 0.8% incidence of acute or delayed hypersensitivity reactions to NASHA gel (Leonhardt et al., 2005).

NASHA may contain immunogenic protein, potentially introduced through the manufacturing process. Hypersensitivity reactions to Restylane (Medicis Aesthetics Inc.) documented in the 1990 s are believed to have been related to protein contaminants. The reduction in the frequency of hypersensitivity reactions since the year 2000 may be partly explained by the introduction of a hyaluronic raw material with trace amounts of protein six times lower than the raw material previously used (Abduljabbar & Basendwh, 2016).

Infections

Injectable fillers are also associated with infections, which can result from the breach in skin surface integrity. The infectious agents may be bacterial, viral or fungal. In order to minimize the risk of infection, the patients' history should be

taken, including any history of recent dental procedures, any periodontal treatment planned within the next two weeks or any history of chronic sinusitis (Cox and Adigun, 2011). The patient should not wear makeup either before or immediately after the procedure. Aseptic technique should be used, including proper skin sterilization with 2–4% chlorhexidine or 70% isopropyl alcohol solution and avoiding contamination of the treatment area after cleansing the patient's skin. An injection approach should be used that reduces the number of skin piercings and uses the smallest gauge needle possible for injections. It is also important to avoid injecting into inflamed or infected skin, to avoid intraoral injections and to avoid injecting through previous layers of filler (Bailey et al., 2011 and Ozturk et al., 2013).

Herpes simplex infection

Reactivation of herpes simplex infection, especially when performing lip augmentation, is not an uncommon adverse effect and should be addressed properly. Patients with a history of recurrent herpes simplex outbreaks should receive prophylactic antiviral therapy in the form of valacyclovir 500 mg bid 2 days before the procedure and 3 days after. Patients with active lesions of herpes simplex infection should postpone their procedure. Patients who develop new lesions post injection need to be started on an appropriate antiviral regimen and appropriate oral antibiotic if a superadded bacterial infection develops (Sanchez-Carpintero et al., 2010, Funt and Pavicic, 2015).

Abscess and cellulitis

Bacterial inoculations can occur after filler injections as a result of skin surface breakage. Inflammatory nodules that present with erythema, edema and tenderness, in other words, a “red angry bump”, which presents within 3–14 days should be treated as an infection (Daines and Williams, 2013)

Mycobacteria

Post filler bacterial infection with *Mycobacterium abscessus* was reported in New York City in 2002 after a non-FDA approved HA filler was used (Hyacell) which was illegally imported from South America (Cohen, 2008, Rousso and Pitman, 2010).

Biofilms

A biofilm is a collection of bacteria surrounded by a protective and adhesive matrix, which was first discovered on dental plaques (DeLorenzi, 2013 and Kunjur and Witherow, 2013). Biofilms use the implanted filler as a surface on which to attach and excrete their own matrix. This matrix gives them the ability to survive, develop and resist antibiotic treatment up to a thousand times more effectively than planktonic bacteria. This excreted polymeric material entraps leukocytes and prevents phagocytosis (Marusza et al., 2012, Cassuto and Sundaram, 2013).

Foreign body granuloma

Foreign body granuloma is a chronic inflammatory reaction that entraps a foreign body, preventing its migration. This reaction occurs because of the inability of the immune system to enzymatically degrade or phagocytose the foreign body (Funt and Pavicic, 2015). HA fillers may still contain little amounts of protein contaminants after purification, which can carry a risk for hypersensitivity reactions and granuloma formations. The incidence of foreign body granuloma after the injection of HA fillers ranges from 0.02% to 0.4% (Lemperle et al., 2009 and Lee and Kim, 2015).

Granulomatous reactions generally have a delayed onset after filler injections, appearing as red papules, plaques or nodules with a firm consistency which may result from fibrosis in late stages (Lemperle et al., 2009). True granuloma must be confirmed histologically, by the presence of multinucleated giant cells that surround the basophilic product (Daines and Williams, 2013). Intralesional hyaluronidase is an effective therapy for granulomatous lesions secondary to HA filler (Brody, 2005 and Curi et al., 2015).

Discolouration

Bluish discolouration has also been reported, representing both traces of hemosiderin associated with vascular injury and visual distortion from light refraction to the filler through the skin (Tyndall effect) especially when the filler is placed too superficially (Lowe et al., 2005 and DeLorenzi, 2013).

Vascular occlusion

Vascular occlusion is the most concerning complication regarding filler injections. It can be a localized occlusion, resulting in skin necrosis, or a distant occlusion causing blindness or cerebral ischemic events (DeLorenzi, 2014 and Carle et al., 2015). Localized vascular occlusion results from either direct intravascular injection or the compression of the vessels by the injected filler material (Cox and Adigun, 2011). Arterial occlusion due to intra-arterial injection usually presents with an immediate or early skin blanching and varying degrees of pain; if not treated swiftly, the affected skin will develop reticulated erythema, purpura and ulceration and consequently, scarring (Gilbert et al., 2012).

Histological features of the implant site

The normal histological aspect, in human volunteers, after the injection of HA, showed a reaction composed of macrophages and a few multinucleated giant cells without fibrosis (Lemperle et al., 2003). The cellular reactivity around the implant material was always more prominent in fat than in dermis. It was seen to be in the form of a mild patchy lymphohistiocytic infiltrate. In a few specimens, the reaction was more vigorous, where a rare giant cell, together with some lymphocytes, histiocytes and a few neutrophils were seen within the infiltrate. This inflammation occurred shortly after the injection and increased in week 2 but became less prominent by week 4 and continued to decrease until it subsided in week 26 (Pinsky et al., 2008).

Duranti et al., 1998 established a classification of foreign body reactions following HA injection where Grade I signifies a slight reaction with a few inflammatory cells. Grade II is a clear inflammatory reaction with one or two giant cells. Grade III is marked by fibrous tissue with inflammatory cells, lymphocytes and giant cells, whereas Grade IV reflects a granuloma with encapsulated implants and a foreign body reaction. In case of complications, the histologic examination always showed inflammation varying from a light chronic infiltrate without a foreign body reaction (Micheels, 2001) to a moderate or dense infiltrate made of lymphocytes, plasma cells and a variable amount of macrophages. When present, the foreign body reaction may be sharply demarcated as a nodule, surrounding the injected material (Lowe et al., 2001). The inflammation reactions may extend into the subcutaneous fat. Fibrosis involving the lower dermis, may sometimes be prominent (Zimmermann and Clerici, 2004). An inflammatory response in the form of sterile abscesses also has sometimes been documented. Such an event is thought to be a result of an interaction between an immunogenic protein and the host immune cells (DeLorenzi, 2013).

The general histological features of the implant, which were noted in an excised nasolabial fold after mid to deep dermal implantation with HA injection, were examined. Large aggregates of an amorphous, lightly basophilic material were identified in the lower half of the reticular dermis and focally in the superficial subcutaneous layer (Greco and Elenitsas, 2010). Mercer et al., 2010 also described the injected HA, whether animal or bacterial, as an amorphous basophilic material, which may be sometimes seen inside histiocytes. It is rarely granulomatous and may mimic granuloma annular, which consists of grouped papules in an enlarging annular shape and is of an unknown cause.

The unsatisfactory bumpy or irregular appearance, was described histologically by a giant cell infiltrate and granuloma formation. A granulomatous reaction to HA may occasionally resemble a lesion of complete necrobiotic stage of granuloma annulare, which is also marked by increased acid mucopolysaccharides in the dermis (Rongioletti and Rebora 2003). Histologically, a collection of macrophages with some multinucleated giant cells and surrounding lymphocytes were seen (Cohen, 2008).

Conclusion

Over the past few years, hyaluronic acid and its numerous uses have been thoroughly investigated and are still being reviewed. Rooster combs or bacterial fermentation are used to extract the hyaluronic acid used in commercial products. People use hyaluronic acid for various joint pains, and in plenty of ophthalmic conditions. FDA has given approval to the use of hyaluronic acid for certain eye surgeries including corneal transplantation, cataract surgery, repair or removal of retina and other eye injuries. In plastic surgeries it is used as filler. It is popular as “Fountain of Youth” for its wound healing and moisturizing property but no clinical evidence is available that says administration of hyaluronic acid prevents the skin changes assisted with aging. Finally, it cannot be stressed enough that nothing can replace the invaluable knowledge gained by observing a seasoned injector or attending live injection demonstrations. Therefore, a better understanding of the chemical and physical makeup of HA

dermal fillers must be accompanied by appropriate training and experience to assure our ability to accomplish results that produce satisfied patients.

Abbreviations

HA: Hyaluronic Acid; NSAID: Aspirin, Nonsteroidal Anti-inflammatory Drugs; ECM: Extracellular Matrix; GAG: Glycosaminoglycans; HMW: High Molecular Weight

Authors' contributions

Writing and reviewing the paper: LA, MA. Critical revision: All authors. Final approval: All authors.

References

- Abduljabbar, M. H., & Basendwh, M. A. (2016). Complications of hyaluronic acid fillers and their managements. *Journal of Dermatology & Dermatologic Surgery* 20(2),100-106.
- Agerup, B., Berg, P., & Åkermark, C. (2005). Non-animal stabilized hyaluronic acid. *BioDrugs*, 19(1), 23-30.
- Akmal, M., Singh, A., Anand, A., Kesani, A., Aslam, N., Goodship, A., & Bentley, G. (2005).The effects of hyaluronic acid on articular chondrocytes. *Bone & Joint Journal*, 87(8), 1143-1149.
- Anderson, I. (2001). The properties of hyaluronan and its role in wound healing. *Professional nurse (London, England)*, 17(4), 232-235.
- Aya, K. L., & Stern, R. (2014). Hyaluronan in wound healing: rediscovering a major player. *Wound Repair and Regeneration*, 22(5), 579-593.
- Balazs, E. A., & Denlinger, J. L. (1989). Clinical uses of hyaluronan. In *The biology of hyaluronan*. Wiley-Interscience New York, USA, (Vol. 143, pp. 265-280).
- Bentkover, S. H. (2009).The biology of facial fillers. *Facial Plastic Surgery*, 25(02), 073-085.
- Bertolami, C. N., Gay, T., Clark, G. T., Rendell, J., Shetty, V., Liu, C., & Swann, D. A. (1993). Use of sodium hyaluronate in treating temporomandibular joint disorders: a randomized, double-blind, placebo-controlled clinical trial. *Journal of Oral and Maxillofacial Surgery*, 51(3), 232-242.
- Bogović, A., Nizetić, J., Galić, N., Želježić, D., Micek, V., & Mladinić, M. (2011). The effects of hyaluronic acid, calcium hydroxide, and dentin adhesive on rat odontoblasts and fibroblasts. *Archives of Industrial Hygiene and Toxicology*, 62(2), 155-161.
- Brandt, F. S., & Cazzaniga, A. (2008). Hyaluronic acid gel fillers in the management of facial aging. *Clinical Interventions in Aging*, 3(1), 153.
- Brody, H. J. (2005). Use of hyaluronidase in the treatment of granulomatous hyaluronic acid reactions or unwanted hyaluronic acid misplacement. *Dermatologic surgery*, 31(8), 893-897.
- Brown, M. B., & Jones, S. A. (2005). Hyaluronic acid: a unique topical vehicle for the localized delivery of drugs to the skin. *Journal of the European Academy of Dermatology and Venereology*, 19(3), 308-318.

- Buck, D. W., Alam, M., & Kim, J. Y. (2009). Injectable fillers for facial rejuvenation: a review. *Journal of Plastic, Reconstructive & Aesthetic Surgery*, 62(1), 11-18.
- Buckwalter, J. A., Mankin, H. J., & Grodzinsky, A. J. (2005). Articular cartilage and osteoarthritis. *Instructional Course Lectures-American Academy of Orthopaedic Surgeons*, 54, 465-480.
- Cantore, S., Ballini, A., Nardi, G., Tetè, S., Mastrangelo, F., Perillo, L., & Grassi, F. (2010). Use of hyaluronic acid in periodontal disease. *Journal of Orthopaedic*, 2(1-3), 1-8.
- Carruthers, A., & Carruthers, J. (2012). *Botulinum Toxin: Procedures in Cosmetic Dermatology Series* (3rd Edition). Elsevier Health Sciences. China, 1-5.
- Cascone, P., Fonzi, L., & Aboh, I. V. (2002). Hyaluronic acid's biomechanical stabilization function in the temporomandibular joint. *Journal of Craniofacial Surgery*, 13(6), 751-754.
- Champion, J. A., & Mitragotri, S. (2006). Role of target geometry in phagocytosis. *Proceedings of the National Academy of Sciences of the United States of America*, 103(13), 4930-4934.
- Champion, J. A., Walker, A., & Mitragotri, S. (2008). Role of particle size in phagocytosis of polymeric microspheres. *Pharmaceutical research*, 25(8), 1815-1821.
- Choi, K. Y., Saravanakumar, G., Park, J. H., & Park, K. (2012). Hyaluronic acid-based nanocarriers for intracellular targeting: interfacial interactions with proteins in cancer. *Colloids and Surfaces B: Biointerfaces*, 99, 82-94.
- Cohen, J. L. (2008). Understanding, avoiding, and managing dermal filler complications. *Dermatologic Surgery*, 34(1), 92-99.
- Cowman, M. K., & Matsuoka, S. (2005). Experimental approaches to hyaluronan structure. *Carbohydrate Research*, 340(5), 791-809.
- Cox, S. E., & Adigun, C. G. (2011). Complications of injectable fillers and neurotoxins. *Dermatologic therapy*, 24(6), 524-536.
- Curi, M. M., Cardoso, C. L., Curra, C., Koga, D., & Benini, M. B. (2015). Late-Onset Adverse Reactions Related to Hyaluronic Acid Dermal Filler for Aesthetic Soft Tissue Augmentation. *Journal of Craniofacial Surgery*, 26(3), 782-784.
- De Araújo Nobre, M., Carvalho, R., & Malo, P. (2009). Non surgical treatment of peri-implant pockets: An exploratory study comparing 0.2% chlorhexidine and 0.8% hyaluronic acid. *Can J Dental Hygiene* 43 (1), 25-30.
- De Araújo Nobre, M., Cintra, N., & Maló, P. (2007). Peri-implant maintenance of immediate function implants: a pilot study comparing hyaluronic acid and chlorhexidine. *International Journal of Dental hygiene*, 5(2), 87-94.
- Dechert, T. A., Ducale, A. E., Ward, S. I., & Yager, D. R. (2006). Hyaluronan in human acute and chronic dermal wounds. *Wound Repair and Regeneration*, 14(3), 252-258.
- DeLorenzi, C. (2013). Complications of injectable fillers, part I. *Aesthetic Surgery Journal*, 33(4), 561-575.
- DeLorenzi, C. (2014). Complications of injectable fillers, part 2: vascular complications. *Aesthetic Surgery Journal*, 34(4), 584-600.
- Duranti, F., Salti, G., Bovani, B., Calandra, M., & Rosati, M. L. (1998). Injectable hyaluronic acid gel for soft tissue augmentation. *Dermatologic surgery*, 24(12), 1317-1325.

- Edwards, P. C., & Fantasia, J. E. (2007). Review of long-term adverse effects associated with the use of chemically-modified animal and nonanimal source hyaluronic acid dermal fillers. *Clinical Interventions in Aging*, 2(4), 509.
- Ellis, I. R., & Schor, S. L. (1996). Differential effects of TGF- β 1 on hyaluronan synthesis by fetal and adult skin fibroblasts: implications for cell migration and wound healing. *Experimental cell research*, 228(2), 326-333.
- Embery, G., Oliver, W. M., Stanbury, J. B., & Purvis, J. A. (1982). The electrophoretic detection of acidic glycosaminoglycans in human gingival sulcus fluid. *Archives of Oral Biology*, 27(2), 177-179.
- Embery, G., Waddington, R. J., Hall, R. C., & Last, K. S. (2000). Connective tissue elements as diagnostic aids in periodontology. *Periodontology 2000*, 24(1), 193-214.
- Esposito, A., Mezzogiorno, A., Sannino, A., De Rosa, A., Menditti, D., Esposito, V., & Ambrosio, L. (2006). Hyaluronic acid based materials for intestine tissue engineering: A morphological and biochemical study of cell-material interaction. *Journal of Materials Science: Materials in Medicine*, 17(12), 1365-1372.
- Fakhari, A., & Berkland, C. (2013). Applications and emerging trends of hyaluronic acid in tissue engineering, as a dermal filler and in osteoarthritis treatment. *Acta biomaterialia*, 9(7), 7081-7092.
- Foschi, D., Castoldi, L., Radaelli, E., Abelli, P., Calderini, G., Rastrelli, A., ...& Trabucchi, E. (1989). Hyaluronic acid prevents oxygen free-radical damage to granulation tissue: a study in rats. *International Journal of Tissue Reactions*, 12(6), 333-339.
- Fraser, J. R. E., & Laurent, T. C. (1989). Turnover and metabolism of hyaluronan. In *Ciba Foundation Symposium 143-The Biology of Hyaluronan*. John Wiley & Sons, Ltd., Chichester, UK. 41-59.
- Fraser, J. R. E., Laurent, T. C., & Laurent, U. B. G. (1997). Hyaluronan: its nature, distribution, functions and turnover. *Journal of Internal Medicine*, 242(1), 27-33.
- Funt, D., & Pavicic, T. (2015). Dermal fillers in aesthetics: an overview of adverse events and treatment approaches. *Plastic Surgical Nursing*, 35(1), 13-32.
- Ghatak, S., Misra, S., & Toole, B. P. (2002). Hyaluronan oligosaccharides inhibit anchorage-independent growth of tumor cells by suppressing the phosphoinositide 3-kinase/Akt cell survival pathway. *Journal of Biological Chemistry*, 277(41), 38013-38020.
- Gold, M. H. (2007). Use of hyaluronic acid fillers for the treatment of the aging face. *Clinical Interventions in Aging*, 2(3), 369.
- Gold, M. H. (2010). What's New in Fillers in 2010?. *Journal of Clinical & Aesthetic Dermatology*, 3(8).
- Greco, T. M., & Elenitsas, R. (2010). Localization and histological characterization of injected hyaluronic acid in excised nasolabial fold tissue. *Journal of drugs in dermatology: JDD*, 9(4), 399-404.
- Gupta, G. (2012). Gingival crevicular fluid as a periodontal diagnostic indicator-I: Host derived enzymes and tissue breakdown products. *Journal of Medicine and Life*, 5(4), 390.
- Hirota, W. (1998). Intra-articular injection of hyaluronic acid reduces total amounts of leukotriene C 4, 6-keto-prostaglandin F 1 α , prostaglandin F 2 α and interleukin-1 β in synovial fluid of patients with internal derangement in

- disorders of the temporomandibular joint. *British Journal of Oral and Maxillofacial Surgery*, 36(1), 35-38.
- Homandberg, G. A. (2001). Cartilage damage by matrix degradation products: fibronectin fragments. *Clinical Orthopaedics and Related Research*, 391, 100-107.
- Homandberg, G. A., Hui, F., Wen, C., Kuettner, K. E., & Williams, J. M. (1997). Hyaluronic acid suppresses fibronectin fragment mediated cartilage chondrolysis: I. In vitro. *Osteoarthritis and Cartilage*, 5(5), 309-319.
- Horkay, F., Bassar, P. J., Londono, D. J., Hecht, A. M., & Geissler, E. (2009). Ions in hyaluronic acid solutions. *The Journal of Chemical Physics*, 131(18), 184902.
- Hunt, D. R., Jovanovic, S. A., Wikesjö, U. M., Wozney, J. M., & Bernard, G. W. (2001). Hyaluronan supports recombinant human bone morphogenetic protein-2 induced bone reconstruction of advanced alveolar ridge defects in dogs. A pilot study. *Journal of Periodontology*, 72(5), 651-658.
- Inuyama, Y., Kitamura, C., Nishihara, T., Morotomi, T., Nagayoshi, M., Tabata, Y., ...& Terashita, M. (2010). Effects of hyaluronic acid sponge as a scaffold on odontoblastic cell line and amputated dental pulp. *Journal of Biomedical Materials Research Part B: Applied Biomaterials*, 92(1), 120-128.
- Jentsch, H., Pomowski, R., Kundt, G., & Göcke, R. (2003). Treatment of gingivitis with hyaluronan. *Journal of clinical periodontology*, 30(2), 159-164.
- John, H. E., & Price, R. D. (2009). Perspectives in the selection of hyaluronic acid fillers for facial wrinkles and aging skin. *Patient preference and adherence*, 3, 225-230.
- Kahmann, J. D., O'Brien, R., Werner, J. M., Heinegård, D., Ladbury, J. E., Campbell, I. D., & Day, A. J. (2000). Localization and characterization of the hyaluronan-binding site on the link module from human TSG-6. *Structure*, 8(7), 763-774.
- Kumar, V., Abbas, A. K., & Aster, J. C. (2012). *Robbins Basic Pathology*, (9th Edition). Elsevier Health Sciences. Philadelphia, PA, 29-74.
- Lafaille, P., & Benedetto, A. (2010). Fillers: contraindications, side effects and precautions. *Journal of Cutaneous and Aesthetic Surgery*, 3(1), 16.
- Laurent, T. C. (1995). An early look at macromolecular crowding. *Biophysical chemistry*, 57(1), 7-14.
- Laurent, T. C. (Ed.). (1998). The chemistry, Biology and Medical Applications of Hyaluronan And Its Derivatives. *Portland Press, London*. 72, 235-242.
- Laurent, T. C., & Fraser, J. R. E. (1991). Catabolism of hyaluronan. *Degradation of bioactive substances: Physiology and pathophysiology*. CRC Press. Boca, Raton, Florida, 249-264.
- Leach, J. B., Bivens, K. A., Collins, C. N., & Schmidt, C. E. (2004). Development of photocrosslinkable hyaluronic acid-polyethylene glycol-peptide composite hydrogels for soft tissue engineering. *Journal of Biomedical Materials Research Part A*, 70(1), 74-82.
- Lee, J. M., & Kim, Y. J. (2015). Foreign body granulomas after the use of dermal fillers: pathophysiology, clinical appearance, histologic features, and treatment. *Archives of plastic surgery*, 42(2), 232-239.
- Lemperle, G., Gauthier-Hazan, N., Wolters, M., Eisemann-Klein, M., Zimmermann, U., & Duffy, D. M. (2009). Foreign body granulomas after all injectable dermal fillers: part 1. Possible causes. *Plastic and reconstructive surgery*, 123(6), 1842-1863.

- Lemperle, G., Morhenn, V., & Charrier, U. (2003). Human histology and persistence of various injectable filler substances for soft tissue augmentation. *Aesthetic Plastic Surgery*, 27(5), 354-366.
- Lowe, N. J., Maxwell, C. A., & Patnaik, R. (2005). Adverse reactions to dermal fillers: review. *Dermatologic surgery*, 31(4), 1626-1633.
- Lowe, N. J., Maxwell, C. A., Lowe, P., Duickb, M. G., & Shah, K. (2001). Hyaluronic acid skin fillers: adverse reactions and skin testing. *Journal of the American Academy of Dermatology*, 45(6), 930-933.
- Mangla, B., Joshi, S. K., Khanna, K., Kapoor, P., & Kukreja, I. (2015). Hyaluronic Acid: The Ingenious Molecule. *Biopharm Journal*, 1(2), 64-70.
- Marusza, W., Mlynarczyk, G., Olszanski, R., Netsvyetayeva, I., Obrowski, M., Iannitti, T., & Palmieri, B. (2012). Probable biofilm formation in the cheek as a complication of soft tissue filler resulting from improper endodontic treatment of tooth 16. *International Journal of Nanomedicine*, 7, 1441.
- Matarasso, S. L., Carruthers, J. D., & Jewell, M. L. (2006). Consensus recommendations for soft-tissue augmentation with nonanimal stabilized hyaluronic acid (Restylane). *Plastic and Reconstructive Surgery*, 117(3), 3-34.
- Mendes, R. M., Silva, G. A., Lima, M. F., Calliari, M. V., Almeida, A. P., Alves, J. B., & Ferreira, A. J. (2008). Sodium hyaluronate accelerates the healing process in tooth sockets of rats. *Archives of Oral Biology*, 53(12), 1155-1162.
- Mercer, S. E., Kleinerman, R., Goldenberg, G., & Emanuel, P. O. (2010). Histopathologic identification of dermal filler agents. *Journal of Drugs in Dermatology: JDD*, 9(9), 1072-1078.
- Mesa, F. L., Aneiros, J., Cabrera, A., Bravo, M., Caballero, T., Revelles, F., ...& O'Valle, F. (2002). Antiproliferative effect of topic hyaluronic acid gel. Study in gingival biopsies of patients with periodontal disease. *Histology and Histopathology*, 17, 0213-3911.
- Micheels, P. (2001). Human Anti-Hyaluronic Acid Antibodies: Is it Possible?. *Dermatologic surgery*, 27(2), 185-191.
- Miyauchi, S., Sugiyama, T., Machida, A., Sekiguchi, T., Miyazaki, K., Tokuyasu, K., & Nakazawa, K. (1990). The effect of sodium hyaluronate on the migration of rabbit corneal epithelium. I. An in vitro study. *Journal of Ocular Pharmacology and Therapeutics*, 6(2), 91-99.
- Monheit, G. D., & Coleman, K. M. (2006). Hyaluronic acid fillers. *Dermatologic therapy*, 19(3), 141-150.
- Moreland, L. W. (2003). Intra-articular hyaluronan (hyaluronic acid) and hylans for the treatment of osteoarthritis: mechanisms of action. *Arthritis Res Ther*, 5(2), 1.
- Necas, J., Bartosikova, L., Brauner, P., & Kolar, J. (2008). Hyaluronic acid (hyaluronan): a review. *Veterinarni medicina*, 53(8), 397-411.
- Newman, J. (2009). Review of soft tissue augmentation in the face. *Clin Cosmet Investig Dermatol*, 2, 141-150.
- Olczyk et al., 2008 Farahani, S., Sexton, J., Stone, J. D., Quinn, K., & Woo, S. B. (2012). Lip nodules caused by hyaluronic acid filler injection: report of three cases. *Head and Neck Pathology*, 6(1), 16-20.
- Pagnacco, A., Vangelisti, R., Erra, C., & Poma, A. (1997). Double-blind clinical trial vs. placebo of a new sodium-hyaluronate-based gingival gel. *Attualita Terapeutica Internazionale*, 15, 1-7. "English Abstract".
- Papakonstantinou, E., Roth, M., & Karakiulakis, G. (2012). Hyaluronic acid: A key molecule in skin aging. *Dermato-endocrinology*, 4(3), 253-258.

- Pinsky, M. A., Thomas, J. A., Murphy, D. K., Walker, P. S., & Juvéderm vs. Zyplast Nasolabial Fold Study Group. (2008). Juvéderm injectable gel: a multicenter, double-blind, randomized study of safety and effectiveness. *Aesthetic Surgery Journal*, 28(1), 17-23.
- Rajan, P., Nair, D., Kumar, C. S., & Dusanapudi, L. N. (2013). Hyaluronic acid-a simple, unusual polysaccharide: A potential mediator for periodontal regeneration. *Universal Research Journal of Dentistry*, 3(3), 113.
- Rongioletti, F., & Rebora, A. (2003). Cutaneous reactive angiomatoses: patterns and classification of reactive vascular proliferation. *Journal of the American Academy of Dermatology*, 49(5), 887-896.
- Ryssel, H., Germann, G., & Koellensperger, E. (2012). An overview of current biomaterials in aesthetic soft tissue augmentation. *European Journal of Plastic Surgery*, 35(2), 121-133.
- Saranraj, P. (2014). Hyaluronic Acid Production and its Applications A Review. *International Journal of Pharmaceutical & Biological Archive*, 4(5), 14.
- Sasaki, T., & Kawamata-Kido, H. (1995). Providing an environment for reparative dentine induction in amputated rat molar pulp by high molecular-weight hyaluronic acid. *Archives of Oral Biology*, 40(3), 209-219.
- Schweiger, E. S., Riddle, C. C., Tonkovic-Capin, V., & Aires, D. J. (2008). Successful treatment with injected hyaluronic acid in a patient with lip asymmetry after surgical correction of cleft lip. *Dermatologic Surgery*, 34(5), 717-719.
- Scott, J. E., & Heatley, F. (2002). Biological properties of hyaluronan in aqueous solution are controlled and sequestered by reversible tertiary structures, defined by NMR spectroscopy. *Biomacromolecules*, 3(3), 547-553.
- Singh, A., Corvelli, M., Unterman, S. A., Wepasnick, K. A., McDonnell, P., & Elisseff, J. H. (2014). Enhanced lubrication on tissue and biomaterial surfaces through peptide-mediated binding of hyaluronic acid. *Nature materials*, 13(10), 988-995.
- Smith, K. C. (2008). Reversible vs. nonreversible fillers in facial aesthetics: concerns and considerations. *Dermatology Online Journal*, 14(8).
- Stern, R. (2003). Devising a pathway for hyaluronan catabolism: are we there yet?. *Glycobiology*, 13(12), 105-115.
- Sudha, P. N., & Rose, M. H. (2014). Beneficial effects of hyaluronic acid. *Advances in Food and Nutrition Research*, 72, 137-176.
- Sukumar, S., & Drizhal, I. (2007). Hyaluronic acid and periodontitis. *Acta Medica (Hradec Kralove)*, 50(4), 225. "English Abstract".
- Tamer, T. M. (2013). Hyaluronan and synovial joint: function, distribution and healing. *Interdisciplinary toxicology*, 6(3), 111-125.
- Tammi, R., Rilla, K., Pienimäki, J. P., MacCallum, D. K., Hogg, M., Luukkonen, M., ...& Tammi, M. (2001). Hyaluronan enters keratinocytes by a novel endocytic route for catabolism. *Journal of Biological Chemistry*, 276(37), 35111-35122.
- Tezel, A., & Fredrickson, G. H. (2008). The science of hyaluronic acid dermal fillers. *Journal of Cosmetic and Laser Therapy*, 10(1), 35-42.
- Thonar, E. M., Masuda, K., Manicourt, D. H., & Kuettner, K. E. (1999). Structure and function of normal human adult articular cartilage. In *Osteoarthritis*. Springer, Berlin Heidelberg. 1-19.

- Tolg, C., Telmer, P., & Turley, E. (2014). Specific sizes of hyaluronan oligosaccharides stimulate fibroblast migration and excisional wound repair. *PLoS one*, 9(2), 88479.
- Toole, B. P. (2013). Proteoglycans and Hyaluronan in Morphogenesis and Differentiation. *Cell Biology of Extracellular Matrix*, (2nd Edition). Springer US. New York.305-341.
- Toole, B. P., & Hascall, V. C. (2002).Hyaluronan and tumor growth. *The American Journal of Pathology*, 161(3), 745-747.
- Tran, C., Carraux, P., Micheels, P., Kaya, G., & Salomon, D. (2013). In vivo bio-integration of three hyaluronic acid fillers in human skin: a histological study. *Dermatology*, 228(1), 47-54.
- Tripathi, K. D. (2013). Essentials of medical pharmacology. *Indian Journal of Pharmacology*, 26(2), 166.
- Trommer, H., Wartewig, S., Böttcher, R., Pöppl, A., Hoentsch, J., Ozegowski, J. H., & Neubert, R. H. (2003). The effects of hyaluronan and its fragments on lipid models exposed to UV irradiation. *International journal of pharmaceutics*, 254(2), 223-234.
- Vedamurthy, M. (2008). Standard guidelines for the use of dermal fillers. *Indian Journal of Dermatology, Venereology, and Leprology*, 74(7), 23.
- Zimmermann, U. S., & Clerici, T. J. (2004).The histological aspects of fillers complications. In *Seminars in cutaneous medicine and surgery*. Elsevier Science, 23(4), 241-250.
- Wang, F., Garza, L. A., Kang, S., Varani, J., Orringer, J. S., Fisher, G. J., & Voorhees, J. J. (2007). In vivo stimulation of de novo collagen production caused by cross-linked hyaluronic acid dermal filler injections in photodamaged human skin. *Archives of Dermatology*, 143(2), 155-163.
- Weidmann, M. J. (2009). New hyaluronic acid filler for Subdermal and long-lasting volume restoration of the face. *European Dermatology*, 1, 65-68.
- Zimmermann, U. S., & Clerici, T. J. (2004).The histological aspects of fillers complications. In *Seminars in cutaneous medicine and surgery*. Elsevier Science, 23(4), 241-250.