

How to Cite:

Hussain. A, K., Parvathavarthine, C., Yoganandham , J., & Janaki , C. (2022). A morphological and morphometric analysis of the facets and the retroarticular groove of Atlas vertebra. *International Journal of Health Sciences*, 6(S7), 6749-6756. Retrieved from <https://sciencescholar.us/journal/index.php/ijhs/article/view/13804>

A morphological and morphometric analysis of the facets and the retroarticular groove of Atlas vertebra

Kafeel Hussain. A

Professor & Head, Department of Anatomy, Bhaarath Medical College and Hospital ,Bharath Institute of higher Education and Research

CR. Parvathavarthine

Associate Professor, Department of Anatomy, Bhaarath Medical College and Hospital ,Bharath Institute of higher Education and Research

Janani Yoganandham

Associate Professor, Department of Anatomy, Bhaarath Medical College and Hospital ,Bharath Institute of higher Education and Research

CS. Janaki

Associate Professor, Department of Anatomy, Bhaarath Medical College and Hospital ,Bharath Institute of higher Education and Research

Abstract--Introduction: An insight into the variable features of the atlas vertebra is indispensable to perform an array of spinal surgeries. This study is designed with the intent to ascertain a secure loci for these interventions. Aim and Objective: 1. To ascertain the incidence of retroarticular groove or canals 2. To determine the dimensions of the superior and inferior articular facets. 3. To observe the morphological differences in the shape of the facets. Materials and Methods: A cross sectional study on 116 adult atlas bones. The Morphometric measurements of the atlas were performed with a vernier caliper. The greatest anterior-posterior (AP) & transverse (T) diameter of Superior & inferior articular facets on both the sides will be measured and the morphometric data thus obtained was statistically analyzed by SPSS software version 23 using a paired t test. Observation and Results: The shape of the superior facets were mostly reniform (36.2%) on the left and dumb-bell shaped (34.4 %) on the right. Complete separation was seen in 5.1% (Right) and 3.4% (left). No difference in the dimensions of the superior and inferior articular facets of either sides was noted. It was observed that the Inferior facets were majorly rounded on both the sides. The presence of retroarticular groove was witnessed in 4 (3.4%) on the right and 2

(1.7%) on the left . The Retroarticular canal was seen in 2(1.7%) (right) & none on left . Two cases of Incomplete foramen transversarium were observed on the left 4(3.4%). Presence of bony spurs in the Anterior arch was noticed in 6 (5.7%). Conclusion: This study provides insight for the safe planning of internal fixation for craniovertebral junction abnormalities which aids in reducing postoperative complications such as vertebral artery and cord injuries.

Keywords---retro articular groove, retro articular canal, articular facets

Introduction

Atlas is foremost vertebra in the cervical region. Atlas is a component of the Cranio-vertebral Junction (CVJ) which consists of occiput, foramen magnum, C1 and C2 vertebra. The lateral masses bear facets both above and below. The anatomy these facets exhibit extensive variability in their morphometry. The posterior arch on its upper surface has a groove (for vertebral artery and C1 nerve). Ponticles often emerge from the margins of the groove transforming it to a foramen. Ponticles could form Retro lenticular vertebral artery Ring [1]. The vertebral artery on its course to the cranial cavity from the foramen transversarium faces the brunt of bony or ligamentous factors (retro-articular canal) that may compress the vertebral artery. The pressure laid on the vertebral artery could lead to vertebro basilar insufficiency. An insight into the variable features of the atlas vertebra is indispensable to perform an array of spinal. This study is designed with the intent to assess and decide the safe locations for the different surgical methods. This study is designed with the intent to ascertain a secure loci for these interventions.

The Atlas is distinct from the other cervical vertebra and also the most diverse. Atlas vertebra is intervened in an array of spinal surgeries. Various literatures on the atlas vertebrae are available but retroarticular groove and foramina have hardly been the focus of any [2]. Compression of vertebral artery in the Retroarticular groove or canal has been documented to cause CVA [3] Traumatic injuries of the incomplete canals could also displace the vertebral artery. An insight into the incidence of variations assist the clinicians and forensic experts [4,5]. The Retroarticular groove/ canal was deciphered foremost by Velenae [6] followed by Gupta [7] and Bilodi [8]. Incomplete canal could dislodge the vertebral artery from position in cervical injuries. These variations could also be misread as fractures in imaging.

Objective:

1. To ascertain the incidence of retroarticular groove or canals
2. To determine the dimensions of the superior and inferior articular facets.
3. To scrutinize the variations in the shape of the facets.

Materials and Methods:

A cross sectional study of 116 adult dry atlas vertebra was performed in the Anatomy department of Bhaarith Medical College from July 2021 to July 2022. The Superior & Inferior articular facets on both the sides were keenly observed for their shape. The side of constriction of the facets and tendency for separation of the facets was also looked for. The atlas was investigated for a retroarticular groove/canal and any abnormalities would be noted down and photographed. Morphometric measurements of the atlas were performed using a vernier caliper. The greatest anterior- posterior (AP) & transverse (T) diameter of Superior & Inferior articular facets on both the sides will be measured and the morphometric data thus obtained was statistically analyzed by SPSS software version 23 using a paired t test.

Exclusion criteria: Worn out, cracked and fragmented bones.

Observation and Results:

In the current study, of the 116 superior facets studied, 38 (32.7%) (right) and 32 (27.5%) (left) depicted no constriction. They were classified "oval". On the right side, 32 (27.5%) were reniform or kidney shaped. Of which 20 (17.2%) portrayed a constriction on the medial (Fig.1) and 12 (10.3 %) on the Lateral aspect respectively. On the Left side, 42 (36.2%) were reniform or kidney shaped and were considered as kidney shaped of which medial and lateral constriction was portrayed by 24 (20.6%) and 18 (15.5%) respectively. The superior facets (Right) were dumb-bell like in 40 (34.4 %) .They were found to have a constriction on both the sides (Fig.2). 38 (32.7 %) showed similar features on the left. Complete separation was seen in 6 (5.1%) (Right) and 4 (3.4%) (left) (Fig.1).

Transverse diameter of superior facet was observed as 12.24 mm (right) & 11.75 mm (left) (P value 0.18). The Anteriorposterior diameter of superior facet was 21.11 mm(right) and 20.56 mm (left) (P value 0.31). Hence, no significant difference in the dimensions of the Superior facets of either sides was noticed (Table1).

It was observed that the Inferior facets were rounded (Fig.3) in 58 (50%) on the right and 62 (53.4%) on the left. They were pear or drop shaped (Fig.4) in 38 (32.7%) (right) and 36 (31%) (left). Triangular facets were observed in 20 (17.2%)(right side) and 18 (15.5%)(Left).

The Anterior-posterior (A-P) and transverse diameter of Inferior facet was 17.31 mm (right) and 17.22 mm (left) (P value 0.6). The Transverse diameter of Inferior facet was 14.72 mm (right) and 20.56 mm (left) (P value 0.17). Hence, no significant difference in the dimensions of the Inferior facets on either sides (Table2).

The presence of retroarticular groove was witnessed in 4 (3.4%) on the right (Fig.5) and 2 (1.7%) on the left. The Retroarticular canal was seen in 2(1.7%) on the right (Fig.6) and none the left. Two cases of Incomplete foramen

transversarium (Fig.7) were observed on the left side 4(3.4%). Presence of bony spurs in the Anterior arch (Fig.8) was observed in 6 (5.7%).

Discussion:

In the present study, difference in the anteriorposterior dimension of superior facet of both the sides was not significant. While the diameters documented by Sengul et al [5] were lower. Konig and Gomez et al [9,10] reported relatively larger values. The current findings were comparable with Kaur & Gosavi et al [11,12]. Woodjones [13] documented that the dimensions in the European race were the largest and much larger than Indian subjects.

The difference in the transverse diameter of superior facet between the two sides was insignificant. Sengul and Gomez et al [4,10] recorded subjacent values than ours.

The constriction on the facets of both the sides presented elevated values in the present study, in relation to Singh & Lalit et al [14,15]. Constrictions witnessed on the facets (either sides) had a lower value in comparison to Singh and Lalit et al [14,15].

A constriction or groove signals the proneness of facet to cleave. A complete facet separation on either side was witnessed in 5.1% (Right) and 3.4% (left). The parameters currently observed are higher in relation to Singh et al. [14]. C1 vertebra develops from occipital somite 4 and cervical somite 1 [16]. The anterior arch emerges from the fusion of lateral mass centres and the superior facet (posterior part) develops from the posterior arch. The distinct origin of the facet reasons out their dissociation.[17]. The proneness of the Superior facet to divide, predisposes the atlantooccipital joint for restricted mobility[3]. Their varied shapes signal movement restriction at the joint. [3].

Singh and Manjunath et al. [14,1] frequently reported combined dumbbell and irregular shaped (39%) facets respectively.

The retroarticular groove incidence currently deciphered was relatively lower than earlier documentations by Velenae and Malukar et al [6,18]. This difference in incidence could be attributed to the variation in the sample size. Dual retroarticular groove/canal was not encountered in this study. Ponticles arise from the remains of proatlas or calcification of atlantooccipital membrane [7]. Ponticles predisposes an individual to vertebrobasilar insufficiency. Vertebral artery (left) have greater dimensions and hence susceptible to compression [19]. The Vertebrae in this study, frequently presented ponticles on the right, thereby putting the vertebral artery (Right) at risk for compression.

Incomplete foramen transversarium could be misread as fractures or anomalies in imaging studies.

The standard text-books depict a rounded inferior articular facet but it was observed that the facet shape was variable with pear and triangular being the commonest.

Conclusion:The shape and dimensions of the articular facets is are precursors for internally fixing CV junction abnormalities. This information aids the safe planning of surgical interventions and abbreviating complications like injury of the spinal cord and vertebral artery.

Table .1

Side	Superior Articular Facet						
	Shape					Mean A-P diameter (mm)	Mean Transverse diameter (mm)
	Oval	Kidney /Reniform		Dumb-bell shaped	Complete separation		
Medial Constriction		Lateral Constriction	Bilateral Constriction				
Right	38 (32.7%)	20 (17.2%)	12 (10.3 %)	40 (34.4 %)	6 (5.1%)	21.11	12.24
Left	32 (27.5%)	24 (20.6%)	18 (15.5%)	38 (32.7 %)	4 (3.4%)	20.56	11.75

Table .2

Side	Inferior Articular facet				Mean A-P Diameter (mm)	Mean Transverse diameter (mm)	Retroarticular groove	Retroarticular canal
	Shape							
	Round	Pear	Triangular					
Right	58 (50%)	38 (32.7%)	20 (17.2%)	17.31	14.72	4 (3.4%)	2(1.7%)	
Left	62 (53.4%)	36 (31%)	18 (15.5%)	17.22	15.63	2 (1.7%)	0 (0%)	

**Fig.1 Complete separation of the Left SAF Fig.2 Dumble shaped superior articular facets
Reniform Right SAF
(constriction on the medial side)**

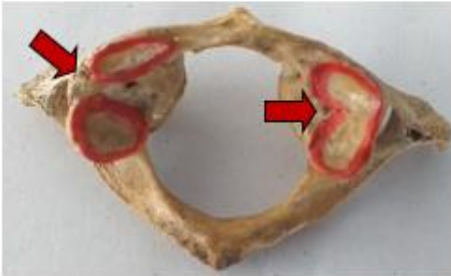

Fig.3 Round shaped Inferior Articular Facets Fig.4 Pear shaped Inferior Articular Facets

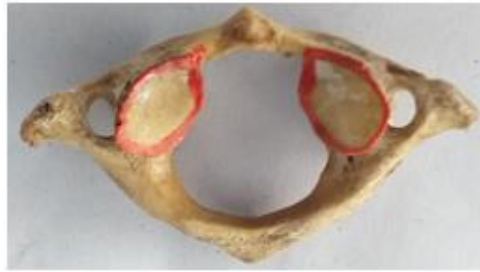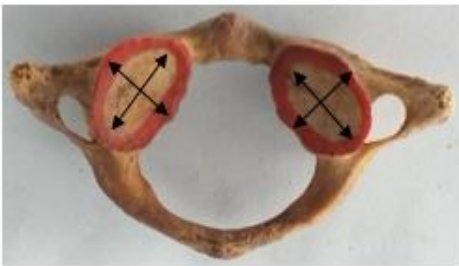


Fig.5 Retroarticular groove on the right side Fig.6 Retroarticular canal on the right side

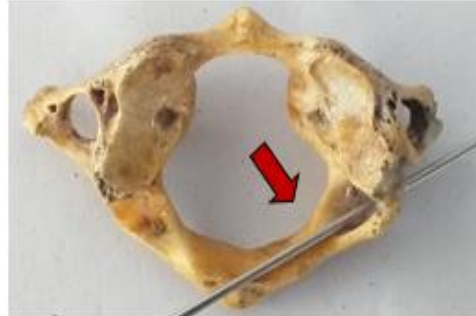
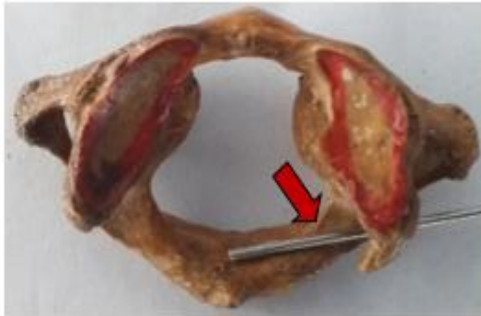
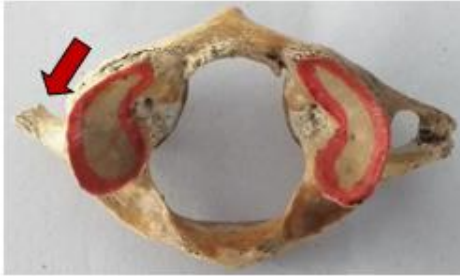Fig.7 Incomplete foramen transversarium**Fig.8 Spur on the Anterior Arch****References:**

1. Manjunath KY. Posterior bridging of the atlas vertebra in South Indians. *Incl. J Med. Sci.* 2001;55(9):488-90.
2. Chauhan R, Khanna J. Absence of costal element of the foramen transversarium of atlas vertebrae. *Int J Res Med Sci.* 2013;1:66-8.
3. Krishnamurthy, Nayak SR, Khan S, Prabhu La Tha V, Lakshmi A, et al. References : Arcuate foramen of atlas: incidence, phylogenetic and clinical significance. *Romanian Journal of Morphology and Embryology.* 2007;48(3):263-66.
4. Agrawal D, Mohanty BB, Shetty S, Parija B, Hazary SK and China a PK. Variations in foramen transversarium: An osteological study in eastern India. *Int J of current research.*2012;4(9):120-122.
5. Senguel G, Kadioglu HH. Morphometric Anatomy of the atlas and axis vertebrae. *Turkish Neuroanatomy.* 2006;16(2):69-76.
6. Velenae C, Barzu S, Panescu S and Udriou C, Retrotransverse groove or canal of atlas and its significance. *Acta Anatomica Basel.* 1997;97:400-2.
7. Gupta SC, Gupta CD, Arora HK, Maheshwari BB. The retro transverse groove/canal in Indian Atlas vertebral. *Anat Anz.* 1979;145:514-16.
8. Bilodi AK and Gupta SC. Presence of retrotransverse groove or canal in atlas vertebrae. *J. Anat Soc. Ind.* 2005;54(1):16-18.
9. Konig SA, Goldammer A, Vitzthum HE. Anatomical data on the craniocervical junction and their correlation with degenerative changes in 30 cadaveric specimens. *J Neurosurg Spine.*2005;3:379-85.
10. Gomez-Olivencia A, Carretero JM, Arsuaga JL, Rodriguez-Garcia L, Garcia-Gonzalez R, Martinez I. Metric and morphological study of the upper cervical spine from Sima de los Huesos site (Sierrade Atapuerca, Burgos, Spain). *J Hum Evol.*2007;53:6-25.
11. Kaur Jasveen, Grewal Harsimran , Singh Poonam, Kumar Ajay . Morphometric study of the articular facets of atlas and axis vertebrae. *Unique Journal of Medical and Dental Sciences.* 2014;02(02):83-89
12. Shilpa N Gosavi, Vatsalaswamy P. Morphometric Study of the Atlas Vertebra using Manual Method. *Malaysian Orthopaedic Journal.* 2012;6(3):18-20.
13. Wood-Jones F. The cervical vertebrae of the Australian native. *J. Anat.* 1938;72(3):411-5.
14. Shamer Singh. Variations of the superior articular facets of atlas vertebrae. *Journal of Anatomy.* 1965;99:565-71.

15. Lalit M, Piplani S, Kullar JS, Arora AK, Mannan R. The morphological analysis of the superior articular facet of the adult human atlas vertebra. *JCDR*. 2011 April; 5(2):274-7.
16. Newell RL, Collins P. Development of the Back. In Standring S, editor. *Gray's Anatomy, the Anatomical Basis of Clinical Practice*. 40 th ed. Churchill Livingstone Elsevier; 2008;763-73.
17. Paraskevas G, Papaziogas B, Traveas A, Natsis K, Spanidou S, Kitsoulis P. Morphological parameters of the superior articular facets of the atlas and potential clinical significance. *Surg Radiol Anat*. 2008;30:611-7.
18. Malukar O, Prajapati VP, Nagar SK. Ponticulus. *J of Med. Res*. 2011;1(2):51-5.
19. Thiel H. Gross morphology and pathoanatomy of the vertebral arterier. *J Manipulat Physiol, Ther*. 1991;14:133-41.