

How to Cite:

Jabeen, H., Ahmed, S., Khan, S. S., Ansari, Y. A., Luni, A., & Tariq, A. (2023). Impact of surgical timing of postoperative ocular motility in orbital blowout fractures. *International Journal of Health Sciences*, 7(S1), 1797–1802. <https://doi.org/10.53730/ijhs.v7nS1.14398>

Impact of surgical timing of postoperative ocular motility in orbital blowout fractures

Hina Jabeen

Assistant professor in the department of Oral and Maxillofacial Surgery, Bahria University Medical and Dental College, Pakistan

Corresponding author email: dr.hina.jabeen@gmail.com

Sufyan Ahmed

Associate professor in the department of Oral and Maxillofacial Surgery Abbasi Shaheed Hospital/KMDC, Pakistan

Email: Drsufyan76@yahoo.com

Sana Shakil Khan

Postgraduate trainee of FCPS in Oral and Maxillofacial Surgery Abbasi Shaheed Hospital/KMDC, Pakistan

Email: sfs1127@gmail.com

Yousuf Ahmed Ansari

FCPS (postgraduate trainee) in Oral and Maxillofacial Surgery, Abbasi Shaheed Hospital Karachi, Pakistan

Email: yousufgem@hotmail.com

Asfandyar Luni

Oral and Maxillofacial Surgeon, DHQ Hospital Loralai, Pakistan

Email: Asfandyarluni2018@gmail.com

Afifa Tariq

Ayub Medical College Abbottabad, Pakistan

Email: afifaawan9@gmail.com

Abstract---Objectives: The aim of the current study was to determine whether, using the Hess area ratio for an objective measurement of ocular motility, orbital blowout fractures should be surgically repaired. Methodology: 200 consecutive patients with ocular fractures were involved in this retrospective analysis (mean age: 27.0 years; range: 7-65 years; 150 males; 50 females). Between March 2009 and September 2017, all patients received an orbital fracture diagnosis at the Zia Uddin Hospital in Karachi, Pakistan's Department of Maxillofacial Surgery. All patients had surgery to correct the problem within 30 days of their diagnoses, and they were all monitored for at

least three months afterward (mean follow-up time: 7.3 months; range: 4-60 months). Results: Out of the 200 instances, 155 patients (77.5%) had fractures of the orbital floor, 31 (15.5%) had fractures of the medial orbital wall, and 14 (7%) had fractures of both the medial and lateral orbital walls. In addition, 132 patients had fractures of the orbital depressed fragment, 58 had fractures of the orbital trap-door with imprisoned tissue, and 10 had fractures of the orbital trap-door with muscle entrapment. Conclusion: The current study's findings indisputably demonstrate that the area and form of an orbital fracture can be accurately assessed using the HAR% and that both factors have an influence on the outcome of surgery. These findings showed that surgery improved ocular motility in patients with orbital fractures and that the HAR% technique was a useful and instructive method for documenting and evaluating the surgical results in patients with orbital fractures.

Keywords---Ocular motility, orbital blowout, fractures, HES

Introduction

Smith and Regan originally identified orbital blowout fractures in 1957 and said that they are brought on by an abrupt rise in intraorbital pressure (Wilkins & Havins, 1982). Fractures of the medial wall and/or orbital floor are frequently the result of blunt trauma to the orbit. In these circumstances, there might be entrapment or pro-lapse of orbital soft tissue, & diplopia and irregular ocular motility might result from extraocular muscle dysfunction (Ebenezer, 2020). The best time to perform surgery to correct ocular fractures is still up for debate. Since orbital blowout fractures are treated by ophthalmologists as well as several surgical experts including otolaryngologists, maxillofacial surgeons, and plastic surgeons, there isn't a universal agreement on how to assess the surgical outcomes (Gooris et al., 2021). Normalizing ocular motility and preventing or treating enophthalmos are two objectives of orbital fracture repair. Therefore, unbiased techniques are required to assess ocular motility before to and during surgery (Pontell et al., 2021). Much earlier research highlighted the existence of diplopia, but the majority of those findings omitted any mention of objective data about ocular movement. We employed the Walter Rudolf Hess screen test, developed in 1908, to assess ocular motility objectively (Wei et al., 2023). This test allowed us to track variations in ocular motility in patients with orbital fractures. Ocular muscle weakness within thirty degrees is easily detected in situations of orbital fracture (Biagiotti et al., 2022). The aim of the current study was to determine whether, using the Hess area ratio for an objective measurement of ocular motility, orbital blowout fractures should be surgically repaired.

Methodology

200 consecutive patients with ocular fractures were involved in this retrospective analysis (mean age: 27.0 years; range: 7-65 years; 150 males; 50 females). Between March 2009 and September 2017, all patients received an orbital

fracture diagnosis at the Zia Uddin Hospital in Karachi, Pakistan's Department of Maxillofacial Surgery. All patients had surgery to correct the problem within 30 days of their diagnoses, and they were all monitored for at least three months afterward (mean follow-up time: 7.3 months; range: 4-60 months). Patients who got surgical treatment for their fractures at a different facility as well as patients who experienced surgery more than a month after their accident were excluded from this research. Additionally, because extreme eyelid bulge impairs normal ocular movement & makes it challenging to acquire accurate Hess screen test readings, patients who had intra orbital emphysema and extensive eyelid swelling at the time of the first assessment were also excluded.

An expert oculoplastic surgeon analyzed the CT scans of each patient to authorize the diagnosis of orbital fracture. The multi-slice CT scans were used to classify fractures by region and form, with the areas being categorized as a medial wall, orbital floor, or mixed orbital floor and medial wall. According to the categorizations outlined by Biagiotti et al.,⁶ shapes were divided into three categories: trap-door fracture, depressed fragment fracture, and fracture with imprisoned tissue. The incidence of symptoms such as diplopia, discomfort with ocular movement, & restricted ocular mobility was used to assess surgical indications. For orbital reconstruction, two alternative surgical approaches were employed, namely the Lynch incision for medial wall fractures and the subsidiary transcutaneous incision for fractures of the orbital floor.

The difference in HAR% amongst the preoperative and postoperative results was compared using the Mann-Whitney U test. For statistical significance, Mann-Whitney U test p values were employed, with a p-value of <0.05 being regarded as statistically significant. Prior informed permission was acquired from each participant in the study, and the Institutional Review Board of Zia Ud Din University authorized the study.

Results

Out of the 200 instances, 155 patients (77.5%) had fractures of the orbital floor, 31 (15.5%) had fractures of the medial orbital wall, and 14 (7%) had fractures of both the medial and lateral orbital walls. In addition, 132 patients had fractures of the orbital depressed fragment, 58 had fractures of the orbital trap-door with imprisoned tissue, and 10 had fractures of the orbital trap-door with muscle entrapment. Table 1 displays the characteristics of the 200 individuals who had orbital blowout fractures in each area and form.

Table 1: Profile of patients

Variables	Orbital Floor	Medial wall	Orbital floor and medial wall	Total cases
Depressed fragment fracture	100	22	10	132
Trap-door fracture with incarcerated tissue	49	6	3	58
Trap-door fracture with muscle Entrapment	6	3	1	10
Total	155	31	14	200

The mean number of days between the first injury and the following operation was 11.86.7 (interquartile range: 0–30). Compared to the mean preoperative HAR%, the mean postoperative HAR% at final follow-up (93%10.6%) was substantially higher ($p < 0.01$) (Fig 1)

Record of HAR% Post Surgery

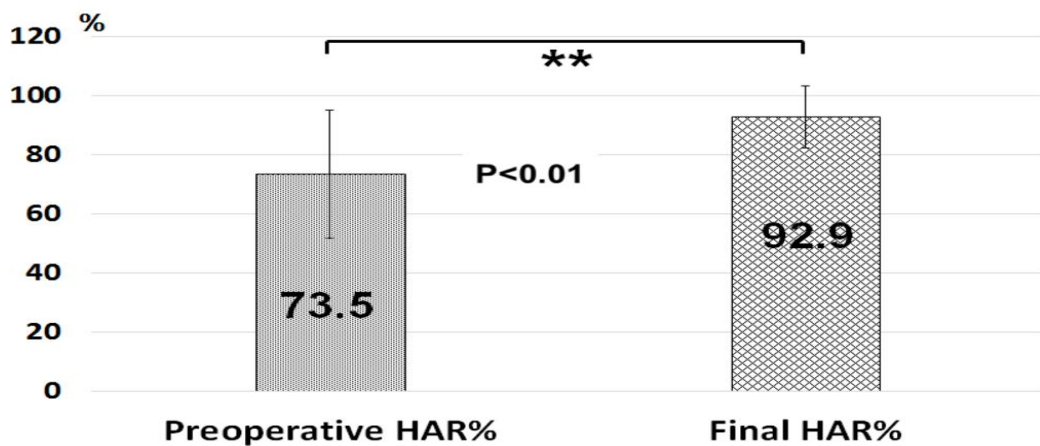


Fig 1: Images demonstrating HAR% improvement after surgery

The total operation time for all of the orbital floor fractures and orbital medial wall fractures was under three hours. Additionally, the mutual orbital floor and medial wall fracture surgeries were completed in less than 4 hours. There were no intraoperative problems in any of the patients. However, it should be mentioned that at the average follow-up time of 7.3 months, significant postoperative problems were seen. Four patients had postoperative infraorbital nerve dysfunction for dysesthesia, and two individuals had orbital hemorrhages. Two days after their surgeries, these two patients complained of acute eyelid swelling

and postoperative diplopia. A CT scan later revealed an orbital hemorrhage. However, in those two patients, the hematoma did not become larger. CT imaging one month after surgery showed that they had vanished, and both patients stopped expressing pain and diplopia complaints (Fig 2)

Discussion

Major effects of orbital blowout fractures include diplopia and enophthalmos, which may be caused by the extraocular tissues, muscles, or fat becoming trapped inside the fractured bone or by the expansion of these intraorbital structures. (Shetty et al., 2022) observed that in eighty two patients, diplopia was a complication in twenty five percent of medial wall fractures, eighty percent of orbital floor fractures, and eighty one percent of combined orbital floor and medial wall fractures. Additionally, they noted that restrictions on eye movement were seen in thirteen percent of medial wall fractures, seventy four percent of floor fractures, and forty eight percent of fractures that included both the orbital floor and medial wall. In two earlier investigations, the presence or absence of diplopia was the only factor used to assess the surgical repair's effectiveness (Koberda et al., 2023) (Taxis et al., 2023) (Hong et al., 2022). But in those investigations, the patients' symptoms of diplopia were too individualized to associate the preoperative & postoperative correction. A Hess screen test and a binocular single vision test were the objective techniques utilized to assess diplopia (Liaquat et al., 2022). In this study, ocular motility was assessed using the Hess screen test. With the use of this test, we are able to quickly track variations in ocular mobility in subjects who have orbital blowout fractures. The objective metric used to associate the surgical outcomes for subjects with ocular blowout fractures in a prior publication by (Yamanaka et al., 2022) was called HAR%. In 30 patients having surgical correction for orbital blowout fractures, (Hammerschlag et al., 1982) observed that HAR% was useful for envisaging postoperative diplopia. In those instances, there was no postoperative diplopia in any of the patients with preoperative HAR >85%. In current research, the mean final follow-up HAR% (93%±10.5%) was expressively improved than that of the initial HAR% (74%±21.7%) (p<0.01) The best time for surgery to treat an orbital blowout fracture is still up for debate. In situations with symptomatic diplopia with positive forced ductions, surgery should be performed within two weeks of the injury, and latent enophthalmos or hypophthalmos may emerge from extensive orbital floor fractures or signs of orbital soft tissue entrapment on a CT scan, according to (Palavalli et al., 2023). It was suggested in 2 more papers that early surgical repair causes a fast enhancement in diplopia & ocular mortality (Hong et al., 2022).

Conclusion

The current study's findings indisputably demonstrate that the area and form of an orbital fracture can be accurately assessed using the HAR% and that both factors have an influence on the result of surgery. These findings displayed that surgery improved ocular mobility in patients with orbital fractures and that the HAR% technique was a useful and instructive method for documenting and evaluating the surgical results in patients with orbital fractures.

References

- Biagiotti, J., Khan, K., Ayrapetyan, M., Wood, J., & Bhatt, N. (2022). Fat-free spindle cell lipoma of the scalp: Lipoma without a lipogenic component. *Journal of Craniofacial Surgery*, 33(4), e429–e431.
- Ebenezer, V. (2020). Materials for orbital floor reconstruction post trauma: A review literature. *European Journal of Molecular & Clinical Medicine*, 7(4), 2020.
- Gooris, P. J., Jansen, J., Bergsma, J. E., & Dubois, L. (2021). Evidence-Based Decision Making in Orbital Fractures: Implementation of a Clinical Protocol. *Atlas of the Oral and Maxillofacial Surgery Clinics of North America*, 29(1), 109–127.
- Hammerschlag, S., Hughes, S., O'Reilly, G., Naheedy, M., & Rumbaugh, C. (1982). Blow-out fractures of the orbit: A comparison of computed tomography and conventional radiography with anatomical correlation. *Radiology*, 143(2), 487–492.
- Hong, S., Choi, K.-E., Kim, J., & Baek, S. (2022). Comparison of Blowout Fracture Sites Observed in Young and Elderly East Asians. *Journal of Craniofacial Surgery*, 33(4), e427–e429.
- Hong, S., Choi, K.-E., Kim, J., Lee, H., Lee, H., & Baek, S. (2022). Analysis of Patients With Blowout Fracture Caused by Baseball Trauma. *Journal of Craniofacial Surgery*, 33(4), 1190–1192.
- Koberda, M., Skorek, A., Kłosowski, P., Żmuda-Trzebiatowski, M., Żerdzicki, K., Lemski, P., & Stodolska-Koberda, U. (2023). Numerical and clinical analysis of an eyeball injuries under direct impact. *International Journal of Occupational Medicine and Environmental Health*, 36(2), 263–273.
- Liaquat, A., Akram, A., Naseer, R., Hussain, B., Abbas, M., & Haq, E. (2022). Correction of Post-Traumatic Enophthalmos by Orbital Floor Reconstruction with Titanium Mesh. *Pakistan Journal of Medical & Health Sciences*, 16(04), 20–20.
- Palavalli, M. H., Huayllani, M. T., Gokun, Y., Lu, Y., & Janis, J. E. (2023). Surgical Approaches to Orbital Fractures: A Practical and Systematic Review. *Plastic and Reconstructive Surgery Global Open*, 11(5).
- Pontell, M. E., Jackson, K., Golinko, M., & Drolet, B. C. (2021). Influence of radiographic soft tissue findings on clinical entrapment in patients with orbital fractures. *Journal of Craniofacial Surgery*, 32(4), 1427–1431.
- Shetty, S. K., Saritha, R. S., & Singh, S. (2022). Isolated Pure Orbital Blowout Fracture-A Rare Case Report. *Annals of Maxillofacial Surgery*, 12(1), 110–113.
- Taxis, J., Ungerboeck, L., Gehrking, M. R., Motel, C., Wurm, M., Eckert, A. W., Spanier, G., Nieberle, F., Platz Batista da Silva, N., & Ludwig, N. (2023). Two-Dimensional Post-Traumatic Measurements of Orbital Floor Blowout Fractures Underestimate Defect Sizes Compared to Three-Dimensional Approaches. *Tomography*, 9(2), 579–588.
- Wei, Y., Wang, H., Song, X., Bi, X., Li, Y., Zhou, H., & Shi, W. (2023). Orbital Soft Tissue Displacement After Blow-Out Fracture Repair Using Poly (L-Lactide-Co-Glycolide) Polymer Plates Based on Image Fusion Technique. *The Journal of Craniofacial Surgery*, 34(2), e149.
- Wilkins, R. B., & Havins, W. E. (1982). Current treatment of blow-out fractures. *Ophthalmology*, 89(5), 464–466.
- Yamanaka, Y., Watanabe, A., Rajak, S. N., Nakayama, T., & Sotozono, C. (2022). Correlation between surgical timing and postoperative ocular motility in orbital blowout fractures. *Graefe's Archive for Clinical and Experimental Ophthalmology*, 260(1), 319–325.