

How to Cite:

Hadi, N. U., Khan, M. Q., Siraj, S., Ullah, K., Ahmad, A., & Naeemullah, N. (2021). A cross-sectional study on clinical utility of neonatal echocardiography. *International Journal of Health Sciences*, 5(S2), 1327–1334. <https://doi.org/10.53730/ijhs.v5nS2.14671>

A cross-sectional study on clinical utility of neonatal echocardiography

Noor ul Hadi

Assistant Professor of Department of Cardiology Bacha Khan Medical College, Mardan

Muhammad Qasim Khan

Associate Professor Paeds BKMC /MMC, Mardan

Corresponding author email: qasimkhan.dr.02@gmail.com

Sumbal Siraj

TMO Gynae Obs, Saidu Group of Teaching Hospital, Saidu Swat

Kirammat Ullah

Assistant Professor Pediatrics Ward MMC/BKMC, Mardan

Ashfaq Ahmad

Associate Professor of Paediatric, Saidu Teaching Hospital, Saidu Swat

Naeemullah

Associate Professor, Community Medicine Department Saidu Medical College, Swat

Abstract--Background and Aim: Congenital heart disease (CHD) is a prevalent anomaly associated with various risk factors and the influence of early diagnosis of neonate cardiac abnormalities on postnatal outcomes has been a topic of controversy in the literature. The present study aimed to assess the clinical utility of neonatal echocardiography. Patients and Methods: This cross-sectional study was carried out on 86 neonates for echocardiography (FE) in the Cardiology Department of Mardan Medical Complex (MMC), Mardan from March 2021 to September 2021. A comprehensive maternal interview gathered extensive information encompassing details such as the ages of parents, consanguinity, and family history of congenital heart disease (CHD). Neonatal echocardiography was conducted to identify any structural or rhythm abnormalities in the neonate heart. Results: The overall mean for paternal and maternal ages were 31.76 ± 5.48 years and 27.52 ± 6.24 years respectively. Of the total 86 cases, the incidence of neonate cardiac abnormalities, congenital heart defects, neonate arrhythmias, cardiomyopathy, cardiac mass,

and rhythm abnormalities were 47.8% (n=41), 34.9% (n=30), 9.3% (n=8), 3.5% (n=3), 2.3% (n=2), and 2.3% (n=2) respectively. Out of 30 cases of CHD, the prevalence of complex heart lesions, common atrioventricular canal, and conotruncal anomalies was 60% (n=18), 26.7% (n=8), and 13.3% (n=4) respectively. The incidence of tachyarrhythmias, ectopics, and neonate had congenital heart block among eight cases of neonatal arrhythmias was 50% (n=4), 37.5% (n=3), and 12.5% (n=1) respectively. Abnormal ultrasound, positive family history of CHD, maternal diseases, and multiple neonatal deaths were common indications for referral of patients found in 46 cases (53.5%), 8 (9.3%), 18 (20.9%), and 14 (16.3%) respectively. Conclusion: Congenital heart defects (CHDs) can occur in neonates without associated perinatal risk factors. Neonatal echocardiography is capable of reliably diagnosing the majority of cardiac anomalies, although some challenges persist, especially in cases like aortic coarctation. Moreover, neonates' echocardiography provides a valuable opportunity for successful early intervention of certain types of neonatal arrhythmias.

Keywords---Neonatal echocardiography, Neonates arrhythmia, congenital heart disease.

Introduction

Congenital cardiac anomalies are observed in approximately 6 to 12 per 1,000 live births [1]. Research indicates that 3 to 4% of live births involve major heart defects requiring intervention within the first year of life [2]. This frequency surpasses that of chromosomal defects by six times and neural tube defects by four times. These anomalies contribute to up to 10% of childhood deaths [3]. The diagnosis of cardiac anomalies among neonates holds the potential to enhance prognosis, reduce infant morbidity and mortality, and guide expectant mothers toward specialized centers [4]. Consanguinity, exposure to teratogens, maternal medical conditions, neonate chromosomal and extra-cardiac abnormalities are numerous risk factors for the development of congenital heart disease (CHD) [5, 6]. The existing protocols for neonatal echocardiography operate on the principle that early in-utero interventions can potentially halt the progression of neonate's cardiac lesions into severe forms or better equip the neonatal team for the arrival of the neonates [7]. Furthermore, the in-utero transfer of compromised neonates is deemed preferable to a post-natal transfer to a specialized unit for further care [8]. This protocol aligns effectively with high-income countries that possess ample resources, well-established referral systems, and a robust neonates and maternal special capable of providing timely intrauterine interventions for affected women during pregnancies [9, 10].

Neonatal echocardiography (FE) serves as a primary diagnostic tool for identifying neonatal arrhythmias and assessing their complications [11]. While neonatal echocardiography is commonly employed for detecting high-risk cases of cardiac anomalies. At present, referrals are frequently initiated upon identifying abnormal 4-chamber views in obstetric ultrasound scans or the presence of prenatal risk

factors, even though only 10% of affected children exhibit identifiable predisposing factors [12]. The present study aimed to assess the clinical utility of neonatal echocardiography.

Methodology

This cross-sectional study was carried out on 86 fetuses of singleton pregnancy referred for neonatal echocardiography in the Cardiology Department of Mardan Medical Complex (MMC), Mardan from March 2021 to September 2021. A comprehensive maternal interview encompassing details such as the ages of both parents, consanguinity, and family history of congenital heart disease (CHD). Neonatal echocardiography was conducted to identify any structural or rhythm abnormalities in the infant's heart. Newborn examination (NE) was conducted within 48 hours of delivery, with the timing determined by the urgency of each specific case. Structural congenital heart defects (CHDs) were classified into categories such as common atrioventricular (AV) canal and conotruncal anomalies. Data were analyzed using SPSS version 27. Qualitative variables were compared using Chi-square test with P value of < 0.05 was considered significant.

Results

The overall mean for paternal, and maternal ages were 31.76 ± 5.48 years and 27.52 ± 6.24 years respectively. Of the total 86 cases, the incidence of neonatal cardiac abnormalities, congenital heart defects, neonates arrhythmias, cardiomyopathy, cardiac mass, and rhythm abnormalities were 47.8% (n=41), 34.9% (n=30), 9.3% (n=8), 3.5% (n=3), 2.3% (n=2), and 2.3% (n=2) respectively. Out of 30 cases of CHD, the prevalence of complex heart lesions, common atrioventricular canal, and conotruncal anomalies was 60% (n=18), 26.7% (n=8), and 13.3% (n=4) respectively. The incidence of tachyarrhythmias, ectopics, and neonates had congenital heart block among eight cases of neonates arrhythmias was 50% (n=4), 37.5% (n=3), and 12.5% (n=1) respectively. Abnormal ultrasound, positive family history of CHD, maternal diseases, and multiple neonatal deaths were common indications for referral of patients found in 46 cases (53.5%), 8 (9.3%), 18 (20.9%), and 14 (16.3%) respectively. Figure-1 depicts the incidence of different anomalies of infants. Congenital heart diseases are illustrated in Figure-2. Details of neonates arrhythmias cases are shown in Table-I. The common indications for referral of fetuses are depicted in Figure-3.

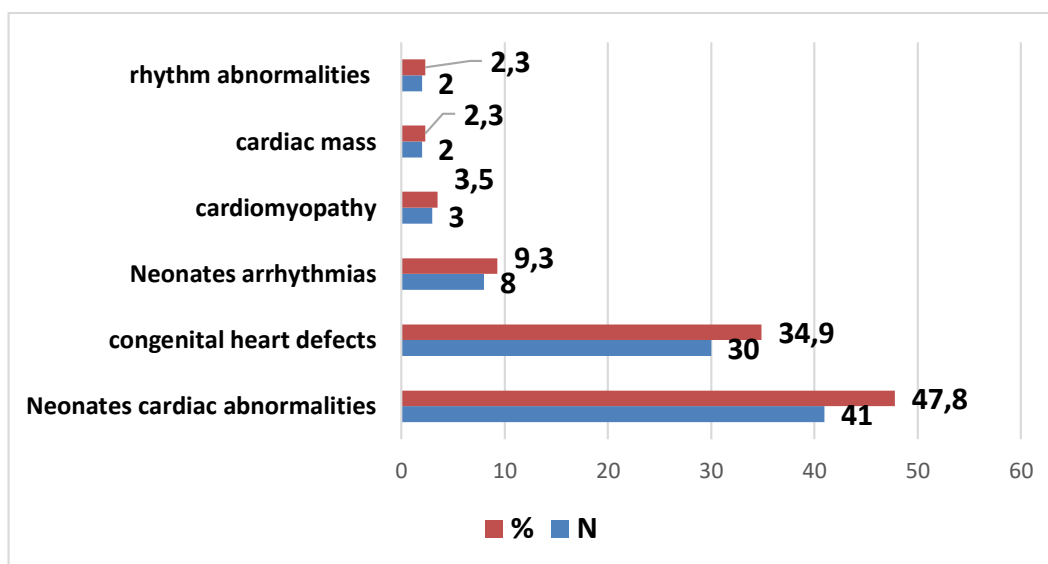


Figure-1 incidence of different anomalies (n=86)

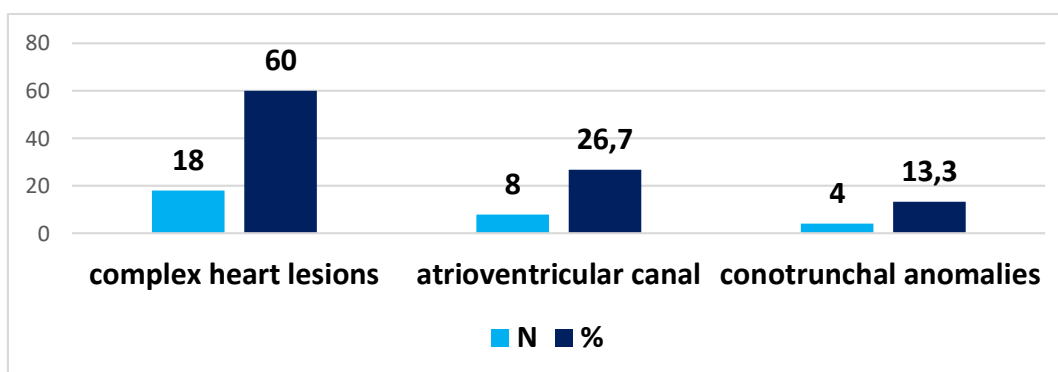


Figure-2 Congenital heart diseases (N=86)

Table-I Details of Neonates arrhythmias (8-cases)

Neonates arrhythmias	N (%)
Tachyarrhythmias	4 (50%)
Ectopics	3 (37.5%)
Infant with congenital heart block	1 (12.5%)

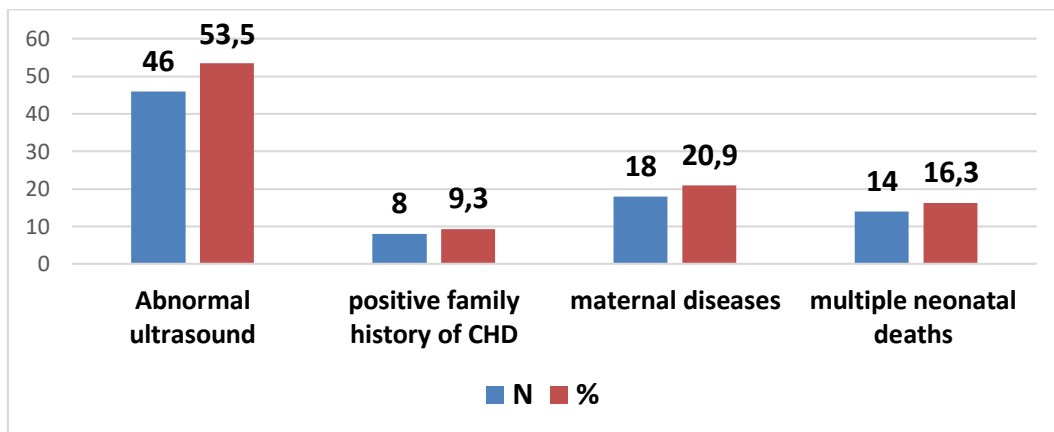


Figure-3 common indications for referral of neonates (N=86)

Discussion

The present study mainly focused on the clinical utility of neonates echocardiography and found that neonate echocardiography is capable of reliably diagnosing the majority of cardiac anomalies, although some challenges persist, especially in cases like aortic coarctation. Moreover, infants with cardiac abnormalities had higher risk of cardiac abnormalities than those without exposure to perinatal risk factors, while it was statistically lower in mothers exposed to perinatal risk factors. The development of the neonate heart commences as early as the fourth week of life and reaches complete formation by the ninth week. Some anomalies manifest during the early stages, while others progress, potentially leading to heart dysfunction. For instance, severe aortic stenosis may advance to hypertrophic left heart syndrome (HLHS) [13]. Notably, only 30 to 50% of cardiac defects are detected in anomaly scans in developed countries. Critical Cardiac Heart Disease encompasses lesions requiring urgent post-delivery intervention, further categorized into right heart obstructive lesions, left heart obstructive lesions, and mixing lesions. Among various neonate cardiac anomalies, approximately one-fourth are classified as critical lesions [14].

Deviation from normality in neonate cardiac assessments involves anomalies such as abnormal cardiac position or axis, chamber dilatation, and neonate arrhythmia [15]. Simply acquiring a standard four-chamber view is not enough to rule out the possibility of underlying cardiac anomalies [16]. Consequently, cardiac anomalies of neonates might not be effectively screened by obstetric scan used on routine basis [17]. Satomi et al. [18] reported that the CHD rate elevated from 47% to 77% in four-chamber view. Similarly, another study by Nayak et al. [19] found 75% detection rate. At present, neonate echocardiography earmarked for pregnancies deemed high risk, where traditionally a CHD higher incidence is anticipated [20]. However, earlier investigations have indicated that a significant portion of CHD cases occurs in low-risk populations [21-24].

Tsuritani et al. [25] identified 25% cases of CHD. Variation in ethnicity of general population are the responsible for different incidence and detection rate of CHD. Patel et al. [26] reported that neonate echocardiography demonstrated a

sensitivity of 68.5% and specificity of 99.8% in detecting CHD. In contrast, Ryd et al. [27] reported a sensitivity of 96.9%, specificity of 90.6%, positive predictive value of 84.2%, negative predictive value of 98.3%, and an accuracy of 92.8%. In the present series, postnatal studies indicated that neonatal echocardiography accurately diagnosed all cases of CHD.

Several studies indicate that neonates diagnosed with congenital heart defects (CHD) during the prenatal period [28]. Despite these considerations of delivery timing and neonate complications, it is important to weigh the advantages of term delivery in such cases [29].

Conclusion

Congenital heart defects (CHDs) can occur in fetuses without associated perinatal risk factors. Neonate echocardiography is capable of reliably diagnosing the majority of cardiac anomalies, although some challenges persist, especially in cases like aortic coarctation. Moreover, neonatal echocardiography provides a valuable opportunity for successful early intervention of certain types of neonate arrhythmias.

References

1. Donofrio MT, Moon-Grady AJ, Hornberger LK, Copel JA, Sklansky MS, Abuhamad A et al (2014) Diagnosis and treatment of fetal cardiac disease: a scientific statement from the American Heart Association. *Circulation* 129(21):2183–2242. <https://doi.org/10.1161/01.cir.0000437597.44550.5d>.
2. Tissot, C. & Singh, Y. Neonatal functional echocardiography. *Curr. Opin. Pediatr.* 32, 235–244 (2020).
3. Barrington, K., El-Khuffash, A. & Dempsey, E. Intervention and outcome for neonatal hypotension. *Clin. Perinatol.* 47, 563–574 (2020).
4. de Boode, W. P. et al. The role of neonatologist performed echocardiography in the assessment and management of neonatal shock. *Pediatr. Res.* 84, 57–67 (2018).
5. Kumar S, Lodge J. Prenatal therapy for neonate cardiac disorders. *J Matern Neonate Neonatal Med* 2019; 32(22): 3871-3881. doi:10.1080/14767058.2018.1472224.
6. Maulik D, Nanda NC, Maulik D, Vilchez G. A brief history of neonate echocardiography and its impact on the management of congenital heart disease. *Echocardiography* 2017; 34(12): 1760-1767. doi: 10.1111/echo.13713. Erratum in: *Echocardiography*. 2018; 35(4): 581.
7. Li YF, Zhou KY, Fang J, Wang C, Hua YM, Mu DZ. Efficacy of prenatal diagnosis of major congenital heart disease on perinatal management and perioperative mortality: a meta-analysis. *World J Pediatr* 2016; 12(3): 298-307. doi: 10.1007/s12519-016-0016-z.
8. Han B, Tang Y, Qu X, Deng C, Wang X, Li J, et al. Comparison of the 1-year survival rate in infants with congenital heart disease diagnosed by prenatal and postnatal ultrasound: A retrospective study. *Medicine (Baltimore)* 2021; 100(4): e23325. doi: 10.1097/MD.00000000000023325.
9. Hamdan MA, Chedid F, Bekdache GN, Begam M, Alsaf W, Sabri Z, Mirghani HM (2015) Perinatal outcome of congenital heart disease in a population with

- high consanguinity. *J Perinat Med* 43(6):735–740. <https://doi.org/10.1515/jpm-2014-0019>
10. Sheridan E, Wright J, Small N, Corry PC, Oddie S, Whibley C et al (2013) Risk factors for congenital anomaly in a multiethnic birth cohort: an analysis of the born in Bradford study. *Lancet* 382:1350–1359. [https://doi.org/10.1016/S0140-6736\(13\)61132-0](https://doi.org/10.1016/S0140-6736(13)61132-0).
 11. El-Khuffash, A. et al. Targeted neonatal echocardiography (TnECHO) service in a Canadian neonatal intensive care unit: a 4-year experience. *J. Perinatol.* 33, 687–690 (2013).
 12. Corredera, A. et al. Functional echocardiography in neonatal intensive care: 1 year experience in a unit in Spain. *An. Pediatr. (Barc.)* 81, 167–173 (2014).
 13. Harabor, A. & Soraisham, A. S. Utility of targeted neonatal echocardiography in the management of neonatal illness. *J. Ultrasound Med.* 34, 1259–1263 (2015).
 14. Khamkar, A. M. et al. Functional neonatal echocardiography: Indian experience. *J. Clin. Diagn. Res.* 9, SC11–SC14 (2015).
 15. Papadhima, I. et al. Targeted neonatal echocardiography (TNE) consult service in a large tertiary perinatal center in Canada. *J. Perinatol.* 38, 1039–1045 (2018).
 16. Alammery, D., Narvey, M., Soni, R., Elsayed, Y. & Louis, D. Targeted neonatal echocardiography service in neonatal intensive care in Manitoba, Canada. *J. Perinatol.* 42, 655–659 (2021).
 17. Premani Z, Mithani Z. Analysis of the health care system of Pakistan: lessons learnt and way forward. *J Ayub Med Coll Abbottabad* 2016; 28(3): 601–604.
 18. Satomi G. Guidelines for neonate echocardiography. *Pediatr Int* 2015; 57(1): 1-21. doi: 10.1111/ped.12467.
 19. Nayak K, Chandra GSN, Shetty R, Narayan PK (2016) Evaluation of neonate echocardiography as a routine antenatal screening tool for detection of congenital heart disease. *Cardiovasc Diagn Ther* 6(1):44–49.
 20. Chitra N, Vijayalakshmi IB (2017) Neonate echocardiography for early detection of congenital heart diseases. *J Echocardiogr* 15(1):13–17.
 21. Knowles RL, Ridout D, Crowe S, Bull C, Wray J, Tregay J, Franklin RC, Barron DJ, Cunningham D, Parslow RC, Brown KL (2017) Ethnic and socioeconomic variation in incidence of congenital heart defects. *Arch Dis Child* 102(6):496–502. <https://doi.org/10.1136/archdischild-2016-311143>
 22. Zhang YF, Zeng XL, Zhao EF, Lu HW (2015) Diagnostic value of neonate echocardiography for congenital heart disease: a systematic review and meta-analysis. *Medicine (Baltimore)* 94:e1759.
 23. Tavares de Sousa M, Hecher K, Yamamura J et al (2019) Dynamic neonate cardiac magnetic resonance imaging in four-chamber view using Doppler ultrasound gating in normal neonate heart and in congenital heart disease: comparison with neonate echocardiography. *Ultrasound Obstet Gynecol* 53:669–675
 24. Lloyd DFA, Pushparajah K, Simpson JM et al (2019) Three-dimensional visualisation of the neonate heart using prenatal MRI with motion-corrected slice-volume registration: a prospective, single-centre cohort study. *Lancet* 393:1619–1627
 25. Tsuritani M, Morita Y, Miyoshi T et al (2019) Neonate cardiac functional assessment by neonate heart magnetic resonance imaging. *J Comput Assist Tomogr* 43:104–108

26. Patel N, Narasimhan E, Kennedy A (2017) Neonate cardiac US: techniques and normal anatomy correlated with adult CT and MR imaging. *Radiographics* 37:1290–1303
27. Ryd D, Fricke K, Bhat M et al (2021) Utility of neonate cardiovascular magnetic resonance for prenatal diagnosis of complex congenital heart defects. *JAMA Netw Open* 4:e213538
28. Birhanu K, Tesfaye W, Berhane M. Congenital Anomalies in Neonates Admitted to a Tertiary Hospital in Southwest Ethiopia: A Cross Sectional Study. *Ethiopian journal of health sciences*. 2021 Nov 1;31(6).
29. Donofrio MT (2018) Predicting the future: delivery room planning of congenital heart disease diagnosed by neonate echocardiography. *Am J Perinatol* 35(6):549–552. <https://doi.org/10.1055/s-0038-1637764>