

**How to Cite:**

Saleh, M., Yousaf, A., Ali, Y., Ali, W., Abo-Tabik, D., Zaheer, S. A., Ahmad, K., & Zafar, S. (2024). Unraveling the connection: Hepatitis C Virus (HCV) and Acute Myelogenous Leukemia (AML) in the absence of antiviral therapy: A case report and literature review. *International Journal of Health Sciences*, 8(S1), 553–559. <https://doi.org/10.53730/ijhs.v8nS1.14858>

# **Unraveling the connection: Hepatitis C Virus (HCV) and Acute Myelogenous Leukemia (AML) in the absence of antiviral therapy: A case report and literature review**

**Mahnosh Saleh**

Resident Physician, Ayub Teaching Hospital, Abbottabad, Pakistan

Email: [mahnoshsaleh496@gmail.com](mailto:mahnoshsaleh496@gmail.com)

**Aima Yousaf**

Clinical Fellow, George Eliot Hospital, United Kingdom

Email: [Aimayousaf1997@gmail.com](mailto:Aimayousaf1997@gmail.com)

**Yasir Ali**

Resident Physician, Hayatabad Medical Complex, Peshawar, Pakistan

Email: [dryasiraliburki@gmail.com](mailto:dryasiraliburki@gmail.com)

**Waqar Ali**

Geriatric Fellow, Russell Hall Hospital, United Kingdom

Email: [waqaralikmc703@gmail.com](mailto:waqaralikmc703@gmail.com)

**Dina Abo-Tabik**

Clinical Fellow, George Eliot Hospital, United Kingdom

Email: [Dinaabo-tabik@outlook.com](mailto:Dinaabo-tabik@outlook.com)

**Syeda Aisha Zaheer**

Registrar Internal Medicine, George Eliot Hospital, United Kingdom

Email: [Syeda.zaheer@geh.nhs.uk](mailto:Syeda.zaheer@geh.nhs.uk)

**Kamran Ahmad**

Resident Physician, Hayatabad Medical Complex, Peshawar, Pakistan

Corresponding Author Email: [drkamikhan123@gmail.com](mailto:drkamikhan123@gmail.com)

**Shahzad Zafar**

Senior House Officer, Tallaght University Hospital, Dublin, Ireland

Email: [shahzadicup@gmail.com](mailto:shahzadicup@gmail.com)

**Abstract**---This case report presents a 40-year-old female with no prior medical history, who presented with symptoms of low-grade fever, shortness of breath, weakness, and pancytopenia. Upon examination, signs of chronic hepatitis C virus (HCV) infection with decompensated cirrhosis and acute myelogenous leukemia (AML) were evident. The patient did not receive any prior treatment for HCV. The case discussion explores the association between HCV infection and the development of AML, considering existing literature suggesting both direct viral effects and potential effects of HCV antiviral drugs on AML development. Despite collaborative efforts from hematology and oncology specialists, the patient's advanced AML stage precluded specific leukemia therapy. She succumbed to complications related to cirrhosis despite intensive care. This case emphasizes the importance of investigating pancytopenia in patients with HCV, highlighting AML as a potential complication, whether due to the virus itself or its treatment, warranting further research.

**Keywords**---Hepatitis C Virus, Virus Pancytopenia, Acute Myelogenous Leukemia, HCV Complication, Case Report, Rare complication, complication oncology.

## **Introduction**

The hepatitis C virus (HCV) is a significant cause of death, morbidity, and resource consumption, making it a serious worldwide health concern. The estimated global frequency of HCV infection is roughly 2%, despite notable variations that can be seen based on geographic location and ethnicity. About 180 million people continuously carry this infection. Prolonged HCV antigenic stimulation leads to the development and release of monoclonal and polyclonal antibodies, the formation of immunological complexes, and the clonal growth of B-lymphocytes. (1) Moreover, hepatitis C virus (HCV) has a well documented association with extra hepatic manifestations particularly hematologic disorders with benign and malignant B-cell proliferations being the most common complications. (2) They are also susceptible to developing peripheral cytopenia, the etiology of which is unclear but it is proposed to involve hypersplenism or autoimmune or the consequence of the use of antiviral drugs. A large study analysing data collected in the third National Health and Nutrition Examination Survey (NHANES III) found that patients with HCV, as determined by the presence of anti-HCV antibodies, are more likely than those in the general public to have neutropenia and thrombocytopenia. (3) The treatment of HCV in hematologic malignancies promises both hepatic and oncologic benefits. (4) So far, to the best of our knowledge, there is no existing data describing AML as a complication to untreated HCV. Here, we present a 40-year-old female without a past medical history of any baseline comorbidities (hypertension, diabetes), who presented with low grade fever, shortness of breath and generalized weakness and was found to have chronic hepatitis C with DCLD, and AML. We discuss our patient's hospital course and the management plan for AML following untreated HCV infection.

## Case Presentation

A 40-year-old woman came to the hospital complaining of feeling short of breath, weak all over, having a low-grade fever, no appetite, vomiting, and a swollen abdomen. She seemed healthy otherwise, with no history of high blood pressure or diabetes. But upon examination, we noticed some concerning signs. Her vital signs were as follows: blood pressure was 110/70, pulse rate was 99 beats per minute, and body temperature was 98.7°F. Physically, we observed that she looked pale, her eyes were yellow, her palms were red, and her feet were swollen. These are signs that something wasn't right internally.

Examining her abdomen, we noticed it was bloated, her belly button was inverted, and when we tapped her abdomen, the sounds were dull. We also felt that her liver was enlarged with rough edges and her spleen tip could be felt below her left rib. Lab tests showed a decrease in blood cells (pancytopenia), with imbalances in white blood cell types, low platelet counts, and low hemoglobin levels (6.1 g/dL).

Further tests revealed low levels of potassium, low creatinine, and decreased albumin. Liver function tests indicated slightly elevated bilirubin and ALT levels. Tests for hepatitis C were positive, while tests for hepatitis B were negative. A PCR test confirmed the presence of hepatitis C. Additionally, the AFP score was higher than usual (4.86 ng/ml), and blood clotting tests showed high PT/INR values (22.7/1.6).

Ultrasound examination of her abdomen showed signs of chronic liver disease, including a coarse liver, no focal lesions, and abdominal fluid accumulation. Microscopic examination of her blood cells revealed fewer platelets and some unusual blast cells (shown in figure1) which were further confirmed by a bone marrow biopsy, indicating acute myelogenous leukemia (AML) with 80% blast cells (shown in figure2)

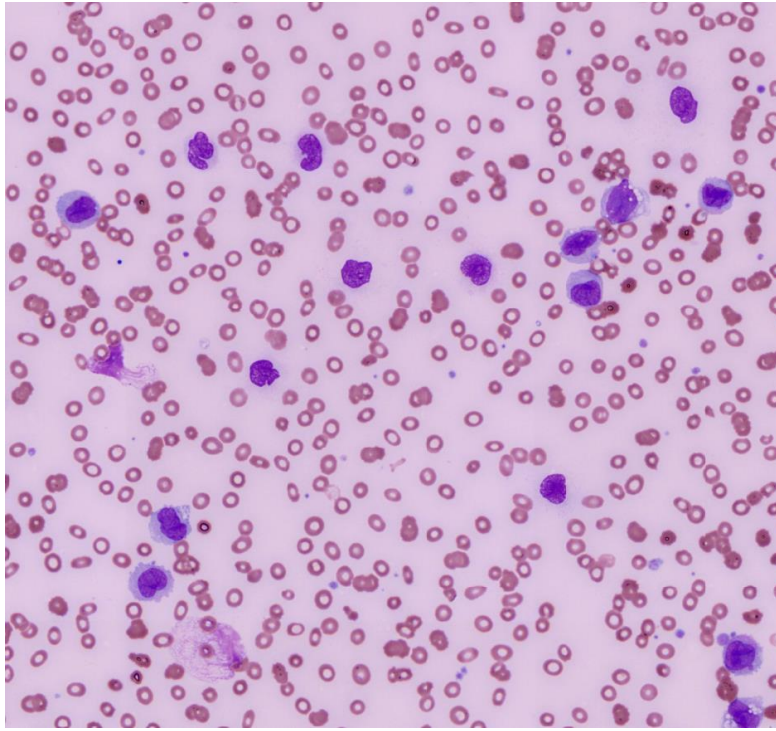


Figure1: Peripheral Blood Smear showing Microcytic Hypochromic morphology with the presence of BLAST CELLS

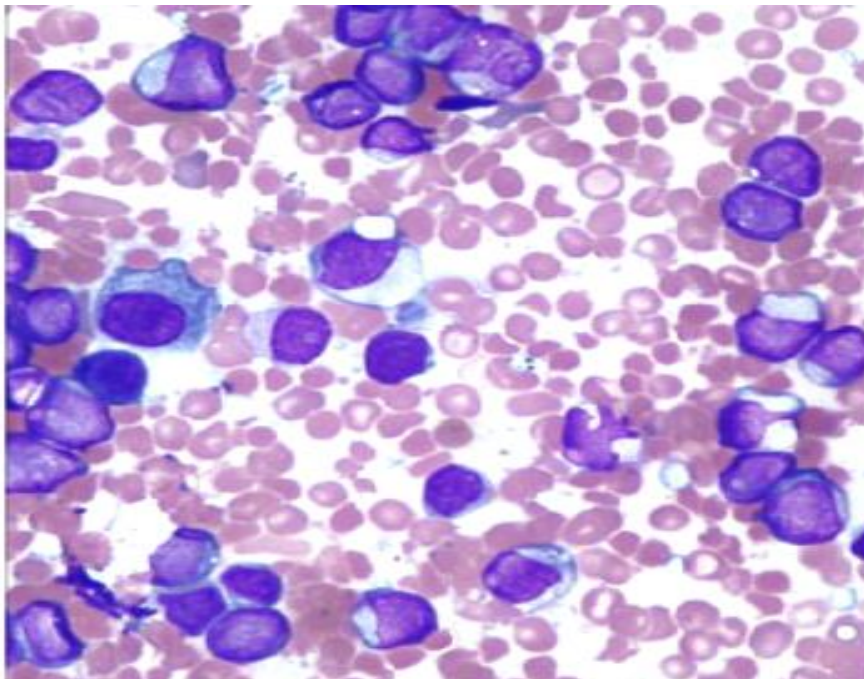


Figure2: Bone Marrow smear showing BLAST CELLS

Fluid analysis from her abdomen confirmed signs of cirrhosis, but fortunately, no cancer cells were found. Her performance status, measured by ECOG, was at a concerning level 4.

#### Management and Outcome:

Recognizing the complications of untreated hepatitis C leading to AML, our team of specialists from hematology and oncology collaborated. However, due to the advanced stage of AML, specific leukemia therapy was deemed too risky. Instead, we focused on managing her hepatic cirrhosis and stabilizing her overall condition.

Despite our efforts, her health continued to deteriorate, and she was eventually moved to the intensive care unit due to unstable blood pressure. Unfortunately, over the next week, her condition worsened, and she succumbed to complications from cirrhosis.

### **Discussion**

The hepatitis C virus (HCV) is still a leading cause of disease worldwide. According to WHO estimates from 1999, 170 million persons worldwide were infected with the virus, with a global incidence of roughly 3%.<sup>(5)</sup> There have been numerous reports of HCV-related extrahepatic manifestations (EHMs). Up to 74% of patients in several large cohort studies had HCV-EHMs of varying severity, ranging from perceived to incapacitating symptoms.<sup>(6)</sup> Hematological manifestations are among one of them. Hematological symptoms associated with HCV infection might vary from benign lymphoproliferative diseases to malignant cytopenias. <sup>(7)</sup> According to one of the systemic review published in 2015, B- Cell Non Hodgkin lymphoma is among the most common Hematological malignancies found in HCV patient.<sup>(1)</sup> However, Our patient presented with AML, which is not a very common hematological malignancy found in HCV patient. A systemic review and meta-analysis performed by the Yanrong in 2022, suggested that HCV could be one of the risk factor for developing AML. <sup>(8)</sup> In most reported cases, AML developing in HCV patient is linked to the treatment given for HCV. A retrospective observational study conducted in Pitié-Salpêtrière hospital, Paris concluded that DAA therapies appeared to increase the incidence of AML, especially in patients with severe HCV, such as those with cirrhosis and/or liver transplants. <sup>(9)</sup> However, Our patient did not receive any treatment of HCV and developed AML showing that HCV itself can cause AML. A study carried out in Korea, to estimate the prevalence of HBV/HCV virus in Hematological malignancies mentioned that HBV virus is more associated with AML. <sup>(10)</sup> Contrary to the above study, Our patient developed AML on the Background of HCV, which though also associated with AML. But rare. Hepatocellular carcinoma is one of the commonest malignancy found in patient with cirrhosis due to HCV. A study carried out in Texas, According to this extensive, single-center experience conducted in the United States, the primary viral cause of the rise in HCC incidence is hepatitis C infection. <sup>(11)</sup> However, Ultrasound did not show any focal lesion consistent with HCC in our patient. Moreover, the AFP value was also within normal limits. AML can occur in patient developing cirrhosis with HCV. Therefore, clinician should be extra vigilant when treating any patient presenting with pancytopenia o background of HCV.

## Conclusion

In conclusion, this case give emphasis to the necessity of thorough investigation for AML in patients presenting with pancytopenia, particularly in the context of HCV infection. The patient's presentation underscores the complex interplay between chronic HCV infection, cirrhosis, and hematological malignancies like AML. While the exact etiology of AML in untreated HCV remains uncertain, whether it stems from the virus itself or from HCV antiviral therapies, this case adds to the growing body of evidence suggesting a potential association. Further studies are imperative to elucidate the underlying mechanisms and guide clinical management strategies. Meanwhile, clinicians should remain vigilant for AML development in cirrhotic patients with HCV, recognizing the need for comprehensive care tailored to individual patient circumstances.

## References

1. Fiorino S, Bacchi-Reggiani L, De Biase D, Fornelli A, Masetti M, Tura A, Grizzi F, Zanella M, Mastrangelo L, Lombardi R, Acquaviva G. Possible association between hepatitis C virus and malignancies different from hepatocellular carcinoma: A systematic review. *World journal of gastroenterology*. 2015 Dec 12;21(45):12896.
2. Allison RD, Tong X, Moorman AC, et al. Increased incidence of cancer and cancer-related mortality among persons with chronic hepatitis C infection, 2006–2010. *J Hepatol*. 2015;63(4):822-828. doi:10.1016/j.jhep.2015.04.021
3. Klco JM, Geng B, Brunt EM, et al. Bone marrow biopsy in patients with hepatitis C virus infection: Spectrum of findings and diagnostic utility. *Am J Hematol*. 2010;85(2):106-110.doi:10.1002/ajh.21600
4. Torres HA, Mahale P, Blechacz B, et al. Effect of hepatitis C virus infection in patients with cancer: addressing a neglected population. *J Natl Compr Canc Netw*. 2015;13(1):41-50.
5. Sy, Theodore, and M. Mazen Jamal. "Epidemiology of Hepatitis C Virus (HCV) infection." *International journal of Medical science* 3, no. 2(2006): 41
6. Cacoub P, Poynard T, Ghillani P, Charlotte F, Olivi M, Charles Piette J, Opolon P. Extrahepatic manifestations of chronic hepatitis C. *Arthritis & Rheumatism: Official Journal of the American College of Rheumatology*. 1999 Oct;42(10):2204-12.
7. Himoto T, Masaki T. Extrahepatic manifestations and autoantibodies in patients with hepatitis C virus infection. *Journal of Immunology Research*. 2012 Jan 1;2012.
8. Guo Y, Wang W, Sun H. A systematic review and meta-analysis on the risk factors of acute myeloid leukemia. *Translational Cancer Research*. 2022 Apr;11(4):796.
9. Scheifer C, Luckina E, Lebrun-Vignes B, Diop AA, Damais-Thabut D, Roos-Weil D, Dechartres A, Lebray P. Acute myeloid leukaemia following direct acting antiviral drugs in HCV-infected patients: A 10 years' retrospective single-center study. *Clinics and Research in Hepatology and Gastroenterology*. 2022 Oct 1;46(8):102000.
10. Kang J, Cho JH, Suh CW, Lee DH, Oh HB, Sohn YH, Chi HS, Park CJ, Jang SS, Lee KH, Lee JH. High prevalence of hepatitis B and hepatitis C virus

- infections in Korean patients with hematopoietic malignancies. *Annals of hematology*. 2011 Feb;90:159-64.
11. Hassan MM, Frome A, Patt YZ, El-Serag HB. Rising prevalence of hepatitis C virus infection among patients recently diagnosed with hepatocellular carcinoma in the United States. *Journal of clinical gastroenterology*. 2002 Sep 1;35(3):266-9.