

How to Cite:

Alanazi, M. M. F., & Alhebs, M. A. (2024). Advancements in hybrid imaging techniques: Enhancing diagnostic accuracy with PET/MRI and PET/CT. *International Journal of Health Sciences*, 8(S1), 1800–1811. <https://doi.org/10.53730/ijhs.v8nS1.15396>

Advancements in hybrid imaging techniques: Enhancing diagnostic accuracy with PET/MRI and PET/CT

Maram Mohammed Fawaz Alanazi

Corresponding email: maram.mf91@gmail.com

Specialty: Radiological Technology

Job: MRI Technologist

Mohammed Abdulrahman Alhebs

Radiology Technician

Abstract--Background Hybrid imaging techniques, including PET/MRI and PET/CT, are transforming medical diagnostics by integrating metabolic data from Positron Emission Tomography (PET) with the detailed anatomical resolution provided by Magnetic Resonance Imaging (MRI) or Computed Tomography (CT). This integration improves diagnostic accuracy, especially in oncology, where accurate tumor localization and characterization are essential for effective treatment planning. PET/CT is commonly utilized; however, PET/MRI presents benefits including enhanced soft tissue contrast and decreased radiation exposure, rendering it especially beneficial for pediatric patients or individuals needing multiple scans. Challenges persist in standardization, accessibility, and addressing the inherent physical limitations associated with the integration of these distinct imaging modalities. **Aim** This review seeks to evaluate the current status of hybrid imaging, specifically PET/MRI and PET/CT, by analyzing their diagnostic efficacy, integration challenges, and prospective developments. The review analyzed the benefits and drawbacks of each technique, compared their clinical applications, and investigated emerging hybrid modalities. **Methods** A thorough literature review was performed, including studies and articles on the applications of PET/MRI and PET/CT in diverse disease areas. The review examined current studies on diagnostic accuracy, technical integration challenges, and prospective developments in hybrid imaging technology. **Results** The review demonstrated significant evidence indicating the enhanced diagnostic efficacy of hybrid imaging relative to standalone modalities. PET/MRI exhibits distinct benefits in the characterization of soft tissues and in minimizing radiation exposure. Integration challenges were identified, specifically in

managing magnetic field interference and achieving precise attenuation correction. The review examined emerging hybrid techniques that may have future clinical applications. **Conclusion** Hybrid imaging, specifically PET/MRI and PET/CT, signifies a notable progression in medical diagnostics, providing enhanced accuracy and diminished radiation exposure. Resolving the outstanding technical challenges and promoting standardization will improve the clinical applicability of these advanced tools. Ongoing investigation into innovative hybrid modalities is expected to enhance diagnostic capabilities in the future.

Keywords---Medical Diagnostics, Oncology, Hybrid Imaging, PET/MRI, and PET/CT.

Introduction

In the last few years, the combination of different imaging technologies has become very relevant in the diagnostic procedures, including PET/MRI and PET/CT. These modalities integrate into a single scan the metabolic imaging of PET with the high spatial resolution of MRI and CT and dramatically improve diagnostic accuracy and its sub-specialities such as oncology (1). Cancer, particularly lung cancer, has been on the increase around the world and therefore accurate diagnostic techniques remain vital. Staging and particularly the identification of a metastatic deposit is central to designing the management strategy (2). Hybrid imaging has been demonstrated to have better sensitivity and accuracy in tumoral localization and metabolic activity measurements, which are crucial for characterizing tumour behaviour and treatment outcomes (3). Even though PET/CT is used routinely for initial tumor staging of NSCLC patients, PET/MRI might be advantageous due its higher soft tissue contrast, and lower radiation dose, so it can be used in young patients or in cases where repeated scans would be required (4).

There has been mounting evidence of the high diagnostic performance of hybrid imaging as demonstrated by PET/MRI and PET/CT. For example, Alshamrani (5) explained how PET/MRI offered superior diagnosticity in cases of prostate cancer compared to other imaging techniques, as well as Crimi et al. (6), which explicated the importance of this technology concerning the preparation of the treatment plans for rectal cancer patients. Also, the usage of PET/MRI is not only being extended into the diagnostic field of neurodegenerative disease as Lee et al (7) mentioned, but this is also parallel to the idea of personalized medicine. However, issues like standardisation of the protocol and its availability are still issues present even in the current state of the field. This review discusses PET/MRI design, examining integration challenges, attenuation correction, image reconstruction methods, and potential advancements in PET/MRI technology.

Positron Emission Tomography (PET)

Positron Emission Tomography (PET) is a non-invasive imaging method that allows for monitoring of physiological and pathological processes at a molecular

scale (8). It employs nuclear imaging principles through the use of radiotracers, which decay and emit positrons. These positrons undergo annihilation, producing gamma rays emitted at 180 degrees, which are detected by collinearly aligned detectors, such as scintillators (9). PET's electronic collimation provides enhanced sensitivity compared to other nuclear imaging techniques. However, a primary limitation of PET is its lack of anatomical context. Magnetic Resonance Imaging (MRI), on the other hand, offers detailed three-dimensional soft tissue contrast through specific T1 and T2 relaxation times, making it an ideal technique for initial tumor evaluation.

MRI systems operate at Ultra High Frequency (UHF) magnetic fields, providing structural imaging with high spatial resolution and functional contrast, particularly Blood Oxygen Level Dependent (BOLD) contrast (10). Functional MRI techniques such as Diffusion Weighted Imaging (DWI), Magnetic Resonance Spectroscopy (MRS), and Perfusion Weighted Imaging (PWI) yield precise estimations for tumor grading (11, 12). Although MRI provides motion correction during anatomical reconstruction and does not involve ionizing radiation, its functional sensitivity and specificity are lower than those of PET.

Combining PET with MRI can integrate their strengths, offering improved soft tissue contrast, flexible tissue characterization parameters, reduced radiation exposure, and higher sensitivity for specialized clinical and research applications (13). PET/MRI was first proposed in 1990, alongside PET/CT; however, PET/CT advanced more quickly due to fewer technical challenges in combining PET and CT. While PET/CT has proven highly useful, PET/MRI surpasses it in soft tissue contrast, radiation dose reduction, and applicability across body regions, making it ideal for small animal imaging in serial studies (14). A significant limitation of PET/CT lies in its sequential imaging setup, as it requires data collection from separate systems with software-based attenuation correction, which can introduce errors due to patient movement. In contrast, PET/MRI offers motion correction based on MRI data, demonstrating high efficacy across a range of clinical applications, including oncology, cardiology, neurology, and musculoskeletal medicine.

Integration Challenges of PET and MRI Modalities

Integrating PET and MRI in a single system presents considerable challenges, particularly in managing the magnetic field. The goal of integration is to maintain the functional integrity of both modalities. Commonly used designs for integration include Sequential and Simultaneous acquisition. In the Sequential design, PET and MRI scans are conducted one after the other with co-registration software and a uniform patient transfer table (Figure 1). Sequential designs are cost-effective and reduce patient claustrophobia by using separate modalities with magnetic shielding (15). Philips Healthcare uses this design in its TF-PET/MRI system (16).

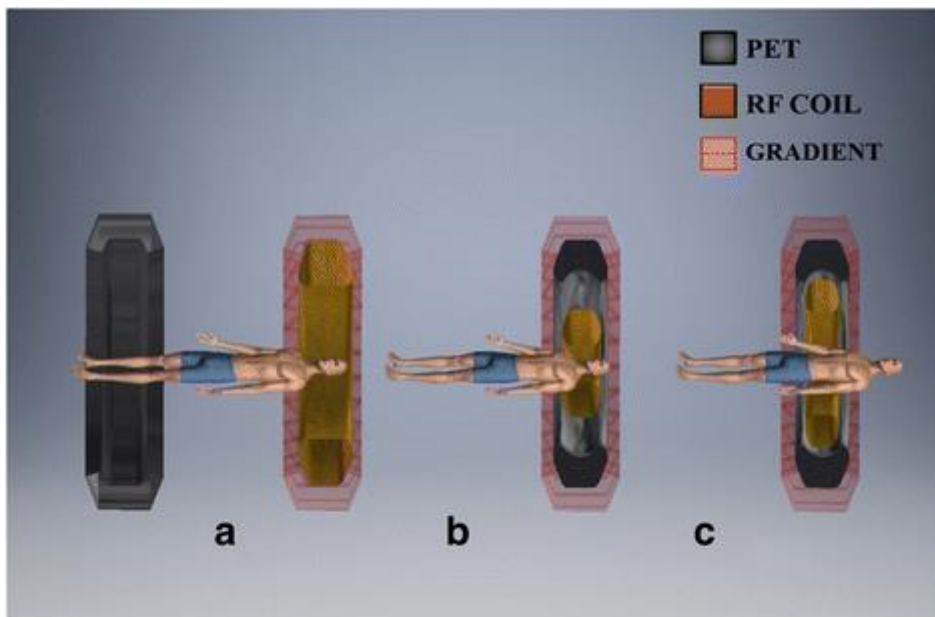


Figure 1. Multiple arrangements of PET/MRI: (a) Sequential layout, (b) Simultaneous PET place MRI scanning device, and (c) Simultaneous completely integrated structure (17).

However, this setup can lead to organ motion artifacts and requires a large space for the equipment, emphasizing the need for simultaneous acquisition. The Simultaneous design uses a shared gantry, with configurations either as a PET insert MRI scanner or a fully integrated system (18). This setup minimizes system occupancy and addresses compatibility challenges between PET and MRI systems, as outlined in Figure 2.

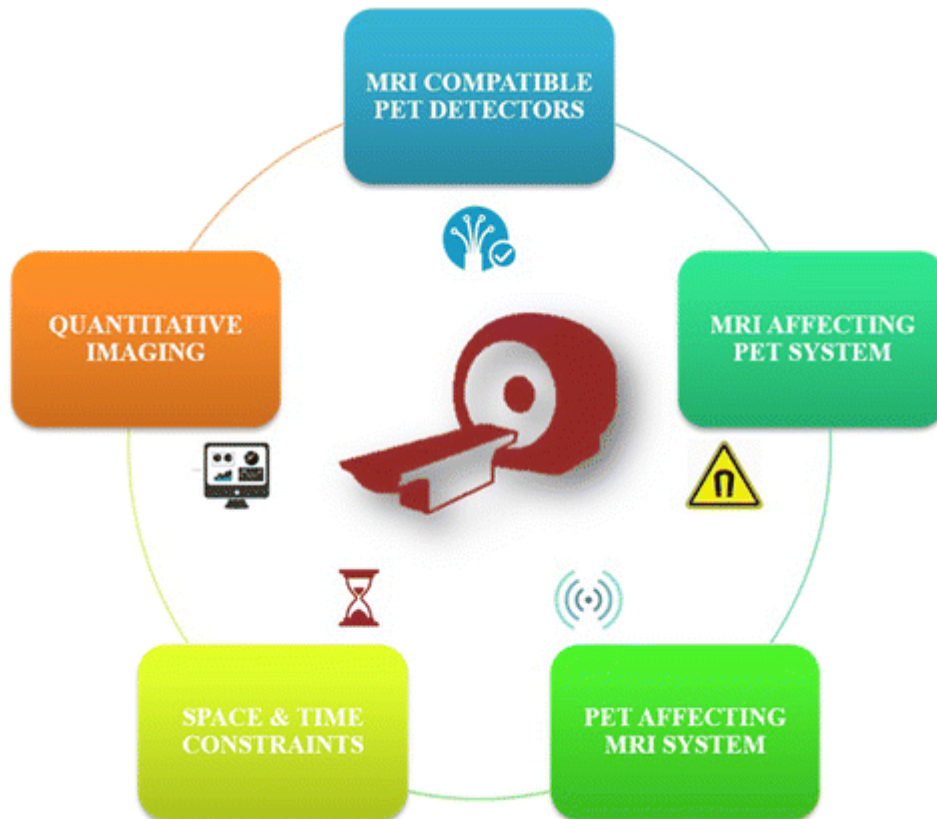

Figure 2. Difficulties in Combining MRI and PET (17)

MRI's Impact on PET Imaging

Integrating PET with MRI faces specific physical interaction challenges due to bore size and detector thickness. High magnetic fields, gradient magnetic fields, and radiofrequency signals in MRI can impair PET functionality, necessitating innovative solutions to maintain both systems' performance (19).

Advances in Hybrid Imaging

Over the past five years, new hybrid imaging techniques have emerged, many with potential for integration with other imaging modalities. These include Fluorescence – X-Ray Computed Tomography (FMT-XCT), PET-Cerenkov light imaging, Fluorescence – Diffuse Optical-Computed Tomography (FT/DOT/XCT), FPhotoacoustic Imaging, luorescence Molecular Imaging-Computed Tomography (FMT-CT), Magnetic Resonance Elastography, and Thermoacoustic Tomography, among others (20-22). Photoacoustic imaging, which combines ultrasound with optical imaging, has shown promise in providing high spatial resolution and optical contrast for organ imaging (23). Cerenkov-light imaging, which captures visible photons from high-speed electrons, has demonstrated effective integration with PET, producing fused images that mitigate some of Cerenkov imaging's limitations. While these advanced systems remain in the preclinical research stage, they are anticipated to play a transformative role in neuroimaging (24).

Comparative Analysis of Three Hybrid Modalities

Hybrid imaging techniques differ significantly in their anatomical, functional, and cognitive capabilities, necessitating a comparative analysis. Figure 3 provides a radar diagram comparing EEG-fMRI, SPECT-CT, PET-CT, MEG-fMRI, EEG-NIRS, and PET-MRI in terms of sensitivity, resolution, cost, and radiation dose. This analysis categorizes modalities into groups based on procedural and principal similarities, revealing the strengths and limitations of each hybrid system (15).

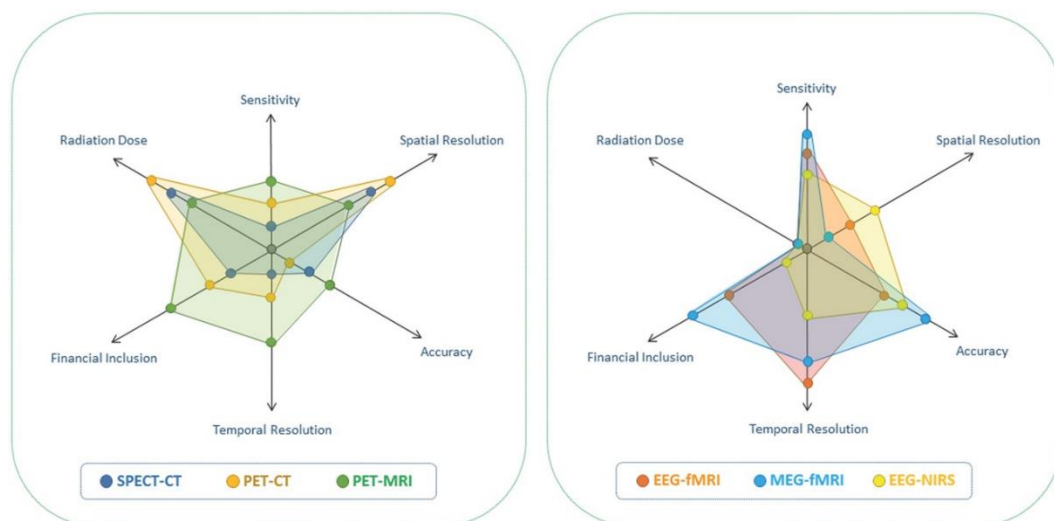


Figure 3. An analytical examination of hybrid imaging techniques for neuroimaging uses across multiple factors (9).

Benefits of Hybrid PET/MRI Compared to PET/CT

Hybrid PET/MRI imaging offers distinct advantages compared to PET/CT, especially in the diagnosis of lesions in the brain, breast, liver, kidneys, and bone, due to MRI's superior soft tissue contrast, which provides enhanced detail relative to CT (25). MRI offers enhanced delineation of lesion margins in intricate areas such as the pelvis and breast. Preliminary research suggests that hybrid PET/MRI could enhance lesion alignment, thereby improving tissue segmentation, attenuation correction, and PET quantification. While CT is currently the standard for detecting small lung nodules, emerging rapid, high-resolution MRI techniques are anticipated to address this limitation (26).

PET/MRI facilitates simultaneous cancer assessment by integrating both modalities in a single session, thereby minimizing overall radiation exposure as CT is unnecessary. PET/MRI provides precise, synchronized multiparametric imaging that integrates high-contrast MRI with the quantitative molecular insights of PET, facilitating a comprehensive evaluation of tumor biology across anatomical, functional, and molecular dimensions (27).

Obstacles in the Implementation of PET/MRI

Despite its potential, PET/MRI encounters obstacles that hinder wider clinical implementation. Optimizing attenuation correction necessitates improved MRI-based techniques for more accurate estimation of tissue density (28). Current Dixon-based correction methods exhibit vulnerability to misregistration resulting from breath-holds and may experience signal loss in proximity to metal artifacts. Additionally, inconsistencies in the segmentation of air cavities can result in quantitative inaccuracies (29). Additional complications arise from MRI contrast agents and coils within the PET field of view, along with magnetic field inhomogeneities, which may influence standardized uptake value (SUV) measurements. The agreement between SUV values and PET/MRI remains inconsistent; however, studies indicate a strong correlation in certain instances, with variations influenced by the generation of the PET/MRI system (30).

New muic MRI sequences are essential for enhancing clinical workflow by minimizing scanning time and improving patient comfort. Research is actively focused on enhanced lung nodule detection, effective motion correction, and dynamic gated PET/MRI with motion correction as key priorities. PET/MRI systems currently exhibit limitations compared to cCT machines, particularly in point-spread-function resolution recovery and time-of-flight capabilities. However, preliminary research indicates potential for incorporating these features to enhance the quantitative accuracy of PET/MRI (28-30).

Additional advancements in hardware, software, and standardization are necessary to tackle these technical challenges. Long-term challenges may involve securing sufficient reimbursement and demonstrating the impact of PET/MRI on patient outcomes relative to PET/CT or MRI alone. Successful integration of PET/MRI in medical settings requires practical considerations such as training radiologists and nuclear medicine specialists in hybrid imaging interpretation, addressing potential role conflicts, establishing standardized protocols for morphologic, functional, and metabolic data, and developing user-friendly software for viewing complex fused images. Institutional stakeholders must acknowledge the benefits of PET/MRI and implement quality assurance protocols. PET/MRI currently accommodates patients requiring both PET and MRI, as well as those needing PET/CT who prefer reduced radiation exposure when basic MRI sequences are clinically adequate (31-33).

Limitations

While hybrid imaging techniques offer substantial diagnostic benefits, ongoing improvements are needed to address their limitations. PET-CT's sequential setup, for example, can result in motion artifacts due to prolonged scanning times. SPECT-CT suffers from lengthy acquisition times and lower spatial resolution, necessitating extensive training. PET-MRI integration requires trade-offs, such as using a wide-bore MRI scanner to accommodate the PET detector ring, which may compromise MRI performance due to thermal effects from magnetic field gradients. EEG-fMRI and MEG-fMRI face limitations related to differing biological foundations, spatial and temporal resolution discrepancies, and challenges in signal integration.

Emerging hybrid modalities like EEG-NIRS show promise in cognitive neuroimaging by leveraging complementary spatial and temporal sensitivity, although precise electrode placement remains challenging. Trimodal systems are still under exploration, with potential for clinical application as research continues.

Conclusion and Future Direction

The integration of anatomical and functional imaging modalities in hybrid imaging techniques, particularly PET/MRI and PET/CT, represents a significant advancement in medical diagnostics. This review highlights significant advancements in diagnostic accuracy and treatment planning achieved through these integrated approaches, especially in the field of oncology. The enhanced soft tissue contrast of PET/MRI, along with its lower radiation exposure relative to PET/CT, establishes it as an effective modality, particularly for pediatric patients or individuals needing repeated imaging assessments. Precise delineation of tumor boundaries, assessment of metabolic activity, and characterization of tissue properties enhance treatment strategy precision, resulting in improved patient outcomes and a potential reduction in unnecessary interventions.

Nonetheless, the field presents several challenges. The integration of PET and MRI presents inherent complexities, especially in addressing magnetic field interference and achieving precise attenuation correction, which require continuous technological advancements. The standardization of protocols and increased accessibility are essential for maximizing the effectiveness of these techniques in various clinical environments. The significant expense linked to these advanced technologies poses a challenge to their widespread adoption, especially in resource-limited settings.

Future directions in hybrid imaging research must concentrate on several critical areas. Continued technological innovation is essential for enhancing the efficiency and robustness of system integration, reducing artifacts, and improving image quality. This involves the advancement of more refined attenuation correction techniques, and the investigation of innovative detector designs to enhance sensitivity and spatial resolution. Secondly, research should concentrate on broadening the clinical applications of hybrid imaging beyond oncology, investigating its potential in cardiology, neurology, and additional medical specialties. Further validation studies are necessary in these areas to determine the clinical utility and cost-effectiveness of hybrid imaging relative to existing techniques. Thirdly, efforts must focus on creating more user-friendly interfaces and streamlined workflows to facilitate the acquisition and interpretation of hybrid images, thereby enhancing accessibility for clinicians.

The integration of emerging imaging modalities, including photoacoustic imaging and Cerenkov luminescence imaging, significantly enhances the capabilities of hybrid systems. These techniques provide distinct benefits regarding spatial resolution, contrast mechanisms, and the capability for molecular-level imaging. The advancement of sophisticated image analysis techniques, particularly those utilizing artificial intelligence (AI), is essential for automating image processing, enhancing diagnostic accuracy, and streamlining clinical workflows. Addressing

these challenges and pursuing future directions will enable hybrid imaging to evolve, thereby transforming medical diagnostics and enhancing patient care.

References

1. Hussain S, Mubeen I, Ullah N, Shah SSUD, Khan BA, Zahoor M, et al. Modern diagnostic imaging technique applications and risk factors in the medical field: a review. *BioMed research international*. 2022;2022(1):5164970.
2. Zhang M, Liu Z, Yuan Y, Yang W, Cao X, Ma M, et al. Head-to-head comparison of 18F-FDG PET/CT and 18F-FDG PET/MRI for lymph node metastasis staging in non-small cell lung cancer: a meta-analysis. *Diagnostic and Interventional Radiology*. 2024;30(2):99.
3. Mirshahvalad SA, Metser U, Basso Dias A, Ortega C, Yeung J, Veit-Haibach P. 18F-FDG PET/MRI in detection of pulmonary malignancies: a systematic review and meta-analysis. *Radiology*. 2023;307(2):e221598.
4. Crimi F, Zanon C, Crimi A, Cabrelle G, Quaia E. New Trends and Advances in MRI and PET Hybrid Imaging in Diagnostics. *MDPI*; 2023. p. 2936.
5. Alshamrani AFA. Diagnostic Accuracy of Molecular Imaging Techniques for Detecting Prostate Cancer. *Diagnostics*. 2024;14(13):1315.
6. Crimi F, Valeggia S, Baffoni L, Stramare R, Lacognata C, Spolverato G, et al. [18F] FDG PET/MRI in rectal cancer. *Annals of Nuclear Medicine*. 2021;35:281-90.
7. Lee J, Renslo J, Wong K, Clifford TG, Beutler BD, Kim PE, et al. Current Trends and Applications of PET/MRI Hybrid Imaging in Neurodegenerative Diseases and Normal Aging. *Diagnostics*. 2024;14(6):585.
8. Catalano OA, Daye D, Signore A, Iannace C, Vangel M, Luongo A, et al. Staging performance of whole-body DWI, PET/CT and PET/MRI in invasive ductal carcinoma of the breast. *International journal of oncology*. 2017;51(1):281-8.
9. Padmanabhan P, Nedumaran AM, Mishra S, Pandarinathan G, Archunan G, Gulyás B. The advents of hybrid imaging modalities: a new era in neuroimaging applications. *Advanced Biosystems*. 2017;1(8):1700019.
10. Olman CA. What multiplexing means for the interpretation of functional MRI data. *Frontiers in Human Neuroscience*. 2023;17:1134811.
11. Laukamp KR, Lindemann F, Weckesser M, Hesselmann V, Ligges S, Woelfer J, et al. Multimodal imaging of patients with gliomas confirms 11c-MET PET as a complementary marker to MRI for noninvasive tumor grading and intraindividual follow-up after therapy. *Molecular imaging*. 2017;16:1536012116687651.
12. Sałyga A, Guzikowska-Ruszkowska I, Czepczyński R, Ruchała M. PET/MR—a rapidly growing technique of imaging in oncology and neurology. *Nuclear Medicine Review*. 2016;19(1):37-41.
13. Sonni I, Baratto L, Park S, Hatami N, Srinivas S, Davidzon G, et al. Initial experience with a SiPM-based PET/CT scanner: influence of acquisition time on image quality. *EJNMMI physics*. 2018;5:1-12.
14. Spick C, Herrmann K, Czernin J. 18F-FDG PET/CT and PET/MRI perform equally well in cancer: evidence from studies on more than 2,300 patients. *Journal of Nuclear Medicine*. 2016;57(3):420-30.

15. Kang HG, Yamaya T. Multi Imaging Devices: PET/MRI. Handbook of Particle Detection and Imaging: Springer; 2021. p. 1317-57.
16. Rajiah P, Hojjati M, Lu Z, Kosaraju V, Partovi S, O'Donnell JK, et al. Feasibility of carotid artery PET/MRI in psoriasis patients. American Journal of Nuclear Medicine and Molecular Imaging. 2016;6(4):223.
17. Musafargani S, Ghosh KK, Mishra S, Mahalakshmi P, Padmanabhan P, Gulyás B. PET/MRI: a frontier in era of complementary hybrid imaging. European journal of hybrid imaging. 2018;2:1-28.
18. Therriault-Proulx F, Wen Z, Ibbott G, Beddar S. Effect of magnetic field strength on plastic scintillation detector response. Radiation measurements. 2018;116:10-3.
19. Davydova MP, Meng L, Rakhmanova MI, Jia Z, Berezin AS, Bagryanskaya IY, et al. Strong Magnetically-Responsive Circularly Polarized Phosphorescence and X-Ray Scintillation in Ultrarobust Mn (II)-Organic Helical Chains. Advanced Materials. 2023;35(35):2303611.
20. Yamamoto S, Suzuki M, Kato K, Watabe T, Ikeda H, Kanai Y, et al. Development of gamma-photon/Cerenkov-light hybrid system for simultaneous imaging of I-131 radionuclide. Nuclear Instruments and Methods in Physics Research Section A: Accelerators, Spectrometers, Detectors and Associated Equipment. 2016;830:444-8.
21. Mariappan YK, Dzyubak B, Glaser KJ, Venkatesh SK, Sirlin CB, Hooker J, et al. Application of modified spin-echo-based sequences for hepatic MR elastography: evaluation, comparison with the conventional gradient-echo sequence, and preliminary clinical experience. Radiology. 2017;282(2):390-8.
22. Lin T-H, Zhan J, Song C, Wallendorf M, Sun P, Niu X, et al. Diffusion basis Spectrum imaging detects axonal loss after transient dexamethasone treatment in optic neuritis mice. Frontiers in Neuroscience. 2021;14:592063.
23. Wang X, Witte RS, Xin H. Thermoacoustic and photoacoustic characterizations of few-layer graphene by pulsed excitations. Applied Physics Letters. 2016;108(14).
24. Yamamoto S, Hamamura F, Watabe T, Ikeda H, Kanai Y, Watabe H, et al. Development of a PET/Cerenkov-light hybrid imaging system. Medical Physics. 2014;41(9):092504.
25. Stecco A, Buemi F, Cassarà A, Matheoud R, Sacchetti GM, Arnulfo A, et al. Comparison of retrospective PET and MRI-DWI (PET/MRI-DWI) image fusion with PET/CT and MRI-DWI in detection of cervical and endometrial cancer lymph node metastases. La radiologia medica. 2016;121:537-45.
26. Hirsch FW, Sorge I, Vogel-Claussen J, Roth C, Gräfe D, Päts A, et al. The current status and further prospects for lung magnetic resonance imaging in pediatric radiology. Pediatric Radiology. 2020;50:734-49.
27. Roy T. MRI Characterization of Peripheral Arterial Disease for Planning Percutaneous Vascular Interventions: University of Toronto (Canada); 2018.
28. Teuho J, Torrado-Carvajal A, Herzog H, Anazodo U, Klen R, Iida H, et al. Magnetic resonance-based attenuation correction and scatter correction in neurological positron emission tomography/magnetic resonance imaging—current status with emerging applications. Frontiers in physics. 2020;7:243.
29. Catana C. Attenuation correction for human PET/MRI studies. Physics in Medicine & Biology. 2020;65(23):23TR02.

30. Boada FE, Koesters T, Block KT, Chandarana H. Improved detection of small pulmonary nodules through simultaneous MR/PET imaging. *PET clinics*. 2018;13(1):89-95.
31. Rakvongthai Y, El Fakhri G. Magnetic Resonance-based Motion Correction for Quantitative PET in Simultaneous PET-MR Imaging. *PET clinics*. 2017 Jul 1;12(3):321-7.
32. Mehranian A, Arabi H, Zaidi H. Vision 20/20: magnetic resonance imaging-guided attenuation correction in PET/MRI: challenges, solutions, and opportunities. *Medical physics*. 2016 Mar;43(3):1130-55.
33. Lindén J, Teuho J, Klén R, Teräs M. Are Quantitative Errors Reduced with Time-of-Flight Reconstruction When Using Imperfect MR-Based Attenuation Maps for 18F-FDG PET/MR Neuroimaging?. *Applied Sciences*. 2022 May 3;12(9):4605.

PET/CT و PET/MRI التقدم في تقنيات التصوير المتكاملة: تعزيز الدقة التشخيصية باستخدام الملخص

، بمثابة نقلة نوعية في مجال التشخيص الطبي PET/CT و PET/MRI الخلفية تُعد تقنيات التصوير المتكاملة، بما في ذلك (مع الدقة التشريحية التي توفرها تصوير الرنين PET من خلال دمج البيانات الأيضية من التصوير بالبوزيترونات الإصداري) . يحسن هذا الدمج من الدقة التشخيصية، خاصةً في مجال علم (CT) أو التصوير المقطعي المحوسب (MRI) المغناطيسي) ، ولكن PET/CT الأورام، حيث تُعد دقة تحديد موقع الورم وتوصيفه أمرًا أساسيًا لتخطيط العلاج الفعال. عادةً ما يتم استخدام تقدم فوائد مثل التباين النسيجي المحسّن وانخفاض التعرض للإشعاع، مما يجعلها مفيدة بشكل خاص للمرضى PET/MRI الأطفال أو الأفراد الذين يحتاجون إلى إجراء فحوصات متعددة. لا تزال هناك تحديات في التوحيد القياسي والإتاحة ومعالجة القيود الفيزيائية الكامنة في تكامل هذه الأساليب التصويرية المختلفة.

، من خلال تحليل PET/CT و PET/MRI الهدف تهدف هذه المراجعة إلى تقييم الوضع الحالي للتصوير المتكامل، تحديدًا فعاليتها التشخيصية وتحديات التكامل والتطورات المستقبلية المحتملة. تم تحليل مزايا وعيوب كل تقنية، ومقارنة تطبيقاتها السريرية، والتحقيق في التقنيات المتكاملة الناشئة.

في PET/CT و PET/MRI المنهجية تم إجراء مراجعة شاملة للأدبيات، بما في ذلك الدراسات والمقالات عن تطبيقات مجالات مرضية متنوعة. تم فحص الدراسات الحالية حول الدقة التشخيصية وتحديات التكامل التقني والتطورات المستقبلية في تكنولوجيا التصوير المتكامل.

النتائج أظهرت المراجعة أدلة كبيرة على الفعالية التشخيصية المعززة للتصوير المتكامل مقارنةً بالتقنيات الفردية. تتمتع بفوائد مميزة في توصيف الأنسجة الرخوة وتقليل التعرض للإشعاع. تم تحديد تحديات التكامل، خاصةً في إدارة PET/MRI تداخل المجال المغناطيسي وتحقيق التصحيح الدقيق للامتصاص. تم فحص التقنيات المتكاملة الناشئة التي قد تكون لها تطبيقات سريرية مستقبلية.

، تقدمًا ملحوظًا في مجال التشخيص الطبي، حيث يوفر دقة PET/CT و PET/MRI يُعد التصوير المتكامل، تحديدًا الخلاصة محسنة وتعرض أقل للإشعاع. إن حل التحديات التقنية المتبقية وتعزيز التوحيد القياسي سيحسن من القابلية التطبيقية السريرية لهذه الأدوات المتقدمة. من المتوقع أن تؤدي الأبحاث المستمرة في التقنيات المتكاملة المبتكرة إلى تعزيز القدرات التشخيصية في المستقبل.

PET/CT ، و PET/MRI الكلمات الرئيسية: التشخيص الطبي، علم الأورام، التصوير المتكامل،