

How to Cite:

Choudhary, A., Ahuja, U. S., Rathore, A., Puri, N., Budakoti, A., & Das, S. R. (2022). Evaluation of pneumatization of the temporal bone with cone beam computed tomography: A radiographic study. *International Journal of Health Sciences*, 6(S1), 1350-1359. <https://doi.org/10.53730/ijhs.v6nS1.4896>

Evaluation of Pneumatization of the Temporal Bone with Cone Beam Computed Tomography: A Radiographic Study

Anuridhi Choudhary

Senior Lecturer, Department of Oral Medicine and Radiology, Faculty of Dental Sciences, SGT University, Gurugram, India

Upasana Sethi Ahuja

Professor and Head, Department of Oral Medicine and Radiology, I.T.S- Centre for dental studies and research, Muradnagar, Ghaziabad, U.P. India

Akshay Rathore

Reader, Department of Oral Medicine and Radiology, I.T.S- Centre for dental studies and research, Muradnagar, Ghaziabad, U.P. India

Nidhi Puri

Professor, Department of Oral Medicine and Radiology, I.T.S- Centre for dental studies and research, Muradnagar, Ghaziabad, U.P. India

Akansha Budakoti

Senior Lecturer, Department of Oral Medicine and Radiology, KM Shah Dental College and Hospital, Sumandeep Vidyapeeth Deemed to be University, Piparia, Vadodara, India

Smiti Rekha Das

Private Practitioner, Good Health dental clinic and Oro facial pain Centre, Dibrugarh, India

Abstract---Purpose: The temporal bone depicts a variety of pneumatization patterns which are incidental findings but have a great clinical significance for planning surgical procedures in this area. The purpose of the present study was to evaluate the prevalence and incidence of pneumatization of articular tubercle and roof of glenoid fossa. Methods: 520 CBCT scans of 260 patients were evaluated to determine pneumatized articular eminence prevalence and characteristics. Gender, laterality and type of pneumatization were observed for both the left and right sides. Chi-square test was

used to evaluate the relationship between pneumatized articular eminence and roof of glenoid fossa and gender and type. The software used for the statistical analysis was SPSS version 21.0 and the p -value < 0.05 were considered to indicate statistical significance. Results: PAT was detected in 180 (34.6%), consisting of 105 (20.2%) unilocular and 75 (14.4%) multilocular. PRGF was observed in 224 (43.1%) patients, consisting of 80 (15.4%) unilocular and 144 (27.7%) multilocular. There was 102(19.6%), 93(17.9%) unilateral PAT and PRGF and 44 (8.5%), 74 (14.2%) bilateral PAT and PRGF respectively. Significant correlation was observed for the distribution of types of PAT according to gender (p -value= 0.001).

Keywords---computed tomography, cone-beam, pneumatization, temporal bone, temporomandibular joint.

Introduction

Pneumatization is the process in which the epithelium infiltrates the developing bone and epithelium-lined air cell cavities are formed.¹ The skull including the temporal bone contains many air-filled cavities which are defined as pneumatization.² Tremble (1934) reported the presence of air cells in the temporal bone.³ Tyndall and Matteson (1985) defined pneumatized articular eminence (PAT) as accessory air cells which occur at the base of the zygomatic arch and articular eminence of the temporal bone.⁴ Carter et al again accentuated the presence of this phenomenon and termed these air cells as zygomatic air cell defects (ZACDs).⁵

The temporal bones form the lateral walls of the cranial vault and contribute to the zygomatic arches. They are derived from five separate ossification centers that fuse after birth which are the squamous, tympanic, mastoid, styloid and petrous. Zygomatic process is a part of squamous portion which joins the zygomatic bone and thus forms the articular tubercle and glenoid fossa.⁶ When these air cells are distributed in the zygomatic process of the temporal bone, they are termed as the pneumatized articular tubercle (PAT) and the pneumatized roof of the glenoid fossa (PRGF).⁷ The pneumatization of temporal bone is clinically asymptomatic and radiographically, they appear as radiolucent defect which is similar to that seen in the mastoid process in the zygomatic process of temporal bone.^{2,4} They are described as unilateral or bilateral and have two pattern types: unilocular or multilocular.⁴

Pneumatized temporal bone are observed very seldom but, when present, it may represent as the probability for complications during the surgical manipulation of that temporomandibular joint (TMJ)² and they also act for sites of minimal resistance and thus facilitate the spread of various pathological processes or infections into the joint.⁸ Over the years, there are various methods which were used to evaluate the pneumatization. In spite of dose and cost benefits, panoramic radiography is subjected to superimposition, which jeopardize the diagnostic accuracy of this technique to evaluate the temporal bone pneumatization⁹ High-resolution CT is also contemplated as the imaging

technique of choice for assessing bony structures and airspaces in the base of the skull however, it subject patients to a high radiation dose.⁹

Cone beam computed tomography (CBCT) has lately been used as an alternative 3-D imaging modality as it has increased precision for oral and maxillofacial diagnostic purposes, including the evaluation of cases with PAT and PRGF. Additionally, the medial portion of the articular eminence could only be thoroughly evaluated on CT or CBCT.⁷ The aim of the study was to evaluate the prevalence and incidence of pneumatization of articular tubercle and roof of glenoid fossa.

Methods

The present study was conducted in the department of Oral Medicine and Radiology of the reputed Dental college of North India after taking the ethical clearance from the institutional ethical committee. The study design was retrospective, cross-sectional study. The CBCT scans were taken retrospectively from the images obtained for implant planning, orthodontics, TMJ disorders, and maxillofacial pathologies such as cysts or tumors. The study sample comprised of 520 CBCT scans of 260 patients.

Imaging procedure

The CBCT images were taken with a NewTom GiANO (CEFLA-SC, CEFLA DENTAL GROUP, ITALY) with a maximum output of 90 kvp, 3 mAs, typical exposure time of 3.6 s and voxel resolution of 150 microns. All images were reviewed on a digital image workstation using NNT software version 7.0 (New Net Technologies Ltd. Naples) by two oral and maxillofacial radiologists independently and if there were any conflicts in the examination, it was resolved by the recommendations of more experienced oral and maxillofacial radiologist.

The CBCT scans were evaluated in the three planes and the presence of pneumatization was recorded at the articular eminence and roof of the glenoid fossa. The PAT and PRGF were only identified on the CBCT scans if the characteristics described by Tyndall and Matteson were found. The characteristics included a radiolucent defect in the zygomatic process of the temporal bone with the appearance similar to mastoid air cells, extending anteriorly to the articular eminence but not beyond the zygomaticotemporal suture, with no enlargement or cortical destruction of the zygoma. If the radiolucent defect will be located on the roof of the glenoid fossa above the condyle, it will be defined as PRGF.

PAT and PRGF were also categorized as unilocular or multilocular. If a single radiolucent defect with well-defined bony borders was present, it was defined as unilocular pneumatization, whereas numerous small radiolucent cavities were defined as multilocular pneumatization. The prevalence of pneumatization by gender and laterality was determined. The software used for the statistical analysis was SPSS version 21.0. Chi-square test was used to compare the difference between variables. Values of $p < 0.05$ were considered to indicate statistical significance

Results

The sample consisted of CBCT images from 260 patients out of which 305 (58.7%) were males and 215 (41.3%) were females (Graph 1). Table 1 depicts the prevalence of pneumatization regarding with its types, localization and laterality. Pneumatization of articular eminence (PAT) was detected in 180 (34.6%), out of which 105 (20.2%) was unilocular and 75 (14.4%) was multilocular. Pneumatization of roof of glenoid fossa (PRGF) was observed in 224 (43.1%) patients, out of which 80 (15.4%) was unilocular and 144 (27.7%) was multilocular. There was 102(19.6%), 93(17.9%) unilateral PAT and PRGF and 44 (8.5%), 74 (14.2%) bilateral PAT and PRGF respectively. Table 2 depicts the distribution of types of PAT and PRGF according to gender and the results were statistically significant for PAT (p-value= 0.001) and non-significant for PRGF (p-value = 0.887). Table 3 depicts the distribution of laterality of PAT and PRGF according to gender and the results were not significant statistically (p value = 0.209, 0.154 respectively).

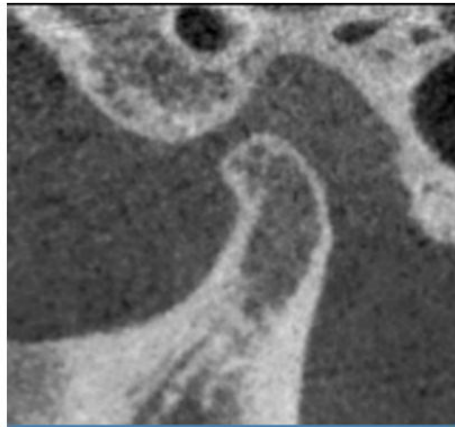


Figure 1. Unilocular Pneumatized articular tubercle

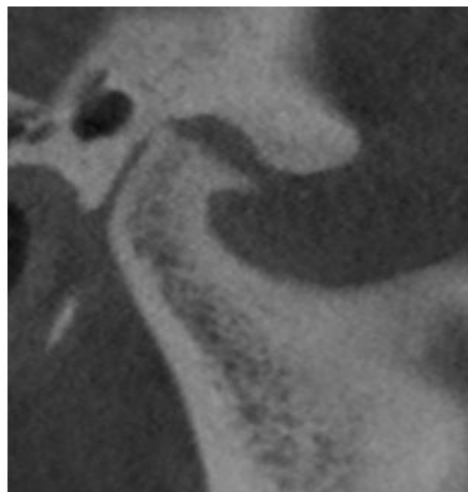


Figure 2. Unilocular Pneumatization of roof of glenoid fossa

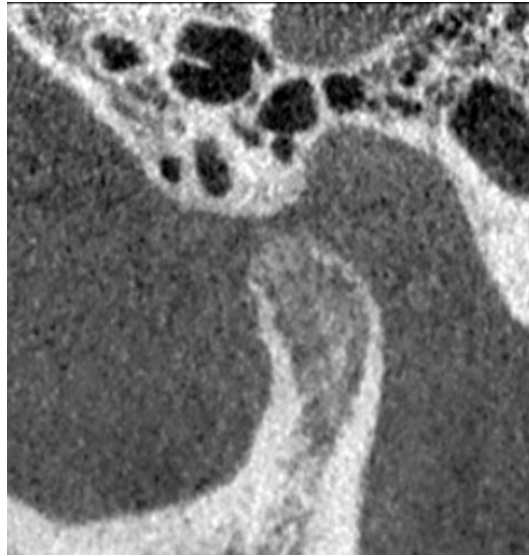


Figure 3. Multilocular pneumatized articular tubercle

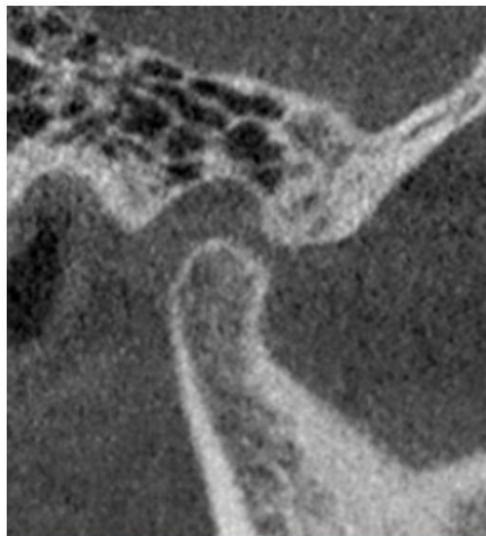


Figure 4. Multilocular Pneumatization of roof of glenoid fossa

Discussion

The development of air cell-like cavities in bone¹⁰ which is preceded by the formation of bone cavities, a normal physiological process related to periosteal activity is termed as pneumatization. In these pneumatized cavities, primitive bone marrow de-differentiates into a loose mesenchymal connective tissue. When the epithelium invaginates into this connective tissue, it produces a mucous membrane that then undergoes atrophy, leaving a thin residual lining membrane which is attached to the periosteum. Furthermore, recession of this residual lining membrane and subepithelial bone resorption leads to enlargement of air cells.¹¹

The process of pneumatization usually begins prenatally during the 22nd to 24th gestational weeks. At around 28th weeks of gestation, the pneumatization of petrous apex begins.¹ The occurrence of complete adult temporal pneumatization can be divided into three stages: the infantile (from birth to 2 years of age), the transitional (from 2 years to 5 years) and the adult. In the first stage i.e. infantile, air cells initiate to appear and are readily visible by 2 years. In the second stage i.e. transitional, there is gradual enlargement of mastoid (squamosmastoid) along with migration of air cells toward the periphery. The air cells which vary in size and shape become more distinct with time due to progressive calcification of walls. During the adult stage, the growth of pneumatization ceases.¹¹ Similarly, the process of pneumatization of the temporal bone is mostly completed by the age of 10 years in females and 15 years in males.¹

The categorization of pneumatization of temporal bone is complex¹¹ and they have been classified as mastoid, perilabyrinthine, petrous apex, and accessory parts. The articular eminence and glenoid fossa together form the zygomatic process, which is part of the squamous portion and is a subdivision of the accessory part.¹² CBCT is used in these recent times for imaging of the head and neck region including the temporal bone, specifically middle and inner ear structures. CBCT not only is being used in pre-operative evaluation of the temporal bone but also is now being tested intraoperatively for surgery of the base of skull and the temporal bone.¹

The prevalence of pneumatization of articular eminence and roof of glenoid fossa was evaluated in this study. Pneumatization type is classified by the cavitation pattern. Tyndall and Matteson¹⁵ provided the first detailed data on population distribution and radiographic appearance of pneumatized articular eminence as they evaluated 1061 panoramic radiographs, and concluded that PAT was found in 28 (2.6%) patients with a mean age of 32.5 years and an age range of 15–74 years.

In the present study, the prevalence of PAT was 180 (34.6%), out of which unilocular PAT was 105 (20.2%) and multilocular PAT was 75 (14.4%). Bronoosh P et al⁹ reported PAT in 43 (9.55%) joints, out of which 15 cases of PAT were unilocular and 28 were multilocular. In another study, Ladeira et al¹⁵ observed PAT in 15.5% of total patients, out of which 3.4% were unilocular and 96.6% were multilocular. Miloglu et al,⁵ found that 17 (41.5%) of PATs were unilocular and 24 (58.5%) of PATs were multilocular. Ilguy et al⁸ reported even higher prevalence of PAT in 65.8% of joints.

In the present study, the prevalence of the pneumatization of roof of glenoid fossa (PRGF) was 224 (43.1%), out of which 80 (15.4%) was unilocular and 144 (27.7%) was multilocular. Ilguy et al⁸ reported a low rate of prevalence (11.7%) of PRGF. Ladeira et al¹⁵ found PRGF in 30.2% of cases, out of which 0.02% was unilocular and 99.8% were multilocular. In a study conducted by Buyuk C et al¹², PRGF was detected in 39.6% of joints, out of which 2.9% were unilocular and 26.7% were multilocular. The present study revealed a prevalence of 27.7% for multilocular PRGF, which was higher than that of multilocular PAT (14.4%). These findings suggest that multilocular PRGF may be more likely to occur than multilocular than PAT. The prevalence of unilocular PRGF was 15.4% which was lower than

that of unilocular PAT (20.2%). These findings suggest that unilocular PAT may be more likely to occur than unilocular PRGF.

We have also evaluated laterality of PAT and PRGF. Our study showed the higher prevalence of unilateral pneumatization than the bilateral pneumatization. There was 102(19.6%) unilateral PAT, 93(17.9%) unilateral PRGF, 44 (8.5%) bilateral PAT and 74 (14.2%) bilateral PRGF which were consistent with the literature. In the current literature, there is variability about the laterality of PAT. Mosavat et al. described that the unilateral-to-bilateral ratios for PAT and PRGF were 2.2:1 and 2.5:1, respectively.¹² İlgüy et al.⁸ reported a unilateral-to-bilateral ratio of 1:1.3, while Miloglu et al.⁵ reported a ratio of 3:1. Meanwhile, the ratio was 1.2:1 in both the present study and that by Ladeira et al.¹⁵ However, Ladeira et al. pointed out that bilateral cases were predominant when PAT and PRGF were evaluated together.¹⁵

In the present study, laterality of pneumatization was also observed according to gender but no correlation was found. There were 53 males and 49 females having unilocular PAT and 28 males and 16 females having bilateral PAT. On the other hand, there were 60 males and 33 females having unilocular PRGF and 39 males and 35 females having multilocular PRGF. The locularity of PAT and PRGF were also evaluated according to gender. There were significant correlations between gender and prevalences of PAT in the present study. There were 45 males and 60 having unilocular PAT and 64 males and 11 females having multilocular PAT. The results were statistically significant for PAT (p-value= 0.001). Our results are in consistent with İlgüy et al.⁸ who reported a correlation between gender and pneumatization, with females being more predisposed than males.

On the contrary, there were no correlations between gender and prevalence of PRGF in the present study. There were 50 males and 30 females having unilocular PRGF and 88 males and 56 females having multilocular PRGF. Our results were in consistent with several previous studies conducted by Nagaraj T et al¹⁶, Khojastepour L et al⁶ and Broonosh P et al⁹. Though pneumatization is an incidental finding in majority of the cases but the evaluation of pneumatization of the articular eminence and TMJ fossa is important as it is a defect that facilitates the spread of various disease processes along the TMJ joint, including tumors, inflammation, and fractures due to minimal resistance.¹² Tumors of the mastoid process and ear may extend into the TMJ, moreover otitis or mastoiditis may involve the TMJ and can result in ankylosis.¹⁵ Also, in the situations where it is mandatory to surgically manipulate the articular eminence, PAT and PRGF should be contemplated as a complicating factor.¹²

In regular oral and maxillofacial radiology practice, the temporal bone is routinely visualized on temporomandibular joint and orthodontic studies or examination; therefore, it is important for dentists and oral radiologists to have knowledge about normal anatomical variations and pneumatization patterns to recognize any pathologic changes and make appropriate referrals to specialists in this region, such as otorhinolaryngologists and neuroradiologists for consultations.¹ Radio-anatomical knowledge of the pneumatized structures provides detailed information to understand the spreading pattern and differential diagnosis of pathological entities located in this anatomical area.¹² Though, the treatment of

PAT is not necessary but asymptomatic lesions should be kept under observation and follow up.¹⁰

Conclusion

CBCT scan are precise and authentic means to evaluate the exact size, type and pattern of pneumatization and their relationship to the surrounding structures. In the present study, it was observed that the prevalence of unilocular variant of pneumatization of articular eminence (PAT) and multilocular variant of pneumatization of roof of glenoid fossa (PRGF) was more commonly observed. Therefore, during routine radiological evaluation, oral and maxillofacial radiologists should always consider the presence of PAT and PRGF in the temporal bone. Further research is warranted in larger populations and specific groups of patients to provide a clearer picture of this clinically relevant issue.

References

1. Jadhav AB, Fellows D, Hand AR, Tadinada A, Lurie AG. Classification and volumetric analysis of temporal bone pneumatization using cone beam computed tomography. *Oral Surg Oral Med Oral Pathol Oral Radiol* 2014;117(3):376-84.
2. Yavuz MS, Aras MH, Gungor MH, Buyukkurt MC. Prevalence of the pneumatized articular eminence in the temporal bone. *J Craniomaxillofac Surg* 2009;37(3):137-9.
3. Tyndall DA, Matteson SR. Radiographic Appearance and Population Distribution of the Pneumatized Articular Eminence of the Temporal Bone. *J Oral Maxillofac Surg*. 1985;43(7):493-7.
4. de Rezende Barbosa GL, Nascimento Mdo C, Ladeira DB, Bomtorim VV, da Cruz AD, Almeida SM. Accuracy of digital panoramic radiography in the diagnosis of temporal bone pneumatization: a study in vivo using cone-beam computed tomography. *J Craniomaxillofac Surg* 2014;42(5):477-81.
5. Miloglu O, Yilmaz AB, Yildirim E, Akgul HM. Pneumatization of the articular eminence on cone beam computed tomography: prevalence, characteristics and a review of the literature. *Dentomaxillofac Radiol* 2011;40(2):110-4.
6. Khojastepour L, Mirbeigi S, Ezoddini F, Zeighami N. Pneumatized Articular Eminence and Assessment of Its Prevalence and Features on Panoramic Radiographs. *J Dent (Tehran)* 2015;12(4):235-42.
7. Mosavat F, Ahmadi A. Pneumatized Articular Tubercle and Pneumatized Roof of Glenoid Fossa on Cone Beam Computed Tomography: Prevalence and Characteristics in Selected Iranian Population. *3dj* 2015;4(3):10-4.
8. Ilguy M, Dolekoglu S, Fisekcioglu E, Ersan N, Ilguy D. Evaluation of Pneumatization in the Articular Eminence and Roof of the Glenoid Fossa with Cone-Beam Computed Tomography. *Balkan Med J* 2015;32(1):64-8.
9. Bronoosh P, Shakibafard A, Mokhtare MR, Munesi Rad T. Temporal bone pneumatisation: a computed tomography study of pneumatized articular tubercle. *Clin Radiol* 2014;69(2):151-6.
10. Shokri A, Noruzi-Gangachin M, Baharvand M, Mortazavi H. Prevalence and characteristics of pneumatized articular tubercle: First large series in Iranian people. *Imaging Sci Dent* 2013;43(4):283-7.

11. Orhan K, Delilbasi C, Orhan AI. Radiographic evaluation of pneumatized articular eminence in a group of Turkish children. *Dentomaxillofac Radiol* 2006;35:365–70.
12. Buyuk, C., Gunduz, K, Avsever, H. Prevalence and characteristics of pneumatizations of the articular eminence and roof of the glenoid fossa on cone-beam computed tomography. *Oral Radiol* 2018.
13. Khojastepour L, Paknahad M, Abdalipur V, Paknahad M. Prevalence and Characteristics of Articular Eminence Pneumatization: A Cone-Beam Computed Tomographic Study. *J Maxillofac. Oral Surg.* 2018;17(3):339–44.
14. Tyndall DA, Matteson SR. Radiographic Appearance and Population Distribution of the Pneumatized Articular Eminence of the Temporal Bone. *J Oral Maxillofac Surg.* 1985;43(7):493-7.
15. Ladeira DB, Barbosa GL, Nascimento MC, Cruz AD, Freitas DQ, Almeida SM. Prevalence and characteristics of pneumatization of the temporal bone evaluated by cone beam computed tomography. *Int J Oral Maxillofac Surg* 2013;42(6):771-5.
16. Nagaraj T, Nigam H, Balraj L, Santosh H, Ghouse N, Tagore S. A population-based retrospective study of zygomatic air cell defect in Bengaluru. *J Med Radiol Pathol Surg.* 2016;3(6):5–8.

Graphs and Tables

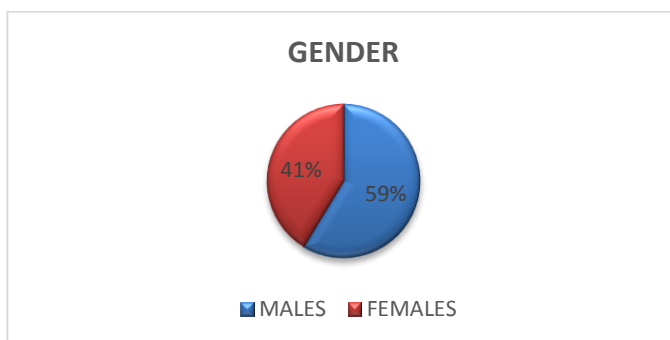


Figure 5. Distribution of Gender

Table 1

Prevalence of pneumatization regarding with its types, localization and laterality

	SAMPLE	PAT n (%)	PRGF n (%)
TYPE	520 (260)	180 (34.6)	224 (43.1)
	UNILOCULAR	105 (20.2)	80 (15.4)
	MULTILOCULAR	75 (14.4)	144 (27.7)
LATERALITY		PAT	PRGF
	UNILATERAL	102 (19.6)	93 (17.9)
	BILATERAL	44 (8.5)	74 (14.2)

Table 2
Distribution of types of PAT and PRGF according to gender

GENDER	UNILOCULAR PAT n (%)	MULTILOCULAR PAT n (%)	UNILOCULAR PRGF n (%)	MULTILOCULAR PRGF n (%)
MALES	45 (41.30)	64 (58.70)	50 (36.20)	88 (63.80)
FEMALES	60 (84.50)	11 (15.50)	30 (34.90)	56 (65.10)
TOTAL	105	75	80	144

Table 3
Distribution of laterality of PAT and PRGF according to gender

GENDER	UNILATERAL PAT n (%)	BILATERAL PAT n (%)	UNILATERAL PRGF n (%)	BILATERAL PRGF n (%)
MALES	53 (65.40)	28 (34.60)	60 (60.60)	39 (39.40)
FEMALES	49 (75.40)	16 (24.60)	33 (48.50)	35 (51.50)
TOTAL	102	44	93	74