

How to Cite:

Mela, O. A., Tawfik, M. A.-M., Ahmed, W. M. A. S., & Abdel-Rahman, F. H. (2022). Efficacy of nano-hydroxyapatite coating on osseointegration of early loaded dental implants. *International Journal of Health Sciences*, 6(S2), 696–712.
<https://doi.org/10.53730/ijhs.v6nS2.4998>

Efficacy of Nano-Hydroxyapatite Coating On Osseointegration of Early Loaded Dental Implants

Osama Alabed Mela

Oral and Maxillofacial Surgery, Faculty of Dentistry, Mansoura University, Egypt

Mohamed Abdel-Monem Tawfik

Oral and Maxillofacial Surgery, Faculty of Dentistry, Mansoura University, Egypt

Wael Mohamed Ahmed Said Ahmed

Oral and Maxillofacial Surgery, Faculty of Dentistry, Mansoura University, Egypt

Fakhreldin Hassan Abdel-Rahman

Oral and Maxillofacial Surgery, Faculty of Dentistry, Mansoura University, Egypt

Abstract---Background and Objectives: The success rates of dental implants have been reported as a challenge, especially for early loading in the posterior maxilla area. The surfaces of dental implants are generally modified in an attempt to improve osseointegration. In which Unitite implants with Nano hydroxyapatite coating affect the healing process acceleration, high hydrophilicity, increased bone formation (BIC - Bone Implant Contact), and the quality improvement of the new bone formed (BAFO - Bone Area Fraction Occupancy), keeping the original implant microtopography. This study aimed to evaluate the efficacy of Nano hydroxyapatite coating osseointegration of early loaded dental implants in the posterior maxilla. Patients and Methods: A clinical trial was carried out on ten patients need twelve implants with early loading were treated in the oral and Maxillofacial Surgery Department, Faculty of Dentistry, Mansoura University ; A root-form implant is the most frequently used type of dental implant today. The basis for dental implants is osseointegration, the HAnano® coating associated with its microtopography generate an increase in the titanium surface energy, making the implant highly hydrophilic, which guarantees the presence of blood and its components in the healing chamber.

Keywords---dental implant surface, nanotechnology-hydroxyapatite, osseointegration, radiographically.

Introduction

The oral rehabilitation of missing teeth by dental implants is one of the most frequently used surgical procedures nowadays. The rate of clinical success of the use of oral implants is widely related to the bone formation at the endo-osseous implant surface in contrast with fibrous encapsulation that often leads to loss of the implant and consequent failure of the treatment. This process known as osseointegration was firstly described by Branemark in 1952 while examining microcirculation of bone and wound healing patterns, as the “direct contact between living bone and functionally loaded implant surface without interposed soft tissue, detectable at the microscope level (1). Research has resulted in better designs, materials, and more extensive clinical knowledge compared with the early years of implant development. However, the main cause for clinical failure is still insufficient bone formation around the biomaterial, immediately after implantation. (2) Therefore, improvements are needed in this area as clinicians and patients are pushing for faster healing times. In 1981, Albrektsson, and colleagues, (3) identified six parameters as pre-requisites for osseointegration: (A) bone status, (B) loading conditions; (C) surgical technique; (D) implant design (or macrostructure); (E) implant material and (F) implant surface.

It is widely accepted that the surface properties of a dental implant play a major role in the osseointegration process and biomechanical fixation due to its influence in the implant tissue interactions as it affects directly the behavior of the surrounding tissues.(4,5) The surface features become extremely important at the initial healing period of an implant as they influence directly the dynamics of the bone-implant interface and consequently command the short and long term success rate of the prosthetic treatment (6). The implant surface characteristics including topography, chemistry, surface charge, and wettability are likely to be of particular relevance to the chemical and biological interface processes in the early healing stages after implantation. In fact, they play an extremely important role in the modulation of host/implant tissue response as it determines the speed and quantity of osseointegration and long-term survival of an implant. (7) Surface modifications influence cell proliferation and differentiation, extracellular matrix synthesis, local production factors, and even cell shape, gene expression, protein secretion, differentiation and apoptosis. This will consequently affect retention and proliferation of osteogenic cells at the implant site. (8) In addition, modified surfaces can also present osteoconductivity which allows for cell migration to the implant surface, promoting the formation of extracellular matrix and bone apposition (9).

Surface chemistry influences the conformational changes in the structures and the interactive nature of adsorbed proteins and cells, which may lead to alterations in the structure of adsorbed proteins, generating a cascade of effects that may ultimately be evident at the clinical level and also affects the hydrophilic character of the surface. Surface wettability is largely dependent on surface energy and influences the degree of contact with the physiological environment, (10) as they influence the adsorption of proteins, and increase adhesion of osteoblasts on the implant surface. The cell behavior on a hydrophilic surface promotes blood coagulation and higher expressions of bone-specific differentiation factors, in contrast with a hydrophobic surface. Consequently, dental implants’

manufacturers have been developing highly hydrophilic and rough implant surfaces which in turn are able to exhibit better osseointegration than implants with smooth surfaces (11).

The rationale for the surface modification of implants is straightforward: to retain the key physical properties of an implant, while modifying only the outermost surface layer to influence the bio-interaction. As a result, much research work is devoted to the elaboration of methods of modifying surfaces of existing implants (biomaterials) in order to achieve the desired biological responses (12, 13). Hydroxyapatite (HA), which is the main mineral present in the natural bone structure, when applied on the surface of nanostructures titanium implants, forms a homogeneous and stable coating functioning as a scar catalyst that speeds up osseointegration when compared to conventional surfaces. This coating differs significantly in thickness, application method, clinical predictability and scientific support when compared to the HA surfaces used in the past. The HAnano® coating is formed by hydroxyapatite nanocrystals, with size and shape similar to those of human bone, sintered on micro rough titanium measuring 20 nm thick that promotes a change on surface energy, increasing the hydrophilicity and providing substrate that stimulates a greater osteoblasts multiplication. (14) These crystals are applied to the titanium implant surface after a chemical treatment with double thermal acid attack (DAA), which brings a series of benefits to the Unitite implants, such as the healing process acceleration, high hydrophilicity, increased bone formation (Bone Implant Contact-BIC) and the quality improvement of the new bone formed (Bone Area Fraction Occupancy-BAFO), keeping the original implant micro topography (15, 16).

It has been shown that the bone mechanical properties, such as modulus of elasticity and hardness in the fraction of bone area formed (BAFO), increased significantly Nano HA, not only in the vicinity of the bone implant interface (BIC), but also within the healing chambers and especially in distant areas of the implants. According to a vivo study, published by Coelho and collaborators, there was an increase of +% BIC and +% BAFO - indexes superior to traditional surfaces implants (17, 18, 19). The Nano HA present on the surface of the Unitite implant has shown an improvement in scar response in molecular tests of signal transduction, where the proteins involved in the scar process recorded a substantial increase in concentration, presenting the coating positive effect on the interaction with the pre-osteoblastic cells. Likewise, there was an increase in the concentration of important osteogenic markers, such as alkaline phosphatase and osteocalcin, in a clear signaling of the mineralization process acceleration. (19) This study aimed to the efficacy of the HAnano® coated surface (S.I.N. Implant System, Sao Paulo, Brazil) on osseointegration of early loaded dental implants in the posterior maxilla.

Patients and Methods

Design and subjects

This study included twelve early loaded implants, single or more maxillary posterior teeth\tooth by dental implants were placed into the 10 patients, 3male and 7females. The patients were selected from the outpatient clinic of the Oral

and Maxillofacial Surgery Department, Faculty of Dentistry, Mansoura University according to the following inclusion and exclusion criteria. Inclusion Criteria included the presence of: Age ranging from 20 to 45years, Free from history of bruxism / Para functional habits, Patient with one missed or more posterior maxillary teeth, Patient's cooperation, motivation and good oral hygiene, Patient medically free from systemic or local conditions that absolutely contraindicate implant surgery, Sufficient alveolar bone volume at the implant site with minimum 6mm width bucco-palataly- sufficient distance from the maxillary sinus) $\geq 12\text{mm}$. Exclusion Criteria included the presence of: Smoking, Pregnancy, Patient during radiotherapy and chemotherapy, and any bone diseases that interfere with bone healing were excluded from this study. The cases are shown in (Fig.1) to outline the technique steps of treatment patients. These patients came for placement implants of maxillary posterior teeth and had our clinical trial after signing an informed consent. Supplementary data table (1) shows the demographic information of these patient, implant tooth site, implant dimensions. Each patient has agreed to receive an implant and accordingly, was replaced by early loading implant.

Pre-operative measures

Each case was evaluated through examination of Panoramic and Cone beam computed tomography (CBCT), to evaluate the amount of the residual bone height, and width was done which allowed proper selection of dental implants. (Fig.1.A, B) All implants (100%) were 4.3mm in diameters with different length (mm) 10.0, 11.5, 13.0.

Surgical procedure

All surgical procedures were done under complete aseptic condition in the operating room of Oral and Maxillofacial Surgery Department, Faculty of Dentistry, Mansour University. Local anesthesia was achieved using buccal infiltration injection (1.5 ml) together with palatal infiltration injection (0.3 ml) using 4% Articaine with 1:100.000 epinephrine. Triangular incision was made using blade No. 15 along the alveolar crest slightly toward the palate for a better visibility and secure flap closure. Then sulcular incision extended mesiodistally to the neighboring teeth for reflection of full mucoperiosteal flap more easily and to expose the alveolar bone from the buccal aspect. For maintaining the blood supply to the bone, the palatal flap was minimally raised.(Fig.1.E) The process of implant osteotomy was started with the cut pilot drill, (speed 1,200 rpm) being made through the hole in the stent, to accurately reproduce the angulations. The stent was removed and the osteotomy was carried to the desired depth. The angulations are checked once again with the paralleling pin, both clinically and radiographically, and any discrepancy found can be corrected subsequently. The osteotomy was then enlarged to the desired width. All these steps are done under constant external irrigation. After preparation of implant bed, the sealed Unitite, dental implant package was opened and the implant was installed in its osteotomy site by using a ratchet wrench with recommended torque (30Ncm) until implant became flushed with the bone crest and initial stability of the implant was achieved. Finally, cover screws were attached to the implants to prevent inward growth of soft tissue or bone into the implant platform.(Fig.1.F, G) The

reflected mucoperiosteal flap was sutured into its original site using non-resorbable 4\0 polypropylene suture in an interrupted manner. An immediate postoperative CBCT was taken. (Fig.1.H, I, J)

Post-operative care

All patients were instructed to avoid chewing solid textured food, maintain optimal oral hygiene, and apply ice packs over the area for the first day (10 min-1\2 h) and then warm packs for the next days. Postoperative medication consisted of: Continuity of the antibiotic course for 7 days after surgery, analgesic: 500mg paracetamol, 3 times daily. 0.2% chlorohexidine gluconate solution rinse daily for 6 days. Follow up of all cases and suture removal was done after 10 days.

Prosthetic preparation

Performed with 1 month later patients were scheduled to uncover submerged fixtures and healing abutments of suitable lengths were connected based on mucosal thickness to be extended above the mucosal surface.(Fig K,L,M) The healing abutment was removed and cement retained porcelain fused to metal (PFM) restorations were fabricated and delivered to all patients. (Fig. 1.N, O).

Clinical assessment

The following parameters were evaluated at 3, 6, months and 12 months after implant loading:

- Implant stability using Osstell ISQ device, Osstell values were interpreted based on the manufacturers guide.(20)
- Modified sulcus bleeding index was measured at mid-buccal\palatal\mesial\distal sites around each implant. A score of 0 meant no bleeding along the gingival margin; a score of 1 meant separate bleeding spots along the gingival margin; a score of 2 meant a bloody red line on the gingival margin; a score of 3 copious bleeding at the gingival margin. (21)
- Peri-implant pocket depth (PPD) was measured from the pocket base to the gingival margin with periodontal probe. The probe was inserted at the mid-buccal\palatal\measial\distal sites at around each implant. (22)

Radiographic assessment

CBCT Scans were taken at 6 months after loading time to evaluation marginal bone loose. (Fig 1, R) The distance between the observed crestal bone level and implant-abutment interface was measured at the (bucally, palatal, mesial, distal) implant surfaces and averaged to yield the mean marginal bone loss for each implant. In such cases, the length (mm) of the implant, and the distance between the observed crestal bone and implant-abutment interface was measured on the radiographs. The actual implant length is known based on manufacturing standards. To adjust the measurements for magnification error, the following equation was used to determine the corrected crestal bone levels: (23)

Corrected crestal bone level= measured crestal bone level x actual implant length

Measured implant length

All the values obtained were tabulated and expressed graphically as shown in the results section.

Data analysis

- Chi-Square test for comparison of 2 or more groups.
- Monte Carlo test as correction for Chi-Square test when more than 25% of cells have count less than 5 in tables ($>2 \times 2$).
- Fischer Exact test was used as correction for Chi-Square test when more than 25% of cells have count less than 5 in 2×2 tables .
- MC Nemar test was used to compare before and after changes in binominal variables.
- Stewart –Maxwell test was used to compare follow up periods for variables with more than 2 categories.

Results

Demographic data

In this study 12 implants were inserted on 3males (30.0%) and 7females (70.0%) The means and standard deviation values for age were 37.0 ± 9.60 years with a minimum of 20 years and a maximum of 45 years. The patients were selected according to certain for replacement of maxillary posterior teeth. Nine first molars, three premolars, were replaced. As shown in table (1).The implant of dimensions used in this study were 2(4.3 x 13mm), 3(4.3 x11.5mm) and 7(4.3 x 10mm).

Clinical outcomes

All implants (100%) showed signs of osseointegration and no of dehiscence, infection or mobility. To make easy to present and interpret, we decided to call the P value same patients of 3 months compared to 6-and 12- months.

Implant stability

In general, implant stability (supplementary data tables 2), showed statistically significant along the evaluation intervals (3 months, 6 months, and 12 months postoperative). Where p values considered significant if $p < 0.05$. There was a statistically significant decrease at the 3 months. From 3 months to 6 months, 3 months to 12 months as well as from 6 months to 12 months. P value considered significant if $p < 0.05$.

Peri-implant pocket depth (PPD)

The peri-implant probing depths were measured using a William`s Periodontal Probe. Four values were recorded for each implant, each value corresponding to a

surface, and then averaged, to yield a mean probing depth for each implant. The changes occurring in the probing depths for each implant are shown in Table (3). There was a statistically significant increase in PPD, from 3 months to 6 months, 3 months to 12 months as well as from 6 months to 12 months; there was statistically significant change in PPD. P value considered significant if $p < 0.05$.

Modified Sulcus Bleeding Index (mSBI)

Data for mSBI finding are presented in Table (4). There was no significant difference between regarding mSBI either at 3 months and 12 months postoperatively ($p > 0.05$). P value considered no significant if $p > 0.05$.

Radiographic evaluation-Marginal bone loss

Mean values of the peri-implant marginal bone loose around implants at the 6 month in table (5). the mean value of the calculated peri-implant bone loss measured at the distal aspect of the implant was 0.995 with (0.64-1.61) mm, the mean value of the calculated peri-implant bone loss measured at the mesially aspect of the implant was 0.975 with (0.56-2.02) mm, the mean value of the calculated peri-implant bone loss measured at the buccally aspect of the implant was 0.720 with (0.29-1.34) mm, and the mean value of the calculated peri-implant bone loss measured at the palatally aspect of the implant was 0.695 with (0.33-1.59) mm . Marked significant amount of peri-implant bone loss was detected for all patients. Moreover, it was shown that there was a statistically significant difference regarding the mean MBL values at different time intervals ($P < 0.05$). There was a statistically significant increase in MBL from distal to mesial, from distal to palatal, and from mesial to palatal, as well as statistically significant decrease in MBL from palatal to buccal side. Through the whole study period (6 month); there was a statistically significant increase in bone height measurements.

Discussion

Dental implant today has become a highly predictable mode for replacement of missing tooth. The main target is to achieve comfort, function, aesthetic as well as reduction of treatment time. (24) Initially a 3-6month stress free healing period was recommended by Branemark et al, to achieve optimum bone healing and osseointegration prior to loading. This undue waiting period was always a source of inconvenience, both to the patient and clinician, and many a time, the reason for opting against implant therapy (25). The early loading of dental implants can be successful, if some clinical precautions are taken. Such precautions may include: under-preparation of the implant sites, particularly in the presence of soft bone, use of implant designs favoring achievement of high insertion torques (35 Ncm or more),(26) and an accurate control of loading. Some authors also advocate the use of specific implant surface modifications to reduce the healing time (27). Long-term success of implants depends up on many factors,(28, 29) such as osseointegration (30). Furthermore, chemical biocompatibility of material and micro geometry of implant's surface are significant for implant success and long-term osseointegration, influencing cellular response, leading to higher/better

quality bone production and, thus, enhancing secondary implant stability (31,32,33).

The presence of hydroxyapatite (HA) on the implants surface is already known to promote faster Osseointegration if compared to conventional surfaces. (34, 35) Even though in the past coatings with HA would lead to thick layers that flaked away from the surface resulting in a number of complications, (36,37) current HA coating techniques offer very advanced topography insertion at the nanometer scale, such as those in the Unitite® implant's surface that are smaller than 100 nm. At this scale, it is possible to witness the most effective cell integration, and the synergistic key role played by texture on the topography, as well as how the chemicals start to promote Osseointegration, accelerating this process.(38) We emphasize that Unitites'® surface is coated with a single nanometric HA layer, which was proven to cause no inflammatory reaction (38).

This clinical study evaluated efficacy of nanohydroxyapatite coating outcomes of 12 early loaded implants in posterior maxilla. The study included 10 patients according to particular inclusion and exclusion criteria. The indicated for the vast majority of clinical situations; unitite implant does not indicate implant installation in patients with: acute inflammatory or infectious processes of living tissue, inadequate bone volume or quality, site root remnants, serious medical problems such as bone metabolism disorders, blood coagulation disorders, low healing capacity, incomplete jaw growth, allergy or hypersensitivity to titanium, patients with history of head and neck irradiation, bone situation anatomically unfavorable to implant stability, acute periodontitis, treatable pathological maxillary diseases, and or a mucosal changes (39). Many implant manufacturers claimed that their implant could be successfully utilized in early loading system. However, Unitite® implant Systems, from (S.I.N. Implant, Sao Paulo Brazil) was selected due to having simple during surgical procedure. (40)After implant placement, re-approximation of mucosal flap and suturing of mucosal flap was performed utilizing 4-0 silk. This step indicates the start of prosthetic stage. An impression is performed, in all our cases. This complies with early loading concepts in implant dentistry.

The parameters of implant's success were evaluated using standardized yardsticks. These included implant stability, (20, 41) Modified sulcus bleeding index, (21, 42) and Peri-implant pocket depth (PPD). (22, 43) The marginal bone levels were assessed radiographic. (20, 23) Regarding implant stability, our study declared that, the mean average Osstell device values (ISQ) were 71.17 ± 2.79 , 81.17 ± 4.04 , and 87.17 ± 3.88 at 3, 6 and 12 months respectively. There was a significant difference between the mean (ISQ) from 3 months to 6 months, 3 months to 12 months but the difference was insignificant thereafter from 6 to 12 months. This was in agreement with Anderson et al. (44) who showed an ankylotic healing and successful maintenance of osseointegration of all implants. Threaded implants are the most commonly used, regardless of their different geometries and screw profiles, since after they are fixed; they remain in intimate contact with the bone bed leading to appositional bone healing. This is a direct result of the smaller or similar implant internal diameter beds created by the drills used in the osteotomy. Thus, primary stability results from the intimate contact between the bone and the implant. Nevertheless, this intimate bone

contact with the implant regions undergoes a healing process that involves necrosis and remodeling, followed by extensive bone resorption, ensued by new bone formation (appositional) (45).

One of the advantages of the double tapered macrogeometric configuration as proposed for Unitite® is to reduce the number of milling cutters and consequently reduce the surgical insertion time of the implant and increase its primary stability. When compared to a cylindrical implant placed according to manufacturer's norms, these advantages were proven, with significantly shorter milling and insertion times with Unitite®. (46, 47) The main advantage of this surface treatment when compared to the absence of texture (machined surface) can be seen in the retention of the clot and subsequent more distributed bone formation in the center and walls of the implant inside the healing chambers, resulting in greater removal of torque after few weeks in vivo (48). Probing depth is another parameter that has been used to determine peri-implant tissue health. Although this parameter is reproducible and repeatable within 1 mm of accuracy at periodontal sites, the accuracy of PD around dental implants remains challenging (49).

During assessment of peri-implant probing depth (PPD), our study declared that, the mean (PPD) were 0.87-1.62, 0.37-1.0, and 0.0-0.50 at 3, 6, and 12 months respectively. Through the whole study period (3 months to 12 months); there was a statistically significant decreased in PPD. decreased incidence of (PPD) values can be attributed throughout the study period that may be attributed to the successful adaptation of the peri-implant sulcular epithelium to the implant surface as reported by Soliman et al. (50). The best soft tissue status around implant is absent inflammatory reaction. Gum hemorrhage while probing indicates inflammatory reaction. Radiological bone loss and enhanced pocket depth are linked to sulcular hemorrhage. Thus, gum condition surrounding implant was documented for monitoring oral hygienic condition. Bleeding index underwent calculation in accordance with Mombelli A et al, (21) a periodontal probe was run along sulcus. Presence of hemorrhage or not was determined according to Ericsson et al. (35) Of special interest are the findings pertaining to the bleeding index, which decreases significantly at the 6th month, after loading implant.

Topographic characterizations of Unitite's® nano surface implant allow the observation of a surface entirely covered by HA nanocrystals with a homogenous thickness of 20 nm. This layer, it should be noted, is over a grade 4 titanium surface with a moderately rough texture, as established in the literature to result in a better Osseointegration response.(51) The presence of HA nanotopography on Unitite® Implant surface increases important osteogenic markers, such as alkaline phosphatase and osteocalcin, while at the same time reducing inflammation. Thus, an HA monolayer with a thickness under 100 nm is metabolized by the system (52). All implants have some degrees of bone loss after installation and loading. An early implant bone loss of 1 mm occurs during healing stage and the 1st year in function at crestal area of implant, followed by a yearly bone loss of 0.2 mm thereafter. Until present, the basic mechanisms of early peri-implant marginal bone losses are unclear. (53) This bone loss could be based on the hypothesis that marginal bone loss is the result of micro-damage

accumulation occurring in bone after implant placement. It was also explained as a manifestation of wound healing which occurs after implant surgical placement and as a reaction to loading. Crestal bone loss could also be explained by the finding that forces applied on implants are distributed on the crestal bone rather than along the entire implant/bone interface (54).

CBCT images showed adequate availability of marginal bone loose at the dental implant platform at sixth month after loading. In this study, results obtained using CBCT images were reliable for linear measurements of marginal bone loose. We used the methodology reported by Yoo and colleagues. (55) Implant's length underwent measurement on radiograph. A distance between marginal bone and implant-abutment interface underwent measurement at buccal, palatal, mesial as well as distal surfaces of the implant. The actual length was known based on manufacturing standards. Regarding marginal bone loss, our study declared that, at sixth month study found a mean marginal bone loss of 0.64 mm distally, 0.56mm mesially, palatal 0.33 and buccal 0.29. There was a significant difference between the mean marginal bone loss from difference between distal &mesial, difference between distal &palatal, difference between distal &buccal, difference between mesial &palatal, difference between mesial &buccal, difference between palatal & buccal sides at the 6 month. Statistically significant if $p < 0.05$. This finding is in agreement with previous clinical study Payne et al. (56).

Among the most important aspects of great clinical relevance is the mechanical quality of the bone forming around this new Unitite® surface. It has been shown that the bone mechanical properties (elasticity and hardness) increased significantly when compared to the same surface without the HA nano coating, and that was true not only around the implant-bone interface, but also inside the healing chambers and especially in remote areas of the implant. This aspect is highly desirable when the conditions of function of the implant over the implant are challenging as is the case with immediate and early loading (57). From a biological standpoint, the space and misalignment observed in prosthetic implant abutment interfaces, as demonstrated by a series of trials, (58) becomes a continent for bacterial colonization and the effects of its byproducts reflected clinically as an important agent in the contribution of peri-implantitis and bone loss around the implant. (59) Considering this context, the distance from the outer edge of the prosthetic abutment towards the center of the implant and the consequent bridging of the gap between the prosthetic abutment / implant and the implant peri-tissue, is a concept known by “platform-switching”, and it presents itself as a real alternative for the preservation of marginal bone tissue. In the case of conical internal connections, the maintaining of the abutment / implant interface distant from peri-implant tissues is inherent to the system, which makes this connection advantageous also from the standpoint of preserving marginal bone (60).

Our results demonstrated that implants in posterior maxilla may be early loaded after being inserted. The success rate accomplished was 100% following one year post-loading. The clinical and radiological features of assessment of implant success in the current study included implant stability, per-implant probing depths, modified bleeding index, as well as mean crestal bone levels. All four parameters seemed to be in healthy limits in 12 implants in the study, which is in

accordance with results of another study, which had prospectively assessed early loading implants. To the best of our knowledge, early loaded implants with HA nano coating have shown encouraging results in a stronger and favorable regeneration of bone and better Osseointegration of implants.

Table 1

Shows patients demographic information, the site of placed implant, the implant diameter and length

Patients number	Patients age (years)	Patients sex	Tooth replaced by implant	Implant dimension
1	20	Female	Upper left first molar	4.3x10mm
			1. Upper left first premolar.	4.3x10mm
2	45	Female	2. Upper left second premolar.	4.3x10mm
			3. Upper right first premolar.	4.3x11.5mm
3	32	Male	Upper right first molar	4.3x10mm
4	45	Female	Upper right first premolar	4.3x13mm
5	44	Male	Upper right first molar	4.3x11.5mm
6	36	Female	Upper left first molar	4.3x11.5mm
7	45	Female	Upper right first molar	4.3x10mm
8	33	Female	Upper right first molar	4.3x10mm
9	40	Female	Upper left first molar	4.3x10mm
10	25	Male	Upper left first premolar	4.3x13mm

Table 2

Implant stability (Osstell ISQ device) at 3, 6-and 12-months (after loading time) all patients

	3 months	6 months	12 months	P value
Implant stability mean±SD	71.17±2.79	81.17±4.04	87.17±3.88	p1<0.001*
				p2<0.001*
				p3<0.001*

Used test: Paired t test, p1: difference between after 3 & 6 months, p2: difference between 3 & 12 months, p3: difference between 6 & 12 months, statistically significant if $p < 0.05$.

Table 3
Peri-implant pocket depth (PPD) values at 3, 6- and 12-months (after loading time) all patients

	3 months	6 months	12 months	P value
PPD median	1.12	0.56	0.12	p1<0.001
(range)	(0.87-1.62)	(0.37-1.0)	(0.0-0.50)	p2<0.001* p3<0.001*

Used test: Wilcoxon signed rank test, p1: difference between after 3 & 6 months, p2: difference between 3 & 12 months, p3: difference between 6 & 12 months, *statistically significant if p<0.05.

Table 4
Modified Sulcus Bleeding Index (mSBI) values at 3, 6- and 12-months (after loading time) all patients

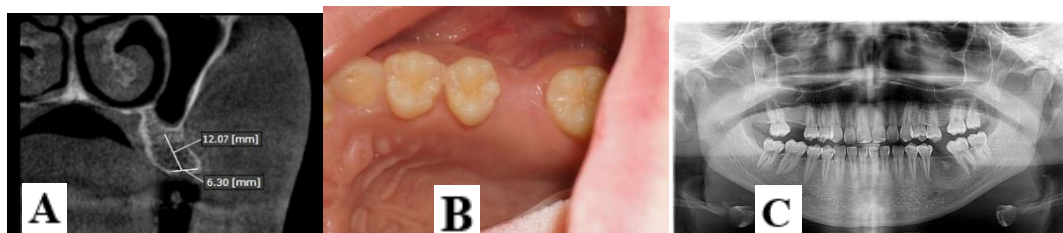	3 months	6 months	12 months	P value
MSBI median	0.5	0.25	0.0	p1=0.164
(range)	(0.0-0.75)	(0.0-0.50)	(0.0-0.50)	p2=0.006* p3=0.057

Used test: Wilcoxon signed rank test, p1: difference between after 3 & 6 months, p2: difference between 3 & 12 months, p3: difference between 6 & 12 months, *statistically significant if p>0.05.

Table 5
Data for marginal bone level findings at 6 months (after loading time) all patients

	Distal	Mesial	Palatal	Buccal	test of significance
MBL median	0.995	0.975	0.695	0.720	p1=0.422
(range)	(0.64-1.61)	(0.56-2.02)	(0.33-1.59)	(0.29-1.34)	p2=0.099 p3=0.02* p4=0.025* p5=0.004* p6=0.08

Used test: Mann Whitney U test. P1: difference between distal & mesial, P2: difference between distal & palatal, P3: difference between distal & buccal, p4: difference between mesial & palatal, p5: difference between mesial & buccal, p6: difference between palatal & buccal sides. *Statistically significant if p<0.05.



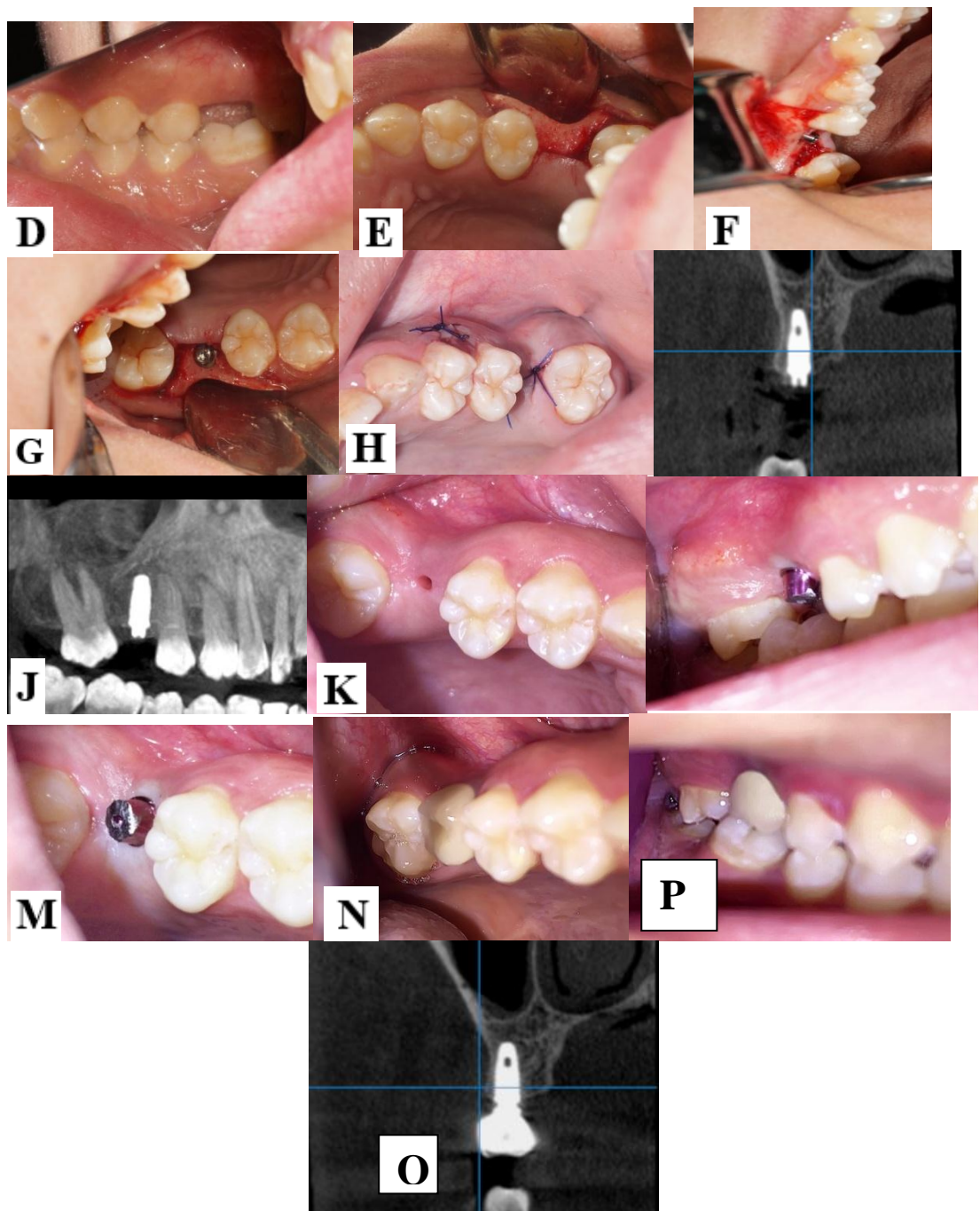


Figure 1. Cases presentation, stages and method of surgery(A,B,C,D,E,F,G,H,I,J,K,L,M,N,O,P,Q)

References

1. Branemark PI, A.R, Breine U, Hansson BO, Lindstrom J, Ohlsson A. Intraosseous anchorage of dental prostheses. I. Ex-perimental studies. *Scand J Plast Reconstruct Surge* 1969; 3: 81 -100.
2. Christenson EM, A.K. Nano-biomaterial applications in orthopedics. *Van den Beucken LJ J Orthop Res* 2007; 25: 11–22.
3. Branemark PI, Albrektsson T. Microcirculation and healing of artificial implants in bone. *Proceedings of the 2nd World Congress for Microcirculation* 1979; 2: 59-60.
4. Nubesh KT, Swaminathan SK, Viswanathan K, RajasekarS.Osseointegration and more. A review of literature *Indian Journal of Dentistry* 2012; 3:72-26.
5. Guehennec Le, Soueidan LA, Layrolle P, AmouriqY.Surface treatments of titanium dental implants for rapid osseointegration. *Dent Mater* 2007; 23: 844-854.
6. Pak HS, Yeo IS, Yang JH. A histomorphometric study of dental implants with different surface characteristics. *J Adv Prosthodont.* 2010; 2(4):142–147.
7. Wennerberg A, Jimbo R, Stubinger S, Obrecht M, Dard M, Berner S. Nanostructures and hydrophilicity influence osseointegration: a biomechanical study in the rabbit tibia. *Clin Oral Implants Res* 2014; 25:1041-50.
8. Anselme K, BM. Topography effects of pure titanium substrates on human osteoblast long-term adhesion. *ActaBiomater* 2005; 1: 211-222.
9. John E, Davies B. Understanding Peri-Implant Endosseous Healing. *Journal of Dental Education* 2003; 67: 932-949.
10. Kilpadi DV, Lemons JE. Surface energy characterization of unalloyed titanium implants. *J Biomed Mater Res* 1994; 28: 1419-1425.
11. Le Guéhennec L., Soueidan A., Layrolle P., Amouriq Y. Surface treatments of titanium dental implants for rapid osseointegration. *Dental Materials.* 2007; 23(7):844–854.
12. Puleo D, Nanci A. Understanding and controlling the bone-implant interface. *Biomaterials* 1999; 20:2311-2321.
13. Klinger MM, Rahemtulla F, Prince CW, Lucas LC, Lemons JE. Proteoglycans at the bone-implantinterface. *Crit Rev Oral Biol Med* 1998; 9:449-463.
14. Jimbo R, Coelho PG, Bryington M, Baldassrri I, Albrektsson T. Nano hydroxyapatite coated implants improve bone nanomechanical properties. *J Dent Res* 2012; 91:1172-1177.
15. Melin SL, Meirelles L, Franke SV, Kjellin P, Currie F, Andersson M, Wennerberg A. Evaluation of bone healing on sandblasted and acid etched implants coated with nanocrystalline hydroxyapatite: an in vivo study in rabbit femur. *International Journal of Dentistry* 2014; 29:97-104.
16. Bordin D, Bergamo ETP, Fardin VP, Coelho PG, Bonfante EA .Fracture strength and probability of survival of narrow and extra-narrow dental implants after fatigue testing: In vitro and in silico analysis. *MechBehav Biomed Mater* 2017; 71:244-249.
17. Sousa RM, Simamoto-Junior PC, FernandesNeto AJ, Sloten JV, Jaecques SV, Pessoa RS. Influence of connection types and implant number on the biomechanical behavior of mandibular full-arch rehabilitation. *Int J Oral Maxillofac Implants* 2016; 31:750-760.

18. Pessoa RS, Sousa RM, Pereira LM, Neves FD, Bezerra FJ, Jaecques SV, Sloten JV, Quirynen M, Teughels W, Spin-Neto R. Bone remodeling around implants with external hexagon and morse-taper connections: a randomized, controlled, split-mouth, clinical trial. *Clin Implant Dent Relat Res* 2017; 19:97-110.
19. Bezerra FJ, Ferreira MR, Fontes GN, da Costa Fernandes C Jr; AndiaDC, Cruz NC, da Silva RA; Zambuzzi WF. Nano hydroxyapatite-blasted titanium surface affects pre-osteoblast morphology by modulating critical intracellular pathways. *BiotechnolBioeng* 2017; 28:868-877.
20. Michael Bornstein, Christopher N Hart. Early Loading of Nonsubmerged Titanium Implants with a Chemically Modified Sand-Blasted and Acid-Etched Surface: 6-Month Results of a Prospective Case Series Study in the Posterior Mandible Focusing on Peri-Implant Crestal Bone Changes and Implant Stability Quotient (ISQ) Values. *Clinical Implant Dentistry and Related Research* 2009; 11:338-47.
21. Mombelli A, van Oosten MA, Schurch E, Jr., Land NP. The microbiota associated with successful or failing osseointegrated titanium implants. *Oral Microbial Immunology* 1987; 2:145-151.
22. Esther M Wilkins. Examination procedures in wilkins EM clinical practice of the dental hygienist. 9th ed. Philadelphia, PA: Lippincott and wilkins 2005; 222-245.
23. Yoo RH, Chuang SK, Erakat MS, Weed M, Dodson TB. Changes in crestal bone levels for immediately loaded implants. *Int J Oral Maxillofacial Implants* 2006; 21:253-261.
24. Editorial. After 40 years: the Mission is Possible. *Int J Oral Maxillofacial Implants* 2005; 20:92-98.
25. Andersen E, Haanæs HR, Knutsen BM. Immediate Loading of Single-tooth ITI Implants in the Anterior Maxilla: a prospective 5-year pilot study. *Clin Oral Impl Res* 2002; 13:281-287.
26. Cannizzaro G, Leone M, Ferri V, Viola P, Gelpi F, Esposito M. Immediate loading of single implants inserted flapless with medium or high insertion torque: a 6-month follow-up of a split-mouth randomized controlled trial. *Eur J Oral Implants* 2012; 5: 333-342.
27. Rocuzzo M, Bunino M, Prioglio F, Bianchi SD. Early loading of sandblasted and acid-etched (SLA) implants: a prospective split-mouth comparative study. *Clin Oral Implants Res* 2001; 12: 572-578.
28. Schroeder, E. Van der Zypen, Stich H. reactions of bone, connective tissue, and epithelium to endosteal implants with titanium-sprayed surfaces," *Journal of Maxillofacial Surgery* 2011; 22: 135-142.
29. Papaspyridakos P, Chen CJ, Singh M. "Success criteria in implant dentistry: a systematic review," *Journal of Dental Research* 2012; 91: 242-248.
30. Esposito M, Hirsch JM, Lekholm U. "Biological factors contributing to failures of osseointegrated oral implants (II): Etiopathogenesis," *European Journal of Oral Sciences* 1998; 106: 721-764.
31. Meirelles L. On Nano Size Structures for Enhanced Early Bone Formation, Department of Prosthodontics/Dental Material Science, Department of Biomaterials, Göteborg University, Göteborg, Sweden, 2007.
32. Wennerberg A, Albrektsson T. "On implant surfaces: a review of current knowledge and opinions," *The International Journal of Oral and Maxillofacial Implants* 2010; 25: 63-74.

33. Deyneka-Dupriez N, Kocdemir B, Herr U. "Interfacial shear strength of titanium implants in bone is significantly improved by surface topographies with high pit density and microroughness," *Journal of Biomedical Materials Research Part B: Applied Biomaterials* 2007; 82: 305-312.
34. Proussaefs P, Lozada J. Immediate loading of hydroxyapatite-coated implants in the maxillary premolar area: Three-year results of a pilot study. *J Prosthet Dent* 2004; 91:228-233.
35. Ericsson I, Nilson H, Lindh T, Nilner K, Randow K. Immediate Functional Loading of Brånemark Single Tooth Implants. An 18 Months' Clinical Pilot Follow-up Study. *Clin Oral Impl Res* 2000; 11: 26-33.
36. Mounir GM, Beheiri W, El-Beialy: Assessment of marginal bone loss using full thickness versus partial thickness flaps for alveolar ridge splitting and immediate implant placement in the anterior maxilla. *Int. J. Oral Maxillofac. Surg* 2014; 5:021.
37. Meirelles L, Peltola T, Mellin L, Kjellin P. Effect of hydroxyapatite and titania nanostructures on early in vivo bone response. *Oral Maxillofac. Surg* 2008; 10:245-254.
38. Jimbo R, Sotres J, Johansson C, Breeding K, Currie F, Wennerberg A. "The biological response to three different nanostructures applied on smooth implant surfaces," *Clinical Oral Implants Research* 2012; 23:706-712.
39. Martins LM, Martins LM, Bonfante EA, Zavanelli RA, Freitas AC Jr, Silva NR, Marotta L, Coelho PG. Fatigue reliability of three single-unit implant-abutment designs. *Implant Dent* 2012; 21:67-71.
40. Suelen CS, Jose CM, Rodrigo R. The Influence of Nanostructured Hydroxyapatite Surface in the Early Stages of Osseointegration: A Multiparameter Animal Study in Low-Density Bon. *Int J of Nanomedicine* 2020; 15:8803-8817.
41. Lorenzoni M, Pertl C, Zhang K, Wegscheider WA. Inpatient comparison of immediately loaded and nonloaded implants within 6 Months *Clin. Oral Impl. Res* 2003; 14: 273-279.
42. Ericsson I, Nilson H, Lindh T, Nilner K, Randow K. Immediate Functional Loading of Brånemark Single Tooth Implants. An 18 Months' Clinical Pilot Follow-up Study. *Clin Oral Impl Res* 2000; 11: 26-33.
43. Proussaefs P, Lozada J. Immediate loading of hydroxyapatite-coated implants in the maxillary premolar area: Three-year results of a pilot study. *J Prosthet Dent* 2004; 91:228-233.
44. Andersen E, Haanæs HR, Knutsen BM. Immediate Loading of Single-tooth ITI Implants in the Anterior Maxilla: a prospective 5-year pilot study. *Clin Oral Impl Res* 2002; 13:281-287.
45. Coelho PG, Suzuki M, Guimaraes MV, Marin C, Granato R, Gil JN, et al. Early bone healing around different implant bulk designs and surgical techniques: A study in dogs. *Clin Implant Dent Relat Res* 2010; 12(3):202-8.
46. Leonard G, Coelho P, Polyzois I, Stassen L, Claffey N. A study of the bone healing kinetics of plateau versus screw root design titanium dental implants. *Clin Oral Implants Res.* 2009; 20:232-9.
47. Berglundh T, Abrahamsson I, Lang NP, Lindhe J. De novo alveolar bone formation adjacent to endosseous implants. *Clin Oral Implants Res.* 2003; 14:251-62.
48. Wennerberg A, Albrektsson T. Effects of titanium surface topography on bone integration: a systematic review. *Clin Oral Implants Res* 2009; 20:172-84.

49. Jeffcoat MK, Reddy MS. Advances in measurements of periodontal bone and attachment loss. *Monogr Oral Sci* 2000; 17: 56 – 72.
50. Soliman M, et al. Clinical and radiographic evaluation of copolymerized Polylactic/ polyglycolic acids as a bone filler in combination with a cellular dermal matrix graft around immediate implants. *Int J Health Sci (Qassim)* 2014; 8(4): 381-92.
51. Wennerberg A, Albrektsson T. "On implant surfaces: a review of current knowledge and opinions," *The International Journal of Oral and Maxillofacial Implants* 2010; 25: 63-74.
52. Reigstad O, Johansson C, Stenport V, Wennerberg A, Reigstad A, Rokkum M. Different patterns of bone fixation with hydroxyapatite and resorbable CaP coatings in the rabbit tibia at 6, 12, and 52 weeks. *J Biomed Mater Res B Appl Biomater.* 2011; 99:14-20.
53. Wennstrom JL, Ekestubbe A, Grondahl K, Karlsson S, Lindhe L. Implant supported single-tooth restoration- a 5 year prospective study. *J Clin Periodontol* 2005; 32:567-574.
54. Mericske-Stern R, Steinlin Schaffner T, Marti P & Geering AH. Peri-implant mucosal aspects of ITI implant supporting overdentures. A five-year longitudinal study. *Clin Oral Implants Res* 1994; 5:9-18.
55. Yoo RH, Chuang SK, Erakat MS, Weed M, Dodson TB. Changes in crestal bone levels for immediately loaded implants. *Int J Oral Maxillofacial Implants* 2006; 21:253-261.
56. Payne AG, Tawse-Smith A, Kumara R & Thompson WM. One-year prospective evaluation of the early loading of unsplinted conical Brånemark fixtures with mandibular overdentures immediately following surgery. *Clin Implant Dent Relat Res* 2001; 3: 9-19.
57. Jimbo R, Coelho PG, Bryington M, Baldassarri M, Tovar N, Currie F, et al. Nano hydroxyapatite coated implants improve bone nanomechanical properties. *J Dent Res* 2012; 91(12):1172-7.
58. Coelho PG, Sudack P, Suzuki M, Kurtz KS, Romanos GE, Silva NR. In vitro evaluation of the implant abutment connection sealing capability of 53 different implant systems. *Journal of oral rehabilitation* 2008; 35(12):917-24.
59. Oh TJ, Yoon J, Misch CE, Wang HL. The causes of early implant bone loss: myth or science? *Journal of periodontology* 2002; 73(3):322-33.
60. Strietzel FP, Neumann K, Hertel M. Impact of platform switching on marginal peri-implant bone-level changes. A systematic review and meta-analysis. *Clin Oral Implants Res* 2015; 26(3):342-58.