

How to Cite:

Singh, N., Kaur, S., & Kaur, R. (2021). MARPE: Review of expansion technique. *International Journal of Health Sciences*, 5(S2), 86–95.
<https://doi.org/10.53730/ijhs.v5nS2.5376>

MARPE: Review of Expansion Technique

Navpreet Singh

Department of Orthodontics & Dentofacial Orthopaedics, Desh Bhagat Dental College & Hospital, Desh Bhagat University, Mandi Gobindgarh, India

Sukhpal Kaur

Department of Orthodontics & Dentofacial Orthopaedics, Desh Bhagat Dental College & Hospital, Desh Bhagat University, Mandi Gobindgarh, India

Rajdeep Kaur

Department of Orthodontics & Dentofacial Orthopaedics, Desh Bhagat Dental College & Hospital, Desh Bhagat University, Mandi Gobindgarh, India

Abstract--Contracted maxillary arch has always been a major concern to those who have interested themselves in regulation of teeth. Rapid expansion of maxilla by forceful separation has been discussed in orthodontic literature revealing considerable controversy over the desire and possibility of splitting the hard palate at the midsagittal suture as a mean of widening the dental arch and nasal cavity. Incorporation of mini screws in a conventional RPE appliance transforms it into a MARPE appliance. Mini screws ensure maximum skeletal expansion, keeping the dental expansion and resultant side effects to a minimum. Various designs have been recommended by authors around the globe; exclusively bone borne, teeth-bone borne and tissue-bone borne with two/ four mini screws in the assembly. Paramedian area 3 mm lateral to the suture in 1st premolar region is considered the most appropriate site for placement of mini screws. Anterior screws are placed in the rugae area while posterior screws in the para-midsagittal area.

Keywords--MARPE, expansion technique, skeletal expansion, paramedian area.

Introduction

Contracted maxillary arch has always been a major concern to those who have interested themselves in regulation of teeth. Rapid expansion of maxilla by forceful separation has been discussed in orthodontic literature revealing considerable controversy over the desire and possibility of splitting the hard

International Journal of Health Sciences ISSN 2550-6978 E-ISSN 2550-696X © 2021.

Corresponding author: Singh, N.; Email: navpreet2195@gmail.com

Manuscript submitted: 18 Sept 2021, Manuscript revised: 9 Nov 2021, Accepted for publication: 12 Dec 2021

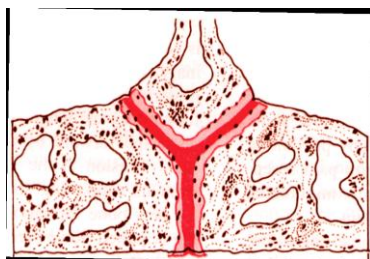
palate at the midsagittal suture as a mean of widening the dental arch and nasal cavity¹. The first reference to this procedure was that of Angell² in 1860s. Animal studies at the University of Illinois followed by clinical studies at his own practice led Haas¹ to report on the increase in nasal width and arch perimeter with maxillary expansion. Later, it was found that expansion performed after the peak pubertal growth spurt led to more dental than skeletal changes with side effects of buccal dental tipping³ and downward and backward rotation of mandible.

Brown introduced the concept of surgically assisted rapid palatal expansion (SARPE) in 1938⁴, which gradually became main treatment modality for adult patients with maxillary transverse discrepancy as it helped overcome increased resistance from bony plates and zygomatic buttress in adults leading to predictable skeletal and dental changes and low rate of relapse. However, many adult patients discouraged from choosing this treatment due to invasive nature, risks, complications and cost of the surgical procedure⁵. To minimize side effects of conventional rapid maxillary expansion like alveolar bone dehiscence, buccal crown tipping, root resorption and marginal bone loss, orthopedic expansion of basal bone is essential in non-growing patients. To ensure expansion of basal bone without surgical intervention and to maintain the separated bone in consolidation, Lee et al⁶ introduced Miniscrew assisted rapid palatal expansion (MARPE) and reported successful expansion of maxilla through opening of mid palatal suture. Incorporation of mini screws in a conventional rapid palatal expansion appliance transforms it into a miniscrew assisted rapid palatal appliance⁷. Three-dimensional finite element studies showed that these devices had greater skeletal and less dental side effects than traditional rapid maxillary expanders⁸.

Anatomy of palatal suture

It articulates anteriorly with maxilla through transverse palatal sutures and posteriorly through pterygoid process of the sphenoid bone. The interpalatine suture joins the two palatine bones at their horizontal plates and continuous as inter maxillary sutures. These sutures form the junction of three opposing pairs of bones: the premaxillae, maxilla, and the palatine. The entire forms mid-palatal suture. Mid Palatine Suture plays a key role in R.M.E. Shape of the suture throughout life⁹ is variable as: (fig 1)

- Infancy - Y-shape
- Juvenile - T-shape
- Adolescence - Jigsaw puzzle



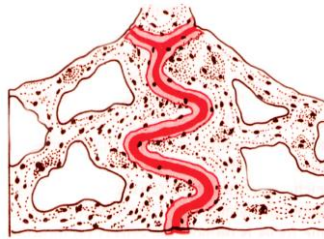


Figure 1. Shape of mid palatine suture

As sutural patency is vital to R.M.E, it is important to know when does the suture closes by synostosis and on an average 5% of suture is closed by age 25 yrs. Earliest closure occurs in girls aged 15 yrs¹⁰. Greater degree of obliteration occurs posteriorly than anteriorly.

Factors to be considered prior to expansion

Important factors to be considered in Rapid Maxillary Expansion:

- Rate of Expansion: By expanding at the rates of 0.3-0.5mm per day, active expansion is completed in 2-4 weeks, leaving little time for the cellular response of osteoclasts and osteoblasts seen in slow expansion.
- Form of Appliance: As the thrust is delivered to the teeth at the inferior free borders of the maxilla, expansion must reach to the basal portions. The form of appliance will play an important role in this effort, according to its rigidity or flexibility, i.e., anchorage or control of tipping.
- Age and Sex of the patient: The increasing rigidity of the facial skeleton with advancing age restricts bony movements remote from the appliance of expansion, which differs in both sexes.
- If discrepancy between maxillary and mandibular first molars & bicuspid width is 4mm or more RME indicated.
- Severity of cross bite i.e., number of teeth involved.
- Initial angulation of molars or premolars: When the maxillary molars are buccally inclined, conventional expansion will tip them further into the buccal musculature and if the mandibular molars are lingually inclined, the buccal movement to upright them will increase the need to widen the upper arch.
- Assessment of roots of deciduous tooth
- Physical availability of space for expansion.
- Nasal Obstruction: All patients considered for RME should be examined for nasal obstruction and, if obstruction is found, they should be referred to an otolaryngologist before orthodontic treatment.
- Medical history: Since the efficacy of maxillary expansion depends on suture patency and the flexibility of craniofacial complex to adapt to mechanical changes hence medical conditions altering these should be considered.
- Metabolic disorders: Many metabolic disorders are found associated with suture synostosis which include hyperthyroidism, hypophosphatemic vitamin D-resistant rickets, and mucopolysaccharidoses and mucopolipidosis. These disorders are mostly associated with bone metabolism. Maxillary expansion would be futile even in young patients if they are suffering from any of these diseases.

- Periodontal Type: It is essential to record the thickness of the gingival tissues during clinical evaluation of the periodontium. This is especially important because a thin and delicate gingiva might be prone to recession after traumatic, surgical, or inflammatory injuries.
- Mucogingival Health: Orthodontic tooth movement has significant effect on the mucogingival tissues and hence it is important to assess the periodontal health of the patient especially before performing maxillary expansion.

Indications of RME

Patients who have lateral discrepancies that result in either unilateral or bilateral posterior crossbites involving several teeth are candidates for RME. Anteroposterior discrepancies are cited as reasons to consider RME. For example, patients with skeletal Class II, Division 1 malocclusions with or without a posterior crossbite, patients with Class III malocclusions, and patients with borderline skeletal and pseudo-Class III problems are candidates if they have maxillary constriction or posterior crossbite. Etiology for maxillary constriction which indicate RME are:

- Habits-thumb sucking
- Obstructive sleep apnea
- Iatrogenic (cleft repair)
- Palatal dimensions and inheritance
- Muscular
- Syndromes
- Klippel-Feil syndrome
- Cleft lip and palate
- Congenital nasal pyriform aperture stenosis
- Marfan syndrome
- Craniosynostosis (Apert's, Crouzon's disease, Carpenter's)
- Osteopatia striata
- Treacher Collins
- Duchenne muscular dystrophy
- Non-Syndromic palatal synostosis

Biomechanics of miniscrew assisted sutural expansion

Lee et al¹² have identified the locations of centres of resistance of dento-maxillary complex in sagittal and frontal views. When an expansion force F is applied, an equivalent moment and force result at the centers of resistance of each maxillary half. The magnitude of the moment is equal to perpendicular distance Y from respective centers of resistance to the line of action of the expansion force. The moment equivalent (FY) tends to cause the maxillary halves to rotate about their respective centers of resistance, while the expansion force F equivalent at the center of resistance tends to translate the maxillary halves. The net result is to provide centers of rotation in line with and superior to center of resistance other than the frontonasal suture.(fig.2)

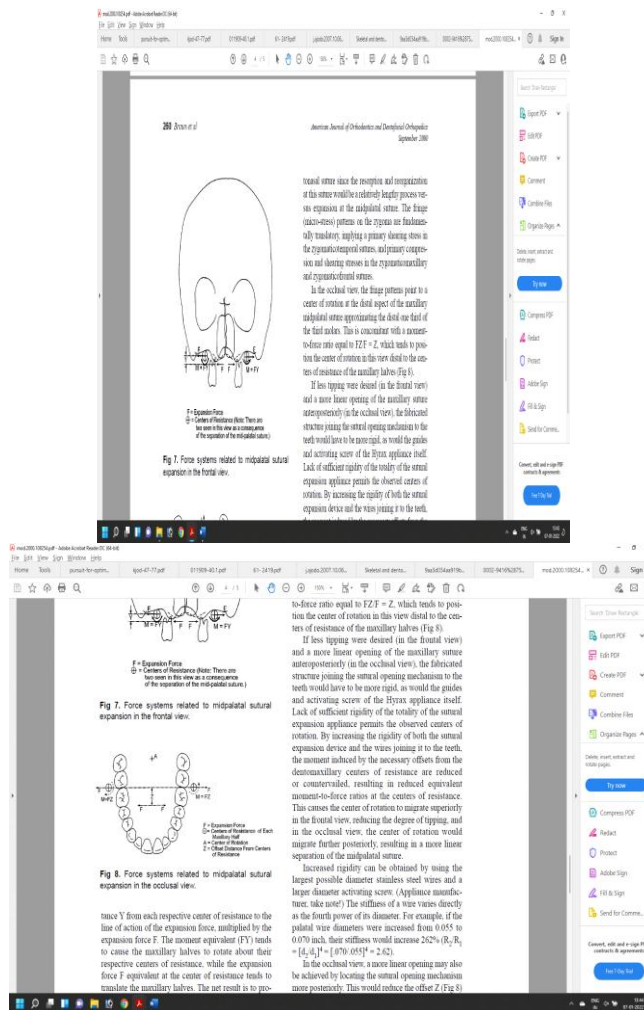


Figure 2. Force and moments generated during Expansion

If less tipping and more linear opening of maxillary suture antero-posteriorly is desired, the fabricated structure joining the sutural opening mechanism to the teeth would have to be more rigid. By increasing the rigidity of both the sutural expansion device and the wires joining it to the teeth, the moment induced by the necessary offsets from the dento-maxillary centers of resistance are reduced or counterbalanced, resulting in reduced equivalent moment-to-force ratios at the centers of resistance. This causes the center of rotation to migrate superiorly, reducing the degree of tipping, the center of rotation would migrate further posteriorly, resulting in a more linear separation of the mid-palatal suture. Increased rigidity can be obtained by using the largest possible diameter stainless steel wires and a larger diameter activating screw. (Appliance manufacturer, take note) The stiffness of a wire varies directly as the fourth power of its diameter. For example, if the palatal wire diameters were increased from 0.055 to 0.070 inch, their stiffness would increase 262% ($R_2/R_1 = (d_2/d_1)^4 = (0.070/0.055)^4 = 2.62$).

In the occlusal view, a more linear opening may also be achieved by locking the sutural opening mechanism more posteriorly. This would reduce the offset Z (Fig 8).

Appliance design

Appliance consists of a central expansion jack screw and four attached arms soldered to orthodontic bands on anchored teeth with 2 implant or 4 implant

design to facilitate placement of appliance. Teeth on which bands are soldered aid in stabilization of jack screw rather than anchorage of appliance as later is provided by the mini screws inserted into the palate.(fig.3)

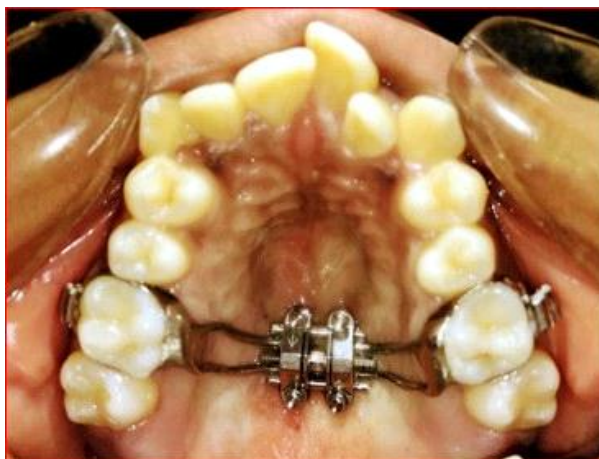

Figure 3. Design of appliance

Mini-screw configuration

Dimensions of mini screws as per the design of appliance i.e., 2 implant or 4 implant design. The length of implant chosen should consider height of insertion slot, space between the appliance and palate, thickness of palatal mucosa and a desired minimum of 5-7mm of bone engagement. Intention should be to achieve bi-cortical engagement aiding for better stability of mini screws 14.

Placement of mini-screw

Moon et al evaluated palatal bone density to allow for selection of placement sites for palatal miniscrews. He suggested that mini screws can be placed successfully in most palatal areas with equivalent bone densities to that located 3mm posterior to incisive foramen and 1-5 mm to para median 15.(fig.4)

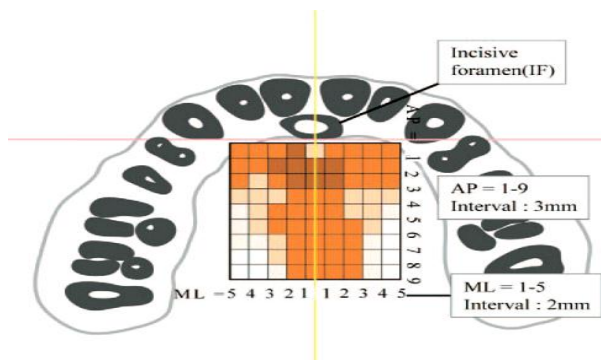
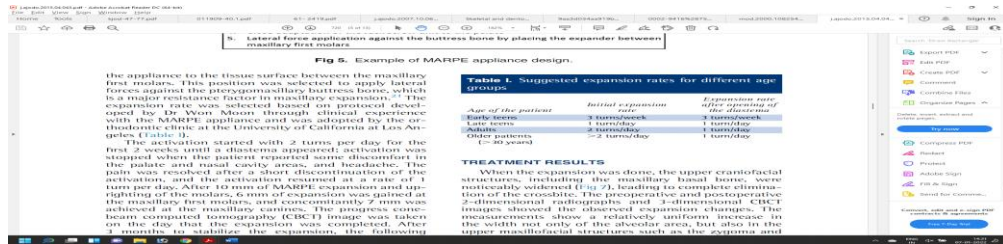


Figure 4. Placement of min screw

Activation schedule

Dr. Won Moon on his extensive work on MARPE developed protocol for expansion of maxilla¹⁶ as follows:



Biologic response of mid-palatal suture to maxillary expansion

The immediate effect of applying force to the suture results in trauma. Small, localized tears occurred within the suture from the localized blood vessels. These small defects are filled with exudate, a few extravasated red blood cells, scattered filaments of fibrin and a few fine collagen fibrils¹⁷. A transient polymorph response was noted in the region of the defects in the first 12 hours and thereafter was not seen again. Following the polymorph response, an influx of macrophages and pioneer fibroblasts into the defect occurred by 24 hours. Within 3 to 4 days, bone formation had begun at the margins of the suture achieved by the pre-existing and undamaged osteoblasts. These formed successive lamellae along the suture margin. The collagen fibers and cells are aligned transversely across the suture corresponding to levels of tension. New bone formation now occurred along the same axis as trabeculae formed at right angles to the lamellae deposited initially at the suture margins. With diminution and cessation of the expansion force (2 to 3 weeks), remodeling of both the bone and the suture occurred by the osteocytic and fibrocytic cell series until normal sutural dimensions were achieved. The mineral content within the suture rise rapidly during the first month after the completion of suture opening. The mineral content in the bone beside the suture decreased rapidly in the first month but returned to its initial level within 3 months¹⁸.

Effects of RME on maxillary complex

- **MAXILLARY HALVES**
It is seen that the two halves of the maxilla rotated in both the sagittal and frontal planes. The maxilla was found to be more frequently displaced downward and forward¹.
- **PALATAL VAULT**
The palatine processes of the maxilla were lowered because of the outward tilting of the maxillary halves, also the palatal vault height decreased significantly during RME. Palatal height returned to pretreatment values one year after expansion and increased an average of 0.5mm two years after treatment.
- **ALVEOLAR PROCESS**

It has been seen in studies that since bone is resilient, lateral bending of the alveolar processes occurs early during RME¹⁹.

- **MAXILLARY ANTERIOR TEETH**

From the patient's point of view, one of the most spectacular changes accompanying RME is the opening of a diastema between the maxillary central incisors. It is estimated that during active suture opening, the incisors separate approximately half the distance the expansion screw has been opened. Following this separation, the incisor crowns converge and establish proximal contact. If a diastema is present before treatment, the original space is either maintained or slightly reduced. The mesial tipping of the crowns is due to the elastic recoil of the transseptal fibers. Once the crowns contact, the continued pull of the fibers causes the roots to converge toward their original axial inclinations.

- **MAXILLARY POSTERIOR TEETH**

With the initial alveolar bending and compression of the periodontal ligament, there is a definite change in the long axis of the posterior teeth. Teeth show buccal tipping and believe to extrude to a limited extent²⁰.

MARPE can be an effective treatment modality for the correction of maxillary transverse deficiency in young adults through separation of the mid-palatal suture. Buccal tipping of maxillary teeth upon MARPE leads to the decrease in buccal alveolar bone thickness and crest height. Attending orthodontists should pay attention to these changes.

Retention and relapse of RME

Expansion through maxillary suture widening by rapid maxillary expanders has been claimed to promote stability after retention. Stability has been attributed to the skeletal component of arch enlargement obtained by the expansion appliance as opposed to dental expansion as a result of edgewise appliance mechanotherapy. The causes of Relapse are:

- High stress accumulated between the articulations of the craniofacial complex.
- Tension produced in the palatal mucosa.
- Imbalance between the buccal and lingual pressures, which is created because of maxillary expansion.
- The application of a fixed retainer immediately and after rapid maxillary expansion, then followed by an intermittent removable retention appliance is highly recommended.

Conclusion

Expansion achieved in the cases treated by MARPE are majorly skeletal expansion, as the appliance is a tooth-and-tissue borne appliance. It can be used in young adults from late teens to mid-twenties and exhibits a high success in this age group. Clinical observations suggest that MARPE prevents many of the adverse effects of RPE and should be considered as a preferred and effective alternative for the same ²¹.

References

1. Haas AJ. Rapid expansion of the maxillary dental arch and nasal cavity by opening the midpalatal suture. *Am J Orthod Dentofac Orthop.* 1961;31:73–90.
2. Angell DH. Treatment of irregularity of the permanent oradult teeth. *Dental Cosmos.* 860;1:599.
3. Ballanti F, Lione R, Fanucci E, et al. Immediate and postretention effects of rapid maxillary expansion investigated by computed tomography in growing patients. *Angle Orthod.* 2009;79:24–29.
4. The surgery of oral and facial diseases and malformations: their diagnosis and treatment including plastic surgicalreconstruction. *J Am Med Assoc.* 1939;112:2199
5. Asscherickx K, Govaerts E, Aerts J, Vande VB. Maxillary changes with bone-borne surgically assisted rapid palatal expansion: a prospective study. *Am J Orthod DentofacialOrthop.* 2016;149:374–383.
6. Lee KJ, Park YC, Park JY, Hwang WS. Miniscrew assisted nonsurgical palatal expansion before orthognathic surgery for a patient with severe mandibular prognathism. *Am J Orthod Dentofacial Orthop* 2010;137:830-9.
7. Kolge, Neeraj Eknath; Patni, Vivek J; Potnis, Sheetal S; Ravindra Kate, Swapnagandha; Fernandes, Floyd Stanley; Sirsat, Chetna Dadarao (2018). Pursuit for Optimum Skeletal Expansion: Case Reports on Miniscrew Assisted Rapid Palatal Expansion (MARPE). *Journal of Orthodontics & Endodontics*, 4(2).
8. Ludwig B, Baumgaertel S, Zorkun B, et al. Application of a new viscoelastic finite element method model and analysis of miniscrew-supported hybrid hyrax treatment. *Am JOrthod Dentofacial Orthop.* 2013;143:426–435.
9. Melson B. Palatal growth study on human autopsy material: Ahistologic micro radiographic study. *Am J Orthod* 1975; 68: 42-54.
10. Persson M, Thilander B. Palatal suture closure in man from 15 to 35years of age. *Am J Orthod* 1977;72:42-52.
11. Kumar SA, Gurunathan D, Muruganandham, Sharma S.Rapid Maxillary Expansion: A Unique Treatment Modality in Dentistry. *J Clin of Diagn Res.*2011; 5(4):906-911.
12. Lee KG, Ryu YK, Park YC, Rudolph DJ. A study of holographic interferometry on the initial reaction of maxillofacial complex during protraction. *Am J Orthod Dentofacial Orthop* 1997;111:623-32.
13. Braun S, Bottrel JA, Lee KG, et al. The biomechanics of rapid maxillary sutural expansion. *Am J Orthod DentofacOrthop.* 2000; 118:257–261.
14. Yilmaz A, Özçirpici AA, Erken S, Özsoy OP. Comparison of short-term effects of mini- implant-supported maxillary expansion appliance with two conventional expansion protocols. *Eur J Orthod*2015; 37: 556-64.
15. Moon SH, Park SH, Lim WH, Chun YS. Palatal bone density in adult subjects: implications for mini-implant placement. *AngleOrthod* 2010; 80: 137-144.
16. Carlson C, Sung J, McComb RW, Machado AW, Moon W. Microimplant-assisted rapid palatal expansion appliance toorthopedically correct transverse maxillary deficiency in an adult. *Am J Orthod Dentofac Orthop* 2016; 149: 716-728.
17. Ten Cate AR, Freeman E, Dickinson JB. Sutural development: structureand its response to rapid expansion. *Am J Orthod* 1977;71:622-36.

18. Ekstrm. C, Henrickson CO and Jeensen R. Mineralization in the midpalatal suture after orthodontic expansion. *Am J Orthod* 1977;71:449-55.
19. Isaacson RJ, Ingram AH. Forces produced by rapid maxillary expansion. Part II. forces present during treatment. *Angle Orthod* 1964;34:261-9.
20. Hicks EP. Slow maxillary expansion: a clinical study of the skeletal vsdental response in low magnitude force. *Am J Orthod* 1978;73:121-41.
21. Wehrbein H, Yildizhan F. The mid-palatal suture in young adults. A radiological-histological investigation. *Eur J Orthod* 2001; 23:105-114.