

How to Cite:

Gupta, G., Bhalla, P., & Singh, A. (2021). Treatment of gingival recession: Case report. *International Journal of Health Sciences*, 5(S2), 100–108.
<https://doi.org/10.53730/ijhs.v5nS2.5435>

Treatment of gingival recession: Case report

Gagandeep Gupta

Department of Periodontics and Implantology, Desh Bhagat Dental College & Hospital, Mandi Gobindgarh, India

Pritish Bhalla,

Department of Periodontics and Implantology, Desh Bhagat Dental College & Hospital, Mandi Gobindgarh, India

Aman Singh,

Department of Periodontics and Implantology, Desh Bhagat Dental College & Hospital, Mandi Gobindgarh, India

Abstract--This case report describes about treatment of gingival recession. Introduction: The increasing esthetic demands from patients has required that clinicians sharpen their skills and adopt newer and more novel techniques to satisfy these demands. In periodontal therapy, periodontal plastic surgery poses a substantial challenge to the clinician, both because it is technique sensitive and also because it includes a wide array of procedures and their variations. Conventional plastic procedures have provided satisfactory results in the treatment of gingival recession but there is, presently, a greater need for more advanced procedures that cause less surgical morbidity as also provide improved results. Minimally invasive surgery has been harnessed in periodontics for this purpose and has been extensively used in multiple indications, including root coverage. Novel-Vestibular Incision Supra-periosteal Tunnel Access (N-VISTA) applies the principles of minimally invasive surgery to provide satisfactory results in root coverage. Very less literature is available about the success of N-Vista Surgery in Mandibular arch. Case presentation: A 23-year-old female patient presented with localised Miller Class I/II buccal recession defects on mandibular anterior teeth. N-VISTA technique allowed coronal repositioning of gingival margin, which was then stabilized by buttons made of composite that was made using orthodontic separators on the labial surface of mandibular anteriors. Collagen graft was inserted in the supra-periosteal tunnel and vertical incision was sutured. Complete root coverage was achieved and maintained even after nine months with excellent aesthetic outcomes. Conclusion: The use of connective tissue

graft along with M-VISTA technique allows the clinician to successfully treat multiple recession defects.

Keywords--gingival recession, esthetics, treatment, connective tissue graft, mucogingival surgery, plastic periodontal surgery, cosmetic periodontal surgery

Introduction

A wide range of therapeutic options are available in the management of marginal recession defects, including soft tissue tunnelling.¹ Various Tunnelling techniques were proposed to preserve aesthetics, prevent relapse, maintain papillary integrity and prevent the scarring resulting from vertical releasing incisions.^{2,3} Tunnelling is a widely accepted but highly sensitive and blind technique causing trauma to the sulcular epithelium, resulting in less than acceptable outcomes. M-Vestibular Incision Supra-periosteal Tunnel Access (M- VISTA)⁴ was proposed to avoid the potential complications occurring with tunnelling techniques. The M-VISTA technique incorporates a supra-periosteal flap design instead of the original sub-periosteal approach. Also M-VISTA technique proposes use of Orthodontic brackets to secure the sutures instead of the original method of luting the sutures using composite resin on the labial surface of tooth. The Novel Vestibular Incision Supra-periosteal Tunnel Access (N-VISTA) proposes to further modify it by using labial buttons made of composites using the orthodontics separators to fasten the sutures. The Orthodontic Brackets used in original M-VISTA technique often leads to labial trauma as it keeps impinging on the inflamed labial tissue after the surgery. The N-VISTA techniques avoids use of brackets and replaces it with the highly polished and rounded composites buttons made in vivo. The aim of the present clinical case report is to describe the N-VISTA technique, combined with Collagen graft, in the treatment of gingival recession.

Case presentation

A 23-year-old, healthy (ASA I)⁷ female reported on June 18th, 2019, to the Department of Periodontics and Oral Implantology, Desh Bhagat Dental College and Hospital, Mandi Gobindgarh, India, with a chief complaint of receding gums, poor esthetics and sensitivity in relation to the left lower front teeth. The patient was a non- smoker with no history of periodontal disease. Clinically class I/II Miller gingival recession defects were observed at teeth #41,31 without concomitant papillary loss, root caries or radiographic interproximal bone loss (Fig.1). The treatment plan included oral prophylaxis implemented four weeks prior to the surgical procedure. Written informed consent was obtained from the patient.

Case management

Button preparation

The labial surface of the tooth #41 & #31 was etched and bonded maintaining dry field (Figure 2). After bonding agent was applied, orthodontic separators were placed over the labial surface and flowable composite resin was injected in the

hole of separator (Figure 3). After injecting the composite, it was light cured. Once Light Cured, the separator was removed (Figure 4). This is how we created the composite buttons on the labial surface of the tooth.

V.I.S.T.A.

Under sterile conditions, local anesthesia was given. Tunnel Access incision was made in the labial vestibule adjacent to the tooth #41, 31. The resulting tissue opening provided access to the buccal recession defects on teeth #41,#31 (Figure 5). A split-thickness tunnel was then prepared supra-periosteally, leaving the periosteum intact. An intrasulcular incision was given at teeth #41,31 to provide continuity with the supra-periosteal tunnel. To prevent tension during coronal advancement, the dissection was carefully extended beyond the mucogingival junction (Fig. 6a, 6b). Following recipient bed preparation, the Collagen membrane was tucked with the aid of a micro-tweezer into the prepared tunnel through the vestibular incision (Fig. 7a, 7b). The graft was stabilized on the periosteum using interrupted sutures (Polyglycolic acid #5-0). The sutures were then horizontally passed across the gingiva, coronally advancing the gingival margin 2mm beyond the cemento-enamel junction (CEJ), and stabilized by labial button created earlier (Fig. 8). Periodontal dressing was given. The patient was asked to refrain from brushing for 2 weeks; Ibuprofen 400mg for postoperative pain and chlorohexidine mouthwash (0.12%) was prescribed. The healing was almost complete by 1week (Figure 9). The brackets were debonded after two weeks. The patient was followed up at two weeks, one, three, six and nine months.

Case outcome

Healing was uneventful. Complete root coverage and an intact papilla was observed at one month (Figure 10) which was subsequently maintained even at 9th month (Fig. 11). The probing depths, mid-buccally on the treated teeth, were limited to 1mm. The root coverage esthetic score for both the clinician and the patient ranged between 9 to 10 with respect to color match and texture.⁹ The surgical site demonstrated an increase in both gingival thickness and width of the keratinized gingiva. The patient's hypersensitivity resolved completely.

Discussion

In this era of patient centred esthetic outcome, restoring the ideal pink and white esthetics is a prime requisite. The M-VISTA technique differs from the original VISTA in incision design, supra-periosteal tunnel access, the graft used and suturing.¹⁰ The N-VISTA is different from M-VISTA in one single aspect, that is the way the repositioned gingiva is secured.

The improved visual access allowed for a more meticulously executed surgery, reducing surgical time, and increasing patient comfort. As opposed to the original VISTA technique, the supra-periosteal tunnel left the periosteum intact over the facial bone, maintaining its vascularity and preventing further bone loss.^{4,11,12} Periosteum retention provides early revascularisation of the site, leading to perfect tissue blending in terms of color and texture.^{11,13} In addition, studies have

implied that the lamina propria consists of genetic information that dictates the keratinization of the overlying surface.¹⁴

Conclusion

The N-VISTA resulted in patient centred esthetic outcome with increased patient comfort and reduced surgical visits. The supra-periosteal tunnel provided greater vascularity and the resin button anchored sutures offered a tension free advancement. Hence, this minimally invasive surgical technique may allow the clinicians to attain functionally and esthetically pleasing root coverage in the mandibular anterior area. Future comparative studies may be undertaken to prove its efficacy over time.

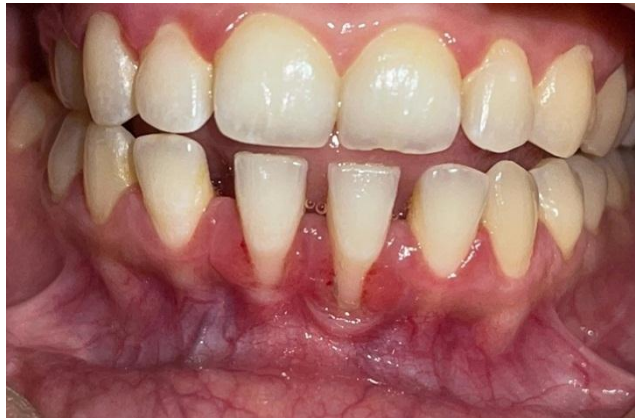

Figure 1: Pre Operative

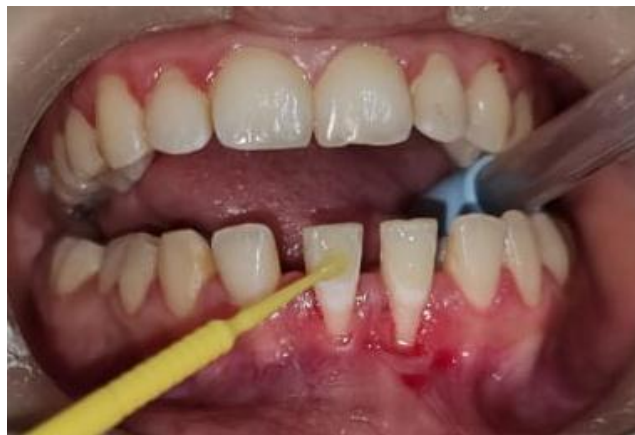

Figure 2: After Etching and Bonding

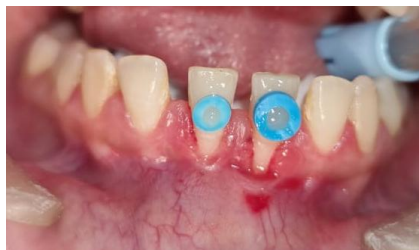

Figure 3: Composite Resin Placed inside Orthodontic Separators

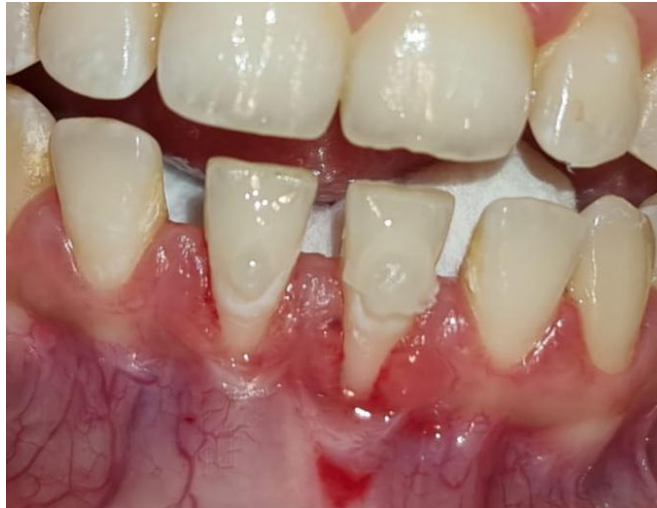

Figure 4: After Removing the Orthodontic Separators

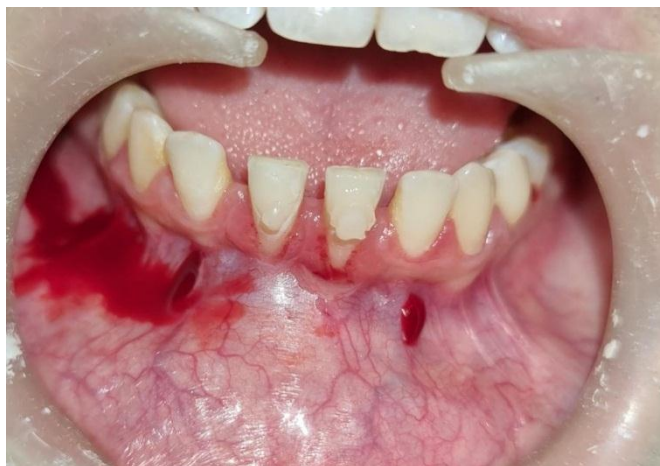

Figure 5: Vestibular Incision for Sub-periosteal Tunnel Access

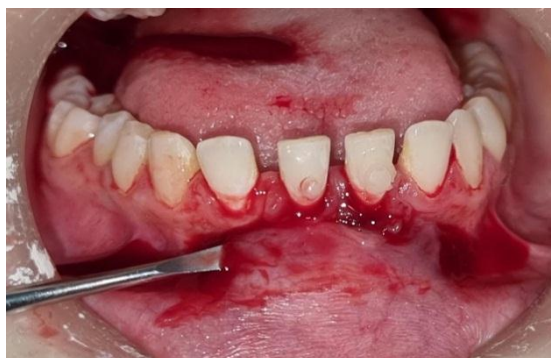

Figure 6a: Tunnel extended 2mm beyond Mucogingival Junction

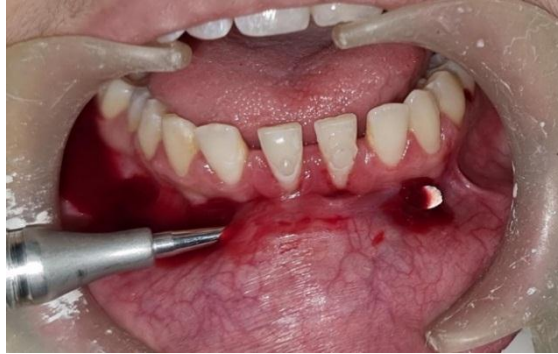

Figure 6b: Tunnel extended 2mm beyond Mucogingival Junction

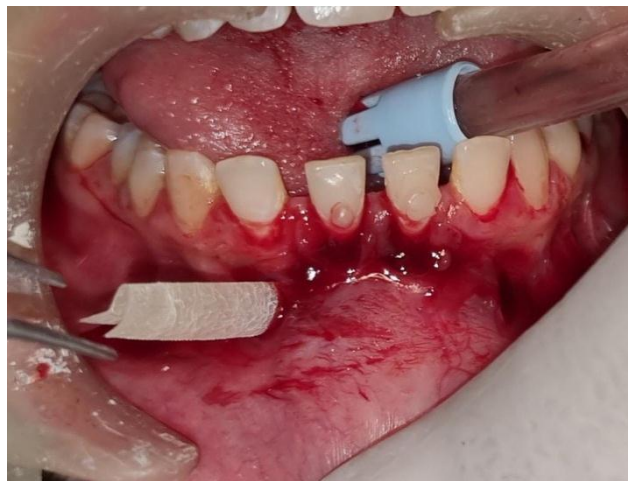

Figure 7a: Collagen Membrane inserted using Tweezer

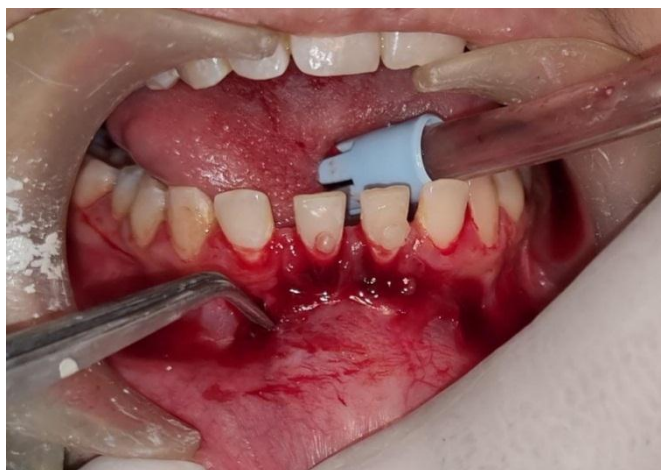

Figure 7b: Collagen Membrane inserted using Tweezer

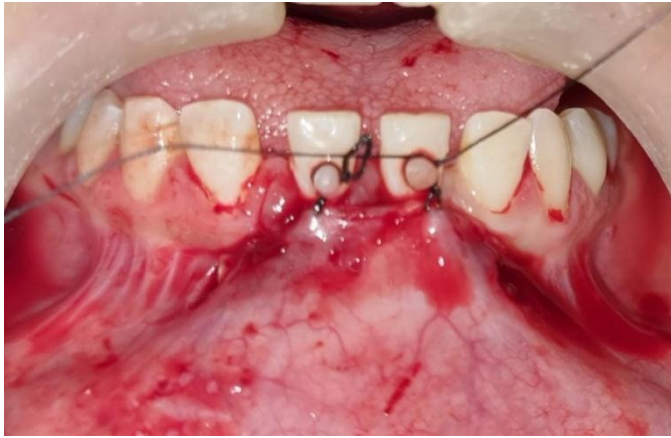


Figure 8: Gingival Margin secured with Labial Button using Sutures

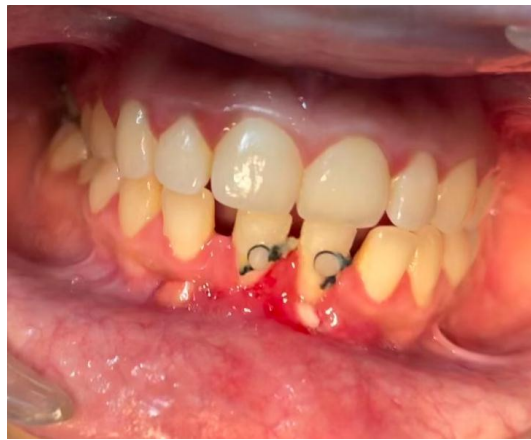

Figure 9: Healing after 1 week

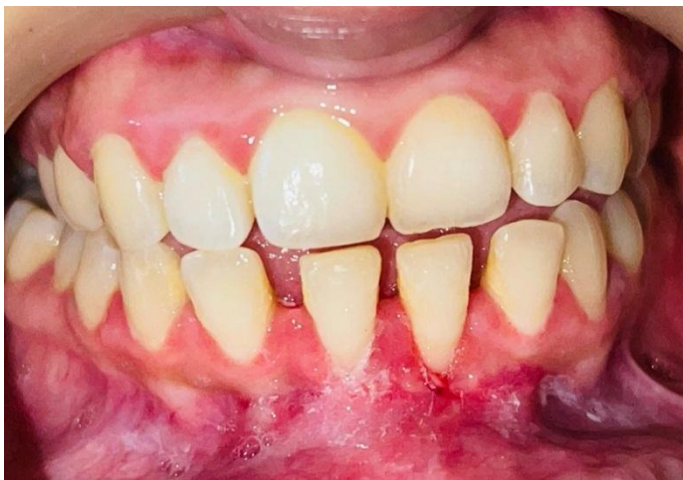

Figure 10: Healing after 4 weeks.

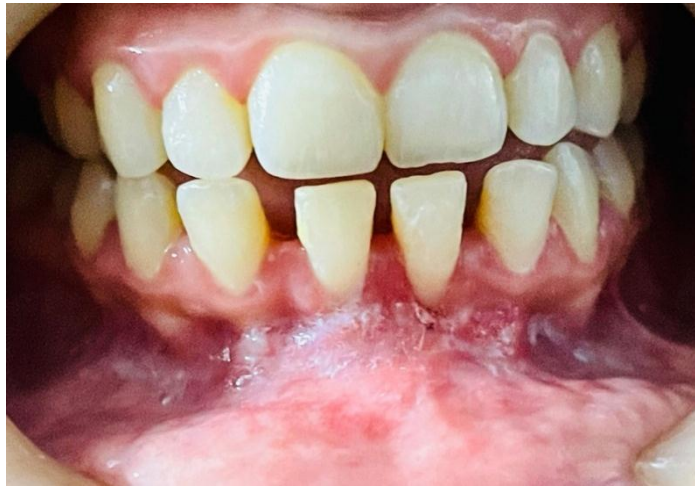

Figure 11: Healing after 9 months

References

1. Chambrone L, Tatakis DN. Periodontal soft tissue root coverage procedures: a systematic review from the AAP Regeneration Workshop. *J Periodontol* 2015;86:S8-51.
2. Zabelgui I, Sicilia A, Cambra J, Gil J, Sanz M. Treatment of multiple adjacent gingival recessions with the tunnel subepithelial connective tissue graft: A clinical report. *Int J Periodontics Restorative Dent* 1999;19:471-479.
3. Tözüm TF, Dini FM. Treatment of adjacent gingival recessions with subepithelial connective tissue grafts and the modified tunnel technique. *Quintessence Int* 2003;34:7-13
4. Chun-Thee Lee, Techkouhie Hamalian, Ulrike Schulze-Späte. Minimally invasive treatment of soft tissue deficiency around an implant-supported restoration in the esthetic zone: Modified VISTA technique case report. *J Oral Implantol* 2015;41:71-76.
5. Harris RJ. Root coverage with connective tissue grafts: An evaluation of short- and long- term results. *J Periodontol* 2002;73:1054-1059.
6. Oates T, Robinson M, Gunsolley JC. Surgical therapies for the treatment of gingival recession. A systematic review. *Ann Periodontol* 2002;3:303-320.
7. Mupparapu M, Singer SR. Editorial: The American Society of Anesthesiologists (ASA) physical status classification system and its utilization for dental patient evaluation. *Quintessence Int* 2018;49:255-256.
8. Hurzeler MB, Weng D. A single-incision technique to harvest subepithelial connective tissue grafts from the palate. *Int J Periodontics Restorative Dent* 1999;19:279-287.
9. Cairo F, Rotundo R, Miller PD, Pini Prato GP. Root coverage esthetic score: a system to evaluate the esthetic outcome of the treatment of gingival recession through evaluation of clinical cases. *J Periodontol* 2009;80:705-710.
10. Zadeh HH. Minimally invasive treatment of maxillary anterior gingival recession defects by vestibular incision subperiosteal tunnel access and platelet-derived growth factor BB. *Int J Periodontics Restorative Dent* 2011;31:653-660.

11. Allen AL. Use of the suprapariosteal envelope in soft tissue grafting for root coverage. I. Rationale and technique. *Int J Periodontics Restorative Dent* 1994;14:216-227.
12. Fickl S, Kerschull M, Schupbach P, Zühr O, Schlagenhauf U, Hürzeler MB. Bone loss after full-thickness and partial-thickness flap elevation. *J Clin Periodontol* 2011;38:157-162.
13. Caffesse RG, Burgett FG, Nasjieti CE, Costelli WA. Healing of free gingival grafts with and without periosteum. *J Periodontol* 1979;50:586-594.
14. Karring T, Lang NP, Loe H. The role of gingival connective tissue in determining epithelia differentiation. *J Periodont Res* 1975;10:1-11.
15. Hui-Yuan Ko, Hsein-Kun-Lu. Systematic review of the clinical performance of connective tissue graft and guided tissue regeneration in the treatment of gingival recessions of Miller's classification grades I and II. *J Exp and Clin Med* 2010;2:63-71.