

**How to Cite:**

Elsharkawy, H., Hegazy, M., Mohamed, M. T., Hanna, A. A. A., Farghaly, A., & Abdelhamid, A. M. (2022). Assessment of percutaneous correction of genu varum in children and young adults . *International Journal of Health Sciences*, 6(S2), 2677–2695. <https://doi.org/10.53730/ijhs.v6nS2.5619>

## **Assessment of percutaneous correction of genu varum in children and young adults**

**Hosam Elsharkawy**

Msc of Orthopedics and traumatology faculty of medicine Al Azhar University  
Email: [hosamelsharkawy@hotmail.com](mailto:hosamelsharkawy@hotmail.com)

**Mohamed Hegazy**

Professor of Orthopedics- Cairo University

**Mohamed Tageldeen Mohamed**

Professor of Orthopedics- Cairo University

**Atef Abdel Aziz Hanna**

Professor of Orthopedics- Cairo University

**Ahmed Farghaly**

Msc of Orthopedics and traumatology faculty of medicine Ain Shams University

**Alhassan Mohamed Abdelhamid**

Msc of Orthopedics and traumatology faculty of medicine Al Azhar University

**Abstract**---Purpose: Corrective osteotomy is the gold standard for varus angular deformity, but is a major surgical intervention with operative site morbidity. The proposed percutaneous technique adds a lot of privileges to corrective osteotomy . It is cosmetically accepted , minimize the risk of infection, acute correction, no need for plate fixation or for a staged operation to remove hardware. Patients and methods: 25 cases (30 limbs) were included in our study. 12 patients were males (14 limbs) and 13 patients were female (16 limbs). Six patients have bilateral genu varum, 19 have unilateral genu varum. The youngest was 13 years and the oldest was 50 years with average (20) years. All patients were treated with percutaneous upper tibial osteotomy technique and above knee casting. The protocol of postoperative rehabilitation was standardized. The patients were followed post-operatively for at least 3 months to evaluate the correction, time required for union, knee joint range of motion, and the overall functional result of the knee using bostman scoring system. Results: All patients treated with the percutaneous osteotomy

consolidated and displayed a marked improvement of functional and radiological outcome measures. Nevertheless, there were 2 under corrected and one case showed skin maceration due to water spelled on cast. Conclusion: The use of percutaneous osteotomy can fulfill its role for correction without exposure to the hazards associated with the standard technique

**Keywords**---above knee cast (AKC), mechanical axis deviation (MAD), medial proximal tibia angle (MPTA).

## Introduction

Angular deformities of the lower limbs are common during childhood and adulthood. In most cases, this represents a variation in the normal growth pattern and is an entirely benign condition(1). Angular deformities of the knee alter the biomechanics of the knee by causing a distorted stress distribution on the weight-bearing surface of the knee joint(2). Because of the wide range of disorders causing angular deformity, history and physical examination need to be sufficiently broad. Elements to elicit from the history include a full birth and family history, nutritional assessment, evaluation of prior fractures, infections, surgeries, age of onset of walking, and the time course of deformity evolution(3).

Lower extremity angular deformity arises in any of the three planes (coronal, sagittal, transverse) When progressive, these deformities can lead to gait abnormalities, pain, or development of future arthritis and disability(3). There are two surgical options for dealing with progressive angular deformities in children: osteotomy or guided growth(4). Osteotomy still considered the "gold standard" by some, is associated with increased expenses and morbidities, including over or under correction, neurovascular risk, hardware healing problems and recurrent deformity with growth(4).

The most common methods to realign a bone are an open or closing wedge osteotomy. Opening wedge osteotomies have the disadvantage of creating a defect between the bone ends that must fill in or be filled with bone graft. Closing wedge osteotomies have the disadvantage of needing greater exposure of the bone circumferentially in order to safely remove a wedge of bone. In the opening wedge osteotomy, undesired lengthening may be produced, while a closing wedge osteotomy may produce undesired shortening. The opening wedge osteotomy is adjustable but is relatively unstable due to minimal bone contact. The closing wedge osteotomy leaves little room for adjustment but produces a very stable situation with a large surface area of bone contact. Both opening and closing wedge osteotomies allow concomitant rotational and translational correction(5).

There are various possibilities for surgical correction of varus malalignment. The purpose of the procedure, which may be a medial opening wedge, lateral closing wedge, dome or "en chevron" osteotomy, is to shift the mechanical axis of the lower limb from the medial to the lateral compartment, thereby reducing the load and contact area over the medial compartment. Unfortunately, local complaints occurred mostly caused by the fixation methods and stability of fixation

method(6,7). Bone healing and length are often opposing considerations. In osteotomies stabilized by plating or nailing, an opening wedge risks non-union and a closing wedge leads to shortening(7). Guided growth is an attractive surgical option for correction of angular deformity in skeletally immature patients. Although guided growth is technically feasible for deformity in any plane or extremity, it is used most commonly and most predictably for coronal plane deformities about the knee(8).

### **Patients and Methods**

This prospective study included 25 cases of genu varum 12 patients were males (14 limbs) and 13 patients were female (16 limbs). Six patients have bilateral genu varum, 19 have unilateral genu varum. The youngest was 13 years and the oldest was 50 years with average (20) years. They were operated in the period between November 2018 and July 2020 at Cairo University Hospital and El-Helal Hospital, Cairo. Our study population included all patients presented above the age of 4 years with genu varum having a Tibio- femoral angle of more than 5 degrees and medial MAD (zone-2 and -3 according to Mecaahnical axis zones ). All patients with any other associated deformity were excluded:

Flexion deformity (fixed flexion deformity > 15 degree), genu recurvatum severe collateral ligament instability, evidence of subluxation, metabolic disorders, morbid obesity and Blount disease . Evaluation included preoperative history taking, physical examination, laboratory investigation and radiographic measurements. Postoperatively, outcome was measured according to the clinical improvements, radiographic measurements and modified Bostman knee score. From history taking, there was no specific maternal problems during pregnancy, no family history of similar cases. The main complaint of the patients was the awkward walking, the abnormal shape of the lower limbs or infrequently knee pain. On presentation, each patient was examined carefully. Examination begins with general examination of the patient for any musculoskeletal problem including upper limb, lower limb and spine. Any patient with associated musculoskeletal deformity due to any syndrome was excluded. Local examination is done with assessing the function score of the patient using modified Bostman knee score. Radiographically, an appropriate standing scanogram can determine the site of deformity and the angel of deformity. Certain angles were measured including; Mechanical axis deviation (MAD), Tibio-femoral angle, Medial proximal tibial angle (MPTA). All these angles were measured at preoperative visit, postoperative and at the follow up. Outcome measures include; improved clinical knee appearance, improved function either walking or climbing stairs ability. On standing scanogram, the restore of the normal angles between the femur and tibia components is a measure of good outcome. Patient satisfaction was included using a questionnaire about the treatment method, satisfaction about the results and modified Bostman knee score(41). All the patients in the series needed the minimally invasive surgical intervention as a primary procedure for maintaining the reduction but some patient (1 case) noticed the difference because they underwent the conventional corrective osteotomy and fixation using a ilizarov on the other side.

### **Surgical Technique**

Spinal anaesthesia was used in all patients except for 7 patients operated under general anaesthesia. The patient is positioned supine on a radiolucent table making sure that the ipsilateral hip, knee, and ankle joints can be visualized with the image intensifier. The operative extremity is prepped and draped in the usual fashion. A sterile tourniquet is placed and raised prior to incision. The surgeon position on the same side while C-arm sets on the contralateral side.

### **Operative technique**

1-Fibular osteotomy is performed at the middle of the fibula.

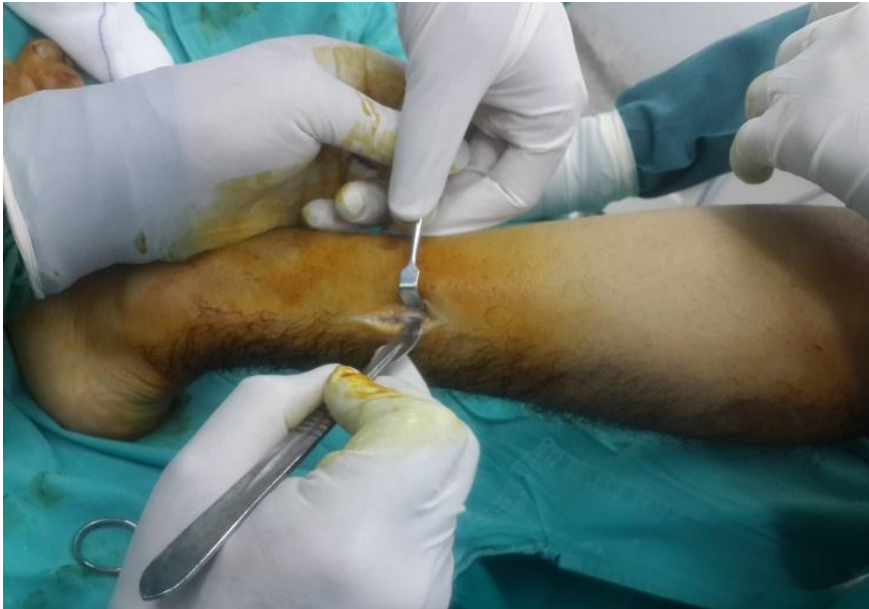

Figure (1): Fibular osteotomy is performed at the middle of the fibula

2-Upper tibial osteotomy: skin incision is small lateral 1-2 Cm incision in upper tibia just distal to tibial tuberosity.

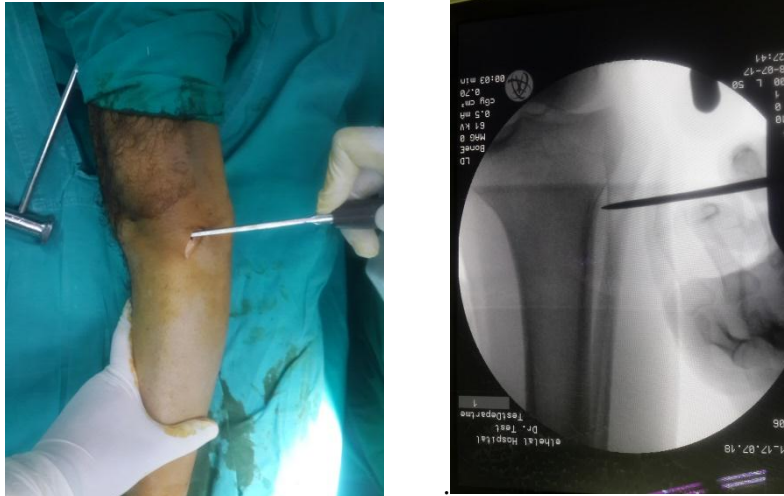

Figure (2): Upper tibial osteotomy : skin incision is small medial 1-2 Cm incision in upper tibia just distal to tibial tuberosity

3-Osteotomy of the lateral cortex only and crushing of the cancellous bone by swinging the osteotome proximally and distally.

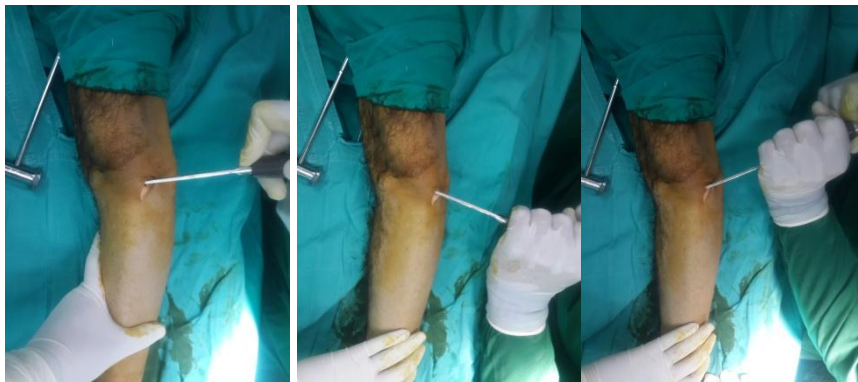

Figure (3): crushing of the cancellous bone by swinging the osteotome proximally and distally

4- Now the lateral cortex is crushed and widely opened of what is called the lateral window and if we push the osteotome through this window it will proceed without resistance until it is held by the far cortex .

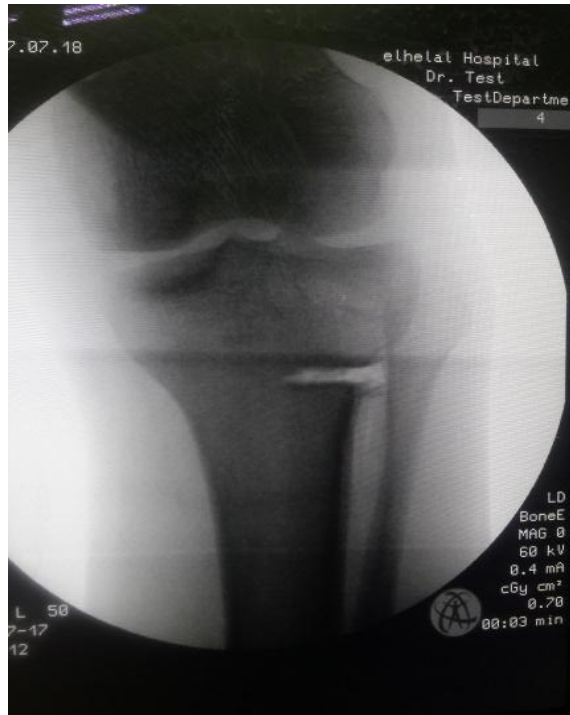

Figure (4): lateral window

5- 4.5 or 3.2 mm drill bit is used to drill the anteriomedial , medial , posteromedial then posterior cortex in an ordered fashion.

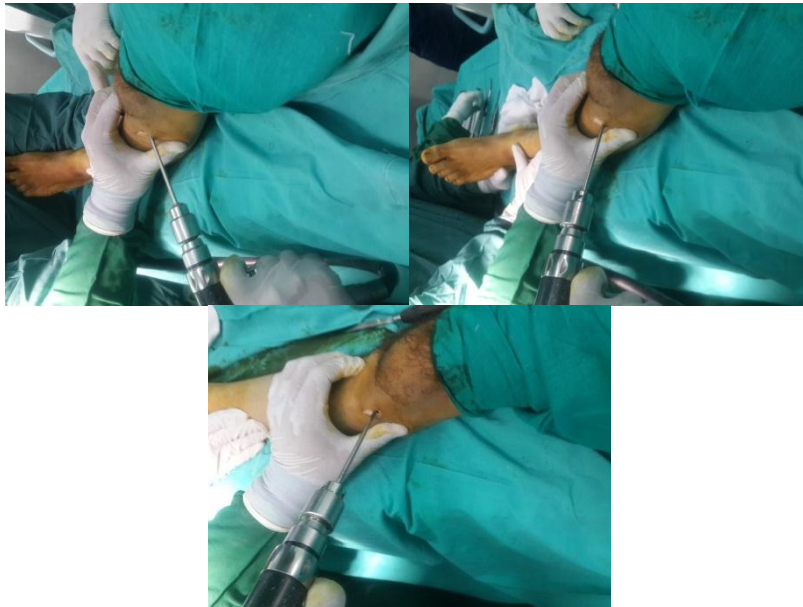

Figure (4): drilling of the anteriomedial , medial , posteromedial then posterior cortex in an ordered fashion

6- The osteotome is advanced easily without resistance through the medial cortical window and is pushed against the far drilled cortex. Axial pressure is applied manually on the osteotome then gentle hammering is done so a sense of release could be appreciated then hammering stopped so as to protect the soft tissue sleeve from injury by advancing the osteotome and checked by image intensifier. Thus the drill holes are connected by the osteotome and the correction is done by a hand is pushing against the upper lateral tibial surface and the other hand is pushing against the lower tibial shaft.

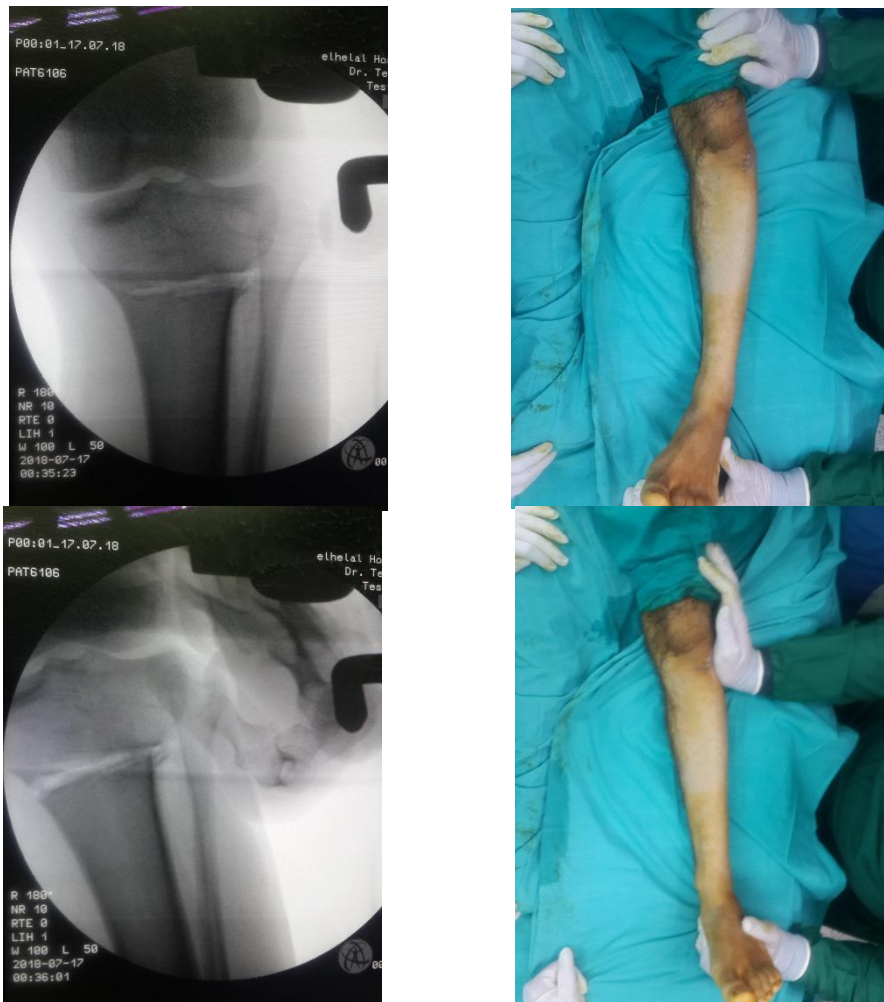


Figure (6): The correction is done by a hand is pushing against the upper lateral tibial surface and the other hand is pushing against the lower tibial shaft

7-Confirmation of correction under C-arm guidance ( AP and Lateral views)

8-Skin closure using absorbable sutures

9-Above knee casting is done by the chief surgeon holding the reduction while the assistant applies the AKC. The planter surface is plunted so as to allow immediate post operative weight bearing.

10- Percutaneous crossed wires may be used in obese patients

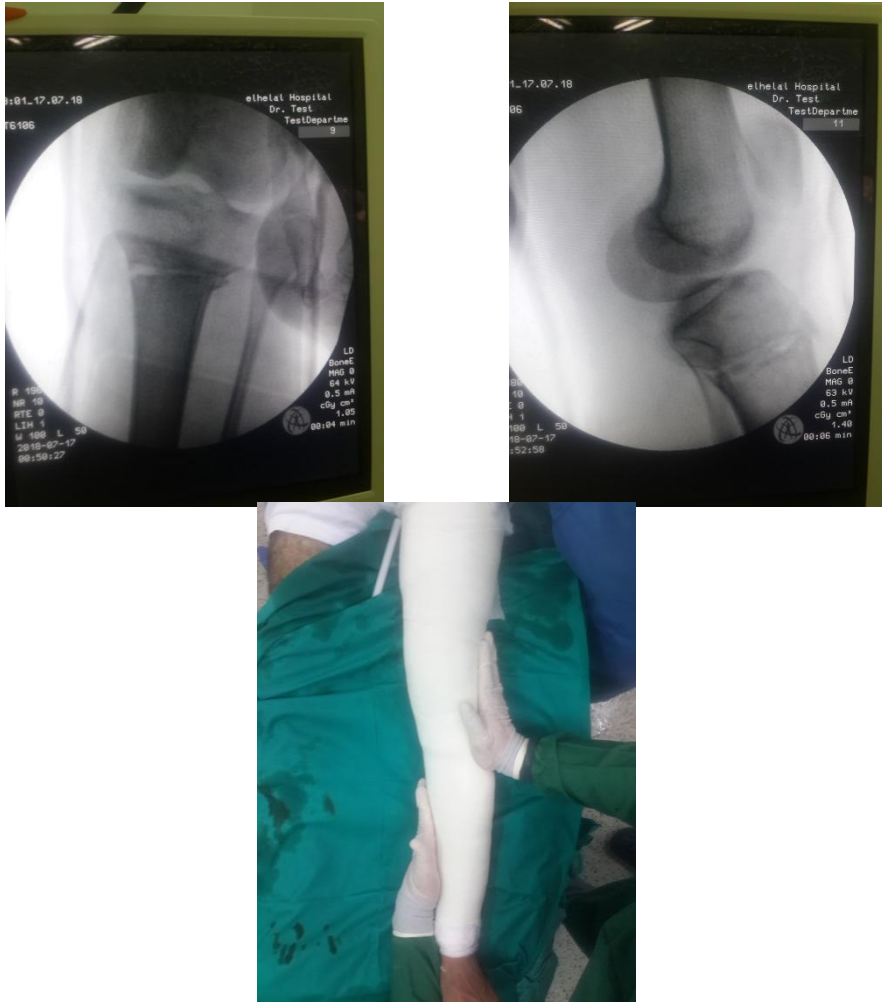


Figure (7): Above knee casting is done by the chief surgeon holding the reduction while the assistant applies the AKC

**Postoperative Care and Rehabilitan**

a- Post operative long film xray is done centered over the knee and the tibia.

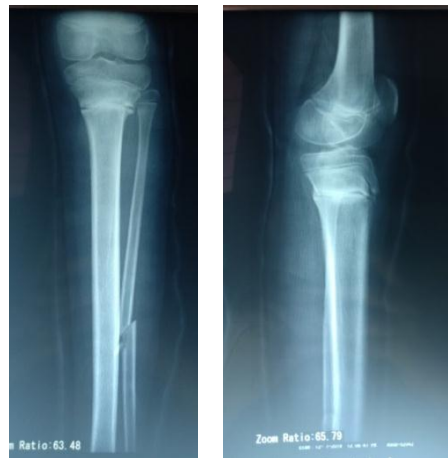

Figure (8): Post operative long film xray

- b- Assisted weight bearing is allowed as tolerated from first day.
- c- After 2 weeks X-ray and scanogram are requested to measure the correction and recasting could be done to increase or decrease the correction.
- d- After 6 weeks xray is done to assess union of the osteotomy and the cast may be removed and the patient start ROM.
- e- After 8 weeks check the the alignment using standing scanogram and start training by 3 – 5 mintes walking and 3 – 5 mintes cycling to be increased by a minte per day till 30 mintes of walking and cycling is achieved after one month.

After 3 months to assess the correction by: the knee score as suggested by Bostman et al to assess the functional outcome.

## Results

This is a prospective case series study, consists of 25 patient with genu varus; 12 females (48%) and 13males (52%). Mean age of case was  $20.72 \pm 8.24$  years and range from 11 to 40 years. All cases were corrected surgically by percutaneous upper tibial osteotomy and above knee cast. Mean duration of surgery was  $41.08 \pm 7.99$  minutes and ranges from 30 to 60 minutes. Outcome of surgery evaluated by comparing pre and post operative scores.

Table (1): Side of lesion in the study group (n=25)

Side of lesion	N	%
Right	8	32
Left	14	56
Bilateral	3	12

Within the study group, 32% of cases have lesion at right side, 56% have lesion at left and 12% have bilateral lesions.

Table (2): Disturbution of causes in the study group (n=25)

<b>Cause</b>	<b>N</b>	<b>%</b>
Idiopathic	22	88
Hyperparathyroidism	2	8
Osteoarthritis	1	4

Within the study group, most of cases have idiopathic cause (88%), 8% have hyperparathyroidism and 4% have osteoarthritis.

Table (3): Distribution of complications in the study group (n=25)

<b>Complications</b>	<b>N</b>	<b>%</b>
No complications	19	76
Recurrence	3	12
Skin maceration from water spelled on cast	1	4
Under correction	2	8
<b>Total</b>	<b>25</b>	<b>100</b>

Table (4): Comparing between pre and post operative Bostman Knee score in the study group by ANOVA test (n=25)

<b>Bostman Knee score</b>	<b>Mean</b>	<b>SD</b>	<b>P.value</b>
Pre operative	26.68	0.87	0.0003*
Post operative	28.97	2.98	

\* P < 0.05 is considered significant

Regarding Bostman Knee score, there is statistically significant increase of mean postoperative score (28.97), in comparison to preoperative score (26.68) ((P<0.05).

Table (5): Comparing between pre and post operative ICD score in the study group by ANOVA test (n=25)

<b>ICD score</b>	<b>Mean</b>	<b>SD</b>	<b>P.value</b>
Pre operative	7.61	2.12	0.6535
Post operative	6.77	9.47	

Regarding ICD score, there is statistically insignificant difference between pre and postoperative ICD score (7.61, 6.77 respectively) ((P>0.05).

Table (6): Comparing between pre and post operative MAD score in the study group by ANOVA test (n=25):

MAD score	Mean	SD	P.value
Pre operative	-2.61	0.95	<0.0001*
Post operative	-0.35	0.87	

\* P < 0.05 is considered significant

Regarding MAD score, there is statistically significant increase of mean postoperative score (-0.35), in comparison to preoperative score (-2.61) ((P<0.05).

Table (7): Comparing between pre and post operative TFA score in the study group by ANOVA test (n=25)

TFA score	Mean	SD	P.value
Pre operative	11.21	11.11	0.0003*
Post operative	1.71	4.16	

\* P < 0.05 is considered significant

Regarding TFA score, there is statistically significant decrease of mean postoperative score (1.71), in comparison to preoperative score (11.21) ((P<0.05).

Table (8): Comparing between pre and post operative MPTA score in the study group by ANOVA test (n=25)

MPTA score	Mean	SD	P.value
Pre operative	82.03	3.91	<0.0001*
Post operative	88	2.09	

\* P < 0.05 is considered significant

Regarding MPTA score, there is statistically significant increase of mean postoperative score (88), in comparison to preoperative score (82.03) ((P<0.05).

Table (9): Pearson correlation (R) between pre and postoperative scores in the study group (n=25)

Postoperative score	Preoperative score	
	R	P. value
Bostman Knee score	-0.030	0.8736
ICD	0.215	0.2544
MAD	0.169	0.3623
TFA	-0.123	0.5253
MPTA	0.528	0.0023*

\* P < 0.05 is considered significant

There is statistically significant positive correlation between preoperative MPTA score and postoperative MPTA score (R +ve P.<0.05).

### **Discussion**

Varus gonarthrosis is one of the most frequently encountered abnormalities currently seen by orthopedic surgeons. There are 3 surgical options for the correction of genu varum deformity:

Acute correction by corrective osteotomy has been the mainstay of pediatric orthopedics and is often considered to be the definitive treatment. However, dissection may result in ugly scar and risk of infection. With high tibial osteotomy, lesser weight bearing impact on subchondral bone, decrease of intraosseous venous hypertension and micro-fractures involving subchondral bone and alleviation of clinical symptoms such as pain and consequently improvement in functional status of the patients are targeted. (9) Physeal manipulations using epiphysiodesis that could be permanent by ablation of one side of the physis or temporary using staple, transphyseal screw, or tension band plate.

Gradual correction using an external fixator and distraction osteogenesis which offers the advantage of accurate coronal, sagittal, and axial plane correction without significant soft tissue dissection. However its complications included intractable pin-site infection, superficial pin-site infection, delayed union, long duration of cumbersome fixation and transfixation of soft tissues. Corrective osteotomy is the gold standard for severe angular deformity, but is a major surgical intervention with operative site morbidity, postoperative pain and prolonged therapy that requires internal or external fixation and restricted weight-bearing that are the main drawbacks of this surgery. Osteotomies are high-risk surgeries with a small but significant incidence of compartment syndrome, neurovascular injury, and overcorrection or under correction, delayed union or nonunion (10).

If there is insufficient growth remaining (less than three years) or the child is skeletally mature and if the cause of the genu varum deformity is a disorder of the physis, hemiepiphysiodesis is unlikely to work. Corrective osteotomies will produce the desired improved alignment but need to be performed with prior deformity analysis. In younger children simple methods of fixation will suffice (crossed Kirschner wires and long leg casts) but in older children or adults more substantial implants or external fixators may be needed. (11)

In addition to this, the proposed percutaneous technique adds a lot of privileges to corrective osteotomy

1. Cosmetically accepted by the patients because it has the smallest incision compared to any fore mentioned technique and in our series there was one keloid formation.
2. Minimize the risk of infection. None of cases has report a wound infection.
3. Acute correction. Gradual correction cannot be certified to accomplish the required correction because many factors intervene.

- a. Severity of the deformity.
  - b. Number of years of remaining growth.
  - c. The state of the physis.
  - d. Focal lesions responsible for deformity.
  - e. Type of fixation used to perform temporary growth arrest.
  - f. The appropriate amount of distraction needed to promote correction without losing good bone contact.
4. No need for plate fixation. The impaction between metaphyseal segments has proved to be sufficient as long as there is preservation of intact periosteal sleeve and soft tissue. It has been reported 7 cases need percutaneous k-wire fixation as a supplementation due to obesity.
  5. No need for a staged operation to remove hardware.
  6. The correction could be tweaked under general anesthesia after primary healing (2-3 weeks) and cast reapplied.
  7. Preservation of soft tissue and periosteal sleeve enhance union and stability.
  8. The operation can be suitable at any age indicated for correction.

As regard Physal manipulations:

The Human Research Review Committee of the University Of New Mexico Health Sciences Center (51) approved a retrospective review of medical records and radiographs about all patients who had received hemiepiphyodesis about the knee for angular deformity from 2000 to 2007. There was no exclusion on the basis of diagnosis, age, bilaterally, comorbidities, or past surgical intervention. For staple hemiepiphyodesis, 3 staples were typically used per physis treated, but 2 were occasionally used in the particularly small child, per surgeon preference, one plate per physis was used in the 8-plate patients. Placement in distal femur, proximal tibia, or both was based on the location of primary deformity. (12).

During the study period, 81 hemiepiphyodesis were performed on 48 patients. Of these, 7 were lost to follow up before radiographic correction or skeletal maturity, 2 had no preoperative radiographs available for review and the outcome of one is still pending at the time of publication (79% follow-up). Sixty three hemiepiphyodesis performed on 38 patients were included in the study. The 8-plate was used in 24 knees and stainless steel staples were used in 39 knees. Patient demographics were similar with the exception of age, The average age at the time of hemiepiphyodesis was 12.6 years (range; 8.5 to 16.7) in the staple group and 11.1 years (range; 5.2 to 16.0) in the 8-plate group. Average time to final follow up was 16.2 months (range; 5 to 34) in the staple group and 14.1 months (range; 6 to 27) in the 8-plate group (P=0.53). The mean overall rate of correction for patients treated with staples was 9.9 degrees per year and in the 8-plate group was 11.1 degrees per year. The difference in mean rate of correction within the first year after surgery was not statistically significant at 11.0 degrees per year in the staple group and 12.2 degrees per year in the 8-plate group. (13).

According to Ballal M. S. et al. study there was a correspondingly large range in the time required for gradual correction; the mean was 16.1 months (7 to 37.3). The rate of correction was influenced by the physis treated and the age of the child. There was a mean rate of correction of 0.7° (0.3° to 1.5°) per month in the

distal femur, of  $0.5^{\circ}$  ( $0.1^{\circ}$  to  $1.0^{\circ}$ ) per month in the proximal tibia and of  $1.2^{\circ}$  ( $0.1^{\circ}$  to  $2.2^{\circ}$ ) per month if femur and tibia were treated concurrently. (13).

When the sample was divided into two groups to reflect an approximate age of onset of puberty, the overall rate of correction for children under the age of 10 years was  $1.4^{\circ}$  per month, compared with  $0.6^{\circ}$  per month for the older children. With high tibial osteotomy, lesser weight bearing impact on subchondral bone, decrease of intraosseous venous hypertension and micro-fractures involving subchondral bone and alleviation of clinical symptoms such as pain and consequently improvement in functional status of the patients are targeted. (9)

Akamatsu et al. (14) in their series consisting 144 knees, detected that mineral densities and sclerosis of medial femoral condyles and tibial bone plateau are denser than those of the lateral compartment. They performed high tibial osteotomies for 23 patients and stated that the degree of bone mineral density and sclerosis decreased by distributing mechanical stress evenly and diminishing weight-bearing forces impinging on medial compartment. It is believed that the patients with isolated medial compartment arthrosis must be managed surgically and high tibial osteotomy is one of the surgical alternatives for these patients.

Since the reports of Debeyre (15) on open -wedge medial osteotomy published in 1951, both the technique and the implants used have undergone considerable modifications. In medial open-wedge osteotomy, fibular osteotomy is not performed, the ability to achieve predictable correction in both coronal and sagittal planes, the ability to adjust correction intraoperative, the requirement for only one bone cut, avoidance of proximal tibiofibular joint disruption and invasion of the lateral compartment and peroneal nerve injury, technique does not require a wide exposure, a stable fixation can be accomplished with a Puddu plate without loss of correction, and the relative ease of combining with other procedures such as ACL reconstruction. (15)

The disadvantages of this procedure include the creation of a defect that requires bone graft ( if the planned wedge  $> 10$  mm ) with attendant harvest morbidity, and theoretically higher risk of non-union, as well as the longer period of restricted weight bearing postoperatively (16). The clinical goals of osteotomy are pain relief, functional improvement, allowance of heavy functional demands, and extension of the functional life of the natural knee (17). The surgical goal is to transfer the weight-bearing forces from the arthritic portion of the knee to a healthier part of the joint (18).

To obtain successful results in HTO not only requires the application of a good surgical technique but also depends on appropriate patient selection. The factors which will increase the rate of success obtained from high tibial osteotomy using Puddu plate with graft procedures include presence of isolated medial compartment arthrosis, good patient compliance for the postoperative rehabilitation program, patients aged  $< 60$  years, absence of knee contractures and excessive patellofemoral arthrosis, range of motion being at least 90 to 100 degrees, varus angle  $< 20$  degrees, stable knees and the usage of rigid fixation material for osteosynthesis. (19)

Hernigou et al. (20) followed 93 cases with genu varum that had undergone open-wedge osteotomies for a median of 11.5 years and reported that the results obtained were satisfactory up to 7 years postoperatively. Several studies report that younger patients respond better and longer to realignment osteotomy, although others did not show a clear relationship between age of the patient and results of the osteotomy, nowadays chronological age is not accepted as a criterion for eligibility. Bone texture, daily activity level and biological age have a greater impact on selection criteria (21). In our study 4 patients with ages (50 – 55) were operated and there was improvement as regard knee pain and alignment (about 9 weeks).

Most authors recommend overcorrection (2-4 degrees) in HTO in middle-aged patients, to effectively unload the medial compartment. It was found that these patients did not have poor results. (22, 23) Coventry et al. (24) stated that they had obtained successful results in varus or neutral (64%) and in 4\_6 degrees valgus (94%) positions. In a study by Hernigou et al. (25) arthrosis did not deteriorate in patients maintained in 3-6 valgus position. Bombaci and colleagues. (26) showed that the tibio-femoral range of motion decreased by 5\_10 degrees in some knees post-operatively. Most of these patients complain of pain or limitation of the patella-femoral joint was observed. They also showed that the posterior tibial slope had a significant increase of 3.5 degrees.

In our study, the knee range of motion and posterior tibial slope were not affected and none of the patients complained of major symptoms related to the patello-femoral joint. One of the most important complications reported for either closed or open wedge osteotomies is patella infra or alta. Concerns regarding patellar height have been raised by some like Wright (27), while denied by others like Weidenhielm (28). Based on Insall-salvati index we did not find neither patella infra nor patella alta in our patient group.

Spahn (29), reported a complication rate as high as 43.6% related to the use of Puddu plate. These included implant failure (16.4%), fractures of lateral tibial plateau (14.6%). Infection (7.3 %), hematoma (3.6%), and deep venous thrombosis (1.8%). They recommended immediate revision in case of infection. Other complications include neurological injury (mainly; peroneal nerve palsy), and non-union of the osteotomy. In our study there was no metal failure but 2 cases were undercorrected as the patient missed the first 2 visits after operation but the patients were satisfied by the results as regard deformity. One patient had recurrence of the deformity as she stopped the medication for hyperparathyroidism. One patient had failure of correction and collapse revised by ilizarov.

As regard the infection no cases were found to be infected only one case showed skin maceration due to water spilled on cast and managed by repeated dressing. Also there was no DVT reported as the patients walk as tolerated from the second day postoperative. There was no neurovascular complication and union rate was good but 4 cases took 9 weeks to be fully united due to delayed weight bearing, over weight and large angle that create large wedge. One case showed loosening of union due to early heavy exercise and managed by re casting.

The use of the gradual correction by external fixation allowed mini-open osteotomy with surgical wound less than 3 cm. This could minimize the wound problems and postoperative hematoma and soft tissue dissection that are always of great concern for acute correction with internal fixation. Accuracy of correction is an important determinant for the postoperative results and the longevity of pain relief. Many techniques were used to assess the correction intraoperative such as visual inspection and cable method. All techniques of intraoperative assessment of the lower limb mechanical axis ignore the effect of weight bearing on the mechanical axis. Gradual correction by external fixation decreases the intraoperative difficulty, as it enables accurate correction postoperatively. It considers the effect of weight bearing on the mechanical axis as the radiographs were taken as standing full-length radiographs (30).

But the major disadvantages of the methods done with an Ilizarov apparatus include a long learning curve for the surgeon, wire and pin tract infections, patient's discomfort of having to cope with a bulky circular ring fixator and the potential risk of introducing deep infection (30). Ohsawa et al., 2006, revealed that fracture of the lateral cortex of the tibia was one of the serious problems in the hemicallotasis method, because this method required an intact lateral cortex as a fulcrum. When the lateral cortex was fractured, the proximal fragment was displaced and bone healing was delayed. They performed osteotomies on 44 patients; 10 with fracture of the tibial lateral cortex and displacement of the proximal fragment and 34 with no fracture. They demonstrated that when transposition of the proximal fragment occurred, the mean FTA at pin removal (169°) had a correction loss at 1 year after surgery (171°) and at the final follow-up (171°) (31) .

Ctagni et al. 1994 reported that HTO using many pins and wires was complicated by infection, up to 10% of cases. (32) Bachhal et al., 2011, reported 16.4 % infection rate of all pins used in their series of 32 patients (37 knees) who underwent hemicallotasis deformity correction done by using a dynamic uni-axial external fixator. They described pin tract infections, delayed union in two, knee stiffness in four, fracture of the lateral cortex in one, and ring sequestrum in one. (32)

## **Conclusion**

Corrective osteotomy is the gold standard for severe angular deformity, but is a major surgical intervention with operative site morbidity, postoperative pain and prolonged therapy that requires internal or external fixation and restricted weight-bearing that are the main drawbacks of this surgery. The use of percutaneous osteotomy can fulfill its role for correction without exposure to the hazards associated with the standard technique. The percutaneous technique provides the privileges of acute correction without the need for dissection and the ability to modify the correction under general anesthesia with appropriate follow up.

## **References**

1. Espandar R, Mortazavi SM-J, Baghdadi T. Angular Deformities of the Lower

- Limb in Children. *Asian J Sports Med.* 2010;1(1):46-53. <http://www.ncbi.nlm.nih.gov/pmc/articles/PMC3289162/>.
2. Stevens PM. Guided growth: 1933 to the present. *Strateg Trauma Limb Reconstr.* 2006;1(1):29-35. doi:10.1007/s11751-006-0003-3.
  3. Celestre PC, Bowen RE. Correction of angular deformities in children. *Curr Orthop Pract.* 2009;20(6):641-647. [http://journals.lww.com/c-orthopaedicpractice/Fulltext/2009/11000/Correction\\_of\\_angular\\_deformities\\_in\\_children.12.aspx](http://journals.lww.com/c-orthopaedicpractice/Fulltext/2009/11000/Correction_of_angular_deformities_in_children.12.aspx).
  4. Stevens PM. Guided Growth for Deformity Correction. *Oper Tech Orthop.* 2011;21(2):197-202. doi:https://doi.org/10.1053/j.oto.2011.01.003.
  5. Franco V, Cipolla M, Gerullo G, Gianni E, Puddu G. Open wedge osteotomy of the distal femur in the valgus knee. *Orthopäde.* 2004;33(2):185-192. doi:10.1007/s00132-003-0597-9.
  6. Paley D. Principles of Deformity Correction. Berlin, Heidelberg: Springer Berlin Heidelberg; 2002. doi:10.1007/978-3-642-59373-4.
  7. Outerbridge RE. The etiology of chondromalacia patellae. 1961. *Clin Orthop Relat Res.* 2001;(389):5-8. <http://www.ncbi.nlm.nih.gov/pubmed/11501822>. Accessed December 2, 2017.
  8. Saran N, Rathjen KE. Guided growth for the correction of pediatric lower limb angular deformity. *J Am Acad Orthop Surg.* 2010;18(9):528-536.
  9. Kharrazi D, Chandler RW, Spitzer AI. High tibial osteotomy for the treatment of unicompartmental arthritis of the knee. *Curr Opin Orthop.* 2000; 11:26-34.
  10. Goldman V, Green DW. Advances in growth plate modulation for lower extremity malalignment (knock knees and bow legs). *Curr Opin Pediatr.* 2010;22(1):47-53. doi:10.1097/MOP.0b013e328334a600.
  11. Joseph B (Professor of orthopaedics). *Paediatric Orthopaedics: A System of Decision-Making.* Hodder Arnold; 2009.
  12. Wiemann JM, Tryon C, Szalay EA. Physeal Stapling Versus 8-plate Hemiepiphyodesis for Guided Correction of Angular Deformity about the Knee. *J Pediatr Orthop.* 2009;29(5):481-485. doi:10.1097/BPO.0b013e3181aa24a8.
  13. Ballal MS, Bruce CE, Nayagam S. Correcting genu varum and genu valgum in children by guided growth: TEMPORARY HEMIEPIPHYODESIS USING TENSION BAND PLATES. *J Bone Jt Surg - Br Vol.* 2010;92-B(2):273-276. doi:10.1302/0301-620X.92B2.22937.
  14. Akamatsu Y, Koshino T, Saito T, Wada J. Changes in osteosclerosis of the osteoarthritic knee after high tibial osteotomy. *Clin Orthop.* 1997; 334:207-214
  15. Debeyre J and Artigou JM. (1972) Long-term results of 260 tibial osteotomies for frontal deviations of the knee. *Rev Chir Orthop ReparatriceApparMot*58:335-339.
  16. Amendola A and Bonasia DE. Results of high tibial osteotomy: Review Of The Literature. *Int Orthop.* 2010; 34:155-160.
  17. Flamme CH, Ruhmann O, Schmolke S. Long-term outcome following high tibial osteotomy with tension bend principle. *Arch Orthop Trauma Surg.* 2003; 123:12-16.
  18. Strecker W. Planning analysis of knee-adjacent deformities. I. Frontal plane deformities. *Oper Orthop Traumatol.* 2006; 18:259- 272.

19. Lobenhoffer P and Agneskirchner JD. Improvements in surgical technique of valgus high tibial osteotomy. *Knee Surg Sports Traumatol Arthrosc.* 2003; 11:132–8.
20. Hernigou P. A 20-year follow-up study of internal gonarthrosis after tibial valgus osteotomy. Single versus repeated osteotomy. *Rev Chir Orthop Reparatrice Appar Mot.* 1997; 82:241–250.
21. Naudie DD, Amendola A, Fowler PJ. Opening wedge high tibial osteotomy for symptomatic hyperextension-varus thrust. *Am J Sports Med.* 2004; 32: 60–70.
22. Hanssen AD, Stuart MJ, Scott RD, et al. Surgical options for the middle-aged patient with osteoarthritis of the knee joint. *Instr Course Lect.* 2001; 50:499–511.
23. Sprenger TR, Doerzbacher JF. Tibial osteotomy for the treatment of varus gonarthrosis. Survival and failure analysis to twenty-two years. *J Bone Joint Surg.* 2003; 85:469–474.
24. Coventry MB, Ilstrup DM, Walrichs SL. Proximal tibial osteotomy. A critical long-term follow-up study of eighty-seven cases. *J Bone Joint Surg (Am).* 1993; 75(2):196–201.
25. Hernigou P, Medevielle D, Debeyre J, Goutallier D. Proximal tibial osteotomy for osteoarthritis with varus deformity: a ten to thirteen-year follow-up study. *J Bone Joint Surg Am* 1987; 69:332–54.
26. Bombaci H, Canbora K, Onur G, et al. The effect of open wedge osteotomy on the posterior tibial slope. *Acta Orthop Traumatol Turc.* 2005; 39:404–410.
27. Wright JM, Heavrin B, Begg M, et al. Observations on patellar height following opening-wedge proximal tibial osteotomy. *Am J Knee Surg.* 2001; 14:163–173.
28. Weidenhielm L, Wykman A, Lundberg A, et al. Knee motion after tibial osteotomy for arthrosis. Kinematic analysis of 7 patients. *Acta Orthop Scand.* 1993; 64:317–319.
29. Spahn G. Complications in high tibial (medial openingwedge) osteotomy. *Arch Orthop Trauma Surg.* 2004; 124:649–653
30. Young Eun Park , Sang Heon Song , Hyeok Nam Kwon , Mohamed Ahmed Refai , Kwang Won Park , Hae Ryong Song . Gradual correction of idiopathic genu varum deformity using the Ilizarov technique . *Knee Surg Sports Traumatol Arthrosc* (2013) 21:1523–1529 .
31. Ohsawa S, Hukuda K, Inamori Y, Yasui N. High tibial osteotomy for osteoarthritis of the knee with varus deformity utilizing the hemicallotaxis method. *Archives of Orthopaedic and Trauma Surgery* 2006; 126 (9): 588–593.
32. Catagni MA, Guerreschi F, Ahmad TS, Cattaneo R. Treatment of genu varum in medial compartment osteoarthritis of the knee using the Ilizarov method. *Orthop Clin North Am.* 1994; 25 (3): 509–514.
33. Bachhal V, Sankhala SS, Jindal N, Dhillon MS. High tibial osteotomy with a dynamic axial fixator: precision in achieving alignment. *J Bone Joint Surg Br.* 2011; 93 (7): 897–903.