

How to Cite:

Singh, N., Kaur, S., & Sharma, V. K. (2021). Pre and post operative orthodontics in orthognathic surgery: A review. *International Journal of Health Sciences*, 5(S2), 156–168. <https://doi.org/10.53730/ijhs.v5nS2.5627>

Pre and post operative orthodontics in orthognathic surgery: A review

Navpreet Singh

PG student (3rd year), department of Orthodontics & Dentofacial Orthopaedics, Desh Bhagat dental college & hospital, Mandi Gobindgarh, India

Sukhpal Kaur

Professor, Department of Orthodontics & Dentofacial Orthopaedics, Desh Bhagat Dental College & Hospital, Desh Bhagat University, Mandi Gobindgarh, India

Vishal Kumar Sharma

Senior Lecturer, Department of Orthodontics & Dentofacial Orthopaedics, Desh Bhagat Dental College & Hospital, Desh Bhagat University, Mandi Gobindgarh, India

Abstract---In the early 21st century, orthodontics differs from what was done previously. There is more emphasis now on dental and facial appearance reflecting awareness that parents and patients seek treatment largely because of concern about facial appearance and those psychosocial problems related to appearance. Second, patients now expect and are granted a greater degree of involvement in planning treatment. Last, Orthodontics now is offered much more frequently to older patients as part of a multidisciplinary treatment plan involving other dental and medical specialties. Orthognathic Surgery is mostly performed to correct developmental or acquired oral and maxillofacial skeletal deformities. The type of tooth movement and mechanics required for Orthognathic surgery is oftentimes different to standard Orthodontics. It is imperative that the treating Orthodontist is conversant with the principles and technical mechanical requirements in the management of the Orthognathic patient.

Keywords---orthognathic patient, skeletal deformities.


Introduction

Edward H. Angle defined Orthodontics as “Science which has for its object the correction of malocclusion of teeth”. He stated that if diagnosis of a case is thoroughly mastered, the line of treatment and the appliance necessary to bring

about various tooth movements is clearly indicated. The key to ideal occlusion is relative position of first molars¹. Similarly, Salzmann in 1950, classified underlying skeletal structure, he stated that Skeletal Class I: Purely dental with the bones of face and jaws being in harmony with one another and with the rest of the head. The profile is orthognathic (Straight). Skeletal Class II: Distal mandibular development in relation to the maxilla. The profile is prognathic (Convex). Skeletal Class III: overgrowth of the mandible with obtuse mandibular angle. The profile is retrognathic (Concave).²

However, in the early 21st century, orthodontics differs from what was done previously in three important ways. First, there is more emphasis now on dental and facial appearance. This reflects a greater awareness that parents and patients seek treatment largely because of concern about facial appearance and those psychosocial problems related to appearance. Second, patients now expect and are granted a greater degree of involvement in planning treatment. Last, Orthodontics now is offered much more frequently to older patients as part of a multidisciplinary treatment plan involving other dental and medical specialties. The goal is not necessarily the best possible dental occlusion or facial aesthetics but the best chances of long-term maintenance of the dentition.³

The term dentofacial deformity refers to significant deviations from normal proportions of the maxilla-mandibular complex that also negatively affect the relationship of the teeth within each arch and the relationship of the arches with one another (occlusion)⁴. Three kinds of treatment are available when malocclusion is caused by severe skeletal discrepancies: Growth modification, Orthodontic Camouflage, Orthognathic Surgery. In growing children, Dentofacial Orthopaedics can alter the expression of growth to some extent. The patients with mild skeletal discrepancy are benefited from Orthodontic camouflage and not surgery. Combined Orthodontic and surgical correction are considered as the best treatment modalities for dentoskeletal imbalances once growth has ceased⁵. It is possible now to be at least semi-quantitative about the limits of orthodontic treatment, in the context of producing normal occlusion.



Orthognathic surgery may be defined as “The surgical repositioning of the maxilla and/or mandible, and/or their segments thereof, with or without Orthodontic

repositioning of the teeth, to improve dentofacial function and aesthetics (in a stable manner) and health-related quality of life". The term 'Orthognathic' is derived from the Greek 'Orthos': correct or straight, and 'gnathos': jaw ⁶. Orthognathic Surgery is mostly performed to correct developmental or acquired oral and maxillofacial skeletal deformities. During past decades, several advances in surgical osteotomy techniques and instrumentation have been developed and carried out in Orthognathic surgery. However, the basic surgical principles have remained unchanged. Osteotomies of jaw must be performed in a safe way and preferably intraorally to avoid scars on the face and at the same time provide adequate exposure to the skeleton.⁷

The essence of treatment planning in Orthognathic surgery is to build a coherent picture of where you are, where you want to get to, and how you are going to get there, albeit allowing for contingencies. Orthognathic surgical procedures should be planned to maximize smile aesthetics. Optimal smile aesthetics can be achieved within a range of normal values. The type of tooth movement and mechanics required for Orthognathic surgery is oftentimes different to standard Orthodontics. It is imperative that the treating Orthodontist is conversant with the principles and technical mechanical requirements in the management of the Orthognathic patient. Surgeons should also have a working knowledge of modern Orthodontics and what is realistically achievable.

Treatment objectives in Orthognathic surgery

Three objectives are fundamentals in Orthognathic surgery:

- a) Function b) Esthetics c) Stability

Function

Functional and esthetic deformities often exist concurrently; when they do, treatment should be designed to correct both. The treatment of patients with poor function but good esthetics is particularly challenging. In most patients improved function is an important motivator, and in some patients, it is the primary motivator. Some of the functional problems that patient may present with: incising food, mastication, deglutition, trauma, biting to tongue, traumatic occlusion, attrition, respiration and sleep apnoea, temporo-mandibular joint dysfunction, speech, drooling.

Esthetics

Facial appearance is often the patient's main concern. It is the patient's perception of what is esthetically wrong that is paramount, and first task of clinician is to establish patient's esthetic concern. The Orthodontic placement of teeth dictates surgical movement and ultimately, facial changes, the clinician may carefully assess patients with musculoskeletal deformities before Orthodontic treatment is begun.

Stability

Without stability, the achievement of good function and pleasing esthetics is obviously not acceptable. Certain Orthodontic tooth movements have questionable stability. Occlusal stability at any moment is the result of sum of all the forces acting against the teeth.⁵

Pre-Operative and Post-Operative Orthodontics

Treatment time for the patient undergoing orthognathic surgery is prolonged. However, attempts by the orthodontist to cut corners to reduce treatment time, or by the surgeon to undertake surgery without adequate preoperative orthodontic preparation, will inevitably lead to problems, for the patient and the clinicians. Clearly, time should not be wasted by the orthodontist in the preparatory phase of preoperative orthodontics, but accuracy in placing the teeth of both arches into the desired positions far outweighs the speed of treatment and may well reduce the overall treatment time by reducing the length of postoperative orthodontics.

The five stages of orthodontic treatment required for the patient undergoing orthognathic surgery are:

- Preoperative orthodontics.
- Immediate preoperative appointment.
- Intraoperative orthodontic requirements.
- Immediate postoperative appointment.
- Postoperative orthodontics.

Preoperative orthodontics

The amount of preparatory orthodontic treatment required for the orthognathic patient is quite variable. It depends on the complexity of tooth movements required and the type of surgery being planned.

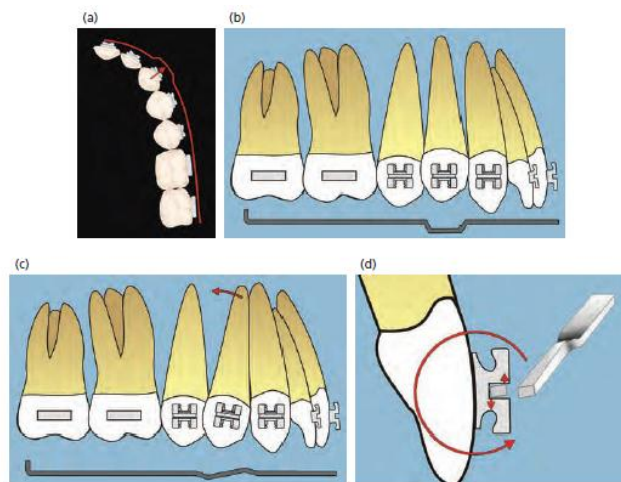
Types of orthodontic appliance

The type of appliance used is essentially down to the preference of the orthodontist, though usually some form of preadjusted edgewise appliance is likely to be employed. The fixed orthodontic appliance is not only employed to achieve the desired tooth movements before and after surgery, but is also used by the surgeon to stabilize the jaws intraoperatively with intermaxillary fixation (IMF).

Preadjusted edgewise appliance

The former standard edgewise appliance employed relatively similar brackets on the teeth, and thereby required the orthodontist to place bends in the archwire to individually position each tooth in terms of their relative horizontal 'in-out' positions, their crown angulation (mesiodistal crown 'tip') and crown inclination (buccolingual crown 'torque'). This prepared archwire then engaged the brackets in an 'edgewise' manner, hence the name. In the mid-1970s, the American orthodontist Lawrence F. Andrews^{8,9} introduced the 'Straight-wire appliance',

which modified the standard edgewise system such that the information for the in-out position of each tooth, its crown tip and crown torque was incorporated into the respective bracket for each individual tooth, i.e., the details of the final tooth position is incorporated in each 'preadjusted' bracket. This was achieved by varying the thickness of each bracket base (for the in-out position of the respective tooth), and by varying the angulation of each bracket slot relative to the long axis of each tooth in the mesiodistal plane (for the crown angulation) and contouring the base of the bracket occluso-lingually (for the crown inclination). These preadjusted bracket systems have reduced the requirement for wire bending dramatically. Nevertheless, accurate tooth positioning in preparation for surgery and effective postoperative finishing and detailing of tooth positions will almost always require some degree of wire bending.



First, Second and Third Order Bends

Bracket slot size

In this context, the bracket slot size refers to the dimensions of the horizontal channel within a bracket that receives the orthodontic archwire. The most used bracket slot sizes are the 0.018 × 0.025-inch (0.46 × 0.64 mm) and the larger 0.022 × 0.028-inch (0.56 × 0.7 mm). The type used is dependent on the preference of the orthodontist, but the 0.022 × 0.028-inch bracket slot does allow use of heavier stainless steel arch wires, which make dental arch levelling potentially easier.

Banding vs. bonding of molar teeth

In modern orthodontics, bonded brackets are the norm for all the teeth, although molar bands are occasionally used, particularly when trans-palatal arches or tooth borne rapid maxillary expanders are required. Some surgeons prefer the molar teeth to be banded, particularly the final tooth in each arch, which is usually the second molar. The reasoning is that should this tooth be bonded rather than banded, and thereby de-bond during surgery, it may be a potential

problem. Alternatively, it may be argued that a loose band may not be noticed for some time.

Molar bands are also required if a band tube needs to be converted into a bracket, e.g., if a maxillary second molar tooth needs to be buccally offset or individually intruded, an archwire with the appropriate bend will not pass through a normal buccal tube on either a molar band or bonded buccal tube on the maxillary first molar. A second, or auxiliary, archwire tube can be incorporated into a molar bond or band. This is useful in cases requiring segmental surgery, if an auxiliary wire needs to be constructed for placement into the auxiliary tubes to stabilize the segments immediately after segmental repositioning. The use of lingual and palatal cleats on molar bands for attachment of elastics may be required in either the preoperative or postoperative phases; however, where bonded molar tubes have been used rather than molar bands, lingual or palatal buttons may be bonded directly onto the teeth if required.

Labial vs. Lingual appliance

Labial orthodontic appliances are superior to lingual appliances in orthognathic patients for a number of reasons:

- Intraoperative IMF placement – Lingual appliances cannot be used by the surgeon intraoperatively for application of temporary intermaxillary fixation, and some form of labial attachment will be required.
- Debonding brackets – If a lingual bracket de-bonds during or immediately after surgery, it is very difficult to rebond in the immediate postoperative period, as the patient has discomfort, an inevitable degree of trismus leading to limited mouth opening, and often a mouth laden with blood-stained saliva.
- Postoperative oral hygiene – The same factors may potentially make it more difficult for the patient to keep the teeth and appliances clean if the brackets are lingual.
- Anterior open bites – An upper lingual appliance may also interfere with complete overbite correction in anterior open bite cases.

Use of aesthetic brackets

Some patients may demand labial ‘aesthetic’ brackets, in which case informed consent is essential. However, routine stainless-steel brackets and bands/tubes are superior to aesthetic labial brackets in patients undergoing orthognathic surgery, for a number of reasons:

- Susceptibility to fracture – Ceramic brackets are brittle and thereby vulnerable to fracture intraoperatively, particularly during placement of IMF. They also often shatter into pieces, in which case parts may potentially enter open surgical sites.
- Tooth wear – Ceramic brackets may also lead to serious tooth wear from abrasion with the enamel of teeth in the opposing arch, which may be a serious problem in orthognathic patients at the start of treatment due to the variety of presenting malocclusions, particularly deep bites, and may also

become a problem during the preoperative period as the teeth align and decompensate.

- Plastic or resin composite type brackets – These are often difficult to see and may impede or reduce tooth movement due to problems of increased friction. They are also usually rather weak, and prone to fracture, which is again an intraoperative problem for which the surgeon will not be thankful.

Objectives of preoperative orthodontics⁶

The aspiration of the orthodontist and overall purpose of preoperative orthodontic treatment is to place the teeth into the correct position for their respective jaw, so that on repositioning the jaws, the surgeon may attain the desired skeletal movements and obtain the best possible dental occlusion. The preparatory orthodontic tooth movements should be determined in relation to the proposed surgical movements of the jaws. The intended tooth movements may be described in relation to the six objectives of preparatory preoperative orthodontic treatment:

- Alignment
- Levelling
- Decompensation
- Incisor inclination preparation
- Arch coordination
- Elimination of occlusal interferences.

There is a seventh objective if segmental surgery is required:

- Creating interdental space for osteotomy cuts.

Alignment

Alignment is usually, though not always, the first step in preoperative orthodontics (arch expansion is sometimes undertaken prior to alignment). Some arch levelling also begins at the same time as alignment, i.e., when the initial archwire is engaged into the brackets the teeth will begin to level. The purpose of alignment is to correctly angulate ('tip') the crowns of the teeth into the correct position for their respective jaw and to correct tooth rotations.

- Bracket positioning – The brackets must be bonded into the correct position for each tooth. Time taken to accurately position the brackets at this stage is never wasted. Minor variations in bracket positioning may be required in some orthognathic patients:
- Maxillary canines – In orthognathic patients, the coordination of the maxillary and mandibular labial segments, i.e., the canine-to-canine region, is paramount. Often, interference may occur between the tip of the mandibular canine and the mesio-palatal aspect of the maxillary canine, which prevents the intercuspation of the teeth. Therefore, it is advisable to bond the maxillary canine bracket approximately 1/2 to 3/4 of a millimeter mesial to the long axis of the tooth, leading to slight mesio-labial rotation of the tooth, and better ultimate interdigitation of the labial segment.

- In-standing maxillary lateral incisors – Inverting the brackets provides labial/buccal root torque when the patient eventually has rectangular arch wires placed, helping to prevent the ‘proclined’ appearance of the lateral incisor crown, which is a common problem in such cases.
- Maxillary second molars – In many instances, these teeth should not be bonded, in order to prevent their extrusion, which will become a major interference in attempting arch coordination. If they must be bonded/banded, e.g., to de-rotate, then care should be taken to bonding the brackets somewhat occlusally. If a convertible tube is placed onto the first molar, steps can be added to an archwire to also minimize extrusion of the second molar.
- Segmental surgery – In preparation for segmental surgery, some interdental space is required, both between the crowns and roots of the teeth on either side of the planned osteotomy, to permit space for the surgical cuts without damaging the teeth. The crowns of the teeth on either side of the planned osteotomy may be separated using active coil spring, but root divergence may be achieved by either having the brackets in the correct positions and placing second-order bends in the archwire, or bonding the brackets at an angle to diverge the roots, and rebonding them in the correct position postoperatively.

Archwire size, shape and material

A thin, round archwire is ideal for initial alignment, producing little binding and friction, and permitting relatively free tipping of the tooth crowns. The forces should be as light as possible, whilst permitting tooth movement. Nickel-titanium alloy (NiTi) is the initial aligning archwire material of choice, having both shape memory (i.e., it returns to its original form following plastic deformation, e.g., being ligated to a malpositioned tooth) and superelasticity (i.e., a flat ‘superelastic’ plateau in the middle of the force deflection curve, allowing appreciable distortion of the wire in order to engage brackets on considerably displaced teeth whilst maintaining acceptable force levels). The preliminary archwire is usually a round 0.014-inch, followed by a 0.016-inch NiTi or 0.018-inch copper NiTi after 1 to 2 visits of re-ligation.

Levelling

Dental arch levelling refers to the stage of orthodontic treatment which aims to flatten (or almost flatten) the curve of Spee, by permitting the relative vertical movement of the teeth in each arch to bring their marginal ridges to lie approximately in the same horizontal plane. A relatively flat (i.e., ‘level’) curve of Spee is one of the prerequisites to a normal dental occlusion. In the orthognathic patient, levelling may be undertaken at different stages of treatment, depending on the requirements of the respective case:

- Preoperatively – In the majority of patients most or all the levelling may be undertaken prior to surgery.
- Intraoperatively – The preoperative phase is used to segmentally align ‘segments’ of each dental arch and the segments are subsequently surgically levelled.

- Postoperatively – Some or most of the levelling is undertaken following surgery, e.g., a 3-point landing.

In the preoperative phase of treatment, the levelling of each individual dental arch may be total, partial or segmental.

- Total continuous arch levelling – In most cases, total arch levelling will occur as the orthodontist moves through the archwire sequence into the flat, heavy rectangular stainless steel arch wires. These will lead to extrusion of premolar and canine teeth, and intrusion of incisor and to a small extent terminal molar tooth, though the extrusive effect is always greater.
- Partial continuous arch levelling – e.g., maintenance of a degree of curve of Spee in preparation for a 3-point landing. An increased curve will need to be 'wiped' into the mandibular steel archwire to maintain or accentuate the curve of Spee preoperatively.
- Segmental arch levelling – For a patient being prepared for segmental surgery requiring levelling, the differential vertical movements required for each segment will depend on aesthetic and occlusal factors. In such cases the segments are aligned and levelled intra-segmentally, avoiding continuous initial aligning arch wires.

Decompensation

The discrepancy between the jaws in all three planes of space has an indirect yet considerable influence on the dental occlusal relationship as a result of dentoalveolar compensation. Dentoalveolar compensation describes the variations in the positions of the teeth, in the sagittal, vertical and transverse dimensions, that may compensate for variations in the skeletal pattern, i.e., it is nature's way of trying to get the teeth to meet when the jaws are growing away from one another. In the normal situation, the erupting maxillary and mandibular teeth are guided towards each other by the surrounding soft tissue envelope of the tongue, lips and cheeks; hence, they erupt into a position of soft tissue equilibrium between the opposing forces of the tongue and lips/cheeks. Therefore, in the presence of sagittal or transverse skeletal discrepancies, alterations in the inclination of the teeth compensate for the skeletal discrepancy. In such cases, the occlusal discrepancy will appear less severe than the underlying skeletal discrepancy.

Orthodontic preparation for orthognathic surgery requires orthodontic decompensation of the dental arches in all three planes of space, i.e., the process of removing the dentoalveolar compensations that may be present in the sagittal, transverse and vertical planes, and re-establishing the correct position of the teeth with regard to their own skeletal base thereby permitting adequate surgical correction of skeletal discrepancies. Total vs. partial decompensation – Total decompensation is usually required, in order to position the teeth correctly in relation to their respective skeletal base. However, in some situations, it may be prudent to partially decompensate only, in order to reduce the extent of skeletal movements required where stability and relapse would be issues postoperatively.

'Worsening' effect on dental occlusion and facial profile – Just as dentoalveolar compensation tends to mask the extent of the underlying skeletal discrepancy, orthodontic decompensation unmasks/unveils the true extent of the underlying skeletal discrepancy.

Incisor inclination preparation

The orthodontic treatment required to prepare the maxillary and mandibular incisor inclinations for surgery often occurs as part of incisor decompensation. Incisor inclination preparation for orthognathic surgery depends on whether surgery is being planned for a jaw, and whether that surgery involves rotation of the jaw round the transverse axis. If surgery is not being planned, then the incisor inclination for that jaw should be corrected prior to surgery, e.g. proclined maxillary incisors should be corrected preoperatively when only mandibular advancement surgery is being planned.

Arch coordination

Of all the parameters that must be dealt with in orthodontic preparation, the coordination of the maxillary arch with the mandibular arch is often the most important, commonly the most challenging, and usually the most likely to cause problems at the time of surgery and in the postoperative phase of treatment. Ideally, the dental arches should be as well coordinated as possible prior to surgery. However, in some patients, if the occlusion is so well-interdigitated as to make expansion difficult, particularly in low angle patients, glass ionomer cement blocks may be placed on the occlusal surface of the maxillary first or second molars to disclude the arches, and permit easier expansion. Conversely, some of the posterior buccal segment expansion (perhaps 3–4 mm, i.e., no more than 2 mm per side) may be completed postoperatively. However, the coordination of the canine-to-canine region of the maxilla to that of the mandible is the single most important preparatory requirement of preoperative orthodontics. Good preoperative coordination of this region is mandatory. The aims of preparatory orthodontic treatment in relation to arch coordination are twofold:

- To expand or contract the maxillary and mandibular dental arches as required, so they will adequately conform to one another at the time of surgery; and
- To prevent undesirable expansion or contraction in either arch.

Elimination of occlusal interferences


Planning to prevent occlusal interferences begins before a single bracket is bonded. Additionally, during treatment the dental arches should be checked at every visit, in order to continue preventing the formation of potential interferences, and eliminating them when they occur. It is vitally important to check the patient's individual dental arches and their occlusion with keen observation and with interim 'snap models' when required, in order to detect potential occlusal interferences. The most common potential interferences in orthognathic patients are the following:

- Coordination of inter-canine width
- Extrusion of maxillary second molars
- Buccal flaring of maxillary molars
- Avoidance of premolar extrusion
- Overeruption

Immediate preoperative appointment

This appointment should be ideally no more than 2–3 weeks prior to the date of the operation. The purpose of this appointment is:

- Checking brackets and bands – It is important to ensure that the brackets and bands are all secure.
- Ligate brackets with stainless steel ligatures – All the brackets should be tied securely with stainless steel ligatures.
- Placement of surgical hooks – A few bracket systems have integrated hooks on some or all of the brackets. These are primarily for the use of the orthodontist in placement of elastics and should be avoided by the surgeon intraoperatively while placing wire intermaxillary fixation, as this may de-bond the respective bracket.
- Kobayashi ligatures – These specific ligatures are fabricated from either 0.012-inch (0.3 mm) or 0.014-inch (0.35 mm) annealed stainless steel wire, with the legs welded onto one another forming a helical hook at the end.



Immediate Pre-Operative Orthodontics

Intraoperative orthodontic requirements

Surgical finesse is vital, and excessive surgical force in placement of intermaxillary fixation may de-bond brackets. Nevertheless, de-bonds do occur intraoperatively, and can usually be ignored and repaired by the orthodontist postoperatively. However, if a band which is part of an RME appliance becomes loose, it may need to be repaired intraoperatively. Additionally, in segmental surgery, continuous arch wires may need to be placed intraoperatively, or over tied to the segmented arch wires, once the jaw has been surgically segmented and repositioned.

Immediate postoperative appointment

The patient should be seen by the orthodontist, together with the surgeon, on the day following surgery. It is important for patients to be mobilized as soon as possible following surgery. The main purpose of this appointment is to check that the skeletal and dental-occlusal aims of the surgery have been achieved.

The patient is then sent for postoperative radiographs prior to returning for placement of intermaxillary guiding elastics as required. The patient should have an Orthopantomograph (OPG) and possibly a lateral cephalometric radiograph taken and critically compared with the preoperative radiographs.

Postoperative orthodontics

Whether the wafer is removed early or not, active orthodontic treatment is usually delayed for 2 weeks, until the patient feels up to having treatment. During this time the patient will usually be wearing light intermaxillary guiding elastics, which help to guide the patient into the planned dental occlusion. If full thickness stainless steel arch wires had been placed prior to surgery, i.e., 0.0215 × 0.025-inch archwire in a 0.022 × 0.028 bracket slot, then these stabilizing arch wires will need to be replaced with working arch wires.

Working arch wires

The type of working archwire required in either the maxillary or mandibular arch depends on the tooth movements desired. Often the most important initial movement is to guide the teeth vertically into a better dental occlusion. The orthodontist must decide on the teeth they would like to extrude, and in which arch. The dimensions and material of the flexible archwire depend on the other types of movement that may be required, e.g., torque control, but the following are commonly used postoperatively:

- Braided (multistrand) stainless steel – 0.017, or 0.018 or 0.019 × 0.025-inch.
- TMA (titanium-molybdenum alloy) – 0.017, or 0.018 or 0.019 × 0.025-inch.
- Nickel–titanium (NiTi) – 0.017, or 0.018 or 0.019 × 0.025-inch.

Kobayashi ligatures

As described previously, these are very useful means of attachment for orthodontic elastics, and should be placed as required.

Intermaxillary working elastics

The configuration of the working intermaxillary elastics depends on the type and direction of desired tooth movement. Incorrectly placed elastics will result in undesirable tooth movement; therefore, every effort must be made to ensure that patients do not incorrectly position them.

Retention

Retention protocol

Retention protocols and regimes vary from unit to unit¹⁰. Retainers should ideally be made and fitted on the same day as appliance removal, or at least within 1–2 days. Retainer wear begins close to full time, except for eating and cleaning of the teeth and retainers. This first 3–4 months of close to full time wear is to permit time for reorganization of the periodontal ligament and supporting tissues¹¹. Wear may be reduced to evening and nights only after 3–4 months, and gradually onto nights only, which may be continued for between 12 to 24 months.

References

1. Angle EH. Classification of malocclusion. Dent Cosmos 1899 ;41;248-64, 350-7.
2. William R Proffit. Contemporary Orthodontics. 4th Edition: 4,5.
3. Mageet AO. Classification of Skeletal and Dental Malocclusion: Revisited. StomaEduJ. 2016 ;3(2).
4. Posnick, Jeffrey C. Orthognathic Surgery || Definition and Prevalence of Dentofacial Deformities, 2014; 61–68.
5. Johan P Reyenke. Essentials of Orthognathic Surgery. 2nd Edition.
6. Farhad B. Naini, Daljit S. Gill, Orthognathic Surgery: Principles, Planning and Practice.
7. Motamedi, Mohammad Hosein Kalantar. A Textbook of Advanced Oral and Maxillofacial Surgery Volume 3 || Osteotomies in Orthognathic Surgery., 2016; 10.5772/61140(Chapter 27).
8. Andrews LF. The straight-wire appliance, origin, controversy, commentary. J Clin Orthod.1976;10:99–114.
9. Andrews LF. The straight-wire appliance. Explained and compared. J Clin Orthod.1976;10:174–95.
10. Reitan K. Tissue rearrangement during retention of orthodontically rotated teeth. Angle Orthod.1959;29:105–13.
11. Reitan K. Principles of retention and avoidance of posttreatment relapse. Am J Orthod.1969;55:776–90.